



Comparative study evaluating the efficiency of cooled and uncooled single-treatment MWA in thyroid nodules after a 3-month follow up

Oscar Maximilian Mader^{a,*}, Nadine Farivar Tanha^a, Alexander Mader^a,
Christian Happel^{a,b}, Yücel Korkusuz^a, Frank Grünwald^{a,b}

^a Department of Nuclear Medicine, University Hospital Frankfurt, Germany

^b German Centre for Thermoablation of Thyroid Nodules, University Hospital, Frankfurt, Germany

ARTICLE INFO

Article history:

Received 5 December 2016

Received in revised form 17 January 2017

Accepted 22 January 2017

Available online 5 February 2017

Keywords:

Microwave ablation

Volume reduction of thyroid nodules

Single-treatment

Pain scale MWA

ABSTRACT

Objective: The aim of this study was to evaluate and compare the efficacy of single-treatment cooled and uncooled microwave ablation in thyroid nodules.

Methods: Eighteen patients (11 women) with an average age of 62 years (range: 41–80) with 18 cold, mainly solid or solid thyroid nodules were treated with cooled or uncooled microwave ablation. Pain during the treatment was measured on a 10-point score. Side effects revealed by ultrasound or patients' complaints were documented. Laboratory data was evaluated before, 24 h and three months after MWA. Nodule volumes were measured before and three months after MWA.

Results: Cooled MWA was better tolerated than uncooled MWA. A significant reduction of thyroid nodule volume was observed in all cases. The reduction after cMWA was higher (40%) than after uMWA (29%). Pain intensity during cMWA was significantly lower than after uMWA. CMWA and uMWA led to a significant decrease of nodule blood circulation and echogenicity and to a significant increase of nodule elasticity. Thyroid function remained intact in all cases. The energy (kJ/s) administered into the nodules in relation to the ablation time during cMWA was higher than during uMWA.

Conclusions: CMWA leads to a slightly higher but statistically not significant nodule volume reduction than uMWA. Patient comfort during cMWA is higher than during uMWA. The risk of unintended side effects is less in cMWA. A Single-treatment provides sufficient results.

© 2017 The Author(s). Published by Elsevier Ltd. This is an open access article under the CC BY-NC-ND license (<http://creativecommons.org/licenses/by-nc-nd/4.0/>).

1. Introduction

Thyroid goiters with growing, mostly benign nodules are found in about 4–8% of the general population by means of palpation and in about 19–67% using ultrasound [1], which make thyroid nodules a widely spread medical condition. Compression of trachea and oesophagus often cause local symptoms, ranging from cosmetic issues, over pain issues to difficulties in swallowing [2].

Large thyroid nodules can even lead into a life-threatening respiratory crisis [3]. Mitigation of patients' suffering and most notably the prevention of malignant reorganization make treatment of symptomatic nodules inevitable. As gold standard, surgery

is associated with a long list of risks such as injury of the recurrent laryngeal and vagus nerve, damage of the parathyroid glands, wound healing disorders, risk of infection, secondary hemorrhage, long hospitalization, and anaesthetic complications [4].

This is particularly a problem for older, multi morbid patients. Thus, various non- and minimal invasive approaches as laser ablation, ethanol injection, high intensity focused ultrasound and radiofrequency ablation have been attempted and have proven to be an effective alternative approach by a variety of international literature [5–7].

As common treatment method of benign tumours of kidney and liver, microwave ablation (MWA) has proven good results in the treatment of benign thyroid nodules as well and is hence another safe and excellently tolerated treatment alternative of thyroid goiters with symptomatic nodules [6,8]. MWA heats tissue to cytotoxic levels through which cell death is caused. Afterwards the created coagulative necrosis is degraded by the patient's own immune system [9]. An electromagnetic field around the applicator antenna forces water molecules in the ablated tissue to oscillate during the microwave ablation, causing kinetic heat in the ablation zone [10].

Abbreviations: MWA, microwave ablation; cMWA, cooled microwave ablation; uMWA, uncooled microwave ablation; IC, internally cooled shaft antenna; NIC, non-internally; RIT, radioiodine therapy cooled shaft antenna; PEIT, Percutaneous ethanol injection; RFA, radiofrequency ablation; US, ultrasound.

* Corresponding author.

E-mail address: max.mader@gmx.de (O.M. Mader).

<http://dx.doi.org/10.1016/j.ejro.2017.01.004>

2352-0477/© 2017 The Author(s). Published by Elsevier Ltd. This is an open access article under the CC BY-NC-ND license (<http://creativecommons.org/licenses/by-nc-nd/4.0/>).

This leads to one of the main side effects of original MWA: skin burn around the ablation area due to the high temperature that is generated in the probe [11].

The aim of this study is to evaluate whether there are any relevant differences between internally cooled shaft or non-internally cooled shaft microwave ablation relying on patients safety and treatment efficiency and if one of the methods should be preferred. The internally water-cooled applicator of the cMWA and the real-time temperature control without cooling system in the uMWA applicator may each have different influences on the tissues surrounding the ablated area during the ablation mechanism resulting in different treatment success. Our study is the first comparing the treatment success of uncooled- and cooled-MWA after a single treatment session.

2. Material and methods

2.1. Patients

Eighteen patients (11 women) with an average age of 62 years (range: 41–80) and a total of 18 thyroid nodules matching the entry criteria were recruited for this study. Both nine patients underwent uncooled and cooled single-treatment microwave ablation. Inclusion criteria for this study were either: symptomatic cold and mainly solid or solid benign thyroid nodules that made treatment inevitable (e.g. local compression syndromes, foreign body sensation), high operative risks, previous thyroidectomy or refusal of surgery [2]. Exclusion criteria for this study were either: thyroids with retrosternal growth and or critical positions near vessels, the recurrent laryngeal and vagus nerve, oesophagus or trachea.

The entry criteria for this study were:

- growing goiters
- symptomatic cold benign thyroid nodules
- mainly solid or solid nodules
- cosmetic concerns
- high operative risk
- refusal of surgery

The exclusion criteria for this study were:

- thyroids with retrosternal growth
- critical positions near vessels, nerves, oesophagus or trachea

2.2. Pre-ablative assessment

All patients underwent pre-therapy assessments (T0), 24 h post-ablation assessment (T1) and three month follow up (T2) including B-mode ultrasound and laboratory.

2.3. Laboratory evaluation

A complete thyroid hormone status, including triiodothyronine, thyroxine, thyrotropine and thyroglobuline was analysed. Further, antibody detection tests against thyroid peroxidase (TPOAb), thyroglobulin (TgAb) and thyrotropin receptor (TRAb) were performed. All tests were determined with commercially available immunoradiometric assay (IRMA) or radioimmunoassay (RIA) kits and had following reference ranges:

T3: 1.0–3.3 nmol/L; T4: 55–170 nmol/L; TSH: 0.3–4.0 mE/L; Tg: 2–70 ng/mL; TPOAb: <50 IU/mL; TgAb: <50 IU/mL; TRAb: <1.5 IU/L

2.4. Ultrasound evaluation

In this study, B-mode ultrasound images were used to evaluate the size, volume, composition, and vascularisation of the thyroid

and the nodules. All images were conducted by the “SonixTOUCH Ultrasound system[®]” (Ultrasonix Medical Corporation, Richmond, Canada). Doppler blood flow, elasticity and echogenicity were categorized as described below: Doppler blood flow was measured on a three-point scale (no perfusion = 1; slight perfusion = 2; marked perfusion = 3). A colour-coded ultrasound elasticity output was used to measure elasticity on four-point scale (soft = ES 1, more soft than solid = ES 2, more solid than soft = ES 3, solid = ES4) [12]. Echogenicity was measured on a three-point scale (hypo-echogenic = 1; isoechoenic = 2; hyper-echogenic = 3).

2.5. Microwave ablation equipment

The cooled microwave ablation was performed with the HS Amica microwave ablation system. The system generates a maximum output power of 100 W (60 W recommended) at a frequency of 2450 MHz with a 14-gauge or 17-gauge water-cooled applicator [13]. The uncooled microwave ablation was performed with the Avecure MWG 881 (MedWaves, Inc. San Diego, CA). The system consists of a microwave generator, a flexible low-loss coaxial cable and an antenna. It generates a variable output power from 24 to 28 W at a frequency of 902–928 MHz. Depending on the target area and the volume of the nodule (14–16 G; small, medium or large), different probes can be used to achieve the target temperature of 60–80 °C (max. 140 °C) with an ablation field of 1–4 cm [14–16]. The frequency is automatically controlled with real-time temperature and reverse-power feedback during ablation to optimize ablation safety, efficiency, energy transfer, and predictability.

2.6. Procedure

In order to provide the best possible access to the thyroid, the patient was placed in a supine position with a hyperextended neck. First, the nodule was reevaluated by B-mode ultrasound. Next, the injection site was determined and local anaesthesia (Mepivacain-hydrochloride 1%) and analgesics (Novalgin[®] IV) were applied. A trans-isthmus access with a small skin incision was chosen as it provides a good visualization of the probe and thus prevents damage to vital structures such as the recurrent laryngeal nerve, oesophagus and trachea. If this approach was not possible, a cranio-caudal access was chosen alternatively. In case of a cystic nodule, the anaesthetic needle could be used to drain the nodule fluid in order to minimize its preoperative ablation volume and to reduce possible heat-sink effects [17]. Yet, the nodules in this study were all mainly solid or solid and could therefore not benefit from this procedure. After making a small skin incision (1–2 mm), the ablation antenna was placed into an exact position under sonographic monitoring. At this point the actual ablation started. Intra-nodular ion movement around the dipole, lead to a temperature raise of the tissue to 60–110 °C, resulting in irreversible coagulation necrosis and hence echo transformation of the nodule. Energy transfer was maintained until the entire nodule appeared hyper-echogenic and was coated with micro bubbles, visualizing the heat created during MWA. After the ablation, the integrity of the recurrent laryngeal nerve was verified by talking to the patient in order to exclude possible phonation anomalies. The complete procedure was performed under aseptic conditions.

2.7. Statistical analysis

Statistical analysis was performed using Prism 6 for Mac OS X Version 6.0 f (GraphPad Software, La Jolla, California, USA). Wilcoxon matched-pairs signed rank tests were performed to compare the sonographic scores mentioned above, before and

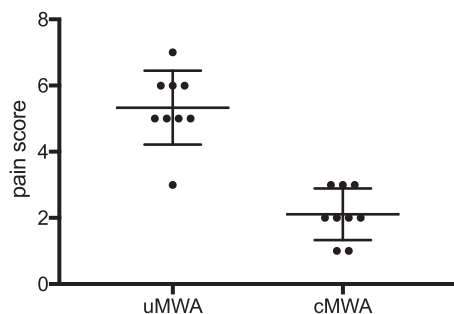


Fig. 1. Comparison of pain patient pain level during non-cooled shaft antenna (uMWA) and cooled-shaft antenna (cMWA) ablation procedure.

after treatment. Statistical significance was indicated with *p*-values <0.05 ($P < 0.05$).

3. Results

3.1. Assessment of patient's tolerance and safety

During the procedure the patients pain level was measured on a 10-point score ranging from “no pain” = 0 to “the most imaginable pain” = 10. Generated side effects revealed by patients' complaints and by ultrasound were documented. With a mean score of 2, pain during cMWA was significantly ($P < 0.05$) lower than pain score during uMWA with a mean of 5. Fig. 1 provides an overview of the pain scores evaluated during cMWA and uMWA. An interruption during the procedure was not necessary, yet cMWA was noticeably better tolerated than uMWA. All nine uMWA patients suffered post ablative first degree burns as well as superficial hematoma, while none of the cMWA patients suffered any of the aforementioned. No serious side effects occurred after any type of ablation. Table 1 summarizes the occurred side effects.

3.2. Assessment of efficacy

Both methods resulted in significant decrease of thyroid volume ($P < 0.05$). No significant differences of thyroid nodule volume reduction between both methods could be observed. Still there was a higher mean nodule volume reduction after cMWA (40%) than after uMWA (29%). Fig. 2 gives an overview of the achieved nodule volume reduction. Cooled MWA resulted in a significant ($P < 0.05$) decrease of blood circulation and echogenicity. Furthermore a significant ($P < 0.05$) increase of nodule elasticity and Tg ($\Delta 4555 \pm 4968$ ng/mL) ($P < 0.05$) were measured. Uncooled MWA resulted in a significant decrease of blood circulation ($P < 0.05$) and echogenicity ($P < 0.05$) with a significant increase in elasticity ($P < 0.05$) and Tg ($\Delta 3635 \pm 5877$ ng/mL) ($P < 0.05$). Tg concentration three months post ablation showed no significant differences to baseline Tg concentration. Thyroid function remained intact in all cases. Table 2 provides an overview of the evaluated data.

Table 1
Overview of occurred side effects.

Side effects	n (%) cMWA	n (%) uMWA
Pain score during ablation (mean)	2	5
Hematoma	9 (100%)	0 (0%)
Hoarseness	0 (0%)	0 (0%)
Burns (1st degree)	0 (0%)	9 (100%)
Infection	0 (0%)	0 (0%)
Nodule rupture	0 (0%)	0 (0%)
Dysphagia	0 (0%)	0 (0%)
Horner's syndrome	0 (0%)	0 (0%)
Vagal reaction	0 (0%)	0 (0%)

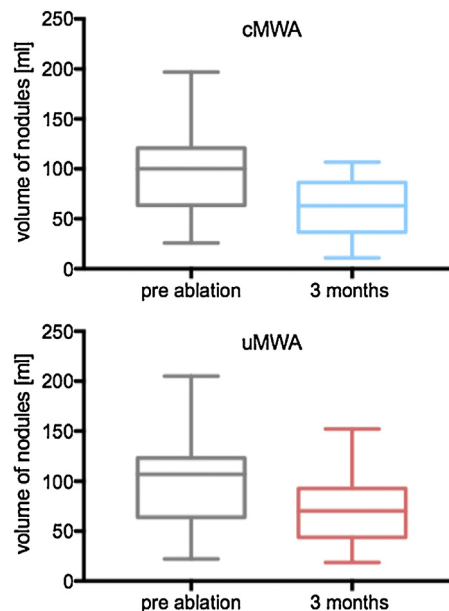


Fig. 2. Comparison of nodule volumes pre and 3 months post ablation after cMWA (blue figure) and uMWA (red figure).

4. Discussion

This study is the first one to compare efficiency and safety after uncooled MWA (uMWA) and cooled MWA (cMWA) of thyroid nodules in a single-treatment session. Although RFA is the most popular and widely studied thermal ablation modality it has technical limitations. With its ability to oscillate in all biological tissues, MWA may be able to overcome the latter. There are only few studies dealing with the question whether an internally cooled (IC) antenna or a non-internally cooled (NIC) antenna should be preferred in ablation devices. The aim of this study was to analyse whether cMWA or uMWA enables a more secure and effective ablation procedure referring to occurred side effects, patient pain level, thyroid gland volume reduction and laboratory data.

Various studies deal with volume reduction after thermal ablation of thyroid nodules. In this study a mean nodule volume reduction of 29% ($P < 0.05$) was reached after uMWA while a mean reduction of 40% ($P < 0.05$) was reached after cMWA in a total of 18 cold and solid or mainly solid thyroid nodules after a three-month follow up. Feng et al. reported from a mean nodule volume reduction ratio of 46% after 12 months while Yue et al. observed a volume reduction ratio greater than 50% in 82% (209 of 254) of measured nodules in a six-month follow up [2,5]. Compared to the aforementioned results, volume decrease reached in this study was lower. A possible reason may be the shorter follow up time of three months. Even though the largest volume reduction could be observed in this interval, there is still a significant reduction afterwards [5]. A further reason for the differences concerning volume reduction may be the composition of the ablated nodules. The authors of the aforementioned studies classified the treated nodules into either solid, mainly solid, mainly cystic, or cystic nodules. All nodules treated in our study were defined as mainly solid or solid. Several studies have proven that cystic nodules show larger volume reduction than complex or solid ones. This can most likely be related to the extraction of the cystic component after draining the nodule during the ablation procedure [2,5].

Two different types of microwave ablation devices were used in this study. The generator used for uMWA is only capable of producing 24–28 W at a frequency of 902–928 MHz. The system used for cMWA is capable of producing 50 W at a frequency of

Table 2
Overview of results.

patient				Nodule	Pain Score	Δ Echo-genicity	Δ Elasto-graphy	Δ Vascular-isation	Δ volume reduction 3 months
no.	age	ablation	gender	volume [mL]					
1	77	uMWA	W	205	5	0	1	1	53
2	66	uMWA	W	107	5	1	0	0	33
3	72	uMWA	W	130	6	0	0	0	50
4	55	uMWA	W	22	6	2	1	2	3.7
5	80	uMWA	W	81	7	1	2	2	17
6	62	uMWA	M	117	3	1	1	1	12
7	48	uMWA	M	100.0	6	1	1	0	40
8	55	uMWA	W	46.9	5	1	1	1	20
9	68	uMWA	M	110.0	5	1	1	1	40
1	75	cMWA	W	48	2	1	2	1	15
2	41	cMWA	M	100	1	0	2	1	37
3	49	cMWA	W	132	3	1	1	2	35
4	45	cMWA	M	100	1	1	1	1	33
5	47	cMWA	W	79	3	0	1	1	39
6	68	cMWA	M	99	2	1	1	1	45
7	56	cMWA	W	197	2	1	1	1	90
8	77	cMWA	M	26	3	1	0	1	15
9	74	cMWA	W	110	2	1	1	1	34
						$p < 0.05$	$p < 0.05$	$p < 0.05$	$p < 0.05$

2450 MHz and includes an internal water-cooling system. There are no studies analysing advantages of any of these systems for thyroid nodule ablation. Most commonly, two frequencies: 2450 MHz and 915 MHz are used in clinical treatment. Sun et al. investigated two different cooled-shaft systems in porcine liver: one running with 2450 MHz, another one running with 915 MHz. Their results show that microwaves with a frequency of 915 MHz create significantly larger ablation zones and furthermore have a deeper penetration depth than microwaves with a frequency of 2450 MHz [18]. The results of our study show that the cooling system of an ablation device might have a larger influence on the volume decrease than the frequency the system is running with. However, further studies are necessary to sufficiently determine the best possible frequency of MWA.

This study detected a significant reduction of patient pain score during cMWA compared to uMWA ($P < 0.05$) (mean pain score of 2 during cMWA vs. 5 during uMWA). A study of Korkusuz et al. describing initial experiences after cMWA also reported an intrablatable pain score of 2 which is comparable to the results presented in the current study [9]. He et al. compared the temperatures created at the antenna shaft during IC and NIC MWA and found out, that the temperature during IC MWA did not exceed 20 °C while temperatures up to 90 °C were measured at the non internally cooled antennas shaft [19]. This leads to higher patient pain levels and may lead to severe damages as voice changes and nerve palsy as reported by multiple studies and supported by the results of our study [2,5]. None of the patients in this study suffered serious side effects.

All participants treated with cMWA suffered superficial hematoma. The increasing heat created among the uncooled antenna shaft in the uMWA collective through which vessels around the antenna are destroyed leads to a lack of hematoma. However, all patients treated with uMWA suffered heat sensitivity and first degree burns, while none of the cMWA patients suffered any of the aforementioned. A reduction of side effects and an increase of patient's comfort during the ablation procedure was achieved by using cooled-shaft antenna MWA [19,20]. Liang et al. also reported a significantly higher number of skin burns after non-cooled-shaft antenna MWA of malignant liver tumours compared to cooled-shaft antenna MWA in a collective of 1136 patients [21]. The mean ablation energy brought into the nodule was about 15 kJ in 720 s during uMWA and about 24 kJ in 542 s during cMWA.

In order to evaluate the treatment success after microwave ablation, nodule elasticity, echogenicity, and Doppler blood-flow

were compared pre- and post-surgical via B-mode ultrasonography. Ultrasonography provides a fast and cost-effective method to diagnose and evaluate thyroid nodules [22]. Significant decrease of echogenicity (uMWA $P < 0.05$, cMWA $P < 0.05$) and Doppler blood-flow (uMWA $P < 0.05$, cMWA $P < 0.05$) pointed out ablation success. Elasticity significantly increased after MWA ($P 0.0156$). No significant differences between the changes of elasticity, echogenicity and vascularization after cMWA and uMWA were observed. Thermal ablation procedure leads to elevated tissue stiffness (elasticity change) due to protein denaturation and dehydration [15,23]. Feng et al. reported a significant decrease in nodule vascularization after MWA as well [2]. The results of B-mode ultrasonography and colour-coded Doppler ultrasound are limited because the method is susceptible to artefacts though ultrasound is an easily feasible method to measure nodular changes after microwave ablation treatment [24]. IC MWA and NIC MWA both lead to a significant increase of Tg-concentration (uMWA $P < 0.05$, cMWA $P < 0.05$) 24 h after treatment. No significant (uMWA $P > 0.05$, cMWA $P > 0.05$) differences between baseline Tg-concentration and three-month follow up Tg-concentration were observed. The fact that Tg-concentration changed drastically after MWA procedure is most likely referable to the destruction of nodule tissue. Valcavi et al. reported significant changes of serum Thyroglobulin after ablation procedure is induced by a high distribution of Tg due to thyroid injury. Still Thyroglobulin is a nonspecific parameter as it reflects thyroid injury but simultaneously also the change of thyroid mass [25]. Laboratory findings did not change significantly after MWA. As shown in various studies our results support the thesis that thyroid gland function remains intact after MWA procedure [2,5,26]. Our results underline the thesis that cMWA is advantageous compared to uMWA. Furthermore, the results achieved in our study with a single treatment session are well comparable to those achieved with multiple treatment sessions in means of thyroid nodule volume reduction. It must be underlined that the results achieved in this study are preliminary due to the short follow-up period and the relatively small patient collective. Further studies with a longer follow-up time and a larger number of patients are necessary to sufficiently provide scientific evidence to support the results achieved in this study.

5. Conclusion

None of the patients in this study, neither of the cMWA, nor of the uMWA collective suffered any severe side effects. However, we

came to the conclusion that cMWA should become the first-choice procedure in order to reduce the risk of severe unintended skin burns and further side effects, and not least because the patient's tolerance of cMWA was much higher compared to their tolerance of uMWA relying on the much lower individual pain score during cMWA procedure. Another advantage of cMWA is that this method enables a greater delivery of microwave energy leading to a larger ablation zone, while reducing the number of necessary ablation sessions required and thus increasing patient comfort.

Clinical relevance

Cooled MWA and uncooled MWA both lead to a significant reduction of thyroid gland volume in a single treatment session.

Thyroid function remains intact.

Patient pain level during uncooled MWA is significantly higher than during cooled MWA.

Cooled MWA reduces the risk of unintended side effects like severe skin burn around the ablation area compared to uncooled MWA.

Conflict of interest

The authors declare that there is no conflict of interest.

Disclosure paragraph

1) The scientific guarantor of this publication is Prof. Dr. Frank Grünwald.

2) The authors of this manuscript declare no relationships with any companies, whose products or services may be related to the subject matter of the article.

3) The authors state that this work has not received any funding.

4) No complex statistical methods were necessary for this paper.

5) Institutional Review Board approval was obtained.

6) Only if the study is on human subjects:

Written informed consent was obtained from all subjects (patients) in this study.

7) Approval from the institutional animal care committee was not required because: No animal study

8) Some study subjects or cohorts have been previously reported: No.

9) Methodology:

- retrospective case-control study performed at one institution

References

- [1] W.-J. Moon, J.H. Baek, S.L. Jung, et al., Ultrasonography and the ultrasound-based management of thyroid nodules: consensus statement and recommendations, *Korean J. Radiol.* 1 (2011) 1–14.
- [2] B. Feng, P. Liang, Z. Cheng, et al., Ultrasound-guided percutaneous microwave ablation of benign thyroid nodules: experimental and clinical studies, *Eur. J. Endocrinol.* 6 (2012) 1031–1037.
- [3] J. Klubo-Gwiedzinska, L. Wartofsky, Thyroid emergencies, *Med. Clin. N. Am.* 2 (2012) 385–403.
- [4] C. Happel, H. Korkusuz, D. Koch, F. Grünwald, W. Kranert, Combination of ultrasound guided percutaneous microwave ablation and radioiodine therapy in benign thyroid diseases, *Nuklearmedizin* (2015).
- [5] W. Yue, S. Wang, B. Wang, et al., Ultrasound guided percutaneous microwave ablation of benign thyroid nodules: safety and imaging follow-up in 222 patients, *Eur. J. Radiol.* 1 (2013) e11–e16.
- [6] H. Korkusuz, C. Happel, K. Heck, H. Ackermann, F. Grünwald, Percutaneous thermal microwave ablation of thyroid nodules, *Nuklearmedizin* 4 (2014) 123–130.
- [7] H. Korkusuz, N. Fehre, M. Sennert, C. Happel, F. Grünwald, Early assessment of high-intensity focused ultrasound treatment of benign thyroid nodules by scintigraphic means, *J. Ther. Ultrasound* (2014) 18.
- [8] C. Happel, H. Korkusuz, W. Kranert, F. Grünwald, Combination of ultrasound guided percutaneous microwave ablation and radioiodine therapy for treatment of hyper- and hypofunctioning thyroid nodules, *Nuklearmedizin Nucl. Med.* 6 (2014) N48.
- [9] Y. Korkusuz, O.M. Mader, W. Kromen, et al., Cooled microwave ablation of thyroid nodules: initial experience, *Eur. J. Radiol.* 11 (2016) 2127–2132.
- [10] C.L. Brace, Radiofrequency and microwave ablation of the liver, lung, kidney, and bone: what are the differences? *Curr. Probl. Diagn. Radiol.* 3 (2009) 135–143.
- [11] L.S. Poulou, E. Botsa, I. Thanou, P.D. Ziakas, L. Thanos, Percutaneous microwave ablation vs radiofrequency ablation in the treatment of hepatocellular carcinoma, *World J. Hepatol.* 8 (2015) 1054–1063.
- [12] J.H. Baek, Y.S. Kim, D. Lee, J.Y. Huh, J.H. Lee, Benign predominantly solid thyroid nodules: prospective study of efficacy of sonographically guided radiofrequency ablation versus control condition, *Am. J. Roentgenol.* 4 (2010) 1137–1142.
- [13] M.G. Lubner, C.L. Brace, J.L. Hinshaw, F.T. Lee, Microwave tumor ablation: mechanism of action clinical results, and devices, *J. Vasc. Interv. Radiol.* 8 (2010) S192–S203.
- [14] H. Korkusuz, F. Nimsdorf, C. Happel, H. Ackermann, F. Grünwald, Percutaneous microwave ablation of benign thyroid nodules, *Nuklearmedizin* 1 (2015) 13–19.
- [15] H. Korkusuz, C. Happel, J. Klebe, H. Ackermann, F. Grünwald, Diagnostic accuracy of elastography and scintigraphic imaging after thermal microwave ablation of thyroid nodules, *RoFo: Fortschritte auf dem Gebiete der Röntgenstrahlen und der Nuklearmedizin* (2015).
- [16] H. Korkusuz, C. Happel, F. Grünwald, Ultrasound guided percutaneous microwave ablation of hypofunctional thyroid nodules: evaluation by scintigraphic ^{99m}Tc-MIBI imaging, *Nuklearmedizin* 6 (2013).
- [17] N. Basu, D. Dutta, I. Maisnam, et al., Percutaneous ethanol ablation in managing predominantly cystic thyroid nodules: an eastern India perspective, *Indian J. Endocrinol. Metab.* 5 (2014) 662.
- [18] Y. Sun, Y. Wang, X. Ni, et al., Comparison of ablation zone between 915- and 2,450-MHz cooled-shaft microwave antenna: results in vivo porcine livers, *Am. J. Roentgenol.* 2 (2009) 511–514.
- [19] N. He, W. Wang, Z. Ji, C. Li, B. Huang, Microwave ablation: an experimental comparative study on internally cooled antenna versus non-internally cooled antenna in liver models, *Acad. Radiol.* 7 (2010) 894–899.
- [20] D. Jiao, L. Qian, Y. Zhang, et al., Microwave ablation treatment of liver cancer with 2,450-MHz cooled-shaft antenna: an experimental and clinical study, *J. Cancer Res. Clin. Oncol.* 10 (2010) 1507–1516.
- [21] P. Liang, Y. Wang, X. Yu, B. Dong, Malignant liver tumors: treatment with percutaneous microwave ablation—complications among cohort of 1136 patients 1, *Radiology* 3 (2009) 933–940.
- [22] D.S. Dean, H. Gharib, Epidemiology of thyroid nodules, *Best Pract. Res. Clin. Endocrinol. Metab.* 6 (2008) 901–911.
- [23] Van Vledder MG, Boctor EM, Assumpcao LR, et al. Intra-operative ultrasound elasticity imaging for monitoring of hepatic tumour thermal ablation. *HPB* 10 (2010) 717–723.
- [24] J. Klebe, C. Happel, F. Grünwald, H. Korkusuz, Visualization of tissue alterations in thyroid nodules after microwave ablation: sonographic versus scintigraphic imaging, *Nucl. Med. Commun.* 3 (2015) 260–267.
- [25] R. Valcavi, F. Riganti, A. Bertani, D. Formisano, C.M. Pacella, Percutaneous laser ablation of cold benign thyroid nodules: a 3-year follow-up study in 122 patients, *Thyroid* 11 (2010) 1253–1261.
- [26] K. Heck, C. Happel, F. Grünwald, H. Korkusuz, Percutaneous microwave ablation of thyroid nodules: effects on thyroid function and antibodies, *Int. J. Hyperther.* (2015) 1–8, ahead-of-print.