

Nonintubated Uniportal Video-Assisted Thoracoscopic Surgery: A Single-Center Experience

Seha Ahn, M.D.¹, Youngkyu Moon, M.D., Ph.D.¹,
Zeead M. AlGhamdi, M.D.^{1,2}, Sook Whan Sung, M.D., Ph.D.¹

¹Department of Thoracic and Cardiovascular Surgery, Seoul St. Mary's Hospital, College of Medicine, The Catholic University of Korea, ²Department of Surgery, College of Medicine, Imam Abdulrahman Bin Faisal University

Background: We report our surgical technique for nonintubated uniportal video-assisted thoracoscopic surgery (VATS) pulmonary resection and early postoperative outcomes at a single center. **Methods:** Between January and July 2017, 40 consecutive patients underwent nonintubated uniportal VATS pulmonary resection. Multilevel intercostal nerve block was performed using local anesthesia in all patients, and an intrathoracic vagal blockade was performed in 35 patients (87.5%). **Results:** Twenty-nine procedures (72.5%) were performed in patients with lung cancer (21 lobectomies, 6 segmentectomies, and 2 wedge resections), and 11 (27.5%) in patients with pulmonary metastases, benign lung disease, or pleural disease. The mean anesthesia time was 166.8 minutes, and the mean operative duration was 125.9 minutes. The mean postoperative chest tube duration was 3.2 days, and the mean hospital stay was 5.8 days. There were 3 conversions (7.5%) to intubation due to intraoperative hypoxemia and 1 conversion (2.5%) to multiportal VATS due to injury of the segmental artery. There were 7 complications (17.5%), including 3 cases of prolonged air leak, 2 cases of chylothorax, 1 case of pleural effusion, and 1 case of pneumonia. There was no in-hospital mortality. **Conclusion:** Nonintubated uniportal VATS appears to be a feasible and valid surgical option, depending on the surgeon's experience, for appropriately selected patients.

Key words: 1. Nonintubated
2. Uniportal
3. Thoracic surgery
4. Minimally invasive surgical procedures

Introduction

Pulmonary resection by video-assisted thoracoscopic surgery (VATS) with single-lung ventilation has become a well-established modality over the last 3 decades [1]. To reduce surgical stress during VATS, many surgeons have adopted uniportal (single-access) VATS pulmonary resection as an alternative to

multiportal VATS [2,3].

Surgeons continued developing uniportal VATS and other minimally invasive techniques, and in 2004 Pompeo et al. [4] reported the resection of pulmonary nodules by conventional VATS under intravenous anesthesia without endotracheal intubation. Within less than a decade thereafter, complete VATS pulmonary resections under anesthesia without endo-

[†]This article was presented in a forum discussion at the 49th Annual Meeting of the Korean Society for Thoracic and Cardiovascular Surgery.

Received: November 13, 2017, Revised: January 29, 2018, Accepted: January 29, 2018, Published online: October 5, 2018

Corresponding author: Sook Whan Sung, Department of Thoracic and Cardiovascular Surgery, Seoul St. Mary's Hospital, College of Medicine, The Catholic University of Korea, 222 Banpo-daero, Seocho-gu, Seoul 06591, Korea (Tel) 82-2-2258-2858 (Fax) 82-2-594-8644 (E-mail) swsung@catholic.ac.kr

© The Korean Society for Thoracic and Cardiovascular Surgery. 2018. All right reserved.

© This is an open access article distributed under the terms of the Creative Commons Attribution Non-Commercial License (<http://creativecommons.org/licenses/by-nc/4.0>) which permits unrestricted non-commercial use, distribution, and reproduction in any medium, provided the original work is properly cited.

tracheal intubation had been reported for a range of thoracoscopic procedures [5-8]. Avoiding tracheal intubation under general anesthesia can reduce the incidence of adverse events, including intubation-related airway trauma, residual neuromuscular blockade, ventilation-induced lung injury, impaired cardiac performance, and postoperative nausea and vomiting [9-12].

Rocco et al. [13] first reported the results of nonintubated uniportal VATS pulmonary resection in 2010. Since then, several other groups have reported their experiences with more complex procedures, including lobectomy and segmentectomy, using a single incision under anesthesia without endotracheal intubation [5,6]. However, there are insufficient reports of the results of nonintubated uniportal VATS pulmonary resection, including lobectomy and segmentectomy, in Korea.

The purpose of this study was to share our surgical experience with nonintubated uniportal VATS pulmonary resection, and to assess the feasibility of this technique.

Methods

1) Patients

From January 2017 to July 2017, 40 consecutive patients underwent nonintubated uniportal VATS pulmonary resection. We excluded patients with a body mass index (BMI) >30 kg/m², an airway expected to be difficult, persistent cough or excessive airway secretion, a high risk of gastric reflux, expected extensive pleural adhesion, prior pulmonary resection, severe cardiopulmonary dysfunction, and clinical stage N2 lung cancer.

2) Anesthesia

All patients were administered a target-controlled infusion of remifentanyl and propofol and were premedicated with dexmedetomidine by the anesthesiology team. Spontaneous respiration was supported by oxygen (6–9 mL/min via mask in all patients), without an endotracheal tube. Standard monitoring included electrocardiography, non-invasive blood pressure measurements, pulse oximetry, and respiratory rate. The bispectral index (BIS XP, A-2000; Aspect Medical Systems, Norwood, MA, USA) was also used to monitor the level of sedation. The target bispectral

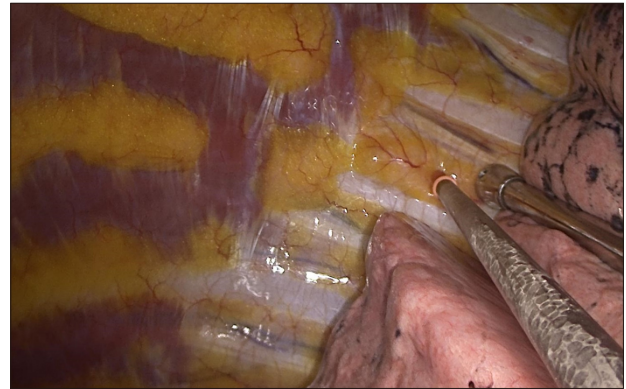


Fig. 1. Intercostal nerve block.

index value was from 40 to 60, and the probe was placed on the forehead. End-tidal carbon dioxide was measured intranasally with a single-nostril catheter.

3) Surgical technique

The patients were positioned in the lateral decubitus position. The surgical incision, approximately 3 to 4 cm long, was made at either the fourth or fifth intercostal space along the anterior axillary line after local anesthesia was injected from the skin into the pleural space (2% lidocaine+0.5% bupivacaine mix). The lung was collapsed by iatrogenic pneumothorax secondary to the surgical incision. The working port was covered with a medium-sized wound protector. A 10-mm 30° scope was positioned on the upper side of the incision by the assistant. Intercostal nerve block was performed in all patients with a 1 mL injection of a mixture of 2% lidocaine and 0.5% bupivacaine into the space beneath the lower margin of each rib, from the third to the ninth rib (Fig. 1). Intrathoracic vagal block was performed in 35 cases (87.5%) to eliminate the cough reflex during more complex procedures, including lobectomies and segmentectomies. The remaining 5 cases (12.5%) did not require an intrathoracic vagal block because the pulmonary procedures were wedge resections for peripheral metastatic nodules and a pleural biopsy for which hilar exposure and manipulation were not needed. For right-sided operations, an intrathoracic vagal block was performed using an infiltration of a mixture of 2% lidocaine and 0.5% bupivacaine (2 mL) in the mediastinal pleura near the vagus nerve emerging from the paratracheal area (Fig. 2A). For

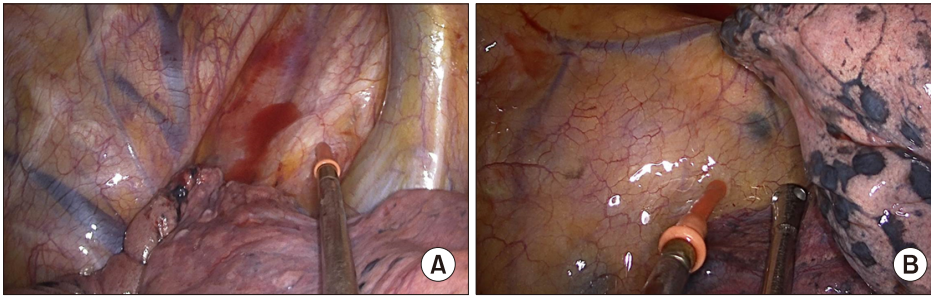


Fig. 2. Intrathoracic vagus nerve block. (A) Right. (B) Left.

Table 1. Patients' clinical characteristics (n=40)	
Characteristic	Value
Age (yr)	60.6±13.8
Sex	
Male	17 (42.5)
Female	23 (57.5)
Current or former smoker	12 (30.0)
Body mass index (kg/m ²)	23.7±2.5
Pulmonary function (%)	
Forced expiratory volume in 1 second	90.7±18.6
Diffusing capacity of the lung for carbon monoxide	85.3±14.1
Diagnosis	
Lung cancer	29 (72.5)
Pulmonary metastasis	7 (17.5)
Benign lung disease	3 (7.5)
Pleural disease	1 (2.5)
Operation	
Wedge resection	10 (25.0)
Segmentectomy	6 (15.0)
Lobectomy	23 (57.5)
Pleural biopsy	1 (2.5)

Values are presented as mean±standard deviation or number (%).

left-sided operations, the intrathoracic vagal block was performed by infiltration of a mixture of 2% lidocaine and 0.5% bupivacaine (2 mL) into the mediastinal pleura near the aortopulmonary window (Fig. 2B).

A curved suction tip and an endoscopic harmonic scalpel (Ethicon Endo Surgery Inc., Johnson & Johnson Medical Spa, Somerville, NJ, USA) were the most frequently used instruments during the procedures. Our usual approach for both upper lobar lobectomies and segmentectomies was in the order of the pulmonary arteries first, then the pulmonary vein, then the bronchi, and finally the incomplete fissures. In lower lobar lobectomies and segmentectomies, the dis-

Table 2. Surgical outcomes	
Variable	Value
Intraoperative nerve block	
Vagus nerve block	35 (87.5)
Intercostal nerve block	40 (100.0)
Anesthesia duration (min)	166.8±52.9
Operation duration (min)	125.9±50.1
Blood loss (mL)	90.9±174.5
Chest tube duration (day)	3.23 (range, 1–13)
Postoperative hospital stay (day)	4.35 (range, 1–18)
Conversion	
Conversion to intubation	3 (7.5)
Conversion to multi-port video-assisted thoracoscopic surgery	1 (2.5)
Conversion to open thoracotomy	0
Complications	7 (17.5)
Prolonged air leak	3 (7.5)
Chylothorax	2 (5.0)
Pleural effusion	1 (2.5)
Pneumonia	1 (2.5)
Mortality	0

Values are presented as number (%), mean±standard deviation, or mean (range).

section and division proceeded from the incomplete fissures to the pulmonary arteries, bronchi, and then the pulmonary vein. The resected lung was removed through the incision using a large lap bag. After thorough dissection of the mediastinal lymph nodes, a 24F chest tube was inserted through the lower incision.

Results

A total of 40 patients, including 17 men and 23 women, with a mean age of 60 years, underwent nonintubated uniportal VATS pulmonary resection. The diagnosis was lung cancer in 29 patients (72.5%), pulmonary metastasis in 7 (17.5%), benign

Table 3. Reason for conversion

Conversion	Operation	Underlying disease	Reason
To intubation			
Case #1	Segmentectomy	Hypertension	Hypoxemia
Case #2	Segmentectomy	Emphysema	Hypoxemia
Case #3	Segmentectomy	Bronchiectasis	Hypoxemia
To multiportal video-assisted thoracoscopic surgery	Lobectomy	0	Pulmonary artery injury
To open thoracotomy	0	0	0

lung disease in 3 (7.5%), and pleural disease in 1 (2.5%), and the operation was lobectomy in 23 patients (57.5%), wedge resection in 10 (25.0%), segmentectomy in 6 (15.0%), and pleural biopsy in 1 (2.5%) (Table 1).

The average anesthesia time and operative duration were 166.8±52.9 minutes and 125.9±50.1 minutes, respectively. The average intraoperative blood loss was 90.9±174.5 mL. The average postoperative chest tube duration was 3.2 days (range, 1–13 days). The average length of hospital stay was 4.4 days (range, 1–18 days). One patient required a 20-day hospital stay due to prolonged air leak (Table 2). There were 3 conversions (7.5%) to intubation, all due to intraoperative hypoxemia in patients undergoing segmentectomy. All these patients maintained oxygen saturation levels above 90%, but extensive respiratory motion caused excessive mediastinal and lung motion, making surgery more difficult. In these patients, hypoxemia resolved after intubation. There was 1 intraoperative conversion (2.5%) to multiportal VATS due to pulmonary artery injury, and there were no conversions to open thoracotomy (Tables 2, 3).

There were 7 complications (17.5%) among the patients: 3 cases of prolonged air leak (lasting longer than 1 week), 2 cases of chylothorax, 1 case of delayed pleural effusion, and 1 case of pneumonia. All 7 complications resolved during the hospital stay. There was no in-hospital mortality (Table 2).

Among the 27 patients diagnosed with lung cancer who underwent either a lobectomy or segmentectomy, 21 (77.8%) underwent a lobectomy and 6 (22%) underwent a segmentectomy. The average operative duration was 143.9±32.2 minutes. The average postoperative chest tube duration was 3.85 days (range, 1–13 days). The average number of dissected lymph nodes was 11.33±7.0. The histology was adenocarcinoma in 26 patients (96.3%) and squamous cell carcinoma in only 1 patient (3.7%). The most

Table 4. Clinicopathological characteristics of patients with lung cancer who underwent anatomical resection (lobectomy or segmentectomy) (n=27)

Variable	Value
Age (yr)	61.6±12.9
Sex	
Male	10 (37.0)
Female	17 (63.0)
Current or former smoker	9 (33.3)
Body mass index (kg/m ²)	23.7±2.4
Pulmonary function (%)	
Forced expiratory volume in 1 second	91.4±21.0
Diffusing capacity of the lung for carbon monoxide	86.7±14.6
Anesthesia duration (min)	188.5±32.4
Operation duration (min)	143.9±32.2
Chest tube duration (day)	3.85 (range, 1–13)
Postoperative hospital stay (day)	5.00 (range, 2–18)
Histology	
Adenocarcinoma	26 (96.3)
Squamous cell carcinoma	1 (3.7)
Pathologic stage	
TisN0M0	1 (3.7)
T1aN0M0	12 (44.4)
T1bN0M0	4 (14.8)
T2aN0M0	5 (18.5)
T2bN0M0	1 (3.7)
T1or2N2M0	4 (14.8)
Operation	
Segmentectomy	6 (22.2)
Lobectomy	21 (77.8)
No. of dissected lymph nodes	11.33±7.0

Values are presented as mean±standard deviation, number (%), mean (range).

frequent pathologic stage was pT1aN0M0 (12 of 27 patients, 44.4%) (Table 4).

Discussion

Conventional VATS pulmonary resection with

1-lung ventilation has become well established over the last 3 decades [1], and our promising initial experience with nonintubated uniportal VATS pulmonary resection indicates that this approach may be a feasible alternative to conventional VATS pulmonary resection with endotracheal intubation for properly selected patients.

Gonzalez-Rivas et al. [3] reported a mean surgical time for uniportal thoracoscopic lobectomy under endotracheal intubation of 154.1±46 minutes and Guo et al. [6] reported an overall mean operative length of nonintubated complete VATS segmentectomy of 166 minutes. In this study, the average operative duration was 125.9±50.1 minutes, which is consistent with the fact that our analysis included both major (72.5%) and minor pulmonary resections.

Three patients (7.5%) in our study, all of whom underwent segmentectomy, developed intraoperative hypoxemia requiring conversion to assisted ventilation with endotracheal intubation. Their BMI did not exceed 30 kg/m², which was one of our selection criteria, but 1 patient had a BMI (26.4 kg/m²) greater than 25 kg/m². Two patients had underlying lung diseases such as emphysema and bronchiectasis. In addition, the patient with emphysema had a poor preoperative lung function test, with a forced expiratory volume in 1 second of 1.46 L (61%) and a diffusing capacity of the lung for carbon monoxide of 6.2 mL/mm Hg/min (39%). However, the other 2 patients' preoperative lung function tests were within the normal range. In addition, 1 patient (2.5%) required intraoperative conversion to multiportal VATS because of a pulmonary artery injury. A lymph node that was proximal to the basal segmental artery was too adhesive to dissect. After the pulmonary artery injury, we decided to add an additional port to suction the blood, so that we could obtain a better operative field. The injured basal segment artery was easily divided using an endostapler afterward. More definite and highly judicious patient selection criteria should be established to avoid these risks. In contrast to our study, Chen et al. [14] reported that 16 of 446 patients (3.6%) required conversion to assisted ventilation with endotracheal intubation because of significant mediastinal movement, persistent hypoxemia, pleural adhesions, ineffective epidural anesthesia, bleeding, and tachypnea. The lower conversion rate in their study may reflect the larger per-

centage of wedge resections in comparison to ours (51.3% versus 25%).

Our postoperative complication rate was 17.5%, which is higher than has been reported in other recent series of nonintubated conventional VATS pulmonary resections [6,15]. Guo et al. [6] reported a postoperative complication rate of 3.1% in a series of nonintubated complete VATS segmentectomies, and Hung et al. [15] had a 6% complication rate in a series of nonintubated uniportal VATS pulmonary resections (31 wedge resections and 1 lobectomy). However, there was no in-hospital mortality in our initial experience, and all the complications were low-grade (I or II) and resolved during the hospital stay. We expect our complication rate to decrease as we accumulate more experience and refine our patient selection process.

There are several limitations to our study. First, the number of patients was small because all the procedures were performed by a single surgeon at our institution. Second, our study was non-randomized and retrospective, but to date no other retrospective study has investigated nonintubated uniportal VATS pulmonary resection, including lobectomy and segmentectomy, in Korea. Lastly, the postoperative complication rate was relatively high, but we believe it can be reduced by strengthening our selection criteria for nonintubated VATS major pulmonary resection.

In conclusion, in our experience, nonintubated uniportal VATS pulmonary resection demonstrated satisfactory early postoperative outcomes (during the first year) in comparison with other studies in the field of minimally invasive thoracic surgery. In the future, nonintubated uniportal VATS appears to be a promising and feasible combined surgical approach for appropriately selected patients.

Conflict of interest

No potential conflict of interest relevant to this article was reported.

References

1. Luh SP, Liu HP. *Video-assisted thoracic surgery: the past, present status and the future.* J Zhejiang Univ Sci B 2006;7:118-28.

2. Gonzalez D, Paradela M, Garcia J, Dela Torre M. *Single-port video-assisted thoracoscopic lobectomy*. Interact Cardiovasc Thorac Surg 2011;12:514-5.
3. Gonzalez-Rivas D, Paradela M, Fernandez R, et al. *Uniportal video-assisted thoracoscopic lobectomy: two years of experience*. Ann Thorac Surg 2013;95:426-32.
4. Pompeo E, Mineo D, Rogliani P, Sabato AF, Mineo TC. *Feasibility and results of awake thoracoscopic resection of solitary pulmonary nodules*. Ann Thorac Surg 2004;78:1761-8.
5. Chen JS, Cheng YJ, Hung MH, Tseng YD, Chen KC, Lee YC. *Nonintubated thoracoscopic lobectomy for lung cancer*. Ann Surg 2011;254:1038-43.
6. Guo Z, Shao W, Yin W, et al. *Analysis of feasibility and safety of complete video-assisted thoracoscopic resection of anatomic pulmonary segments under non-intubated anesthesia*. J Thorac Dis 2014;6:37-44.
7. AlGhamdi ZM, Lynhiavu L, Moon YK, et al. *Comparison of non-intubated versus intubated video-assisted thoracoscopic lobectomy for lung cancer*. J Thorac Dis 2018;10:4236-43.
8. Moon Y, AlGhamdi ZM, Jeon J, Hwang W, Kim Y, Sung SW. *Non-intubated thoracoscopic surgery: initial experience at a single center*. J Thorac Dis 2018;10:3490-8.
9. Minambres E, Buron J, Ballesteros MA, Llorca J, Munoz P, Gonzalez-Castro A. *Tracheal rupture after endotracheal intubation: a literature systematic review*. Eur J Cardiothorac Surg 2009;35:1056-62.
10. Whitehead T, Slutsky AS. *The pulmonary physician in critical care * 7: ventilator induced lung injury*. Thorax 2002;57:635-42.
11. Murphy GS, Szokol JW, Avram MJ, et al. *Postoperative residual neuromuscular blockade is associated with impaired clinical recovery*. Anesth Analg 2013;117:133-41.
12. Tarhan S, Moffitt EA, Taylor WF, Giuliani ER. *Myocardial infarction after general anesthesia*. JAMA 1972;220:1451-4.
13. Rocco G, Romano V, Accardo R, et al. *Awake single-access (uniportal) video-assisted thoracoscopic surgery for peripheral pulmonary nodules in a complete ambulatory setting*. Ann Thorac Surg 2010;89:1625-7.
14. Chen KC, Cheng YJ, Hung MH, Tseng YD, Chen JS. *Nonintubated thoracoscopic surgery using regional anesthesia and vagal block and targeted sedation*. J Thorac Dis 2014;6:31-6.
15. Hung MH, Cheng YJ, Chan KC, et al. *Nonintubated uniportal thoracoscopic surgery for peripheral lung nodules*. Ann Thorac Surg 2014;98:1998-2003.