

Received: 2020.10.01

Accepted: 2021.02.18

Available online: 2021.02.24

Published: 2021.04.07

Iodine Contrast Complex Rash Responding to Topical Steroids: A Case Report

Authors' Contribution:

Study Design A
Data Collection B
Statistical Analysis C
Data Interpretation D
Manuscript Preparation E
Literature Search F
Funds Collection G

ADEF 1 **Mahmoud El-Hussein**
ABDEF 2 **Cima Hamieh**
EG 1 **Elie Zaghrini**

1 Department of Emergency Medicine, Lebanese American University (LAU) Medical Center, Beirut, Lebanon

2 Department of Family Medicine, Lebanese American University (LAU) Medical Center, Beirut, Lebanon

Corresponding Author: Mahmoud El-Hussein, e-mail: Mahmoud.elhussein@lau.edu

Conflict of interest: None declared

Patient: Male, 75-year-old
Final Diagnosis: Delayed IV contrast allergic reaction
Symptoms: Rash
Medication: —
Clinical Procedure: —
Specialty: Dermatology

Objective: Rare co-existence of disease or pathology

Background: Iodine contrast allergy can cause acute and delayed allergic reactions. Just like any other sensitivity reaction, the severity can vary from mild to moderate skin manifestations such as erythematous rash to an even more severe presentation or life-threatening event, such as angioedema and anaphylaxis.


Case Report: This case report discusses a patient who presented to our institution with a diffuse complex rash 2 days after undergoing CT scan imaging with intravenous iodine contrast injection. The rash started by being maculopapular in nature. Later on, the patient developed a purpuric and petechial pattern, and eventually, an acute exanthematous pustulosis rash was noticed. Several attempts to treat the patient with intravenous corticosteroids failed. Three days after admission (5 days after the rash started), topical steroids were used in place of parenteral steroids. The rash showed remarkable improvement in a very short time. The patient was diagnosed with delayed hypersensitivity IV iodine reaction, resistant to parenteral corticosteroids. The workup of such an extensive rash and odd presentation include several laboratory tests and skin testing to be able to rule out more serious differential diagnoses.

Conclusions: This case is unique as it enables us to show the importance of substituting topical management, more specifically, topical steroids that might even replace parenteral steroids, to our management in order to treat allergic reactions, especially in the presence of a rash.

Keywords: Contrast Media • Exanthema • Steroids • Acute Generalized Exanthematous Pustulosis • Exanthema • Hypersensitivity

Abbreviations: IV – Intravenous; CT scan – computed tomography scan; PCP – primary care physician; CRP – C-reactive protein; AKI – acute kidney injury; AGEP – acute generalized exanthematous pustulosis; EBV – Epstein-Barr virus; CMV – cytomegalovirus; SARS-COV2 – severe acute respiratory syndrome corona virus 2; ANA – anti-nuclear antibodies; COVID-19 – coronavirus disease 19; PCR – polymerase chain reaction

Full-text PDF: <https://www.amjcaserep.com/abstract/index/idArt/928930>



1232



—



7



8



Background

One of the adverse effects of medications is an allergic reaction, which can range from only mild erythema to a life-threatening event. Antibiotics, anti-inflammatories, anesthetics, and anti-epileptics are common triggers for an allergic reaction, not to mention iodine contrast, especially when given through an intravenous (IV) route [1]. Reactions to iodine contrast, also known as radiocontrast-associated hypersensitivity reactions, can range from a benign acute-onset to anaphylaxis. In between these 2 extremes, a delayed onset reaction has been identified, that can start more than 3 hours after exposure, and can be seen after 5 days [1,2]. This allergic reaction presents as skin rash and fever and sometimes presents with end-organ damage [2,3]. However, different types of skin rashes have been reported as a manifestation to IV iodine. Maculopapular erythematous rash, bullae, and blisters, some with xerotic eczema, Stevens-Johnson syndrome, acute generalized exanthematous pustulosis (AGEP), and hypersensitivity vasculitis are all manifestations of iodine-induced skin rashes [3]. Although maculopapular eruptions and erythema, urticaria, and even pustular rashes are commonly seen in an allergic reaction, hypersensitivity vasculitis is a rare finding. Hypersensitivity vasculitis, also referred to as leukocytoclastic vasculitis, is usually seen secondary to an infection, and very rarely is due to a reaction to drugs. The rash evolves 1 week after exposure and is associated with low-grade fever, myalgias, and arthralgias. Also of utmost importance is the possibility of finding multiple rash presentations in the same patient experiencing a delayed sensitivity to IV iodine, such as in this case.

The case we are about to present is interesting not only for its presentation but mainly for its response to an unconventional treatment of listed rashes. Management options range from oral antihistamine to oral and IV steroids. Colchicine and dapsone are also systematically used for hypersensitivity purpuric vasculitis; for resistant rashes on the other hand, the use of immunosuppressant therapy is common [4-6]. Topical management is thought to be reserved for mild cases of urticarial and maculopapular rashes; but this patient, with a complex resistant rash, responded only to topical steroids.

Case Report

A 75-year-old man with multiple comorbidities presented to the Emergency Department with diffuse rash, itching, and facial flushing 48 hours after undergoing abdominal CT scan with iodine IV contrast and 72 hours after the beginning of a diffuse abdominal pain that encouraged his primary care physician (PCP) to order this imaging in the first place. As the pain did not resolve, the patient presented to our care with the previously mentioned symptoms and also with a fever of 38.6°C.

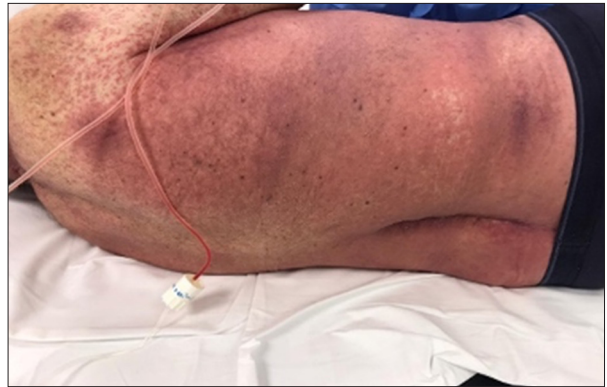

Figure 1. Maculopapular rash over the back and buttocks.

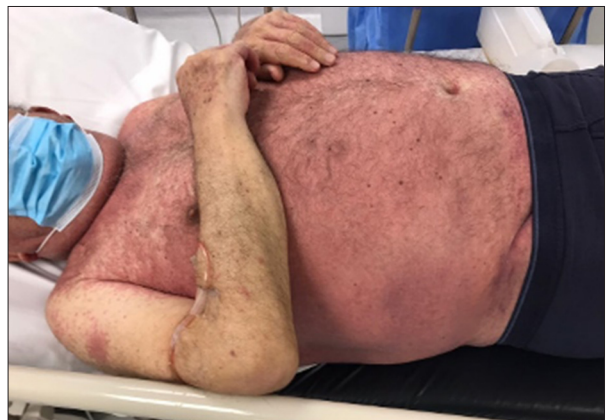

Figure 2. Maculopapular rash over the trunk.

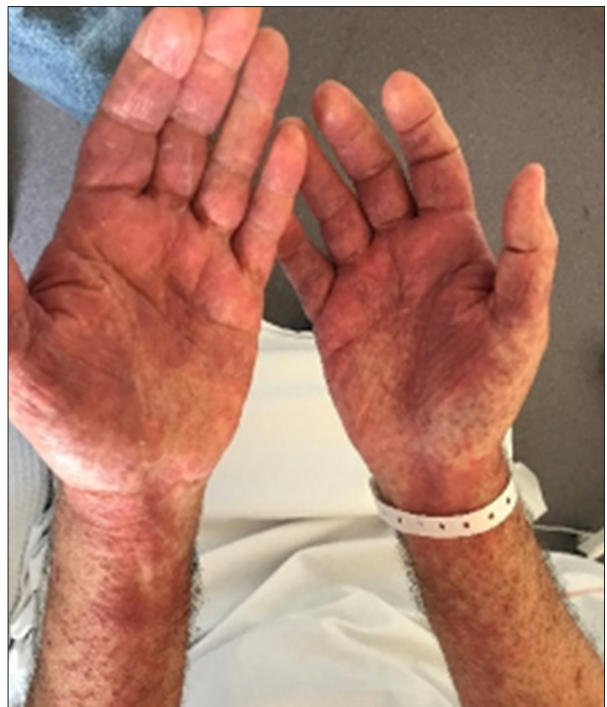

Figure 3. Maculopapular rash over the palms.

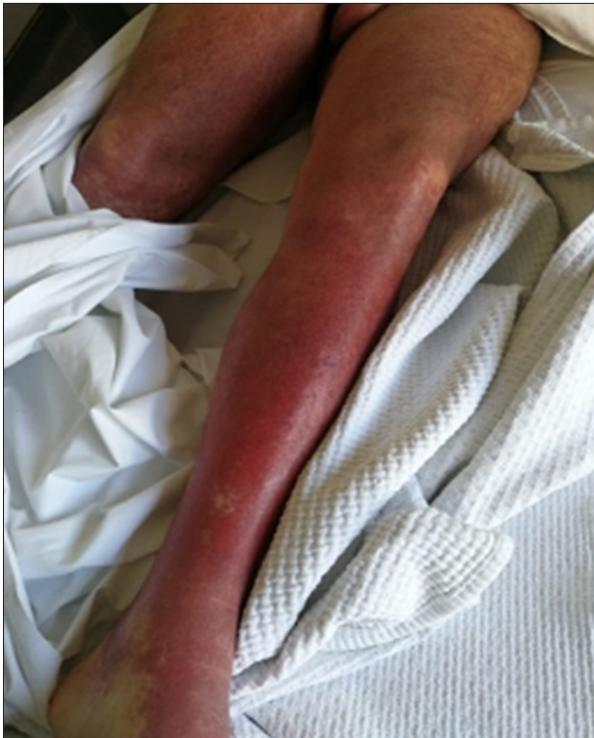

Figure 4. Purpura and petechia over the lower extremities.

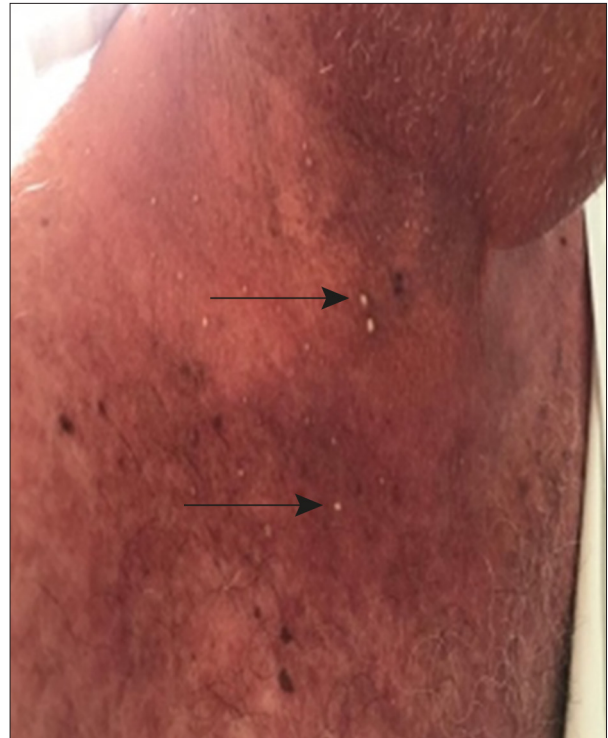


Figure 5. Exanthematous pustulosis over the neck and upper chest. Arrows point to pustulosis.

He denied nausea, vomiting, headaches, dyspnea, and wheezes. On physical examination, the patient had mild facial flushing with an extensive maculopapular rash over his trunk, back, neck, buttocks, and lower and upper extremities, involving the palms (**Figures 1-3**). Upon workup, the patient had an elevated white blood cell count, with no eosinophilia. Elevated CRP was noticed as well as an acute kidney injury (AKI) with hyponatremia. The patient was admitted for further management and was started on IV steroids of 2 mg/kg methylprednisone repeated twice and oral antihistamine and desloratadine 5 mg for 2 days. The patient had received IV iodine contrast on multiple occasions but never experienced a similar reaction.

Review of systems was non-pertinent. His home medications were valproate and topiramate for epilepsy, tamsulosin for prostate hyperplasia, Lisinopril with a hydrochlorothiazide diuretic, and bisoprolol, metformin, and sulfonylurea for diabetes mellitus type II, and esomeprazole for gastritis; none of them is recently added.

After admission, the rash and pruritis did not improve with IV steroids and oral antihistamine, and the lower extremities started developing a non-pitting edema. The patient also developed diffuse arthralgias, with evolution of the rash to petechial and purpuric patterns (**Figure 4**), and AGEP (**Figure 5**). A viral serology workup for hepatitis B and C, EBV, CMV, SARS-COV2, and Group A streptococcus antigen and ANA were all negative.

Next, the patient underwent 2 skin-punch biopsies, one from the back and one from the lower extremity; both were consistent with delayed hypersensitivity reaction to iodinated contrast material, with urticarial vasculitis-like patterns. While awaiting the results, the patient was switched from the IV and oral route treatment to topical steroid, clobetasol (propionate) 0.5 mg/g at a dose of 25 mg, which was applied over the whole body on a daily basis. Forty-eight hours later, the patient showed marked improvement and the rash was almost resolved (**Figures 6, 7**).

The patient was hence diagnosed with delayed hypersensitivity reaction to IV iodine, and treatment was continued for 1 month. Upon follow-up in clinic 1 month after discharge, the patient had resolution of his electrolyte imbalances and AKI, and a complete resolution of his rash.

Discussion

It is not rare for physicians to encounter allergic reactions to iodine; however, in this particular case not only the presentation of the rash was unique, being complex and atypical, but also the management was unusual.

Upon presentation, the patient was found to have a maculopapular rash with fever, and later on developed a purpuric rash with pustules. He was diagnosed with hypersensitivity reaction to IV

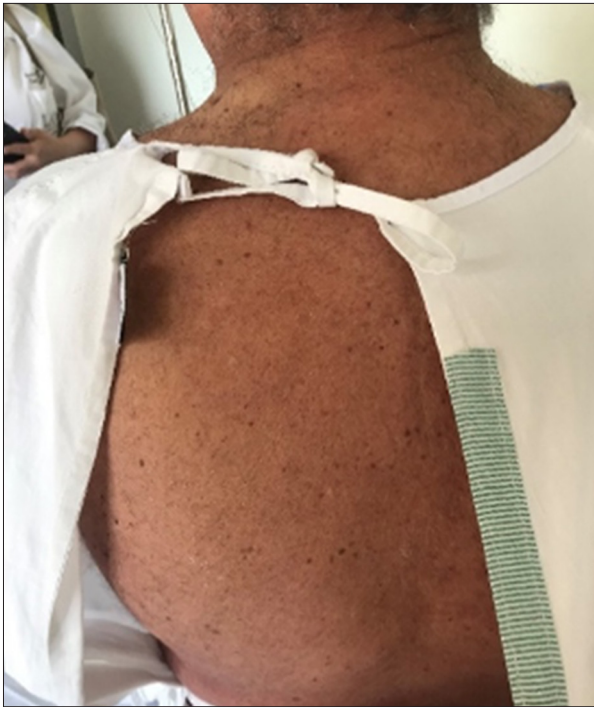

Figure 6. Resolution of the rash over the back.

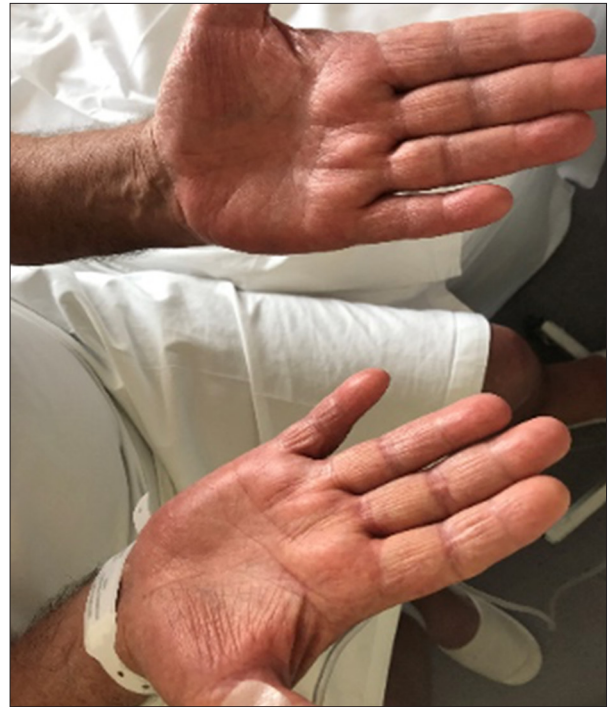

Figure 7. Resolution of the rash over the palms.

iodine contrast. Several differential diagnoses were raised, including an underlying infection process like viral hepatitis, EBV, CMV, and even COVID-19-related hives. Extensive blood tests, imaging, and PCRs were done to find the correct diagnosis. In the evaluation of the purpuric vasculitis per se, the laboratory tests that were done included a complete blood count with differentials, erythrocyte sedimentation rate, liver and renal function tests, and a urinalysis. All of these were used to exclude other vasculitis and to determine the presence of systemic diseases.

Atopic dermatitis or underlying inflammatory conditions such as Henoch-Schoenlein purpura were ruled out by biopsy; allergen skin testing was, however, not performed. It is therefore important to highlight that in this case, our patient most likely had a delayed reaction to IV iodine, causing 3 rash presentations, beginning with the maculopapular rash, then purpuric vasculitis, and lastly AGEP.

As for the management, while the guidelines support the usage of supportive treatment for maculopapular rash secondary to drug reactions and also for AGEP, oral or IV steroids are recommended for hypersensitivity vasculitis; also, one would think that such a severe presentation would require high-dose IV or oral steroids with antihistamine. However, our patient showed marked improvement on only topical steroids.

Limitations

During the management of this case of iodine contrast-induced delayed hypersensitivity reaction, multiple differential diagnoses and underlying etiologies were ruled out. However, the patient did not receive any skin testing, which the literature showed to be helpful in the identification of a T cell-mediated reactions to iodinated contrast. In addition, the fact that the patient had prior exposure to contrast without any documented reaction suggests the importance of skin testing to rule out other causes of this specific allergic reaction [7]. Workup to rule out malignancy should also have been offered to this patient, as the vasculitis he presented with could be a sign of an underlying hematologic or solid malignancy, as it is present in 3.8% of cases [8].

Conclusions

IV iodine contrast may be a cause of a delayed hypersensitivity reactions, causing different kinds of skin rashes. Topical steroids can be an essential part of the treatment regimen, especially if the patient presents with a systemic steroid-resistant rash. The patient in this case most likely had a delayed reaction to iodine contrast, but a definitive diagnosis can only be attained after immunologic and allergen skin testing.

References:

1. InformedHealth.org. Cologne, Germany: Institute for Quality and Efficiency in Health Care (IQWiG); 2006. Drug allergies: Overview. [Updated 2020 May 7]. <https://www.ncbi.nlm.nih.gov/books/NBK447110/>
2. Macy EM. Current epidemiology and management of radiocontrast-associated acute- and delayed-onset hypersensitivity: A review of the literature. *Perm J*. 2018;22:17-72
3. Tasker F, Fleming H, McNeill G, et al. Contrast media and cutaneous reactions. Part 2: Delayed hypersensitivity reactions to iodinated contrast media. *Clin Exp Dermatol*. 2019;44(8):844-60
4. Baigrie D, Bansal P, Goyal A, et al. Leukocytoclastic vasculitis. [Updated 2020 Aug 11]. In: StatPearls. Treasure Island (FL): StatPearls Publishing; 2020. <https://www.ncbi.nlm.nih.gov/books/NBK482159/>
5. Einhorn J, Levis JT. Dermatologic diagnosis: Leukocytoclastic vasculitis. *Perm J*. 2015;19(3):77-78
6. Sangolli PM, Lakshmi DV. Vasculitis: A checklist to approach and treatment update for dermatologists. *Indian Dermatol Online J*. 2019;10(6):617-26
7. Kanny G, Pichler W, Morisset M, et al. T cell-mediated reactions to iodinated contrast media: Evaluation by skin and lymphocyte activation tests. *J Allergy Clin Immunol*. 2005;115(1):179-85
8. Eastham G, Vleugels RA, Callen J. What are the signs and symptoms of a malignant etiology for leukocytoclastic vasculitis (LCV)? *Medscape*. 1999;42(10):2204-12