

This is an Open Access article licensed under the terms of the Creative Commons Attribution-NonCommercial-NoDerivs 3.0 License ([www.karger.com/OA-license](http://www.karger.com/OA-license)), applicable to the online version of the article only. Distribution for non-commercial purposes only.

# Bilateral Corneal Ulceration Caused by Vitamin A Deficiency in Eosinophilic Gastroenteropathy

Alex P. Lange Greg Moloney Claire A. Sheldon  
Sachiko Sasaki Simon P. Holland

Eye Care Center, Cornea Unit, Department of Ophthalmology, University of  
British Columbia, Vancouver, B.C., Canada

## Key Words

Corneal ulcer · Vitamin A deficiency · Xerophthalmia · Xerosis

## Abstract

**Purpose:** Vitamin A deficiency is a very rare condition in the developed world and can lead to a variety of ocular changes from xerosis and xerophthalmia to corneal ulcer and perforation. The treatment of this devastating disease is simple and inexpensive. It is therefore important to recognize and treat accordingly, especially in the event of ulcers unresponsive to treatment or in the presence of severe malnutrition/malabsorption syndromes. The purpose of this case report is to remind physicians of the potentially devastating effects of vitamin A deficiency on the eyes and to demonstrate outcomes after vitamin A treatment.

**Methods:** Single observational case report.

**Results:** A 29-year-old male with known eosinophilic gastroenteropathy was treated with oral steroids for peripheral ulcerative keratitis. Two weeks after resolution, the patient suffered from peripheral ulcerative keratitis in his other eye, with a self-sealing perforation. Vitamin A deficiency was confirmed and successfully treated, leading to subsequent resolution of signs and symptoms.

**Conclusions:** Vitamin A deficiency can be present in patients with malabsorption and malnutrition syndromes and should be considered as cause of corneal ulceration.

## Introduction

Vitamin A deficiency is the leading cause of preventable childhood blindness in the developing world [1]. Although rare in the United States, vitamin A deficiency has been known to occur as a result of poor dietary intake, liver diseases, and gastrointestinal malabsorption [2–5].

Vitamin A is a fat-soluble vitamin ingested in the diet in two forms: as retinol itself from animal sources, such as milk, meat, fish, liver, and eggs, or as the provitamin carotene from plant sources, such as green leafy vegetables, yellow fruits, and red palm oil [6].

On the ocular surface, retinol is necessary for epithelial cell RNA and glycoprotein synthesis. As a result, vitamin A deficiency has a wide range of ocular manifestations including conjunctival and corneal xerosis, keratomalacia, retinopathy, visual loss, and nyctalopia, also called night blindness, which is the earliest and most common symptom [7].

We report a case of bilateral sequential corneal ulceration in a patient with severe vitamin A deficiency in the context of eosinophilic gastroenteropathy.

### Case Report

A 29-year-old man was referred to our cornea unit with a left corneal ulcer of 6 weeks' duration. He was previously diagnosed with eosinophilic gastroenteropathy (biopsy proven), skin atopy and atopic keratoconjunctivitis. He had been treated with peroral steroids 15 mg/day and methotrexate 6 mg/week since the age of 11 years for his gastroenteropathy. He had surgery for steroid-induced cataracts with toric intraocular lens implantation at the age of 27 years. In addition, he had a number of food intolerances and subsisted mostly on a diet of potatoes.

Prior to his presentation, he had noted irritation, itchiness, and a decrease in vision in his left eye for 6 weeks and was treated with topical anti-allergic and topical steroid drops; however, no improvement could be observed. Polymerase chain reaction testing for herpes simplex virus was negative, and the cultures did not show any growth.

Acuity without correction was 20/80 OD, improved by pinhole to 20/50, and 20/150 OS with a manifest refraction of  $-0.25/-2.5/5$ , not improved by pinhole. The intraocular pressure was 19 mm Hg OD and 21 mm Hg OS by tonopen.

Slit-lamp examination showed temporal wrinkling of the conjunctiva in both eyes, with a dry granular pattern and loss of transparency ([fig. 1a](#)). The corneas appeared dull with superficial punctate keratopathy. The left temporal cornea showed an epithelial defect overlying a partial-thickness ulcer with approximately 50% thinning and adjacent limbitis. In both eyes, the anterior chambers were quiet and there were well-centered posterior chamber IOLs. A fundus examination was not possible.

### Results

Our patient was initially diagnosed with peripheral ulcerative keratitis in the left eye in the presence of atopic keratoconjunctivitis. His steroids were increased to 50 mg/day and tapered every 3 days by 10 mg/day. He was put on preservative-free artificial tears. A vasculitic workup (C-reactive protein, erythrocyte sedimentation rate, antinuclear antibody, antineutrophil cytoplasmic antibody, rheumatoid factor, syphilis serology) was unremarkable. Serum was sent for analysis of vitamin A and retinol-binding protein (RBP) levels, with a processing time of several weeks at our location.

The ulcer in the left eye epithelialized over the following 2 weeks and subsequently vascularized from the temporal conjunctiva. Two weeks later, the patient presented to our clinic again with significant right eye pain. He had a corneal ulcer in his right eye, complicated by a small corneal perforation, with the iris plugging the wound ([fig. 2a](#)).

Serendipitously, at that time, the results of his serum vitamin A levels were available, revealing that the levels were significantly decreased to 0.2  $\mu\text{mol/l}$  (normal range 0.9–2.5). The RBP level was also reduced to 12 mg/l (normal 30–92). A diagnosis of vitamin A deficiency with subsequent corneal ulceration was established. The patient was treated with IV Multivitamin (containing 10,000 IU vitamin A, C, D, E and B complex) for 5 consecutive days while in hospital, and then with oral vitamin A 200,000 IU once a week for 2 weeks. The corneal ulcer in his right eye healed (fig. 2b) and the corneal keratinization in both eyes resolved over the following 6 weeks (fig. 1b). Similarly, vitamin A and RBP levels normalized after 6 weeks of treatment.

## Discussion

We present a rare case of vitamin A deficiency secondary to a malnutrition syndrome leading to bilateral xerosis and sequential corneal ulceration. Similar reports from developed populations are rare, but have been described in association with disorders such as chronic alcoholism [8], cystic fibrosis [9], and anorexia nervosa [10].

The initial treatment with an increase of systemic steroids improved the ulceration and seemed to suggest an immunogenic process. However, the involvement of the second eye while on steroid treatment forced consideration of other causes. Clinical suspicion of xerophthalmia at the time of presentation prompted testing for vitamin A and serum RBP. It was unfortunate in our case that the progression of the disease occurred in the time taken for results to be reported. The earliest ocular symptom of vitamin A deficiency is nyctalopia, secondary to depletion of photopigments. Unfortunately, we were not able to obtain an electroretinogram (ERG) before the treatment. An ERG was done on the fifth day of treatment and was reported normal. An abnormal ERG at presentation in association with the anterior segment findings would have helped to establish a diagnosis of vitamin A deficiency before serum levels were available.

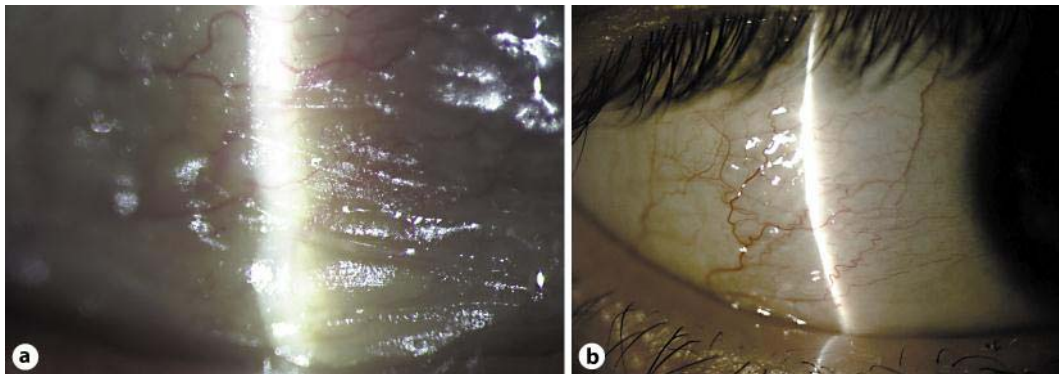
The reason for the vitamin A deficiency is not exactly understood. It has been shown that eosinophilic gastroenteropathy can cause malabsorption or protein-losing enteropathy [11, 12], but in our case, a gastroenterology consult confirmed inactive disease and showed no other signs of malabsorption (normal albumin levels and international normalized ratio). The most likely reason was felt to be malnutrition due to lack of vitamin A uptake secondary to the patient's multiple food intolerances that accompany eosinophilic gastroenteropathy. The long-lasting success of oral vitamin A supplementation further favors previous malnutrition over malabsorption.

The goal of the therapy is the replenishment of vitamin A stores. The oral dosage regimen is 200,000 IU vitamin A in oil, followed the next day with an additional dose of 200,000 IU [13]. If patients have severe corneal disease or malabsorption, the preferred dose is 100,000 IU water-miscible vitamin A administered intramuscularly [14]. It is important to note that if vitamin A deficiency is associated with a protein-energy malnutrition syndrome, protein levels must be corrected at the same time as vitamin supplementation. If this is not done, symptoms will recur within weeks after therapy [14].

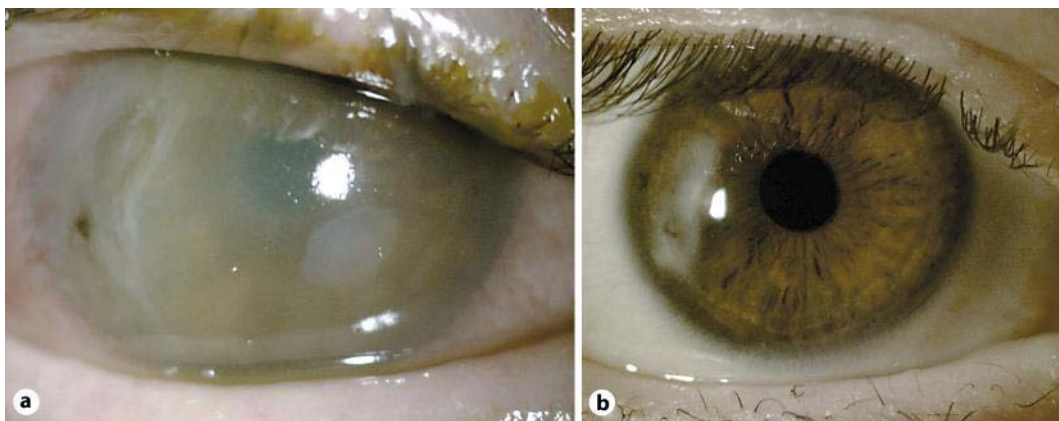
Our case serves as a reminder to corneal specialists in developed populations of the potentially devastating effects of vitamin A deficiency on the eye. Vitamin A deficiency should be suspected in any practice in the presence of corneal ulceration in combination with malabsorption and malnutrition syndromes.

### Disclosure Statement

The authors have no conflict of interest to declare.



**Fig. 1.** **a** Keratinized conjunctiva before vitamin A therapy. **b** Resolved keratinization on the conjunctiva after vitamin A therapy.



**Fig. 2.** **a** Right cornea with temporal perforation, old scar and opacified stroma. **b** Right cornea after vitamin A therapy.

## References

- 1 Thylefors B, Négrel AD, Pararajasegaram R, Dadzie KY: Global data on blindness. *Bull World Health Organ* 1995;73:115–121.
- 2 Bishara S, Merin S, Cooper M, Azizi E, Delpre G, Deckelbaum RJ: Combined vitamin A and E therapy prevents retinal electrophysiological deterioration in abetalipoproteinaemia. *Br J Ophthalmol* 1982;66:767–770.
- 3 Russell RM, Morrison SA, Smith FR, Oaks EV, Carney EA: Vitamin-A reversal of abnormal dark adaptation in cirrhosis. Study of effects on the plasma retinol transport system. *Ann Intern Med* 1978;88:622–626.
- 4 Rogers EL, Douglass W, Russell RM, Bushman L, Hubbard TB, Iber FL: Deficiency of fat soluble vitamins after jejunoileal bypass surgery for morbid obesity. *Am J Clin Nutr* 1980;33:1208–1214.
- 5 Eckert MJ, Perry JT, Sohn VY, Boden J, Martin MJ, Rush RM, Steele SR: Incidence of low vitamin A levels and ocular symptoms after Roux-en-Y gastric bypass. *Surg Obes Relat Dis* 2010;6:653–657.
- 6 Combs G: *The Vitamins: Fundamental Aspects in Nutrition and Health*, ed 2. San Diego, Academic Press, 1998.
- 7 Smith J, Steinemann TL: Vitamin A deficiency and the eye. *Int Ophthalmol Clin* 2000;40:83–91.
- 8 Benitez Cruz S, Gomez Candela C, Ruiz Martin M, Cos Blanco AI: Bilateral corneal ulceration as a result of caloric-protein malnutrition and vitamin A deficit in a patient with chronic alcoholism, chronic pancreatitis and cholecystostomy (in Spanish). *Nutr Hosp* 2005;20:308–310.
- 9 Brooks HL Jr, Driebe WT Jr, Schemmer GG: Xerophthalmia and cystic fibrosis. *Archives Ophthalmol* 1990;108:354–357.
- 10 Berthout A, Sellam M, Denimal F, Lalau JD, Milazzo S: The eye and anorexia nervosa: a case report (in French). *J Fr Ophtalmol* 2007;30:e15.
- 11 Baig MA, Qadir A, Rasheed J: A review of eosinophilic gastroenteritis. *J Natl Med Assoc* 2006;98:1616–1619.
- 12 Lucendo AJ: Eosinophilic diseases of the gastrointestinal tract. *Scand J Gastroenterol* 2010;45:1013–1021.
- 13 Rustigi AK MD: Vitamin deficiencies; in Albert DM, Jackobiac FA (eds): *Principles and Practice of Ophthalmology*. Philadelphia, Saunders, 1996, vol 5, pp 2981–2982.
- 14 Sommer A, Tarwotjo I: Protein deficiency and treatment of xerophthalmia. *Arch Ophthalmol* 1982;100:785–787.