

CASE REPORT

Spontaneous Isolated Common Iliac Artery Dissection Treated with Self-Expandable Stent in a 38-year-old Patient: A Case Report

Robert Novotny^{a,*}, Jaroslav Chlupac^{a,b}, Jan Beran^c, Libor Janousek^{a,d}, Jiri Froněk^{a,b}

^a Transplant Surgery Department, Institute for Clinical and Experimental Medicine Prague, Czech Republic

^b Second Faculty of Medicine, Charles University, Prague, Czech Republic

^c Department of Radiology, Institute for Clinical and Experimental Medicine, Prague, Czech Republic

^d First Faculty of Medicine, Charles University, Prague, Czech Republic

Introduction: Isolated iliac artery dissection (ISIAD) without the involvement of the aorta is a rare medical condition.

Report: A case of a 38-year-old man with sudden onset of rest pain and paraesthesia on the right lower limb (RLL) is presented. Upon admission, the RLL was pulseless, with mild paraesthesia in the foot. The patient underwent computed tomography angiography, which revealed isolated common iliac artery (CIA) dissection followed by endovascular treatment (stenting) of the CIA dissection, with an instant therapeutic effect. Hospital stay was uneventful. The patient was discharged on the third post-procedural day.

Discussion: Endovascular treatment of ISIAD is a viable treatment modality, with low periprocedural complications, mortality, and morbidity. Owing to its mini-invasiveness, it is a viable treatment modality.

© 2018 The Author(s). Published by Elsevier Ltd on behalf of European Society for Vascular Surgery. This is an open access article under the CC BY-NC-ND license (<http://creativecommons.org/licenses/by-nc-nd/4.0/>).

Article history: Received 25 May 2018, Revised 4 November 2018, Accepted 7 November 2018,

Keywords: Connective tissue, Disorder, Dissection, Iliac artery

INTRODUCTION

Isolated iliac artery dissection (ISIAD) without the involvement of the aorta is a rare medical condition. Only a few cases regarding this condition have been published. The causes for this condition can be classified as either traumatic or non-traumatic. The most common “traumatic” causes of an ISIAD are blunt trauma, extreme physical activity, pregnancy, and iliac catheterisation.^{1–4} The “non-traumatic” group of medical conditions that causes ISIAD include various connective tissue disorders (CTD) such as Marfan syndrome, Ehlers-Danlos syndrome, fibromuscular dysplasia, cystic medial degeneration, Erdheim-Gsell, and atherosclerosis.^{5–9} The most frequent and potentially fatal complication of ISIAD is rupture.

Most of the reports presented in the literature are associated with a CTD. An extremely rare case of a 38-year-old man who presented with an ISIAD without a CTD is discussed.

Case presentation

A 38-year-old man was referred for sudden onset of rest pain and paraesthesia on the right lower limb (RLL). Upon

admission, the RLL was pulseless with mild paraesthesia in the foot. Acute limb ischaemia was classified as Rutherford grade IIb. Left lower limb showed no signs of ischaemia with palpable peripheral pulsation on the anterior tibial artery and left dorsal artery of the foot. The patient’s medical history revealed only compensated arterial hypertension treated with amlodipine. The patient underwent computed tomography angiography (CTA) revealing isolated common iliac artery (CIA) dissection. False lumen compressed the true lumen of the CIA just above the iliac bifurcation. The external iliac artery (EIA), internal iliac artery, and proximal part of the common femoral artery had no blood flow on CTA (Fig. 1). The procedure was performed through the contralateral groin under local anaesthesia. Through a 6-Fr sheath, a hydrophilic guidewire was used to cross through the true lumen of the dissected CIA into the common femoral artery. The entry of the dissection was localised in the right distal CIA above the iliac bifurcation. The proximal part of the EIA was spastic without atherosclerotic infiltration. The entry of the dissected CIA and proximal part of the EIA were treated with self-expanding nitinol OptiMed Sinus stent 7 × 60 mm (OptiMed Medizinische Instrumente, Ettlingen, Germany). Post-dilatation was completed with Admiral Xtreme PTA balloon 6 × 60 mm (Admiral Xtreme; Medtronic, Minneapolis, MN, USA). The procedure was technically successful, with blood flow fully restored into the RLL (Fig. 2). The left femoral artery was closed with an AngioSeal vascular closure device (AS, St. Jude Medical, Minneapolis, MN,

* Corresponding author. Institute for Clinical and Experimental Medicine, Transplant Surgery Department, Videnska 1958/9, Prague 4, 140 21, Czech Republic.

E-mail address: novr@ikem.cz (Robert Novotny).

2405-6553/© 2018 The Author(s). Published by Elsevier Ltd on behalf of European Society for Vascular Surgery. This is an open access article under the CC BY-NC-ND license (<http://creativecommons.org/licenses/by-nc-nd/4.0/>).

<https://doi.org/10.1016/j.ejvsr.2018.11.001>

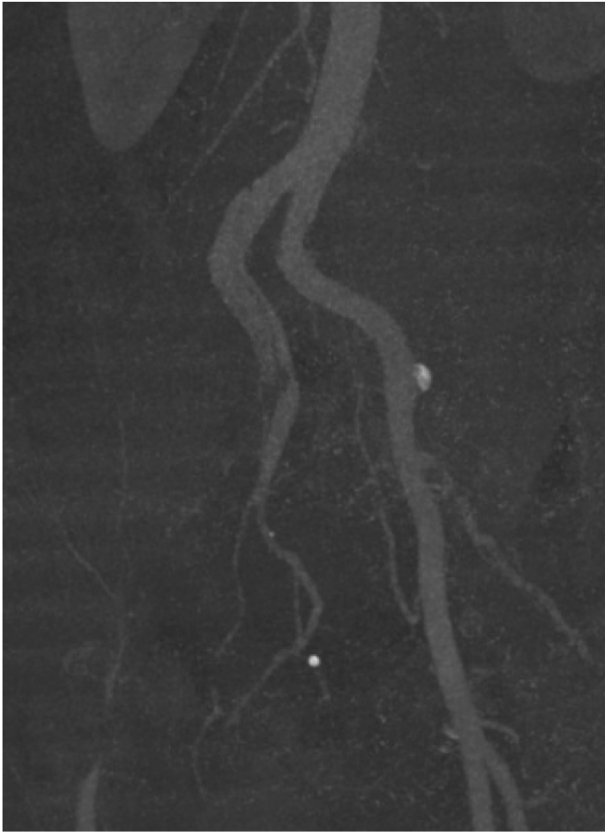


Figure 1. Computed tomography angiography of the dissected right common iliac artery with no blood flow in the external iliac artery, internal iliac artery and common femoral artery.

USA). Post-procedural hospital stay was uneventful. No reperfusion compartment syndrome occurred after the procedure. The patient was discharged on the third post-procedural day with palpable peripheral pulsation. The

patient was given a daily dose of 100 mg acetylsalicylic acid (aspirin) and will undergo an annual follow-up with a Doppler ultrasound check-up. The patient's collagen connective tissue work-up was negative.

Written informed consent was obtained from the patient for publication of this case report and accompanying images. A copy of the written consent is available for review by the Editor-in-Chief of this journal.

DISCUSSION

To date, only a few cases of ISIAID have been reported in the literature.^{1,2,6,7,9} The most frequent causes of ISIAID are connective tissue disorders.^{5,6,8} They are characterised as "non-traumatic causes". Under extreme circumstances, ISIAID can be caused by so-called "traumatic causes".¹⁻⁴ However, idiopathic cases are very sporadic. Based on the literature search, only two previous papers have reported an ISIAID.^{10,11}

Criteria for the treatment of asymptomatic patients with ISIAID are not yet defined, owing to the rarity of the condition. The study by Liang et al. reported that asymptomatic patients could be safely treated conservatively.¹² However, the question regarding further follow-up is still not answered. Owing to the nature of the disease, these patients are prone to aneurysmatic degeneration of arteries. Patients should undergo an annual check-up for screening an arterial aneurysms formation and their eventual progression. The urgency of the intervention is determined by the presentation mode, and those presenting with acute limb ischaemia or rupture require emergency endovascular or open repair.⁸

Endovascular treatment is associated with high technical and clinical success rates with low periprocedural mortality and morbidity when compared with open repair.¹² The

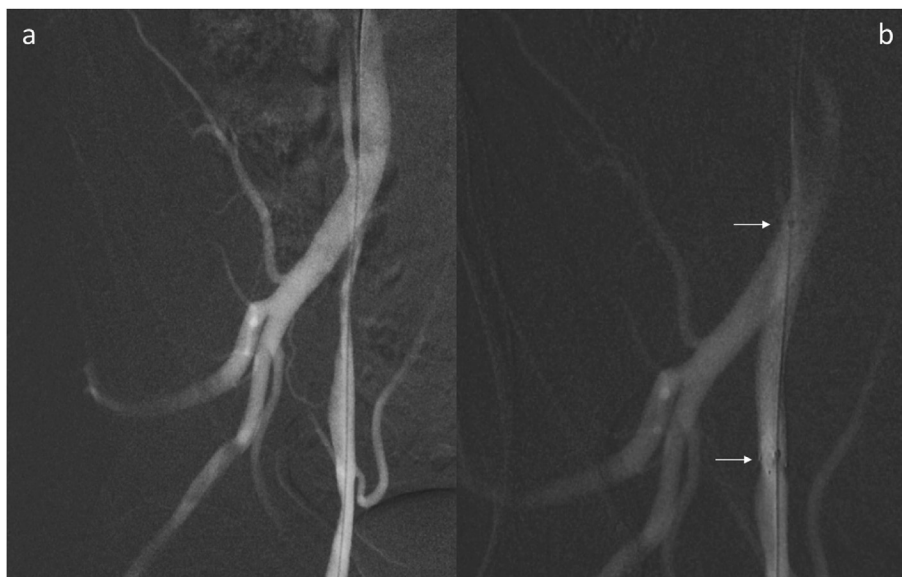


Figure 2. Digital subtraction angiography: hydrophilic guide wire and stent positioning in the common iliac artery (CIA) and external iliac artery (EIA). (A) Hydrophilic guide wire crossing through the true lumen of the dissected CIA into the common femoral artery under angiographic verification. The proximal part of the EIA is spastic with atherosclerotic infiltration. (B) Entry of the dissection treated with an OptiMed Sinus stent 7 × 60 mm after post-dilation (white cursors show stent positioning).

implantation of these devices can, in some cases, be limited by tortuosity of the iliac vessels. The risk of continued false lumen perfusion from distal tears has to be also taken into the account when performing an endovascular treatment. Embolisation of the false lumen can be combined with stent/stent-graft implantation to achieve an optimal result.¹³

CONCLUSIONS

Endovascular treatment of ISIAD is a viable treatment modality with low periprocedural complications, mortality, and morbidity.

ACKNOWLEDGEMENTS

The author would like to thank Doc. MUDr. Jiri Fronek, PhD FRCS, Transplant Surgery Department, Institute for Clinical and Experimental Medicine, Prague, Czech Republic and MUDr. Jaroslav Chlupac PhD, Transplant Surgery Department, Institute for Clinical and Experimental Medicine, Prague, Czech Republic for providing their opinion on this case.

CONFLICTS OF INTEREST

The authors declare that there is no conflict of interests regarding the publication of this article. This research received no specific grant from any funding agency in the public, commercial, or not-for-profit sectors.

REFERENCES

- 1 Lyden SP, Srivastava SD, Waldman DL, Green RM. Common iliac artery dissection after blunt trauma: case report of endovascular repair and literature review. *J Trauma* 2001;**50**:339–42.
- 2 Ehsan O, Darwish A, Edmundson C, Mills V, Al-Khaffaf H. Non-traumatic lower limb vascular complications in endurance athletes. Review of literature. *Eur J Vasc Endovasc Surg* 2004;**28**:1–8.
- 3 Nolte JE, Rutherford RB, Nawaz S, Rosenberger A, Speers WC, Krupski WC. Arterial dissections associated with pregnancy. *J Vasc Surg* 1995;**21**:515–20.
- 4 Gul M, Aksu HU, Oz K, Bakir I. Rupture of the NovaFlex balloon during transcatheter aortic valve implantation and subsequent dissection of the right iliac arteries. *Eur J Cardiothorac Surg* 2013;**43**:437–8.
- 5 Barker SG, Burnand KG. Retrograde iliac artery dissection in Marfan's syndrome. A case report. *J Cardiovasc Surg (Torino)* 1989;**30**:953–4.
- 6 Abayazeed A, Hayman E, Moghadamfalahi M, Cain D. Vascular type Ehlers-Danlos Syndrome with fatal spontaneous rupture of a right common iliac artery dissection: case report and review of literature. *J Radiol Case Rep* 2014;**8**:63–9.
- 7 Lück I, Hanschke D, Geissler C, Gruss JD. [Spontaneous dissection of the external iliac artery due to fibromuscular dysplasia]. *VASA* 2002;**31**:115–21.
- 8 Dueppers P, Jankowiak S, Schelzig H, Wagenhäuser MU, Oberhuber A. Spontaneous rupture of an isolated iliac artery dissection in a young man because of cystic medial degeneration Erdheim-Gsell. *Ann Vasc Surg* 2015;**29**:596. e11–13.
- 9 Sedivy P, El Samman K, Slais M, Abtova E. A spontaneous isolated dissection of the external iliac artery in a roofer. *Bratisl Lek Listy* 2011;**112**:407e9.
- 10 Honjo O, Yamada Y, Kuroko Y, Kushida Y, Une D, Hioki K. Spontaneous dissection and rupture of common iliac artery in a patient with fibromuscular dysplasia: a case report and review of the literature on iliac artery dissections secondary to fibromuscular dysplasia. *J Vasc Surg* 2004;**40**:1032–6.
- 11 Spinella G, Pane B, Perfumo MC, Palombo D. Spontaneous iliac artery dissection treated with a combination of covered and self-expandable stents to preserve hypogastric patency. *J Vasc Surg Cases* 2016;**2**:14–7.
- 12 Liang Z, Guo W, Du C, Xie Y. The effectiveness of the conservative therapy for spontaneous isolated iliac artery dissection: preliminary results. *Vascular* 2017;**25**:649–56.
- 13 Fiorucci B, Tsilimparis N, Rohlfes F, Wipper S, Debus ES, Kölbel T. Isolated spontaneous dissection of the iliac arteries: false lumen embolization as an adjunct to percutaneous stent grafting. *Ann Vasc Surg* 2017;**42**:300.e1–5.