

CASE REPORT

Acute thyroid swelling with severe hypothyroid myxoedema after COVID-19 vaccination

Massimo Giusti¹  | Agostino Maio²¹BIOMEDICAL, Genoa, Italy²ASL 3 Genovese, Genoa, Italy**Correspondence**

Massimo Giusti, BIOMEDICAL SpA,
via Prà 1B, I-16157 Genoa, Italy.
Email: omsv1416@gmail.com

Funding information

No financial support was received from any source.

Abstract

The SARS-CoV-2 virus can trigger thyroid dysfunction. Thyroid dysfunctions after COVID-19 vaccination have been rarely reported. We report the case of overt hypothyroidism in a 61-year-old woman seen after BNT162b2-mRNA vaccination. This case underlines the fact that thyroid function should also be monitored after COVID-19 vaccination, especially in at-risk subjects.

KEYWORDS

COVID-19, levothyroxine, myxedema, thyroid, vaccination overt hypothyroidism

1 | INTRODUCTION

The pandemic of coronavirus disease 2019 (COVID-19), caused by severe acute respiratory syndrome virus 2 (SARS-CoV-2), remains a challenge, owing to its high transmissibility and mortality. The last two years have seen the emergence of a rapidly growing body of literature regarding the target organs of SARS-CoV-2, including the endocrine system, indicating that the disease may have short^{1,2} and long-term³ consequences.

Currently available vaccines against SARS-CoV-2 promise to reduce the spread and severity of the disease. However, several side effects of vaccines have been reported both in phase 3 trials⁴ and in the real-life setting.⁵⁻⁸ The thyroid seems to be the most frequently affected endocrine gland by postvaccination autoimmune/inflammatory reactions.⁹⁻¹² Moreover, Hashimoto's thyroiditis, Graves' disease, and subacute thyroiditis after vaccinations against human papillomavirus, influenza, and hepatitis B have been already described.¹³ In addition, the spike glycoprotein of the SARS-CoV-2 vaccine,

which shares similar features with some human proteins, may precipitate the onset of autoimmunity in susceptible patients.^{14,15}

We present the case of a patient who suddenly developed thyroid enlargement, overt hypothyroidism, and myxoedema features soon after receiving the COVID-19 BNT162b2-mRNA vaccine manufactured by Pfizer-BioNTech. Signs and symptoms of myxoedema are generally linked to undiagnosed or untreated severe hypothyroidism.¹⁶ We discuss whether the COVID-19 vaccine could have been the precipitating trigger of acute thyroid swelling and overt hypothyroidism in our patient.

2 | CASE PRESENTATION

In May 2021, a 61-year-old woman presented for endocrine examination with biochemical data of overt hypothyroidism (Table 1). The patient had no family or personal history of previous thyroid disease or other autoimmune diseases. She reported having completed her

This is an open access article under the terms of the Creative Commons Attribution-NonCommercial-NoDerivs License, which permits use and distribution in any medium, provided the original work is properly cited, the use is non-commercial and no modifications or adaptations are made.

© 2021 The Authors. *Clinical Case Reports* published by John Wiley & Sons Ltd.

TABLE 1 Some clinical and laboratory data

	On diagnosis	1 month later	3 months later	Reference range
Body weight (kg)	81	80	77	–
Pulse rate (min)	56	76	74	–
Systolic blood pressure (mm Hg) (*)	110	110	110	<130
Diastolic blood pressure (mm Hg)	85	60	70	<80
L-T4 (µg/day)	–	50	100	–
Free triiodothyronine (pmol/L)	Undetectable	1.89	4.23	2.95–5.41
Free thyroxine (pmol/L)	5.1	6.8	20.2	11.4–22.7
TSH (mIU/L)	89.7	78.8	1.83	0.35–4.50
Thyroperoxidase antibody (mIU/L)	>2000	–	728	<5.6
Thyroglobulin antibody (mIU/L)	7671	–	911	<4.1
TSH receptor antibody (IU/L)	1.2	–	–	<1.75
Thyroid volume (ml) (**)	37.6	22.5	21.3	8.0 (IQR 6.7–9.8)
C-reactive protein (mg/L)	–	2.7	2.3	<5

Note: (*) in sitting position; (**) median and interquartile (IQR) range; see also Ref [17].

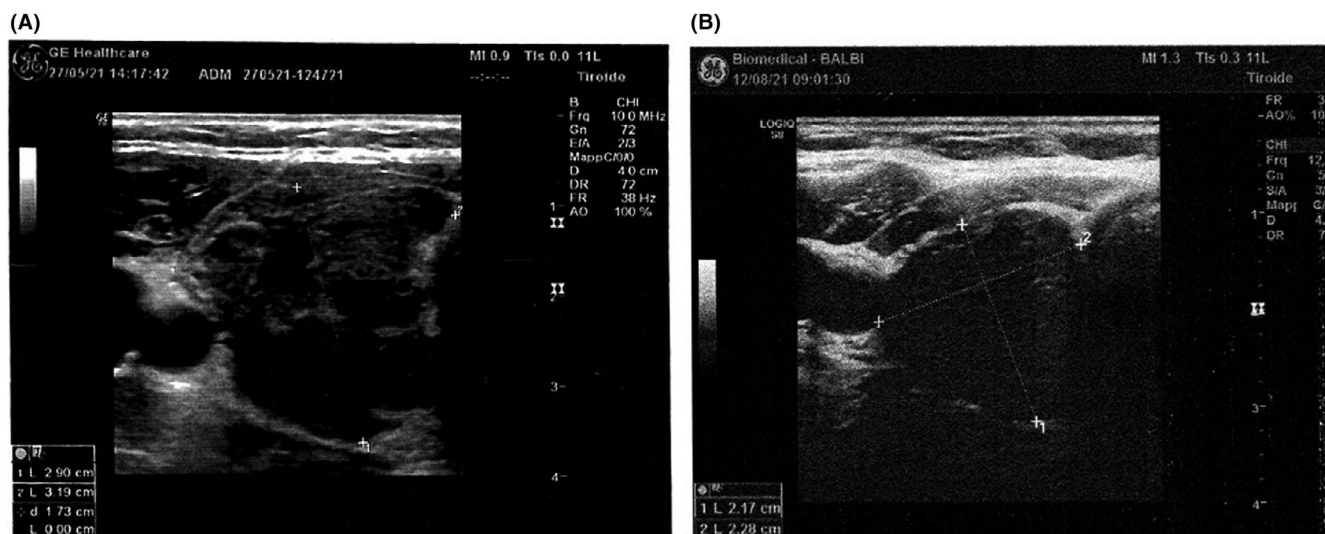


FIGURE 1 Transverse ultrasonography images recorded with a 10 MHz probe at the baseline (A) and 3 months (B) after the beginning of L-T4 treatment

SARS-CoV-2 vaccination program with the BNT162b2-mRNA vaccine 6 weeks earlier. No significant side effects immediately after vaccination were reported. About 3 weeks after receiving the second dose of vaccine, she noted swelling of her neck and face, without pain. Two weeks before the availability of hormonal data and the first endocrinological examination, her general practitioner began oral betamethasone (1 mg/day), in order to reduce the swelling. At the time of endocrinological examination, the patient complained of asthenia and weight gain but not of cognitive impairment. Her family history reported unknown thyroid disorders in 2nd-degree relatives. The patient smoked 15 cigarettes daily. On endocrinological examination, she had first-degree obesity (body mass index 30.5 kg/m²), normal body

temperature, bradycardia (pulse rate: 56/min), reduced differential blood pressure (110/85 mm Hg), facial and limb swelling, and diffuse tender goiter. Her body weight was 2–3 kg greater than it had been before. Neck sonography showed a diffuse hypoechoic and enlarged thyroid gland (Figure 1). She reported no pain during probe apposition on the neck. Thyroid volume, calculated according to the ellipsoid formula, was 37.6 ml, a value about 5-fold greater than the median thyroid volume observed in women in the Liguria region.¹⁷

The patient started levothyroxine (L-T4) treatment at an initial dosage of 14.2 µg/day; this was subsequently increased by 7.1 µg/day every 5 days up to the current dosage of 100 µg/daily. Betamethasone was tapered off over 2 weeks. Hormonal and clinical changes in the first

3 months of therapy are reported in Table 1. After 1 and 3 months of treatment, the thyroid volume decreased to 22.5 and 21.3 ml, respectively. Positive thyroid antibodies (Table 1) and the hypoechoic pattern of the gland (Figure 1) slightly changed. The neck and facial swelling of the patient improved, while her body weight only minimally changed (Table 1).

3 | DISCUSSION

The clinical manifestations of hypothyroidism range from life-threatening—in the case of myxoedema coma due to long-standing untreated and severe hypothyroidism—to no signs or symptoms. In our case, the occurrence of facial and neck swelling and overt hypothyroidism soon after the COVID-19 vaccination suggests that the immune response to the vaccine had induced or precipitated Hashimoto's thyroiditis. In our patient, in whom the personalized L-T4 dosage has been probably reached, further relief of symptoms could be imagined after the first 3 months of therapy. Indeed, the substitutive hormone treatment prescribed has proved effective in reducing the signs of hypothyroidism. In such cases, long-term L-T4 therapy has proved able to control generally permanent thyroid dysfunction and progressively reduce goiter.¹⁸ The same evolution can be expected in the present case, which was diagnosed after the COVID-19 vaccination.

Acute effects of the COVID-19 vaccination on the thyroid have been recently reported. Vera-Lastra et al.⁹ reported two female care workers, one with a history of previous COVID-19 disease, in whom anti-TSH receptor antibodies and clinical Graves' disease appeared very few days after the administration of the BNT162b2-mRNA vaccine. Subacute thyroiditis within a week after administration of the same vaccine has been recently described.¹¹ Moreover, neck pain and swelling associated with thyrotoxicosis 3 weeks after the first dose of the AstraZeneca adenovirus-vectored COVID-19 vaccine has been reported; this was interpreted as vaccine-induced subacute thyroiditis.¹⁰ Iremli et al.¹² reported subacute thyroiditis in three women soon after the administration of the inactivated coronavirus vaccine manufactured by Sinovac Biotech Ltd. We can hypothesize that there will be an increase in cases of acute thyroid dysfunction after the COVID-19 vaccination. To our knowledge, however, this is the first report of overt hypothyroidism associated with myxoedema.

The BNT162b2-mRNA vaccine is a two-dose vaccine adjuvanted with lipids that have not been widely used in medicinal products. These adjuvants are used to induce a more substantial and sustained humoral and cellular

immune response. However, adjuvants can trigger adverse immune reactions in predisposed individuals, causing autoimmune/inflammatory syndrome (ASIA syndrome).⁹ ASIA syndrome induced by SARS-CoV-2 vaccines seems to be less frequently associated with positive antibodies than that induced by HPV and influenza vaccines. In the cases reported by Iremli et al.,¹² thyroid antibodies were negative, while in those of Vera-Lastra et al.⁹ they were positive. However, in our case of chronic thyroiditis, high titers of thyroid antibodies were recorded. In addition, the potential for cross-reactivity between the SARS-CoV-2 spike protein targeted by the mRNA vaccine and thyroid antigens^{14,15} could be mentioned in our case. In our patient and in other studies,^{9,12} irrespective of the clinical presentation, the immune response seems to be unrelated to the rapid onset of thyroid dysfunction symptoms.

Rapidly improving the thyroid status is considered to be risky in overt hypothyroidism, especially in elderly and cardiopathic patients, in whom thyroid hormones, particularly T3, can rapidly increase metabolic rate and oxygen consumption.¹⁰ Moreover, we preferred to relatively slowly increase L-T4, and in this setting, a liquid L-T4 preparation was easy to use.

In conclusion, our patient met the diagnostic criteria for ASIA after exposure to the vaccine and developed manifestations of vaccine-induced autoimmunity. In our case, the COVID-19 vaccine may have been the precipitating trigger of acute thyroid swelling and overt hypothyroidism. Surveillance after the COVID-19 vaccination should be broadened to include autoimmune hypothyroidism and not solely autoimmune hyperthyroidism or subacute thyroiditis. All these dysfunctions can develop from 5 days to several weeks after vaccination. We strongly recommended surveillance and safety monitoring of other approved candidate vaccines in the future.

ACKNOWLEDGMENTS

The authors thank the patient for giving her permission to publish this information. We thank Mr. Bernard Patrick for revising the English language of the paper.

CONFLICT OF INTEREST

The authors declare no conflict of interest.

AUTHOR CONTRIBUTIONS

MG conceived the study, carried out US evaluations, conducted data collection, and drafted the manuscript. AM participated in data collection. The authors have read and approved the final manuscript.

CONSENT

Written informed consent was obtained from the patient.

DATA AVAILABILITY STATEMENT

Data sharing is not applicable to this article as no new data were created or analyzed in this study.

ORCID

Massimo Giusti  <https://orcid.org/0000-0002-1269-8376>

REFERENCES

1. Pal R, Banerjee M. COVID-19 and the endocrine system: exploring the unexplored. *J Endocrinol Invest*. 2020;43(7):1027-1031.
2. Pastor S, Molina Á Sr, De Celis E. Thyrotoxic crisis and COVID-19 infection: an extraordinary case and literature review. *Cureus*. 2020;12(11):e11305. doi:10.7759/cureus.11305
3. Mongioi LM, Barbagallo F, Condorelli RA, et al. Possible long-term endocrine-metabolic complications in COVID-19: lesson from the SARS model. *Endocrine*. 2020;68(3):467-470.
4. Castells MC, Phillips EJ. Maintaining safety with SARS-CoV-2 vaccines. *N Engl J Med*. 2021;384(7):643-649.
5. Montgomery J, Ryan M, Engler R, et al. Myocarditis following immunization with mRNA COVID-19 vaccines in members of the US military. *JAMA Cardiol*. 2021;6(10):1202. doi:10.1001/jamacardio.2021.2833
6. See I, Su JR, Lale A, et al. US case reports of cerebral venous sinus thrombosis with thrombocytopenia after Ad26. COV2.S vaccination, March 2 to April 21, 2021. *JAMA*. 2021;325(24):2448-2456.
7. Banerji A, Wickner PG, Saff R, et al. mRNA vaccines to prevent COVID-19 disease and reported allergic reactions: current evidence and suggested approach. *J Allergy Clin Immunol Pract*. 2021;9(4):1423-1437.
8. Shemer A, Pras E, Einan-Lifshitz A, Dubinsky-Pertsov B, Hecht I. Association of COVID-19 vaccination and facial nerve palsy: a case-control study. *JAMA Otolaryngol Head Neck Surg*. 2021;147(8):739-743.
9. Vera-Lastra O, Ordinola Navarro A, Cruz Domiguez MP, Medina G, Sánchez Valadez TI, Jara LJ. Two cases of graves' disease following SARS-CoV-2 vaccination: an autoimmune/inflammatory syndrome induced by adjuvants. *Thyroid*. 2021;31(9):1436-1439. doi:10.1089/thy.2021.0142
10. Oyibo SO. Subacute thyroiditis after receiving the adenovirus-vectored vaccine for coronavirus disease (COVID-19). *Cureus*. 2021;13(6):e16045. doi:10.7759/cureus.16045
11. Franquemont S, Galvez J. Subacute thyroiditis after mRNA vaccine for Covid-19. *J Endocrinol Soc*. 2021;5:A956-957. doi:10.1210/jendso/bvab048.1954
12. İremli BG, Şendur SN, Ünlütürk U. Three cases of subacute thyroiditis following SARS-CoV-2 vaccine: post-vaccination ASIA Syndrome. *J Clin Endocrinol Metab*. 2021;106(9):2600-2605. doi:10.1210/clinem/dgab373
13. Bragazzi NL, Hejly A, Watad A, Adawi M, Amital H, Shoenfeld Y. ASIA syndrome and endocrine autoimmune disorders. *Best Pract Res Clin Endocrinol Metab*. 2020;34(1):101412. doi:10.1016/j.beem.2020.101412
14. Kanduc D, Shoenfeld Y. Molecular mimicry between SARS-CoV-2 spike glycoprotein and mammalian proteomes: implications for the vaccine. *Immunol Res*. 2020;68(5):310-313.
15. Vojdani A, Vojdani E, Kharrazian D. Reaction of human monoclonal antibodies to SARS-CoV-2 proteins with tissue antigens: implications for autoimmune diseases. *Front Immunol*. 2021;11:617089. doi:10.3389/fimmu.2020.617089
16. Elkattawy S, Dhanoa P, Kotys J, Fichadiya H, Eckman A. Myxedema coma: case report and literature review. *Cureus*. 2021;13:e15277. doi:10.7759/cureus.15277
17. Giusti M, Sidoti M. Normal thyroid volume in subjects evaluated in a primary ambulatory setting in Liguria. *Minerva Endocrinol*. 2021. doi:10.23736/S0391-1977.20.03312-X
18. Giusti M, Sidoti M. Long-term observation of thyroid volume changes in Hashimoto's thyroiditis in a series of women on or off levo-thyroxine treatment in an area of moderate iodine sufficiency. *Acta Endocrinol (Buc)*. 2021;17(1):131-136.

How to cite this article: Giusti M, Maio A. Acute thyroid swelling with severe hypothyroid myxoedema after COVID-19 vaccination. *Clin Case Rep*. 2021;9:e05217. doi:[10.1002/ccr3.5217](https://doi.org/10.1002/ccr3.5217)