

## Cerebral microbleeds (CMBs) – relevance for mechanisms of cerebral hemorrhage – analysis of 24 MRI evaluated patients

Ghelmez D\* \*\*, Sorin Tuță S\* \*\*, Popa C\* \*\*

\*National Institute of Neurology and Neurovascular Diseases, Bucharest

\*\*"Carol Davila" University of Medicine and Pharmacy, Bucharest

Correspondence to: : Dana Ghelmez

National Institute of Neurology and Neurovascular Diseases,  
10-12 Berceni Road, District 4, Bucharest

Mobile phone: 0723991701; E-mail: danaghelmez@gmail.com

Received: June 5th, 2013 – Accepted: September 19th, 2013

### Abstract

**Introduction.** The new MRI techniques introduced in the last decade allowed the detection of cerebral microbleeds (CMBs) in different groups of diseases: stroke, Alzheimer disease, vascular dementia or healthy people of advanced age. CMBs are radiologically defined as small, rounded, homogeneous, hypointense lesions on T2\*-weighed gradient-recalled echo (T2\*-GRE) sequences.

**Objective and Method.** We evaluated the prevalence, number and location of CBMs in a cohort of 26 consecutive cerebral hemorrhage patients admitted in the National Institute of Neurology and Neurovascular Diseases. We also assessed the association between CMB, classical vascular risk factors and small vessel disease.

**Results and Conclusions.** From the 26 patients, 2 patients had secondary intracerebral hemorrhage (ICH) (hemorrhage in metastasis, respectively a cavernoma). From the 24 ICH patients 12 have had at least 1 CMB lesion. The average volume of the cerebral hemorrhage was larger in patients with CMBs, with a relative increase of 42%. Small vessel disease was associated with a significant increase in the presence of CMBs (relative increase of 86%). In both cases, however, since the number of patients enrolled was small, the correlations did not reach statistical significance.

**Keywords:** cerebral microbleeds, CMBs, small vessel disease, intracerebral hemorrhage

### Introduction

The new MRI techniques introduced in the last decade allowed the detection of cerebral microbleeds (CMBs) in different groups of diseases: stroke, Alzheimer disease, vascular dementia or healthy people of advanced age. CMBs are radiologically defined as small, rounded, homogeneous, hypointense lesions on T2\*-weighed gradient-recalled echo (T2\*-GRE) sequences [1]. SWI technique, recently introduced into practice is a high resolution, three-dimensional T2 \*-GRE with a very high sensitivity for CMBs (and bleeding in general). Another benefit of the SWI sequence is that it can differentiate CMBs from calcification or subarachnoid space vessels, all appearing as hypointense lesions on T2 \*-GRE [2,3]. The histopathological examination showed that CMBs are small hemorrhages adjacent to small caliber abnormal vessels affected by cerebral amyloid angiopathy (CAA) or hypertensive angiopathy [4].

### Objective and Method

We evaluated the prevalence, number and location of CBMs in a cohort of 26 consecutive cerebral hemorrhage patients admitted in the National Institute of

Neurology and Neurovascular Diseases. We also assessed the association between CMBs, classical vascular risk factors and small vessel disease. Besides the emergency cerebral CT scan, brain MRI was performed in these patients, including beside the classic sequences, the special sequences of SWI or T2 \*-GRE. According to the data found in literature, CMBs are associated with both ischemic stroke, especially lacunar stroke, and with cerebral hemorrhage, hypertensive or the CAA type [5].

### Results

From the 26 patients with ICH, 12 have had at least 1 CMB lesion: 1 patient had one lesion, 4 patients two CMBs, 1 patient had 3 CMBs and the rest of the patients more than 3. 26 patients were included in the study but 2 of them proved to have secondary hemorrhages (hemorrhage in metastasis and, respectively, a cavernoma). All 12 CMB patients were hypertensive and 9 of them had other signs of small

vessel disease (lacunar strokes and/or leukoaraiosis). Regarding the ICH topography there were two cerebellar hemorrhages, one brainstem hemorrhage, three lobar hemorrhages, 8 hemorrhages in the basal ganglia and 10 thalamic hemorrhages.

We analyzed the prevalence of CMBs in patients with cerebral small vessels disease (SVD) (Fig. 1). Within our group, small vessel disease (lacunar strokes and/or leukoaraiosis) was associated with a significant increase in the presence of CMBs (relative increase of 86%). Given the small number of patients in the group, we tried to use the exact Fischer test [6] to assess the statistical significance of the observed association. The P-value obtained was 0.24, so, although the presence of small vessel disease appears to be associated with a higher prevalence of CMBs, our data did not reach statistical significance.

The average volume of bleeding was higher in patients with CMBs, 9.1 cm<sup>3</sup> vs. 6.44 cm<sup>3</sup> (relative increase of 42%). To compare the means we performed a unifactorial analysis of variance (ANOVA) and contrary to our expectations the mean variance was relatively homogeneous (F1, 22 = 0.84) (Fig. 2), but this result, again, failed to reach statistical significance (P value 0.37).

We tried to analyze the differences between the average volume per location depending on the presence or absence of CMBs (Fig. 3,4). There is a tendency for the growth of the volume in the locations that had a greater number of cases, but the rare locations made the association not to reach statistical significance.

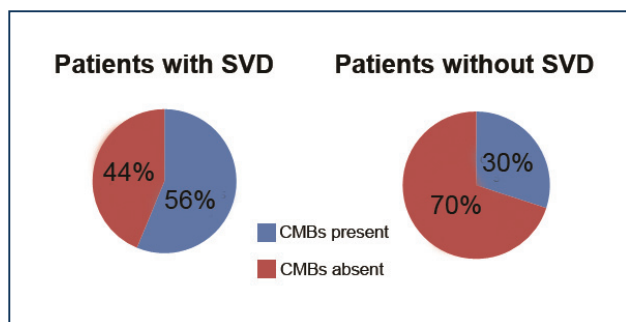


Fig. 1 Prevalence of CMBs in patients with small vessels disease

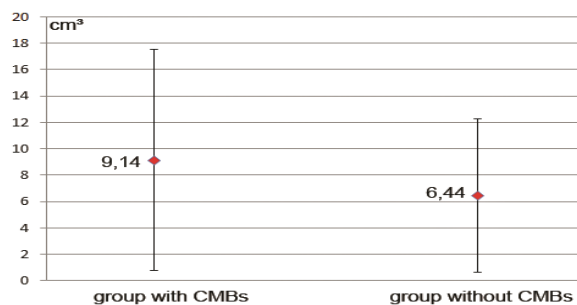


Fig. 2 ICH volume (cm<sup>3</sup>) in patients with and without CMBs. The large superposition of the variance standard deviations is obvious

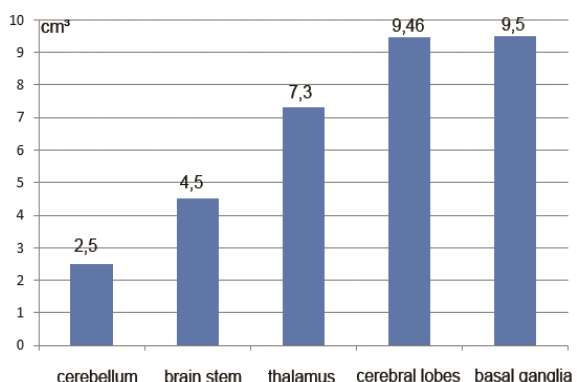


Fig. 3 Average volume of ICH (cm<sup>3</sup>) according to location

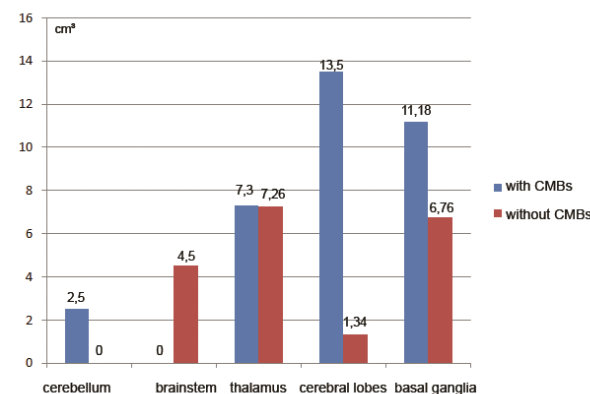


Fig. 4 The average volume of ICH (cm<sup>3</sup>) according to location and presence of CMBs

Table 1. Topography and number of CMBs

Age	Sex	ICH location	Location and no. of CMBs
57	M	Thalamocapsular	multiple, basal ganglia bilateral
48	M	basal ganglia	3 CMBs: pontine, left basal ganglia and right frontal
79	M	lobar temporo-parietal	2 CMBs: occipital and right basal ganglia
43	M	basal ganglia	2 CMBs: left basal ganglia
76	M	cerebellum	2 CMBs: right parietal and occipital subcortical
56	M	thalamocapsular	multiple: cerebellum and temporal bilateral
45	M	basal ganglia	2 CMBs: left parietal subcortical and right parietal cortical
53	M	lobar frontal	multiple cortico-subcortical on the right
74	F	basal ganglia	multiple supra and infratentorial, especially left temporo-

			occipital
37	F	thalamus	multiple: right frontal and some in the basal ganglia bilateral
64	F	cerebellum	multiple supra and infratentorial
88	F	basal ganglia	1 CMB left pontine

## Discussions

Although in this case there was only a tendency in the increase of the volume of hematoma in patients with CMBs but without reaching statistical significance, this trend was confirmed by other studies. According to one study, in patients with lobar or basal ganglia hemorrhages, the lesional volume was two to three times larger in patients who associated CMBs than in the control group [7]. This fact is important in clinical practice to quantify the risk of secondary ICH in patients receiving antithrombotic therapy. The presence of CMBs is an independent risk factor for secondary ICH in patients with oral anticoagulation or those undergoing thrombolytic therapy. A study that enrolled patients with oral anticoagulation, an arm with secondary ICH and the other arm without ICH, showed that a higher percentage of patients had CMBs lesions on MRI imaging in ICH group compared to the control group and that the number of CMBs was also higher in the first case [8]. With regard to the thrombolytic treatment, the results of a BRASIL study showed a 5.8% brain hemorrhage in patients with CMBs compared with 2.7% in those without CMBs [9]. Another multicentered study tried to stratificate the post-thrombolysis risk of cerebral hemorrhage in patients with

acute ischemic stroke, who associated CMBs lesions on MRI. There was a trend towards increasing the risk of cerebral hemorrhage with a borderline p-value ( $p = 0.05$ ) but the bleeding risk had significantly increased with the increase in the number of CMBs. In the subgroup of patients with a number of more than 10 CMBs, the cerebral hemorrhage rate was 29% [10].

## Conclusions

Of the 24 patients with primary ICH, half of them had at least one CMB lesion. All the patients with CMBs were hypertensive. The average volume of the ICH lesions was larger in patients with CMBs with a relative increase of 42%. Small vessel disease was associated with a significant increase in the presence of CMBs (relative increase of 86%). However, in both cases, since the number of patients enrolled was small, the correlations did not reach a statistical significance. CMBs presence, detected by modern imaging techniques (MRI-SWI), appeared to be an important factor in assessing the risk of hemorrhagic stroke in patients with anticoagulant or thrombolytic therapy for ischemic stroke.

## References

1. Greenberg SM, Vernooij MW, Cordonnier C et al. Cerebral microbleeds: a guide to detection and interpretation. First consensus on microbleed MRI detection and interpretation. *Lancet Neurol.* 2009; 8, 165—174.
2. Mittal S, Wu Z, Neelavalli J, Haacke EM. Susceptibility-weighted imaging: technical aspects and clinical applications. Part 2. *AJNR Am. J. Neuroradiol.* 2009; 30, 232—252.
3. Wu Z, Mittal S, Kish K, Yu Y, Hu J, Haacke EM. Identification of calcification with MRI using susceptibility-weighted imaging: a case study. *J. Magn. Reson. Imaging.* 2009; 29, 177—182.
4. Fazekas F, Kleinert R, Roob G et al. Histopathologic analysis of foci of signal loss on gradient-echo T2\*-weighted MR images in patients with spontaneous intracerebral hemorrhage: evidence of microangiopathy-related microbleeds. First post-mortem imaging—histopathological study reporting the underlying substrate of CMBs to be hemosiderin deposits within macrophages, surrounding diseased small vessels. *AJNR Am. J. Neuroradiol.* 1999; 20, 637—642.
5. Lee SH, Bae HJ, Kwon SJ et al. Cerebral microbleeds are regionally associated with intracerebral hemorrhage. *Neurology.* 2004; 62: 72—76.
6. Fisher's Exact Test-<http://www.langsrud.com/fisher.htm>
7. Lee SH, Kim BJ, Roh JK. Silent microbleeds are associated with volume of primary intracerebral hemorrhage. *Neurology.* 2006 Feb 14.
8. Lee SH, Ryu WS, Roh JK. Cerebral microbleeds are a risk factor for warfarin-related intracerebral hemorrhage. *Neurology.* 2009 Jan 13.
9. Fiehler J, Albers GW, Boulanger JM et al. Bleeding Risk Analysis in Stroke Imaging Before Thrombolysis (BRASIL): pooled analysis of T2\*-weighted magnetic resonance imaging data from 570 patients. *Stroke.* 2007; 38, 2738—2744.
10. Shoamanesh A, Kwok C, Lim P, Benavente O. Cerebral Microbleed Burden Predicts Symptomatic Intracerebral Hemorrhage Following Thrombolysis. *Neurology.* February 12, 2013.