

Usefulness of PET/CT in the diagnosis of recurrent or metastasized differentiated thyroid carcinoma

CUN-ZHI LU¹, SU-SHENG CAO², WEI WANG², JUN LIU², NING FU¹ and FENG LU¹

Departments of ¹Nuclear Medicine and ²Thyroid Surgery, Xuzhou Central Hospital, Xuzhou, Jiangsu 221009, P.R. China

Received October 7, 2015; Accepted February 15, 2016

DOI: 10.3892/ol.2016.4229

Abstract. The aim of the present study was to determine the usefulness of the positron emission tomography/computed tomography (PET/CT) with ¹⁸F-fluorodeoxyglucose (FDG) in the detection of recurrence or metastasization of differentiated thyroid carcinoma (DTC) in patients with abnormal thyroglobulin levels and negative findings on the ¹³¹I-diagnostic whole-body scanning (dWBS). Fifteen patients with DTC, abnormal thyroglobulin levels, and negative ¹³¹I-dWBS findings were scanned using the ¹⁸F-FDG PET/CT. Positive diagnosis was based on postoperative histologic findings, and clinical and imaging follow-up results obtained in the subsequent 6 months. In addition, preoperative and postoperative thyroglobulin levels were compared. Using the findings of ¹⁸F-FDG PET/CT and data on confirmed positive diagnosis, sensitivity and positive predictive value (PPV) were calculated. Sensitivity and PPV of PET/CT in detecting recurrence or metastasization of DTC were 93.30 and 91.40%, respectively. Furthermore, postoperative thyroglobulin levels were markedly lower compared to the preoperative levels (respectively, 4.67±1.71 vs. 58.53±18.34 ng/ml; p<0.05). PET/CT scan with ¹⁸F-FDG is an informative technique for the detection of recurrent or metastasized DTC in patients with abnormal thyroglobulin levels and negative ¹³¹I-dWBS findings.

Introduction

The incidence of thyroid carcinoma is the highest among head and neck carcinomas. Differentiated thyroid carcinoma (DTC) accounts for 90% of thyroid cancers, with 20% of patients experiencing disease relapse, which decreases survival rates (1). A timely diagnosis of thyroid cancer recurrence is critical. Evaluation of serum thyroglobulin and ¹³¹I-diagnostic

whole-body scanning (dWBS) are the most commonly employed detection techniques. However, 15-20% of patients with abnormal thyroglobulin levels show negative findings on ¹³¹I-dWBS (2,3). Furthermore, it is difficult to differentiate the recurrence of DTC from cicatricial tissue by computed tomography (CT), positron emission tomography (PET), magnetic resonance imaging (MRI), or ultrasound (4). Subsequently, PET/CT has been introduced in the diagnostics of DTC, since PET/CT shows metabolic activity and anatomical abnormalities, characteristic of the tumour.

Between December 2005 and June 2013, ¹⁸F-fluorodeoxyglucose (FDG) PET/CT was utilized to diagnose 15 patients with DTC. The results identified ¹⁸F-FDG PET/CT as a valuable detecting technique for the recurrence or metastasization of DTC.

Materials and methods

Patients. Fifteen patients with DTC were admitted to the Department of Nuclear Medicine of the Xuzhou Central Hospital (Xuzhou, China) between December 2005 and June 2013. There were 3 male and 12 female patients, aged 25-58 years, with a median age of 46 years (Table I). The patients were diagnosed with DTC, and underwent total or subtotal thyroidectomy.

The pathological types comprised 14 cases of papillary carcinoma and 1 case of follicular carcinoma. The patients received 1 or several courses of postoperative treatment with ¹³¹I: 1 patient was treated once, 4 patients were treated twice, 6 patients were treated three times, 2 patients were treated four times, 1 patient was treated six times, and the remaining patient was treated eight times. At the follow up after the treatment, elevated levels of thyroglobulin (>20 ng/ml) and negative ¹³¹I-dWBS findings were present in each of these patients. Subsequently, tumour recurrence or metastasization was suspected. The patients underwent PET/CT examination. Patients continued receiving thyroidin pills following surgery, including during PET/CT, to avoid deterioration of the tumour.

¹⁸F-FDG PET/CT imaging. The Philips GXL 16 PET/CT scanning instrument (Philips Medical Systems, Inc., Cleveland, OH, USA) was used. The patients fasted for ≥6 h prior to scanning. Strict blood glucose levels (non-diabetic patients, <6.1 mmol/l; patients with diabetes, <8.3 mmol/l) were maintained. The patients were intravenously administered 270-370 MBq of

Correspondence to: Dr Su-Sheng Cao, Department of Thyroid Surgery, Xuzhou Central Hospital, 199 Liberation of South Road, Xuzhou, Jiangsu 221009, P.R. China
E-mail: cssxzsy@126.com

Key words: ¹⁸F-fluorodeoxyglucose positron emission tomography/computed tomography, differentiated thyroid carcinoma, tumour recurrence, metastasization

Table I. Demographic and clinical data of 15 study patients.

Patient, no.	Gender	Age, years	Histological type of the tumour	PET/CT diagnosis	Surgery/follow-up confirmation	Preoperative thyroglobulin, ng/ml	Postoperative thyroglobulin, ng/m
1	Female	36	Papillary carcinoma	2 cervical lymph nodes	2 in neck	53.36	4.34
2	Female	45	Papillary carcinoma	2 cervical lymph nodes	2 in neck	34.51	2.47
3	Male	33	Papillary carcinoma	2 cervical lymph nodes	2 in neck	61.74	5.02
4	Female	48	Follicular carcinoma	4 cervical lymph nodes	4 in neck	66.85	5.77
5	Female	25	Papillary carcinoma	3 cervical lymph nodes	2 in neck	56.27	4.73
6	Female	58	Papillary carcinoma	4 cervical lymph nodes	3 in neck	72.02	6.08
7	Male	55	Papillary carcinoma	2 cervical lymph nodes	2 in neck	42.25	3.34
8	Female	29	Papillary carcinoma	2 cervical lymph nodes	2 in neck	58.13	4.86
9	Female	52	Papillary carcinoma	2 cervical lymph nodes	2 in neck	49.61	3.53
10	Female	40	Papillary carcinoma	1 cervical lymph node	1 in neck	26.68	1.18
11	Female	50	Papillary carcinoma	5 cervical lymph nodes	4 in neck	83.43	6.71
12	Female	42	Papillary carcinoma	3 cervical lymph nodes	3 in neck	92.62	7.29
13	Female	52	Papillary carcinoma	3 cervical lymph nodes	3 in neck	63.45	5.43
14	Female	49	Papillary carcinoma	3 in the lung and 2 in the mediastinum	3 in lung and 2 in mediastinum	475.03	-
15	Male	46	Papillary carcinoma	Negative	1 in neck	46.02	-

PET, positron emission tomography; CT, computed tomography.

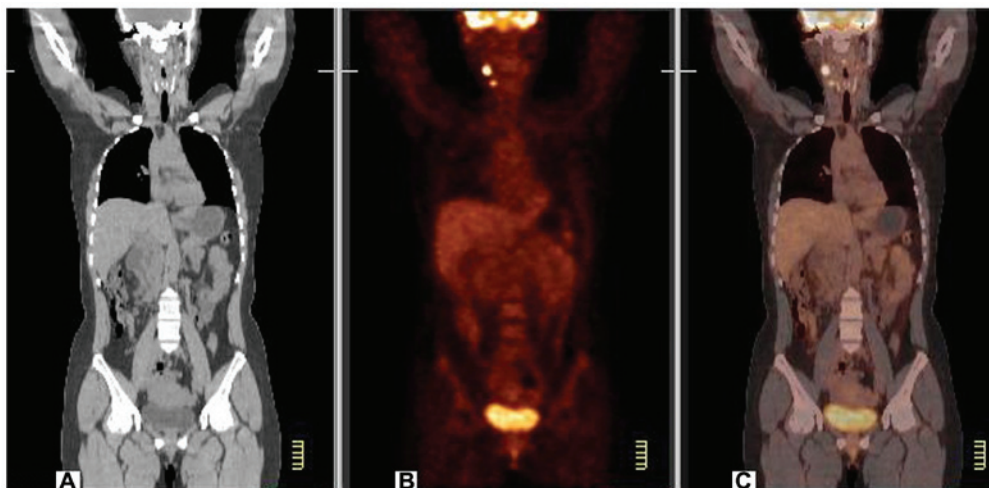


Figure 1. Cervical lymph node metastasis revealed by positron emission tomography/computed tomography (PET/CT) scanning. (A) CT imaging shows no significant neck mass. (B) PET imaging shows two lumpy abnormal radioactive concentration shadows on the right side of the neck. (C) PET/CT imaging shows two abnormal fluorodeoxyglucose hypermetabolism areas in the sternocleidomastoid region of the right side of the neck, which were considered lymph node metastases.

¹⁸F-FDG (4.4 MBq/kg). After 60 min and prior to the scanning, the patients were required to empty their bladders.

Collection ranges were from the basilar part to the proximal femur. The 16-slice helical CT scanning parameters were 140 kV, 320 mA, with flat sweeping. Data were analyzed by image fusion following iterative reconstruction, obtaining coronal, sagittal and cross-sectional CT, PET and PET/CT fusion images. The PET/CT images were reviewed independently by two radiologists who calculated a standardized uptake value of radioactive hot lesion. A standardized uptake value of ≥ 2.5 localized in metastatic regions was considered as indicative of tumour metastasization.

Diagnostic criteria of tumour recurrence or metastasization.

Based on the positive results of PET/CT scanning, the lesions located in the neck underwent surgical excision, and postoperative histopathology was carried out. The patients were monitored for their serum thyroglobulin levels for 1 month. If the lesions were located in the organs where surgical excision was problematic, the status was determined by clinical situation and the follow-up imaging results within 6 months after the initial PET/CT examination.

Data analysis. The PET/CT images were qualitatively ranked as true positive, false negative, and false positive. Sensitivity and positive predictive value (PPV) for the diagnosis of recurrence and metastasization of DTC were calculated.

Statistical analysis. The SPSS 13.0 statistical software (SPSS, Inc., Chicago, IL, USA) was used for statistical analysis. Data were presented as mean \pm standard deviation. The differences were tested using the paired t-test. $P < 0.05$ was considered to indicate a statistically significant difference.

Results

In 14 patients, PET/CT scanning had a sensitivity of 93.33%. The 14 patients were found to have 40 tumour recurrences or metastases, of which 35 were cervical lymph node metastases (Fig. 1). The tumours were excised and were identified by postoperative pathology as being tumour metastases in 32 cases and as inflammatory changes in 3 cases. Thus, PPV comprised 91.43%. In 1 patient, 5 lumps were located in the lungs and the mediastinum. No biopsy or surgical intervention were conducted in this patient. The lumps increased during the follow up for 6 months, confirming their metastatic nature.

One patient had negative PET/CT findings and developed neck lumps after 6 months of follow up, which were confirmed as tumour metastases.

A total of 13 patients with preoperative serum thyroglobulin levels of 58.53 ± 18.34 ng/ml underwent surgery. Their postoperation serum thyroglobulin levels were 4.67 ± 1.71 ng/ml ($p < 0.05$ vs. preoperative).

Discussion

Examination of thyroglobulin levels and ¹³¹I-dWBS following treatment is important for tumour monitoring and the detection of metastasization in DTC (5). Elevated thyroglobulin levels indicate recurrence or metastasization, resulting in ¹³¹I-dWBS

scans being able to locate the tumour. When ¹³¹I-dWBS shows negative findings, B-mode ultrasound, CT, MRI, PET or other imaging techniques are used to localize recurrent or metastatic tumour. The first three methods are mainly used to locate the tumour by anatomical abnormalities, while PET reveals the tumour through metabolic abnormalities (6). Each of these techniques has its advantages and limitations. By contrast, PET/CT imaging can simultaneously reveal metabolic status and anatomical location of the lesion, thus combining the advantages of PET and CT (7). This technique is useful in difficult diagnoses, such as that for postoperative scars or nodules, which lack typical benign or malignant signs. Malignant tumours consume glucose at 10-fold higher rates than normal or scar tissue, and this feature enables precise differential diagnosis in those cases (8). Therefore, combined functional and morphological examination during PET/CT can improve the ability to detect recurrent and metastatic tumours (9).

The diagnostic efficiency of ¹⁸F-FDG PET/CT imaging in the postoperative follow up of patients with DTC depends on patient selection, sample size, thyroglobulin levels, and thyroid-stimulating hormone levels (10). Sensitivity and PPV for recurrence and metastasization of DTC range from 66 to 93.3% and from 87.5 to 100%, respectively (11-13). These values are significantly higher than those achieved by B-mode ultrasound, CT, MRI, or PET alone. In the present study, sensitivity and PPV were 93.33 and 91.43%, respectively, for patients with positive thyroglobulin levels and negative ¹³¹I-dWBS findings. This is in agreement with previous findings (14-19). In such patients, metastatic tumour is more aggressive, which leads to elevation of the sensitivity of ¹⁸F-FDG PET/CT imaging. However, tumours that uptake iodine do not uptake FDG, therefore, ¹⁸F-FDG PET/CT cannot fully replace ¹³¹I-dWBS and should not be recommended for routine screening for recurrent or metastatic DTC.

In conclusion, findings of the present study indicate that ¹⁸F-FDG PET/CT imaging is an informative technique for the detection of recurrence or metastasization of DTC in patients with positive thyroglobulin levels and negative ¹³¹I-dWBS.

References

1. Wang E, Karedan T and Perez CA: New insights in the treatment of radioiodine refractory differentiated thyroid carcinomas: to lenvatinib and beyond. *Anticancer Drugs* 26: 689-697, 2015.
2. Zhang Y and Gao Z: Clinical application and progress of PET/CT in differentiated thyroid carcinoma with positive TG and negative ¹³¹I scanning. *Chin Med Device Inf* 17: 8-12, 2011 (In Chinese).
3. Bertagna F, Bosio G, Biasiotto G, Rodella C, Puta E, Gabanelli S, Lucchini S, Merli G, Savelli G, Giubbini R, *et al*: F-18 FDG-PET/CT evaluation of patients with differentiated thyroid cancer with negative I-131 total body scan and high thyroglobulin level. *Clin Nucl Med* 34: 756-761, 2009.
4. Laurens ST and Oyen WJG: Value of fluorodeoxyglucose pet/computed tomography patient management and outcomes in thyroid cancer. *Pet Clinics* 10: 265-278, 2015.
5. Krajewska J and Jarzab B: Novel therapies for thyroid cancer. *Expert Opin Pharmacother* 15: 2641-2652, 2014.
6. Kim TY, Kim WG, Kim WB and Shong YK: Current status and future perspectives in differentiated thyroid cancer. *Endocrinol Metab (Seoul)* 29: 217-225, 2014.
7. Lauri C1, Di Traglia S, Galli F, Pizzichini P and Signore A: Current status of PET imaging of differentiated thyroid cancer with second generation radiopharmaceuticals. *Q J Nucl Med Mol Imaging* 59: 105-115, 2015.

8. Tiedje V1, Schmid KW, Weber F, Bockisch A and Führer D: Differentiated thyroid cancer. *Internist (Berl)* 56: 153-166; quiz 167-168, 2015.
9. Kim SJ, Lee TH, Kim IJ and Kim YK: Clinical implication of F-18 FDG PET/CT for differentiated thyroid cancer in patients with negative diagnostic iodine-123 scan and elevated thyroglobulin. *Eur J Radiol* 70: 17-24, 2009.
10. Ma C, Xie J, Lou Y, Gao Y, Zuo S and Wang X: The role of TSH for 18F-FDG-PET in the diagnosis of recurrence and metastases of differentiated thyroid carcinoma with elevated thyroglobulin and negative scan: A meta-analysis. *Eur J Endocrinol* 163: 177-183, 2010.
11. Kaneko K, Abe K, Baba S, Isoda T, Yabuuchi H, Sasaki M, Hatakenaka M and Honda H: Detection of residual lymph node metastases in high-risk papillary thyroid cancer patients receiving adjuvant I-131 therapy: The usefulness of F-18 FDG PET/CT. *Clin Nucl Med* 35: 6-11, 2010.
12. Panareo S, Rossi R, Cittanti C, Giganti M, Prandini N, Franceschetti P, De Biasi V, Lunardon S and Feggi L: Recombinant thyrotropin stimulation improves 18F-FDG PET/CT sensitivity in patients with recurrent differentiated thyroid cancer. *J Nucl Med* 52 (Suppl 1): 1308, 2011.
13. Leboulleux S, Schroeder PR, Busaidy NL, Auperin A, Corone C, Jacene HA, Ewertz ME, Bournaud C, Wahl RL, Sherman SI, *et al*: Assessment of the incremental value of recombinant thyrotropin stimulation before 2-[¹⁸F]-Fluoro-2-deoxy-D-glucose positron emission tomography/computed tomography imaging to localize residual differentiated thyroid cancer. *J Clin Endocrinol Metab* 94: 1310-1316, 2009.
14. Vera P, Kuhn-Lansoy C, Edet-Sanson A, Hapdey S, Modzelewski R, Hitzel A, d'Anjou J and Basuyau JP: Does recombinant human thyrotropin-stimulated positron emission tomography with [¹⁸F]fluoro-2-deoxy-D-glucose improve detection of recurrence of well-differentiated thyroid carcinoma in patients with low serum thyroglobulin? *Thyroid* 20: 15-23, 2010.
15. Hevrouet T, Devillers A, Cuggia M, Bernard AM, Le Jeune F, Le Dortz L, Herry JY and Garin E: Influence of rhTSH on 18 FDG uptake in a population of 42 patients with suspected recurrence of differentiated thyroid carcinoma. *Med Nucl (Paris)* 33: 321-330, 2009 (In French).
16. Volante M, Collini P, Nikiforov YE, Sakamoto A, Kakudo K, Katoh R, Lloyd RV, LiVolsi VA, Papotti M, Sobrinho-Simoes M, *et al*: Poorly differentiated thyroid carcinoma: The Turin proposal for the use of uniform diagnostic criteria and an algorithmic diagnostic approach. *Am J Surg Pathol* 31: 1256-1264, 2007.
17. Stokkel MP, Duchateau CS and Dragoiescu C: The value of FDG-PET in the follow-up of differentiated thyroid cancer: a review of the literature. *Q J Nucl Med Mol Imaging* 50: 78-87, 2006.
18. Yamaga LY, Cunha ML, Wagner J, Thom AF, Daniel MM and Funari MB: Diagnostic value of positron emission tomography/computed tomography with fluorine-18 fluorodeoxyglucose in patients with differentiated thyroid gland carcinoma, high thyroglobulin serum levels and negative iodine whole body scan. *Arq Bras Endocrinol Metabol* 51: 581-586, 2007 (In Portuguese).
19. Rivera M, Ghossein RA, Schoder H, Gomez D, Larson SM and Tuttle RM: Histopathologic characterization of radioactive iodine-refractory fluorodeoxyglucose-positron emission tomography-positive thyroid carcinoma. *Cancer* 113: 48-56, 2008.