

Access this article online
Quick Response Code:

Website: www.jorthodsci.org
DOI: 10.4103/jos.JOS_21_18

# Accuracy and reliability of tooth length measurements on conventional and CBCT images: An *in vitro* comparative study

Kumar Adarsh, Payal Sharma and Achint Juneja

## Abstract:

**CONTEXT:** The purpose of this study was to evaluate the accuracy and reliability of tooth length measurements using conventional and cone-beam computed tomography (CBCT) imaging techniques.

**AIM:** The aim of this study was to assess the accuracy and reliability of various tooth length measurements made on CBCT scans and conventional imaging techniques [intraoral periapical radiograph (IOPA) and orthopantomogram (OPG)].

**SETTINGS AND DESIGN:** This is an *in-vitro* comparative study.

**SUBJECTS AND METHODS:** In total, 50 extracted single-rooted premolar teeth were mounted on the dry human mandible. For each extracted tooth, measurements for tooth length, crown length, and root lengths were taken with a Vernier caliper and using three imaging modalities: CBCT, OPG, and IOPA radiographs. The measurements were compared with the gold standard (Vernier caliper).

**STATISTICAL ANALYSIS USED:** One-way analysis of variance was used to compare mean values between the groups that are Vernier caliper, CBCT, IOPA, and OPG. The multiple comparisons of means of tooth length, root length, and crown length were done by Bonferroni test.

**RESULTS:** A significant difference in the tooth length measurements was seen between the measurements taken by CBCT and IOPA and between IOPA and OPG. But, no significant difference was seen between any other groups. The highly significant difference was seen between the root length measurements taken by IOPA and OPG and by CBCT and OPG. However, no significant difference was seen between any other groups. No significant difference was seen in between the crown length measurements taken by Vernier caliper and CBCT and between IOPA and OPG. However, a significant difference was seen between all the groups.

**CONCLUSIONS:** Among the radiographic techniques, CBCT was found to be the most accurate in measuring the tooth, root, and crown lengths.

## Keywords:

CBCT, conventional radiographic technique, IOPA, tooth length measurements

Department of  
Orthodontics and  
Dentofacial Orthopedics,  
I.T.S. Dental College,  
Muradnagar, Affiliated from  
Chaudhary Charan Singh  
University, Ghaziabad,  
Uttar Pradesh, India

## Address for correspondence:

Dr. Kumar Adarsh,  
S/o Dr. Anjani Kumar  
Sinha, House No-11,  
Road No-5, East Patel  
Nagar, Patna - 800 023,  
Bihar, India.  
E-mail: kumarkumaradarsh  
@gmail.com

## Introduction

As stated by Mah and Hatcher,<sup>[1]</sup> if the aim is to improve the “quality, efficiency and accessibility of craniofacial care,” then there is a great need for “accurate and effective imaging modalities.” The

This is an open access journal, and articles are distributed under the terms of the Creative Commons Attribution-NonCommercial-ShareAlike 4.0 License, which allows others to remix, tweak, and build upon the work non-commercially, as long as appropriate credit is given and the new creations are licensed under the identical terms.

For reprints contact: reprints@medknow.com

complication of root resorption has puzzled dental researchers and clinicians for many years. Anterior maxillary teeth resorb an average of 1.4 mm<sup>[2]</sup> during orthodontic treatment, and 20% of patients have at least one maxillary incisor resorb >2 mm during the first year of treatment.<sup>[3]</sup> Orthodontically induced root resorption is also common in posterior teeth, with

**How to cite this article:** Adarsh K, Sharma P, Juneja A. Accuracy and reliability of tooth length measurements on conventional and CBCT images: An *in vitro* comparative study. J Orthodont Sci 2018;7:17.

up to 47% with some root blunting, up to 27% having moderate root resorption, and up to 6.5% with severe resorption of at least a third of pretreatment root length.<sup>[4]</sup>

The periapical radiograph, using paralleling technique, is considered the clinical gold standard for measuring tooth length and estimating root resorption.<sup>[2,3]</sup>

Errors in vertical film positioning (angulation errors, linear errors, film bending, and so on) or incorrect angulation of the film-holding instrument (FHI) causes distorted (elongated or foreshortened) radiographic images.<sup>[5]</sup> Anatomic variations (e.g., high narrow palate, large tori, and so on) also cause the error in radiographs. Changes in the angle between the tooth and the film also have a significant effect on periapical radiograph-based linear measurements.<sup>[6]</sup> Being a two-dimensional (2D) radiography, there might also be overlapping of anatomic structures, making it difficult to identify reference points.

Interest in three-dimensional (3D) imaging devices has grown over the last decade. In the quest to adopt 3D imaging for orthodontic diagnosis and treatment planning, scans providing high diagnostic quality that allows for accurate 3D measurements of the entire craniofacial structure are needed.

Cone-beam computed tomography (CBCT), a radiographic alternative that produces multiplanar reformatted (MPR) images and allows 2D views in all three dimensions (axial, coronal, and sagittal planes), can overcome the orientation errors and overlapping problems inherent with periapical radiographs.<sup>[7]</sup> In CBCT, the volumetric data can also be reconstructed to produce a view that is perceived as 3D and can be rotated for alternative perspectives. We can also orient the volumetric data to produce specialized views in various 2D planes. Clear visualization of the dentition (root positions, exact locations of impacted teeth, and so on) can be performed with CBCT. The radiation risk associated with CBCT is approximately equivalent to a conventional full mouth intraoral series of radiographs; CBCT volumetric data give the clinician significantly more diagnostic information. The high accuracy of CBCT measurements has been shown in many studies evaluating geometric objects and human skulls, with CBCT estimates within 1%–2% of the actual lengths.<sup>[8]</sup>

The aim of this study was to assess the accuracy and reliability of various tooth length measurements made on CBCT scans and conventional imaging techniques [intraoral periapical radiograph (IOPA) and orthopantomogram (OPG)].

## Subjects and Methods

Fifty single rooted premolar teeth extracted for orthodontic purposes were selected according to the following inclusion and exclusion criteria.

### Inclusion criteria

1. Fully developed teeth
2. Intact and with an undamaged root structure.

### Exclusion criteria

1. Presence of metal restorations
2. The incomplete growth of the root apex (RA) or presence of obvious root resorption
3. Presence of severe occlusal attrition.

The selected teeth were cleaned of any adherent soft tissue, bone fragment, and calculus by scaling and polishing. The cleaned teeth were collected and stored as per centers for disease control and prevention (CDC) guidelines. These teeth were placed in a container with 5% sodium hypochlorite solution.

For each extracted tooth, the actual measurements for tooth length, crown length, and root length were measured with a Vernier caliper (group 1) and using three imaging modalities: CBCT (group 2), OPG (group 3), and IOPA (group 4) radiographs. The following landmarks were used to make the measurements:

1. Root apex: RA was the most apical portion of the root
2. Mesial cementoenamel junction (MCEJ): MCEJ was the most apical part of the cementoenamel junction in the mesial side
3. Distal cementoenamel junction (DCEJ): DCEJ was the most apical part of the cementoenamel junction in the distal side
4. Cusp tip: most occlusal point of cusp.

Total tooth length was measured from the RA to cusp.

Root length was measured from the midpoint of the line joining MCEJ and DCEJ to the RA.

The crown length was measured from the midpoint of the line joining MCEJ and DCEJ to the cusp tip.

For each extracted tooth, each measurement was taken thrice with a digital Vernier caliper (Precision 150 digital caliper) accurate to within 0.01 mm [Figure 1]. The average of these measurements was taken as the actual value.

The selected teeth were mounted in the socket of a dry human mandible to simulate natural condition [Figure 2]. Ten teeth are mounted at a time. Five samples were prepared to be mounted on the extraoral imaging system.

As stated by Schropp *et al.*,<sup>[9]</sup> the soft tissues of the average human cheek can be simulated with 13–17 mm wax or 14.5 mm acrylic in *in-vitro* radiographic studies. A layer of modeling wax of 15 mm thickness was placed buccally and lingually to mimic soft tissues. A wooden customized base was prepared over which the mandible was placed to simulate normal standing patient position. The same customized table was used for each scan in CBCT and OPG

CBCT radiograph and measurement [Figure 3]: The mounted mandible was placed on top of the custom made wooden table/stool and centered over the plastic bite plate of the New Tom Giano Extra-Oral Imaging System (Newtom – Giano, Vila Silverstrini, Verona, Italy) (high frequency, stationary anode: 60–90 kV; 1–10 mA, pulsed mode 0.5 mm focal spot). The guidance beams were used to determine the mounted mandible's correct position simulating the patient positioning protocol. Then, two initial scout images were taken to confirm the correct positioning. The final scan was taken at 90 kV at a resolution of 200 microns or 0.2 mm at a field of view (FOV) of 5 × 8 cm. After the acquisition, each tooth was individually localized in the MPR view in all three orthogonal planes, that is, axial, coronal, and sagittal. The measurements were done on each respective section in the sagittal plane. Measurements were made by two calibrated examiners using NNT software with the free viewer and sharing application version.



Figure 1: Measurement by Vernier caliper

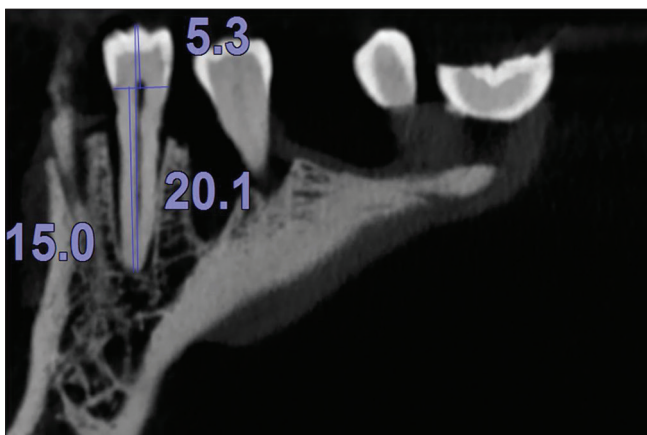


Figure 3: Measurement by cone-beam computed tomography

Panoramic radiograph and measurement [Figure 4]: The mounted mandible was placed on top of the customized wooden base centered over the flat plastic bite plate of KODAK 8000C Digital Panoramic and Cephalometric Extraoral Imaging orthopantomogram machine (KODAK 8000C Digital Panoramic and Cephalometric Extraoral Imaging System, Carestream Inc., NY, USA) in such a way that it lay within the confine of focal trough of the machine. Then, the panoramic imaging mode was selected on the Care Stream software and image acquisition was done. Total tooth length, crown length, and root length were measured as mentioned before.

Intraoral periapical radiograph and measurement [Figure 5]: Periapical radiographs of the teeth were taken with the Satelac-X Mind radiograph machine (Satelec-X Mind, France). Size-2 Kodak Insight (F speed) film and 0.40 s exposure time was used for imaging the teeth. All periapical radiographs were taken with the paralleling technique. Each tooth was mounted in the mandible socket individually. The film was aligned vertically parallel to the long axis of the tooth (clinical crown) and the x-ray tube (perpendicular to the incident x-ray beam). Horizontally, the film was placed parallel to a line connecting the most mesial and distal aspects of the tooth. The film was placed in a Rinn XCP film holding

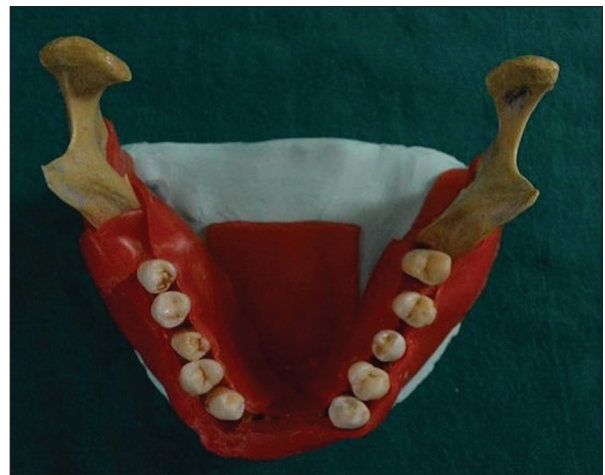

Figure 2: Extracted teeth mounted on the human mandible

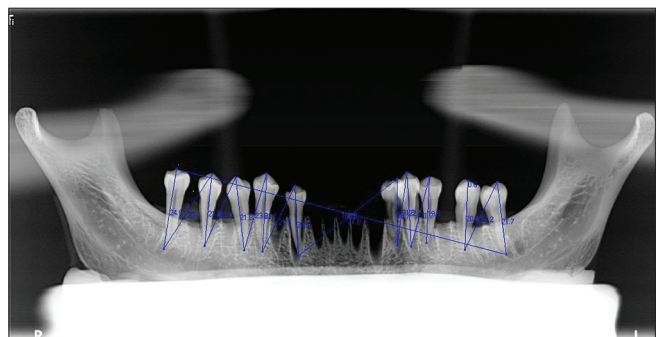


Figure 4: Measurement by orthopantomogram

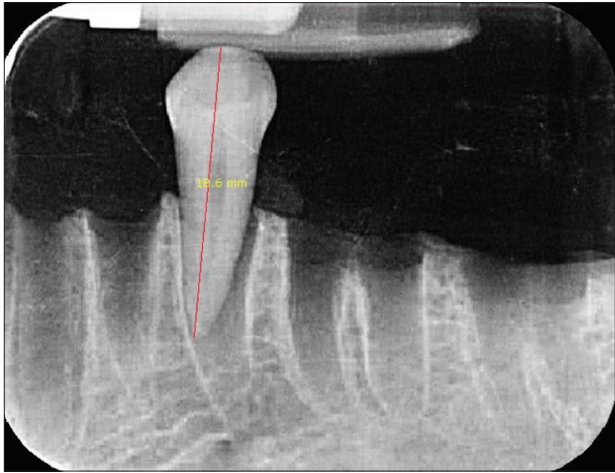


Figure 5: Measurement by intraoral periapical radiograph

instrument (Rinn, Elgin, IL, USA). Before capturing each radiograph, the bite block of the Film Holding Instrument was placed against the incisal edge or cusp tip of the tooth. Film holder was stabilized with modeling wax to maintain constant film position (parallel with the table) during image capture. The images were transferred to DBSWIN software for measurements.

The data were subjected to statistical analysis using SPSS (Statistical Package for Social Sciences) version 20.0 statistical analysis software. The descriptive statistics including the mean, standard deviation (SD), minimum, and maximum values were calculated for each of the four experimental groups. One-way analysis of variance (ANOVA) was used to compare the mean tooth length, root length, and crown length by the four groups (Vernier caliper, CBCT, IOPA, and OPG). The *t*-test was used to compare the individual mean between all four groups.

## Results

It was evident that based on the pilot study, the length difference, mean, and SD of group 1 (Vernier caliper) and group 2 (CBCT) were 0.74 and 1.67 and 1.71, respectively, and mean difference of length was of two groups. Using the given formula with software Open Epi, Version 3, we have found the sample size for each group was 50. The formula used for this calculation was

$$n = \frac{(\sigma_1^2 + \sigma_2^2)(Z_{1-\alpha/2} + Z_{1-\beta})^2}{\Delta^2}$$

The notation for the formulae is as follows:

*n* is the sample size of groups,  $\sigma_1$  is the SD of group 1 = 1.67,  $\sigma_2$  is the SD group 2 = 1.71,  $\Delta$  is the difference in group means = 0.95,  $Z_{1-\alpha/2}$  = Z value (e.g., Z = 1.96 for 95% confidence interval), and  $Z_{1-\beta}$  = power = 80%.

To check the reliability, measurements were repeated on 10 teeth after an interval of 1 month. There was no significant difference in the repeated measurements of all the three variables. One-way ANOVA was used to compare mean values between the groups. The multiple comparisons of means of tooth length, root length, and crown length were done by Bonferroni test. A significant difference in the tooth length measurements [Table 1] was seen between the measurements taken by CBCT and IOPA ( $P = 0.020$ ) and between IOPA and OPG ( $P = 0.000$ ). No significant difference was seen between any other groups. The highly significant difference was seen between the root length measurements [Table 2] taken by IOPA and OPG ( $P = 0.001$ ) and by CBCT and OPG ( $P = 0.043$ ). However, no significant difference was seen between any other groups. No significant difference was seen between the crown length measurements [Table 3] taken by Vernier caliper and CBCT ( $P = 1.000$ ) and between IOPA and OPG ( $P = 1.000$ ). However, a significant difference was seen between all the groups.

The intraclass correlation coefficient for tooth length, root length, and crown length between Vernier caliper and different imaging methods was found to be significant with ICC value >0.70 indicating high correlation.

## Discussion

Advances in CBCT technology now make it feasible for this imaging to be the standard of care in orthodontic practice. However, the realization of its full potential in everyday diagnosis and treatment planning requires its validation through accuracy and reliability studies. Debates are found in the literature about the accuracy of the measurements obtained from CBCT scans. Some claim that there are underestimations<sup>[10]</sup> of the measurements, and others claim that the measurements have a 1:1 ratio to the real size measurements.<sup>[11]</sup> The present study was conducted to evaluate the accuracy of measurements of tooth lengths made on different imaging modalities compared to actual lengths measured with a Vernier caliper. The results indicated that CBCT can measure tooth length more accurately than any other radiographic method. On an average, it underestimated the actual tooth length by ~0.2 mm, whereas on OPG tooth lengths were found to be 0.8 mm shorter and IOPA gave an average magnification of 0.82 mm. The findings of this study are in agreement with those of Sherrard *et al.*,<sup>[12]</sup> who evaluated the accuracy and reliability of tooth length and root length measurements derived from CBCT volumetric data. In their study, CBCT tooth length and root length measurements were not significantly different from the actual lengths; the mean differences were <0.3 mm, which is very close to the 0.2 mm average difference found in our study.

**Table 1: Descriptive analysis and multiple comparisons of tooth length measurement**

Group	n	Mean±SD	SE	95% CI for mean		Significant
				Lower bound	Upper bound	
Vernier caliper	50	21.50±1.67	0.24	21.03	21.98	0.001*
CBCT	50	21.2±1.7	0.26	20.7	21.7	
IOPA	50	22.3±1.8	0.25	21.8	22.8	
OPG	50	20.7±2.0	0.28	20.1	21.2	

SE – Standard error; SD – Standard deviation; CI – Confidence interval; CBCT – Cone-beam computed tomography; IOPA – Intraoral periapical radiograph; OPG – Orthopantomogram. \* $P < 0.001$  is highly significant. A significant difference was seen between group CBCT versus IOPA; and group IOPA versus OPG

**Table 2: Descriptive analysis and multiple comparisons of root length measurement**

Group	n	Mean±SD	SE	95% CI for mean		Significant
				Lower bound	Upper bound	
Vernier caliper	50	14.02±1.38	0.19	13.63	14.41	0.002*
CBCT	50	14.2±1.3	0.18	13.8	14.6	
IOPA	50	14.5±1.4	0.20	14.1	14.9	
OPG	50	13.4±1.5	0.22	12.9	13.9	

SE – Standard error; SD – Standard deviation; CI – Confidence interval; CBCT – Cone-beam computed tomography; IOPA – Intraoral periapical radiograph; OPG – Orthopantomogram. \* $P < 0.05$  is significant. A significant difference was seen between group CBCT versus IOPA and group IOPA versus OPG

**Table 3: Descriptive analysis and multiple comparisons of crown length measurement**

Group	n	Mean±SD	SE	95% CI for mean		Significant
				Lower bound	Upper bound	
Vernier caliper	50	8.15±1.05	0.15	7.85	8.44	0.001*
CBCT	50	7.9±0.9	0.12	7.7	8.2	
IOPA	50	7.3±1.3	0.18	6.9	7.6	
OPG	50	7.1±0.8	0.11	6.9	7.4	

SE – Standard error; SD – Standard deviation; CI – Confidence interval; CBCT – Cone-beam computed tomography; IOPA – Intraoral periapical radiograph; OPG – Orthopantomogram. \* $P < 0.05$  signifies a significant difference between the value of four groups. A significant difference was seen between group Vernier caliper versus IOPA; group Vernier caliper versus OPG and group CBCT versus OPG

The high accuracy of CBCT measurements has been shown in many studies evaluating geometric objects and human skulls, with CBCT estimates within 1%–2% of the actual lengths. A study by Marmulla *et al.*<sup>[8]</sup> using CBCT on a 12 × 12 × 12 cm phantom geometric cube showed an absolute measurement error of 0.13 mm. Periago *et al.*<sup>[13]</sup> compared the accuracy of linear measurements made on CBCT-derived 3D surface rendered volumetric images to direct measurements. Although the results showed significant differences between all measurements, they were not clinically significant. Lascala *et al.*<sup>[10]</sup> made 13 measurements on 8 skulls using landmarks identified throughout the craniofacial complex. Interestingly, real measurements were always found to be larger than those from the CBCT images, with statistically significant differences involving measurements of the skull base. The authors suggested that this result was expected since the NewTom 9000 was specifically designed for imaging the dentomaxillofacial region.

In this study, CBCT underestimated tooth length by 0.2 mm (1.2%), but overestimated root length by 0.2 mm (1.4%). OPG underestimated tooth length by an average of 0.8 mm (3.9%) and root length by 0.6 mm (4.2%). IOPA overestimated tooth length by about 0.82 mm (3.8%), whereas root length was magnified by 0.5 mm (3.5%). The crown length was measured

shorter than the actual length by about 0.2 mm (2.9%), 0.8 mm (10.7%), and 0.9 mm (12.5%) with CBCT, IOPA, and OPG respectively. The tooth length measurements by IOPA were statistically different than those made on CBCT and OPG. For root length, a significant difference was seen between the measurements by CBCT and OPG and also between IOPA and OPG.

The findings of this study agree with that of Sherrard *et al.*<sup>[12]</sup> who also found that root length measurements derived from periapical radiographs were less accurate than those from CBCT scans. However, in contrast to this study in which root length was overestimated on periapical radiographs by about 0.5 mm, they found that IOPA underestimates actual root length by an average of 2.6 mm, with errors between 1.1 and 4.1 mm, with underestimation 95% of the time. This difference can be explained by the difficulty in identifying the actual CEJs on the periapical radiographs. These landmarks were obscured with 2D radiographs, even with ideal horizontal angulation. Brezniak *et al.*<sup>[14]</sup> showed that the median CEJ (i.e., the midpoint between MCEJ and DCEJ) is a reliable reference point to measure root length (even with changes in tooth angulation), but they used amalgam dots on an acrylic tooth. Identification of the actual landmarks with 2D radiography might be more difficult.

Although imaging errors can be reduced by paralleling techniques, it can still be difficult to obtain ideal film and x-ray tube head orientations. Errors in vertical film positioning (angulation errors, linear errors, film bending, and so on) or incorrect angulation of the FHI can lead to distorted images. Anatomic variations such as high narrow palate and large tori can further complicate the ability to reproduce orientations. Linear measurements made on periapical radiographs can be affected by changes in the angle between the tooth and the film. Overlapping of anatomic structures makes it difficult to identify reference points on 2D radiographs.

Both periapical and panoramic radiographs can be used to assess root resorption. In this study, IOPA and OPG measurements of the tooth and root lengths showed a similar amount of difference when compared with Vernier caliper measurements; however, the differences were in the opposite direction. IOPA overestimated root and total tooth lengths by about 0.5 and 0.8 mm, respectively. However, OPG underestimated total tooth, root, and crown lengths by 0.8, 0.6, and 0.9 mm, respectively. This is in contrast to some studies where periapical films were found to be superior in estimating root length compared with panoramic images, because there are less image distortion and greater fine detail resolution on periapical radiographs. Panoramic images have been found to both overestimate and underestimate the amount of root loss following orthodontic movement. By positioning the chin too high, the hard palate becomes superimposed on the roots of the maxillary teeth. If the chin is tilted down, the teeth will appear overlapped. The correct position is to align the head so that the Frankfort plane is parallel to the floor. The difficulty in identifying the cemento-enamel junction was given as the main reason for the inability to measure in panoramic films. The amount of magnification varies within the skull, but generally averages 20%–35%. The magnification factor is relatively constant in the vertical dimension, but horizontal measurements were found to be less reliable.

The findings of this study show that CBCT is the most accurate when measuring root length. This is in agreement with studies,<sup>[15]</sup> which show multidetector computed tomography to be more accurate than 2D intraoral radiography in identifying root resorption caused by ectopically erupting canines. Pittayapat *et al.*<sup>[16]</sup> used 21 dry human skull and 13 linear measurements were completed twice by two observers with a 4-week interval. This study has confirmed the knowledge on the accuracy of linear cephalometric measurements of 2D and 3D images. Although the results did not show that 3D measurements were more accurate than the 2D standard digital lateral cephalograms, the results did confirm that 3D measurements were more reliable

than measurements on 2D images. According to Asgary *et al.*,<sup>[17]</sup> CBCT has acceptable diagnostic accuracy for measurement of canal wall thickness. Anter *et al.*<sup>[18]</sup> concluded that CBCT provides an assessment of alveolar bone loss in the periodontal defect with a minimum reported mean measurements error of  $0.19 \pm 0.11$  mm and maximum reported mean measurements error of  $1.27 \pm 1.43$  mm, and there is no agreement between the studies regarding the direction of the deviation whether over- or underestimation.

In the study performed by Rokn *et al.*,<sup>[19]</sup> estimation of size on CBCT scans had an error of 8.46% (underestimation) to 5.21% (overestimation). In 26.5% of the cases, an accepted error of  $\pm 1\%$  was found. The absolute value of errors was found to be in the range of 0.21–8.46 mm with an average value of  $2.86 \pm 2.30$  mm.

Yi *et al.*<sup>[20]</sup> conducted a systematic study and meta-analysis to compare the diagnostic accuracy of CBCT and periapical radiographs (PR) for the detection of external root resorption (ERR) and found that CBCT had significantly higher sensitivity than PR. All studies adopted the artificially created ERR as the reference text. Comparisons between CBCT and PR of the diagnostic efficacy to detect ERR were performed. The results showed that CBCT had a significantly higher sensitivity than PR. Unfortunately, the current clinical trials seem to be unconvincing because there is no gold standard for ERR *in vivo*. Moreover, the comparison indicates that CBCT is superior to PR in diagnosing ERR. This study suggests that CBCT could be reliable in detecting the presence of ERR in clinical practice, which has a higher diagnostic efficacy than PR. However, in this study, we have chosen three radiographic techniques, which are used in our daily orthodontic practice. This study describes proper accuracy and reliability of all radiographic technique with a gold standard of Vernier caliper, which was lacking in earlier studies.

The results of this study indicate that CBCT is a better modality to measure the tooth lengths as compared to IOPA and OPG. Intraobserver reliability in the measurement of tooth length, root length, and crown length was also found to be significantly higher with CBCT when compared with 2D measurements.

A limitation of this study was the use of only single-rooted premolar teeth. They were used as a convenience sample because of their availability in premolar extraction cases in orthodontic patients and because they could be placed easily in the sockets of the mandible. However, the accuracy of the tooth and root lengths should also be evaluated on multirooted teeth and morphologically different types of teeth.

## Conclusions

1. The tooth, root, and crown lengths were found to be significantly different when measured with the Vernier caliper and on CBCT, OPG, and IOPA
2. Among the radiographic techniques, CBCT was found to be the most accurate in measuring the tooth, root, and crown lengths
3. CBCT underestimated tooth length by 1.2% and crown lengths by an average of 2.9%; it overestimated root length by 1.2%
4. IOPA overestimated tooth length by an average of 0.8 mm and root length by 0.5 mm. OPG underestimated tooth length by about 0.8 mm and root length by 0.6 mm
5. On comparing the crown length measurement, IOPA underestimated by 0.8 mm and OPG by 0.9 mm.

## Financial support and sponsorship

Nil.

## Conflicts of interest

There are no conflicts of interest.

## References

1. Mah J, Hatcher D. Current status and future needs in craniofacial imaging. *Orthod Craniofac Res* 2003;6 Suppl 1:10-6.
2. Sameshima GT, Sinclair PM. Predicting and preventing root resorption: Part I. Diagnostic factors. *Am J Orthod Dentofacial Orthop* 2001;119:505-10.
3. Artun J, Smale I, Behbehani F, Doppel D, Van't Hof M, Kuijpers-Jagtman AM. Apical root resorption six and 12 months after initiation of fixed orthodontic appliance therapy. *Angle Orthod* 2005;75:919-26.
4. McNab S, Battistutta D, Taverne A, Symons AL. External apical root resorption following orthodontic treatment. *Angle Orthod* 2000;70:227-32.
5. Kazzi D, Horner K, Qualtrough AC, Martinez-Beneyto Y, Rushton VE. A comparative study of three periapical radiographic techniques for endodontic working length estimation. *Int Endod J* 2007;40:526-31.
6. Brezniak N, Goren S, Zoizner R, Dinbar A, Arad A, Wasserstein A, *et al.* A comparison of three methods to accurately measure root length. *Angle Orthod* 2004;74:786-91.
7. White SC, Pharoah MJ, Tyndall DA. *Oral Radiology: Principles and Interpretation*. St. Louis: Mosby; 2000.
8. Marmulla R, Wörtche R, Mühling J, Hassfeld S. Geometric accuracy of the NewTom 9000 cone beam CT. *Dentomaxillofac Radiol* 2005;34:28-31.
9. Schropp L, Alyass NS, Wenzel A, Stavropoulos A. Validity of wax and acrylic as soft-tissue simulation materials used in *in vitro* radiographic studies. *Dentomaxillofac Radiol* 2012;41:686-90.
10. Lascala CA, Panella J, Marques MM. Analysis of the accuracy of linear measurements obtained by cone beam computed tomography (CBCT-newTom). *Dentomaxillofac Radiol* 2004;33:291-4.
11. Lagravère MO, Carey J, Toogood RW, Major PW. Three-dimensional accuracy of measurements made with software on cone-beam computed tomography images. *Am J Orthod Dentofacial Orthop* 2008;134:112-6.
12. Sherrard JF, Rossouw PE, Benson BW, Carrillo R, Buschang PH. Accuracy and reliability of tooth and root lengths measured on cone-beam computed tomographs. *Am J Orthod Dentofacial Orthop* 2010;137:S100-8.
13. Periago DR, Scarfe WC, Moshiri M, Scheetz JP, Silveira AM, Farman AG, *et al.* Linear accuracy and reliability of cone beam CT derived 3-dimensional images constructed using an orthodontic volumetric rendering program. *Angle Orthod* 2008;78:387-95.
14. Brezniak N, Goren S, Zoizner R, Dinbar A, Arad A, Wasserstein A, *et al.* The use of an individual jig in measuring tooth length changes. *Angle Orthod* 2004;74:780-5.
15. Alqerban A, Hedesiu M, Baciut M, Nackaerts O, Jacobs R, Fieuws S, *et al.* Pre-surgical treatment planning of maxillary canine impactions using panoramic vs. cone beam CT imaging. *Dentomaxillofac Radiol* 2013;42:20130157.
16. Pittayapat P, Bornstein MM, Imada TS, Coucke W, Lambrechts I, Jacobs R, *et al.* Accuracy of linear measurements using three imaging modalities: Two lateral cephalograms and one 3D model from CBCT data. *Eur J Orthod* 2015;37:202-8.
17. Asgary S, Nikneshan S, Akbarzadeh-Bagheban A, Emadi N. Evaluation of diagnostic accuracy and dimensional measurements by using CBCT in mandibular first molars. *J Clin Exp Dent* 2016;8:e1-8.
18. Anter E, Zayet MK, El-Dessouky SH. Accuracy and precision of cone beam computed tomography in periodontal defects measurement (systematic review). *J Indian Soc Periodontol* 2016;20:235-43.
19. Rokn AR, Hashemi K, Akbari S, Kharazifard MJ, Barikani H, Panjnoosh M, *et al.* Accuracy of linear measurements using cone beam computed tomography in comparison with clinical measurements. *J Dent (Tehran)* 2016;13:333-9.
20. Yi J, Sun Y, Li Y, Li C, Li X, Zhao Z. Cone-beam computed tomography versus periapical radiograph for diagnosing external root resorption: A systematic review and meta-analysis. *Angle Orthod* 2017;87:328-37.