

RESEARCH

Open Access



Therapeutic potential of a novel combination of Curcumin with Sulfamethoxazole against carbon tetrachloride-induced acute liver injury in Swiss albino mice

Rasha Fekry Zahran^{1*} , Zeinab M. Geba¹, Ashraf A. Tabll² and Mohammad M. Mashaly³

Abstract

Background: In the current study, we have investigated the effect of each of curcumin (CUR) and sulfamethoxazole (SMX) either separate or mixed together (CUR + SMX) on biochemical, hematological and histological alternations associated with carbon tetrachloride (CCl₄)-induced liver fibrosis in mice.

Results: CCl₄ caused changes of several biomarkers, proving its hepatotoxic effects, such as an increase in aminotransferases liver enzymes alanine and aspartate transaminases (ALT, AST), malondialdehyde (MDA), and nitric oxide (NO) formation, with a decrease in superoxide dismutase (SOD), glutathione reductase (GSSG), total antioxidant capacity (TAO), glutathione (GSH), total protein, and albumin, compared to a negative control mice group. Compared to the CCl₄ group of mice, the CUR and SMX separate and/or together (CUR + SMX) treatments showed significance in ($p < 0.001$), ameliorated liver injury (characterized by an elevation of (ALT, AST) and a decrease ($p < 0.001$) in serum albumin and total protein), antioxidant (characterized by a decrease in ($p < 0.001$) MDA, NO; an increase ($p < 0.001$) SOD, GSSG, TAO; and reducing GSH), hematological changes (characterized by a decrease ($p < 0.001$) in white blood cells count and an increase ($p < 0.001$) in platelets count, hematocrit levels, hemoglobin concentration, and ($p < 0.05$) red blood cells count), SDS-PAGE electrophoresis with a decrease in protein synthesis and changes in histological examinations.

Conclusions: CUR and SMX either separate or together (SUR + SMX) may be considered promising candidates in the prevention and treatment of liver fibrosis.

Keywords: Fibrosis, Carbon tetrachloride, Curcumin, Sulfamethoxazole, Oxidative stress, Histopathology

Impact statement

Liver diseases particularly liver fibrosis, cirrhosis, and hepatocellular carcinoma are major health problems worldwide and in Egypt. The current work reports on the impact of the therapeutic potential of curcumin (CUR) and/or sulfamethoxazole (SMX) against carbon

tetrachloride-induced acute liver injury in Swiss albino mice. We demonstrated the CUR and SMX used separate or mixed together may be promising therapy in the prevention and treatment of liver fibrosis.

Background

The liver carries out an essential job in the control of various physiological processes and it controls some vital functions, for example secretion, storage, and metabolic activities. It is frequently exposed to different xenobiotic

* Correspondence: zahran@du.edu.eg; rzahran17@yahoo.com

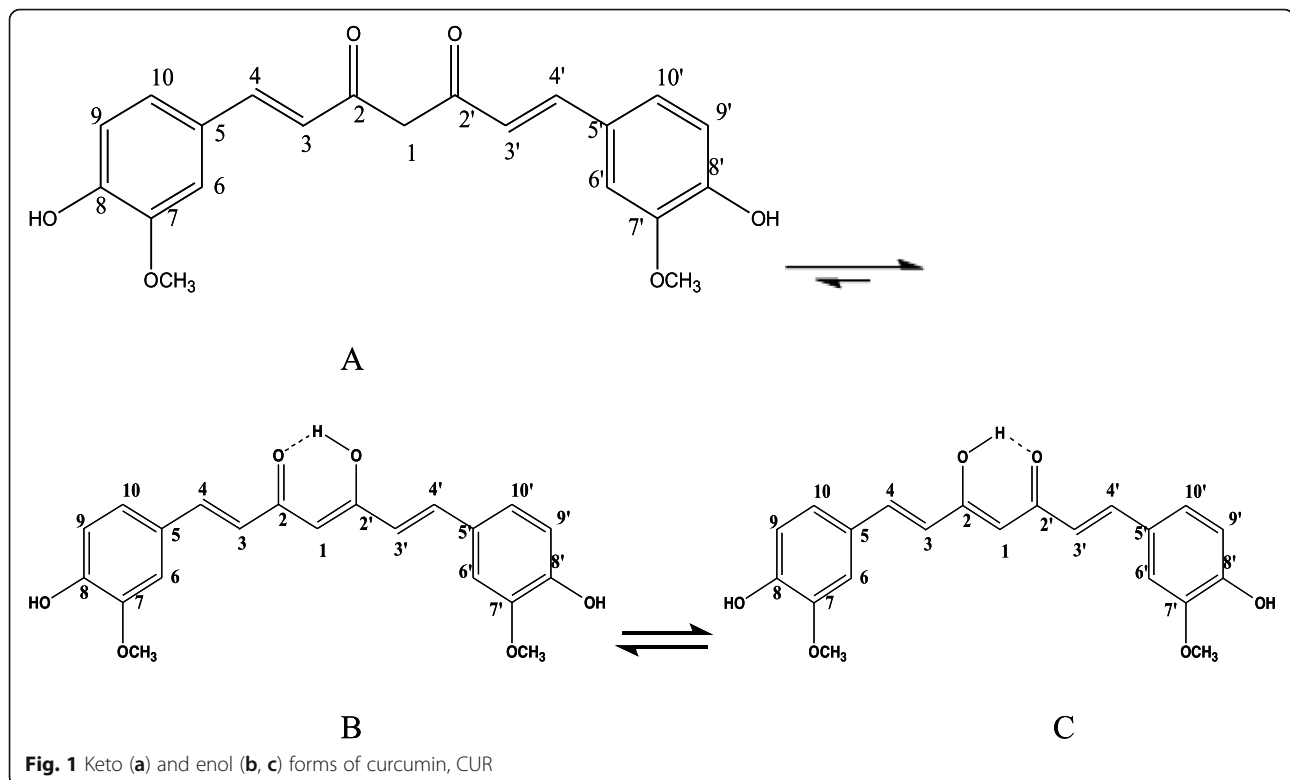
¹Department of Chemistry (Biochemistry division), Faculty of Science, Damietta University, New Damietta, Egypt

Full list of author information is available at the end of the article

and therapeutic agents. It detoxifies exogenous (toxic compounds) and endogenous (waste metabolites) substances of organisms and integrates helpful operators [1]. As far as anyone is concerned, no reports are available regarding actual curative therapy agents for liver disorders or diseases and most of the existing remedies only aid in healing or regeneration of liver [2]. Fibrosis, a general clinical condition, can be seen in various organs, but mostly in the liver. It is regularly connected with the end phase's of chronic inflammatory diseases [3, 4]. Liver fibrosis is the phenomena of the advancement of a hepatic scar because of chronic liver injury, coming about because of complex interconnected changes in cell population, extracellular matrix (ECM), and cytokines [5, 6]. For this study, fibrosis utilized carbon tetrachloride (CCl_4)-induced animal model [7, 8], published reports [9], showed CCl_4 as xenobiotic to induce acute and chronic tissue injuries through bio-enactment of the stage I cytochrome P450 enzymes to deliver receptive metabolic trichloromethyl radicals (CCl_3) and peroxy trichloromethyl radicals (OOCCL_3). These receptive metabolites have potential to covalently bond with enormous particles, for instance, lipids, proteins, and nucleic acids, pushing them out of their typical crucial usefulness. CCl_4 injection lead to an expansion type of free radicals that are chemically highly reactive, and if they do not cause injury or necrosis, they bring about

genuine unsafe impacts, such as hepatic fibrosis, copying the oxidative stress that has a fibrogenic effect on hepatic stellate cells (HSC) [3, 5, 6, 10, 11]. Curcumin, CUR (Fig. 1): 1, 7-bis (4-hydroxy-3-methoxyphenyl) hepta-1, 6-diene-3, 5-dione. ($\text{C}_{21}\text{H}_{20}\text{O}_6$, molecular weight = 368.38) is the most bioactive structure among the curcuminoid chemical compounds that are extracted from the powdered dry rhizome of *Curcuma longa* Linn (*Zingiberaceae*), which is a perennial herb widely cultivated in the tropical region of Asia, especially in India [12, 13]. The medicinal value of curcumin has been well recognized. It has been proven that curcumin has anti-cancer [14], chemo preventive effect [15], antioxidant [16], anti-proliferative [17], immunomodulatory [18], hepatoprotective [19], and anti-inflammatory properties [20]. Furthermore, CUR has shown to inhibit fibrosis; however, the specific mechanism of curcumin bioactivity still remains unclear [21].

In contrast, the sulfonamides are a chemical family of synthetic organic compounds containing the sulfonamide ($-\text{SO}_2\text{NH}_2$) or substituted sulfonamide functional group [22, 23]. There are many recent reports on the biochemical investigation of many sulfonamides as carbonic anhydrase inhibitors [24], antibacterial and antibiofilm [25], antifungal [26], anticancer [27], and anti-inflammatory active agents [28]. Nowadays, many sulfonamide-containing agents are in clinical use, under



different trade names, in different countries. Some examples of these clinically applied agents, mentioned above are, the tyrosine-kinase inhibitor drug [29], anti-inflammatory drug [30], anti-psychotic drug [31], anti-cancer drug [32], anti-inflammatory drug [33], carbonic anhydrase inhibitor drug [34], anti-diabetes [35], antiarrhythmic [36], anti-glaucoma, antidiuretics, antiepileptics [37], sweeten products [38], and the antibiotic [39]. Moreover, the sulfa drug, sulfamethoxazole (SMX), (Fig. 2) is a well-known antibiotic, acting as a bacteriostatic agent against gram-positive and gram-negative bacteria [40]. It, also, has been reported that low-dose of trimethoprim-sulfamethoxazole combination could be a treatment of pneumocystis pneumonia in nonhuman immunodeficiency virus-infected patients, with a low rate of adverse reactions [41].

In this study, we have investigated the effect of each of curcumin (CUR) and sulfamethoxazole (SMX) either separate or together (CUR + SMX) on induced liver fibrosis of carbon tetrachloride (CCl_4), and induced acute liver injury in Swiss albino mice. The study, also, included an investigation of the effects of these, previously mentioned, compounds on biochemical, hematological, and histological alternations associated with carbon tetrachloride (CCl_4)-induced liver fibrosis in mice.

Methods

Chemicals

All reagents and solvents were of high quality and were purchased from commercial sources and were used as received. CCl_4 was purchased from BDH Chemicals, Ltd., Poole, England. CCl_4 was diluted 1:1 with Virgin Olive Oil. SMX, Boric acid powder, and Vanillin were purchased from El-Gomhouria Company for Drugs and Chemicals, Egypt. Dimethyl sulfoxide (DMSO), Ethanol, $\geq 99.8\%$ (GC), n-Butyl amine, 99.5% and Ethyl acetate, $\geq 99.5\%$ (GC) were purchased from Sigma-Aldrich Chemical Co., (St Louis, MO, USA). Acetylacetone (2, 4-

pentanedione), 99+%, Triisopropyl borate, 98+%, were purchased from ACROS ORGANICS, (Geel, Belgium). Hydrochloric acid, 37%, extra pure, and sodium sulfate, anhydrous, 99+%, extra pure were purchased from Fisher Scientific UK. Kits used for the experiments of biochemical studies were purchased from Biodiagnostic Company, Dokki, Giza, Egypt.

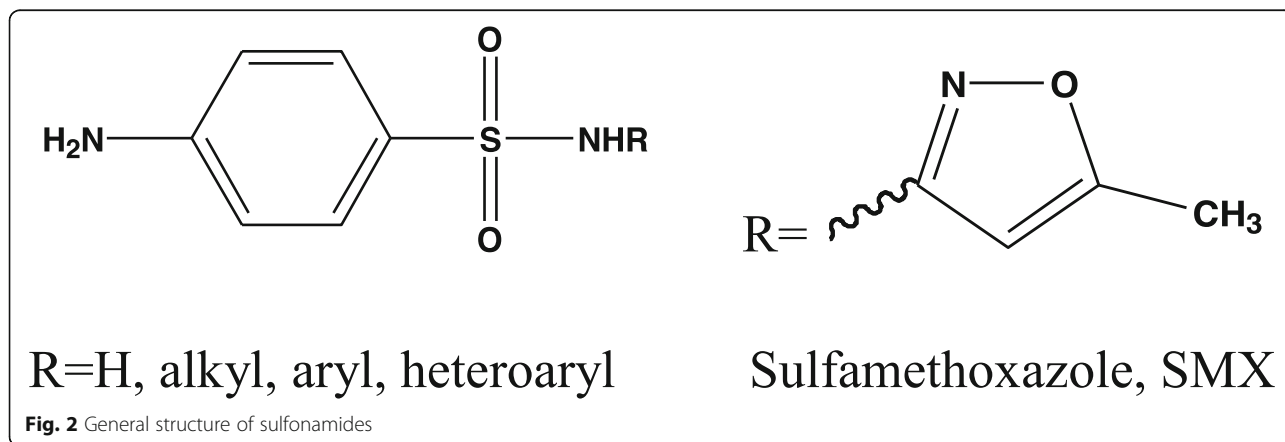
Preparation of curcumin (CUR)

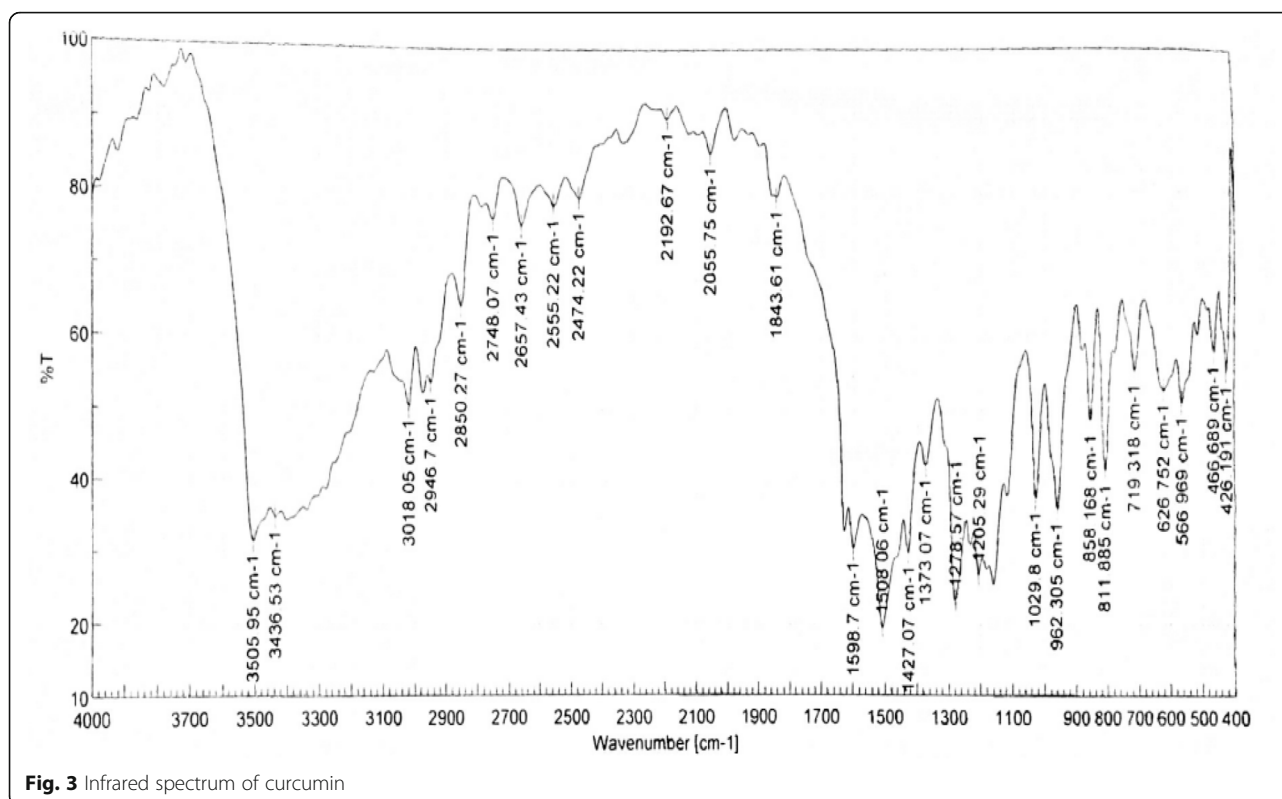
Curcumin, CUR, was prepared according to reported modified methods [42–44].

Analysis of curcumin (CUR)

The melting point (m.p.) of CUR was measured in an open capillary glass tube on a Gallenkamp melting point apparatus (Gallenkamp and CO, UK) and was uncorrected. Infrared (IR) spectrums of CUR was obtained on Perkin Elmer 1430 spectrophotometer with potassium bromide (KBr) disc, in the wavenumber range of 4000–400 cm^{-1} . Its ^1H nuclear magnetic resonance (NMR) (500 MHz, DMSO-d_6) and ^{13}C NMR (125 MHz, DMSO-d_6) spectra were determined on JEOL's NMR spectrometer (500 MHz, Japan), using DMSO-d_6 as solvent. Chemical shifts are expressed as δ values (ppm), using tetramethylsilane (TMS) as an internal standard. The following abbreviations were used to indicate the NMR-signals: s (singlet), d (doublet), and br (broad). Electron impact (EI) mass spectral (MS) analysis at 70 eV of curcumin was performed on Thermo Scientific Trace DSQ II GC-MS (50–400 m/z), (Waltham, MA) system.

Measuring the melting point and the IR analysis of curcumin were performed at the Chemistry Department, Faculty of Science, Egypt, while its ^1H and ^{13}C NMR and MS spectral analysis were performed at the Spectral Analysis Unit, Chemistry Department, Faculty of Science, Egypt.





Curcumin (1, 7-bis (4-hydroxy-3-methoxyphenyl) hepta-1, 6-diene-3,5-dione) (Fig. 1)

It was obtained as a yellow-orange crystalline solid; m.p. 180–181 °C; IR (KBR, cm⁻¹) (Fig. 3): 3505.95, 3436.53 (OH, H-bonded), 3018.05 (C–H aromatic stretching vibration), 2946.70, 2850.27 (CH₂ and CH₃ asymmetric stretching), 1643.61 (C=O), 1598.70 (C=C conjugated with C=O), 1508.06 (benzene ring), 1427.07 (enol C–O), 1373.07 (CH₃ bending), 1278.57 (Phenolic C–O), 1029.80 (C–O–C in OCH₃), 858.17, 811.89 (two adjacent aromatic C–H), 719.32 (C–H vibration aromatic); ¹H NMR (DMSO-d₆, 500MHz) (Fig. 4): δ (ppm) = 2.11(s, 2H, H-1, keto-form), 6.05 (s, 1H, H-1, enol-form), 6.75(d, 2H, H-3, H-3'), 7.53 (d, 2H, H-4, H-4'), 7.31(d, 2H, H-6, H-6'), 9.68(s, br, 2H, Ar-OH), 6.80 (d, 2H, H-9, H-9'), 7.13(dd, 2H, H-10, H-10'), 3.83(s, 6H, OCH₃); ¹³C NMR (DMSO-d₆, 125MHz) (Fig. 5): δ (ppm) = 100.93 (C-1), 183.25(C-1, C-1'), 121.11 (C-3, C-3'), 140.77(C-4, C-4'), 126.37 (C-5, C-5'), 111.31(C-6, C-6'), 148.02 (C-7, C-7'), 149.37 (C-8, C-8'), 115.73(C-9, C-9'), 123.19(C-10, C-10'), 55.71(OCH₃); MS: m/z = 368 (0.92%)

Ethics approval and consent to participate

All animal experiments conformed to the British Home Office Regulations (Animal Scientific Procedures Act 1986) and associated guidelines, EU Directive 2010/63/

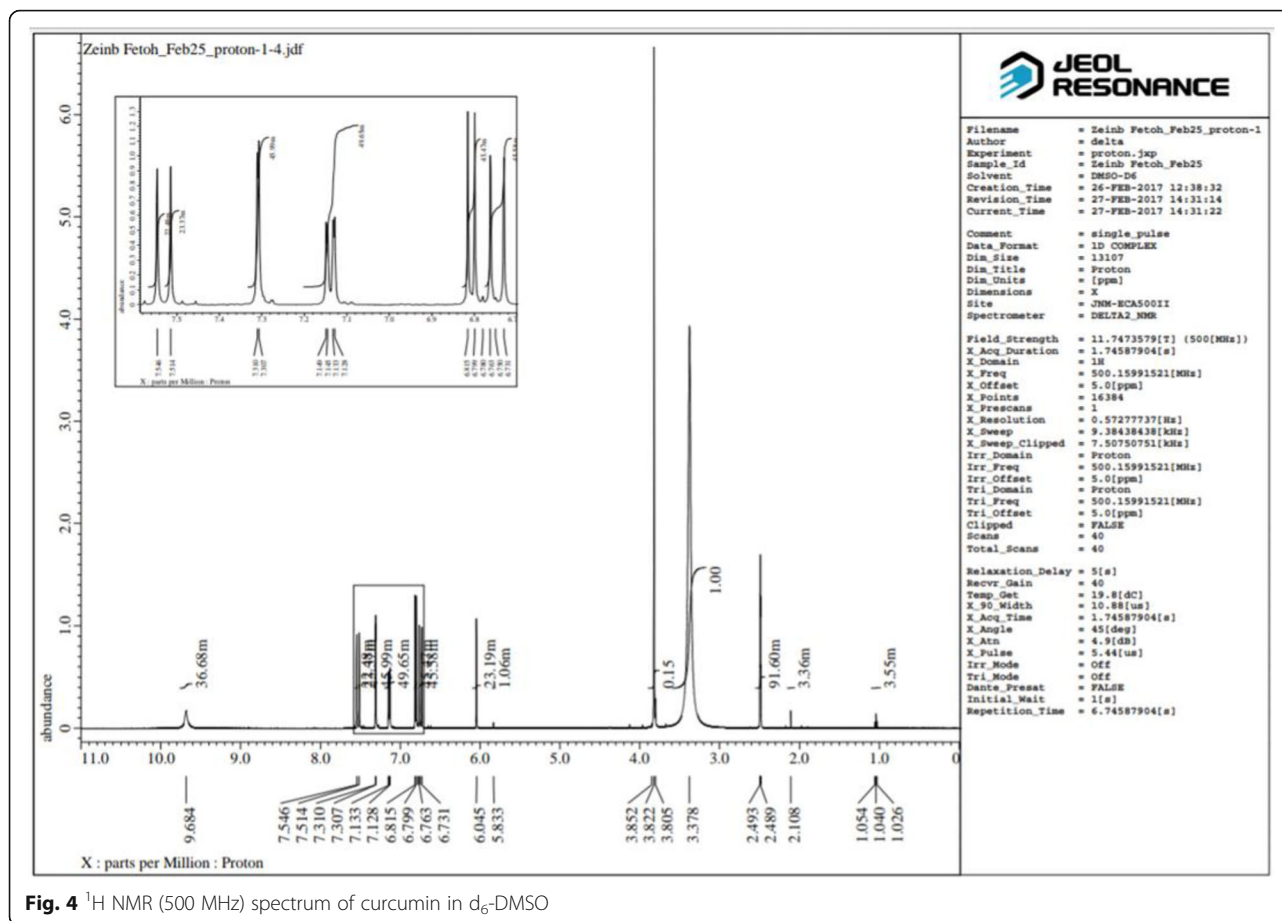
EU for animal experiments. This work launched after attaining permission from the scientific and ethical committees of Faculty of Science.

Experimental animals

Adult male Swiss albino mice (total number, *n* = 180) were purchased from Zoology Department, Faculty of Science, Egypt, with average weight (25–30 gm each) and housed at the experimental animal house of the Faculty of Science. The animals were maintained in a properly controlled environment of temperature, humidity, and light. The mice were fed with autoclaved chow and filtered water and were adapted for a week prior to experimentation.

Experimental design

The Swiss male adult albino mice were divided into nine (I–IX) groups (20 mice/each) as shown in Table 1. At the end of the experiment, mice fasted for 12 h and then blood samples were taken from the heart puncture under light ether anesthesia. Blood samples were collected for biochemical and hematological analysis. Animals were sacrificed and the liver dissected out and washed with isotonic saline and divided into two parts, the first part was stored at – 20 °C until assay for estimation of antioxidant parameters. The second part of



the liver tissue was fixed in (10%) formalin for histopathology assessment.

Biochemical analysis

Estimation of nitric oxide (NO) level was determined in liver tissues by using Biodiagnostic kit, Egypt (cat. no. NO2533), according to the method of Montgomery and Dymock [48]. Glutathione reductase (GSSG) was determined by using Biodiagnostic kit, Egypt (cat. no. GR2523), according to the method of Goldberg and Spooner [49]. The serum samples were collected for liver function tests. The activities of aspartate transaminase (AST) and alanine transaminase (ALT) were estimated by using Biodiagnostic kits, Egypt (cat. no. AS1061 (45), cat. no. AL1031 (45), according to the method of Reitman and Frankel [50]. Serum total protein and albumin concentrations were estimated by using Biodiagnostic kits, Egypt (CAT.NO. TP2020, cat. no. AB1010), according to the method of Gornall et al. [51] and Dumas et al. [52]. Moreover, plasma samples were collected for antioxidant assays. Estimation of superoxide dismutase (SOD) activity was assayed according to the method of Nishikimi et al. [53]. Glutathione reduced (GSH) was estimated by using a commercial kit (Biodiagnostic

Company, Dokki, Giza, Egypt), according to the method of Beutler et al. [54]. Total antioxidant activity (TAO) carried out according to the method of koracevic et al. [55]. Malondialdehyde (MDA) level was assayed using Biodiagnostic kit, Egypt (cat. no. MD2529), according to the method of Satoh [56] and Rubio et al. [57].

Hematological analysis

Complete blood count (CBC)

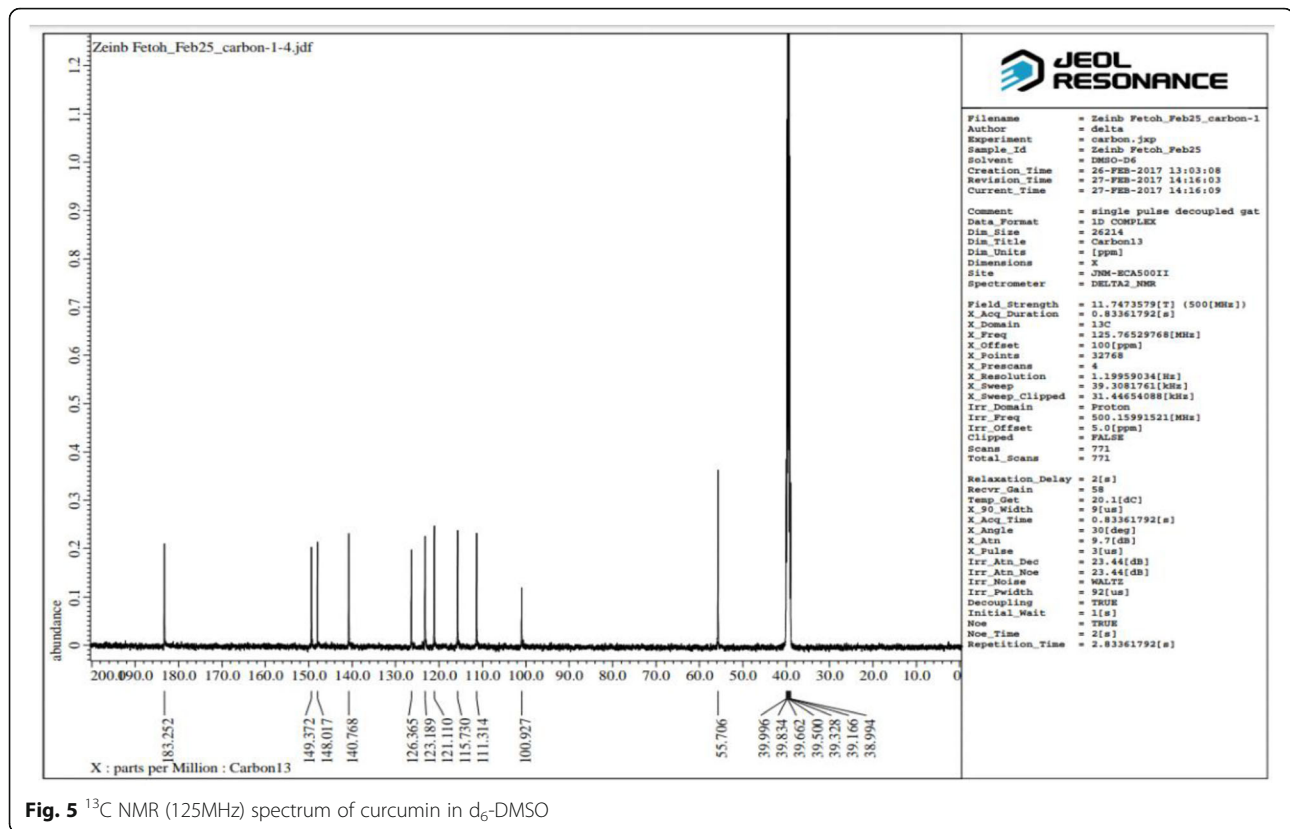
A portion of retro-orbital blood samples was collected from each animal used for a complete blood count. Blood cell counts (white blood cells, red blood cells, and platelets) were performed with HORIBA Hematology analyzer (model: MICROS 60 OT) (France).

Sodium dodecyl sulphate polyacrylamide gel electrophoresis (SDS-PAGE)

Protein fractionation was done by using one-dimensional polyacrylamide gel electrophoresis according to the method of Leammli [58].

Sample preparation

One gram of each sample (liver tissue) was ground in 1 ml homogenate buffer (0.02 M Tris-HCl pH ~ 7.5) using



a mortar. The content was transferred to a new Eppendorf tube, centrifuged at 10000 rpm for 10 min at 4 °C, and then the supernatant was kept frozen at – 20°C until required. Protein samples were denatured by boiling in a water bath for 5 min with SDS sample buffer. Then, they

were loaded into the wells of gel which was composed of 5% stacking gel and 12% polyacrylamide separating gel next to the molecular weight marker protein. The separated protein on the polyacrylamide gel was stained with Coomassie blue R-250 Andrews [59]. After that, the gel

Table 1 Experimental design

Groups	Dose	Method of section	Duration
Group I negative control	0.5 ml olive oil/kg b.w.	i.p	3 times a week for 5 weeks
Group II DMSO control	(0.2%) DMSO	i.p	3 times a week for 4 weeks
Group III CCl_4 control	1 ml (50% in olive oil)/kg b.w.	i.p	3 times a week for 5 weeks
Group IV CUR group	CCl_4 as group III followed by CUR 100 mg/kg b.w. in olive oil [45, 46]	CCl_4 i.p CUR orally through a gastric tube	CCl_4 3 times a week for 5 weeks then 4 times a week for 4 weeks
Group V CUR control	100 mg/kg b.w. in olive oil [45, 46]	orally through a gastric tube	4 times a week for 4 weeks
Group VI SMX Group	CCl_4 as group III followed by 15 mg SMX/kg b.w. in DMSO [47]	i.p	CCl_4 3 times a week for 5 weeks then 4 times a week for 4 weeks
Group VII SMX control	15 mg SMX/kg b.w. in DMSO [47]	i.p	4 times a week for 4 weeks
Group VIII Combination (CUR + SMX) group	CCl_4 as group III followed by CUR as group V and SMX as group VII	CCl_4 and SMX i.p CUR orally through a gastric tube.	CCl_4 3 times a week for 5 weeks then 4 times a week for 4 weeks
Group IX Combination (CUR. + SMX.) control	CUR as group V and SMX as group VII	CUR orally through a gastric tube. SMX i.p	4 times a week for 4 weeks

CCl_4 carbon tetrachloride, CUR curcumin, SMX sulfamethoxazole, i.p intraperitoneally

was removed from the destaining solution, placed between two transparent sheets, and was left to air dry. Then, the gel was scanned and analyzed by the Gel-Pro Analyzer program <http://meyerinst.com/imaging-software/image-pro/gel/index.htm> (Media cybernetics, Georgia, USA).

Histopathological examinations

Mouse liver tissues were fixed in 10% neutral formalin, then dehydrated, and further embedded with paraffin. Paraffin-embedded liver samples were sectioned to 3- μ m-thin slices, which were stained with hematoxylin-eosin (HE) staining and Masson staining according to standard protocols of Oner-lyidogan et al. [60].

Statistical analysis

Data were evaluated by one-way analysis of variance (ANOVA) by "SPSS" 14.0 for Microsoft Windows, SPSS Inc. and considered statistically significant at a two-sided $p < 0.05$. Numerical data were expressed as mean \pm SD.

Results

Characterization of curcumin

The melting point of curcumin

The prepared curcumin was crystallized from absolute ethanol as a yellow-orange crystalline solid, melting at 180–181 °C which is effective concur with the literature (m.p = 181–182 °C, [42, 61]; and m.p = 178–182 °C, [62]).

Infrared spectroscopy (IR) of curcumin

The IR spectrum of curcumin is shown in Fig. 3 along with its data and assignments, which are effective and concur with the literature [42, 63–68].

Nuclear magnetic resonance spectroscopy of curcumin

The ^1H and ^{13}C NMR spectra of curcumin are shown in Figs. 4 and 5, respectively. The NMR data of curcumin, whose interpretation confirmed its structure and its effectiveness, concurring with the literature [42, 64, 67, 68].

Mass spectrometry (MS) of curcumin

The MS analysis has confirmed the structure of curcumin, showing its molecular ion peak at $m/z = 368$ with a relative intensity of 0.92%.

Curcumin and sulfamethoxazole relieved CCl_4 -induced on antioxidants in Swiss mice

The mean value of MDA and NO levels were 58.051 ± 0.92 nmol/ml and 40.07 ± 0.71 μ mol/l, respectively in a group (I, Table 1). The CCl_4 -positive control group (III, Table 1) showed a significant increase in MDA and NO levels to be 88.83 ± 0.70 nmol/ml and 77.08 ± 0.57 μ mol/l, respectively, ($p < 0.001$) compared to the control group (I, Table 1). Their levels demonstrated a

significant decrease in curcumin (IV, Table 1), sulfamethoxazole (VI, Table 1), and their combination group (VIII, Table 1) compared to the CCl_4 -positive control group (III, Table 1) as shown in Fig. 6a, b. On the other hand, SOD, GSH, GSSG, and TAO activities were decreased ($p < 0.001$) from 157.35 ± 0.75 U/ml, 9.3 ± 0.54 mg/dl, 9.9 ± 0.24 U/L, and 0.18 ± 0.022 mmol/L in the negative control group (I, Table 1) to 58.97 ± 0.65 , 2.4 ± 0.54 , 1.6 ± 0.26 , 0.064 ± 0.011 , respectively in CCl_4 control group (III, Table 1). While their concentration was significantly increased in the curcumin group (IV, Table 1), sulfamethoxazole group (VI, Table 1) and highly increased in the combination group (VIII, Table 1) compared to the CCl_4 -positive control group as shown in Fig. 6c–f, respectively.

Curcumin and sulfamethoxazole relieved CCl_4 -induced on liver enzymes in Swiss mice

Measurement of liver enzyme activities demonstrated a significant increase in ALT and AST activities in CCl_4 -positive control group (III, Table 1) to 78.37 ± 4.3 and 130.14 ± 5.0 U/L; respectively, in comparison to the negative control group (I, Table 1) ($p < 0.001$). These high activities of liver enzymes were significantly reduced by curcumin (IV, Table 1), sulfamethoxazole (VI, Table 1), and their combination (VIII, Table 1) in comparison with CCl_4 -positive control group (III, Table 1), ($p < 0.001$) as in Fig. 7a, b. Also, measurement of total protein and albumin concentration demonstrated a significant decrease in CCl_4 -positive control group (III, Table 1) to 6.69 ± 0.24 and 3.17 ± 0.28 g/dl, ($p < 0.001$) in comparison with a negative control group (I, Table 1). These concentrations were significantly increased to 10.48 ± 0.83 and 4.79 ± 0.17 , respectively in ($\text{CCl}_4 + \text{CUR}$) group (IV, Table 1), to 10.42 ± 0.41 and 4.50 ± 0.37 in ($\text{CCl}_4 + \text{SMX}$) group (VI, Table 1) and to 10.63 ± 0.36 and 5.03 ± 0.15 , in ($\text{CCl}_4 + \text{CUR} + \text{SMX}$) group (VIII, Table 1), respectively, compared to CCl_4 -positive control group (III, Table 1), ($p < 0.001$) as in Fig. 7c, d.

Curcumin and sulfamethoxazole relieved CCl_4 -induced on hematological changes in Swiss mice

Red blood cells (RBCs) count, hematocrit (HCT) value, platelets (PLT) count, and hemoglobin (HGB) concentration were significantly decreased to $6.25 \pm 0.29 \times 10^6/\text{mm}^3$ ($p < 0.05$), $27.30 \pm 1.27\%$, $523.85 \pm 22.57 \times 10^3/\text{mm}^3$, and 9.44 ± 0.51 g/dl ($p < 0.001$), respectively. While white blood cells (WBCs) count was significantly increased to $21.02 \pm 2.0 \times 10^3/\text{mm}^3$ ($p < 0.001$) in the control CCl_4 -positive control group (III, Table 1) in comparison with the negative control group (I, Table 1). RBCs count, HGB concentration, HCT value, PLT count, and HGB concentration were significantly increased in curcumin group, sulfamethoxazole group, and

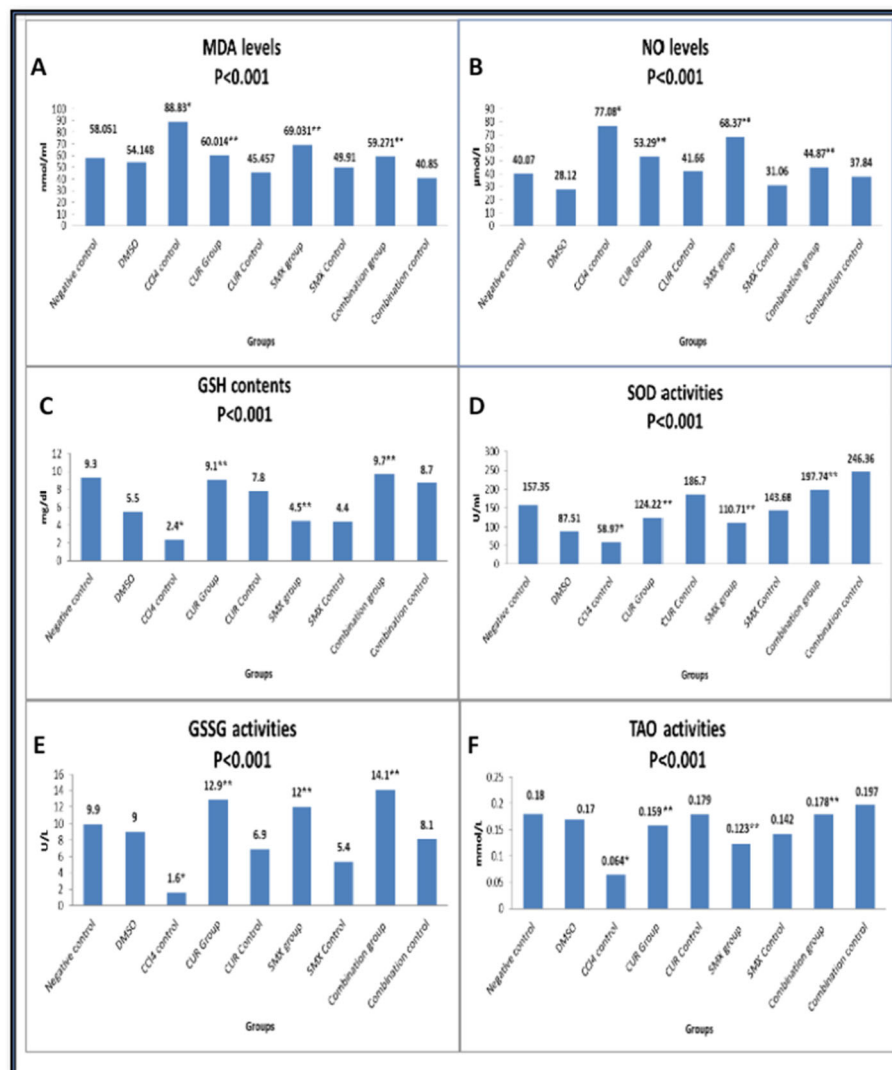


Fig. 6 Effect of curcumin and sulfamethoxazole on antioxidants in all studied groups. **a** MDA levels, **b** O levels, **c** GSH contents, **d** SOD activities, **e** GSSG activities, and **f** TAO activities. Results were expressed as mean. (*) Compared with normal control, (**) Compared with CCl₄ control showed a highly significant difference from control value at ($p < 0.001$)

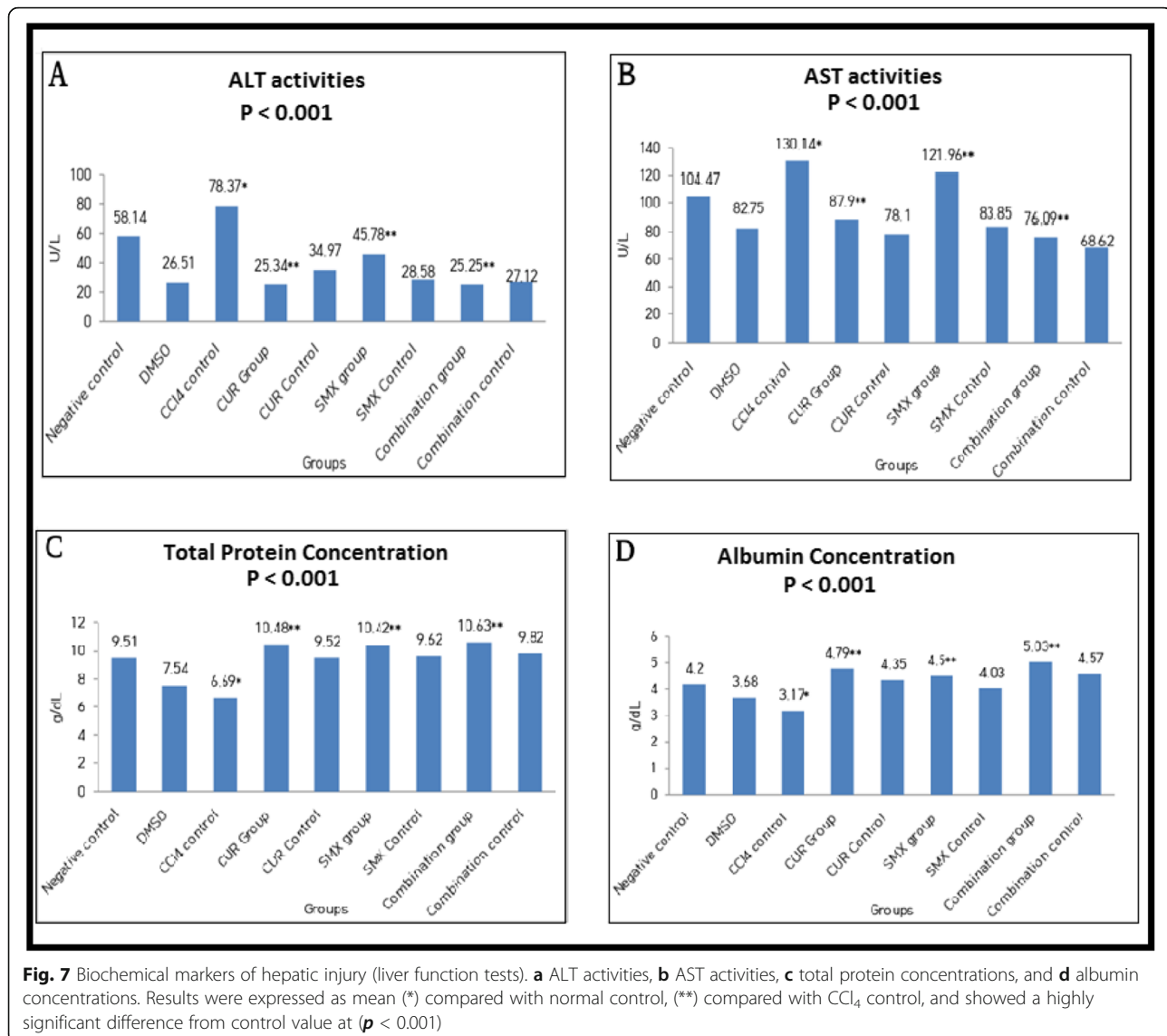
in combination CUR + SMX group, while WBCs count was significantly decreased in curcumin group (IV, Table 1), sulfamethoxazole group (VI, Table 1), and in combination CUR + SMX group (VIII, Table 1) in comparison with CCl₄-positive control group (III, Table 1) as in Fig. 8a–d.

Sodium dodecyl sulphate polyacrylamide gel electrophoresis (SDS-PAGE) on liver tissue of Swiss mice

The electrophotography showed that the protein band, especially at M.wt nearly 53 KDa, in CCl₄-positive control group (lane-1) completely disappeared in the normal control group (lane-9), DMSO control group (lane-5), curcumin control group (lane-8), sulfamethoxazole control group (lane-7), and combination (curcumin + sulfamethoxazole) control group

(lane-6). However, the band partially disappeared in the curcumin group (lane-4), sulfamethoxazole group (lane-2), and combination (curcumin + sulfamethoxazole) group (lane-3) as in Fig. 9.

The gel pro analysis demonstrated that six bands in CCl₄-positive control group, three bands in normal control group, three bands in DMSO control group, three bands in sulfamethoxazole control group, three bands in curcumin control group, three bands in combination (curcumin + sulfamethoxazole) control group, four bands in curcumin group, five bands in sulfamethoxazole group, and four bands in combination (curcumin + sulfamethoxazole) group with molecular weight approximately ranged from 11 to 75 KDa as in Fig. 10a–i



Histopathological studies

The histological examination of liver tissues in all studied groups confirmed the biochemical study in all different groups (Fig. 11). The histological examination of the control mice group (negative control) (I, Table 1) showed, the normal hepatocytes around the portal area (arrowhead), H&E, $\times 200$, (Fig. 11a). The DMSO group (II, Table 1) showed normal liver structures, H&E, $\times 200$, (Fig. 11b). However, the CCl₄ group (III, Table 1) had degenerative changes with an increase number of fibroblasts and fibrosis, H&E X400, (Fig. 11c). Meanwhile, the curcumin-treated group (IV, Table 1) showed cell swelling of hepatocytes within the centrilobular area (arrow) besides a moderate degree of vacuolation of hepatocytes within the periportal area, H&E, $\times 200$, (Fig. 11d). While the curcumin control group (V, Table 1) showed normal liver structures, H&E, $\times 200$, (Fig. 11e). the sulfamethoxazole treated group (VI, Table 1) showed cloudy swelling,

vacuolar degeneration of hepatocytes, and mononuclear cells infiltration, H&E, $\times 200$ (Fig. 11f), while the sulfamethoxazole control group (VII, Table 1) showed normal liver structures, H&E, $\times 200$, (Fig. 11g). The combined CUR + SMX group (VIII, Table 1) showed cell swelling and mild vacuolization of hepatocytes, H&E, $\times 200$, (Fig. 11h), while, the combined CUR + SMX control group (IX, Table 1) showed normal liver structures, H&E, $\times 200$, (Fig. 11i).

Discussion

Curcumin (CUR) is a widely examined natural compound that has demonstrated imposing in vitro therapeutic potential. Disregarding the way that the experimental efficacy of natural curcumin is frail due to its low bioavailability and high metabolism in the gastrointestinal tract because of its poor solubility in water and quick in liver and intestinal digestion which add to

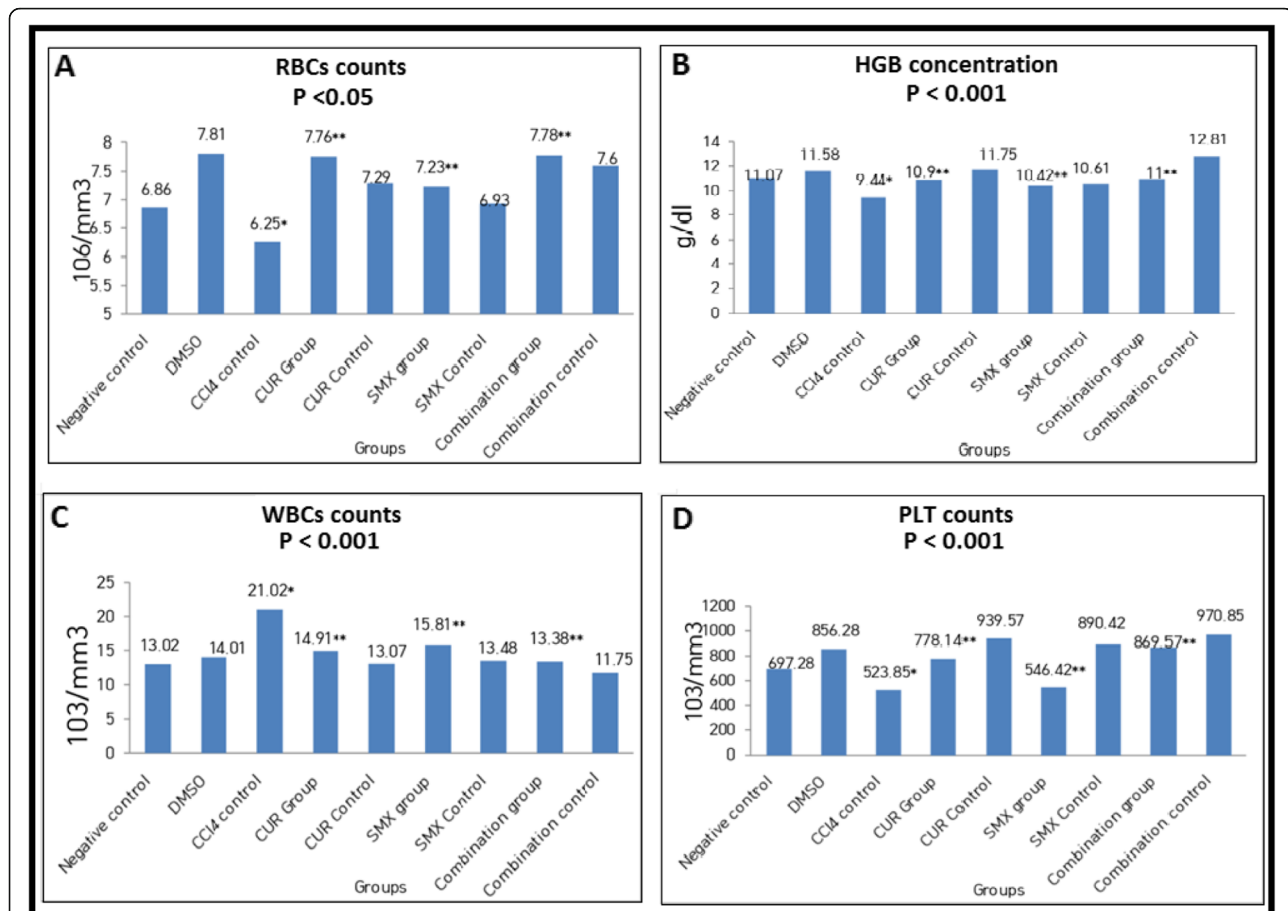


Fig. 8 Effect of curcumin and sulfamethoxazole on hematological changes in all studied groups. **a** RBCs counts, **b** HGB concentrations, **c** WBCs counts, **d** PLT counts. Results were expressed as mean (*) compared with normal control, (**) compared with CCl₄ control, and showed a highly significant difference from control value at ($p < 0.001$) except for RBCs which was at ($p < 0.05$)

its fast excretion, researchers have focused on ameliorative bioavailability in the most recent decade [69, 70]. Sulfonamides are the central and historically most prominent class of carbonic anhydrase inhibitors, being discovered in 1940, with many representatives in clinical use for decades [71]. Thus, we used sulfamethoxazole with curcumin in combination group (VIII, Table 1) to circumvent the problem of rapid metabolism and to improve its pharmacokinetics profile. The purpose of this study is to investigate the effect of each of curcumin (CUR) and sulfamethoxazole (SMX) either separate or together (CUR + SMX) on biochemical, hematological, and histological alternations associated with carbon tetrachloride (CCl₄)-induced liver fibrosis in mice, and to explain the underlying mechanism. The CCl₄ is a causative agent of numerous disarranges through its capability of causing oxidative stress and inflammation. CCl₄ uses, through enzymes of the CYP 450 system, producing hepatotoxic metabolites for example, trichloromethyl radicals and trichloroperoxy radicals. These metabolites cause hepatotoxicity through induction of

lipid peroxidation that all together gives malondialdehyde (MDA) products that lead to hepatic injury [72]. According to our present data, CCl₄ caused changes of several biomarkers which proved its hepatotoxic effects such as an increase in aminotransferases liver enzymes (ALT, AST), MDA, and NO, with a decrease in SOD, GSSG, TAO, GSH, total protein, and albumin compared to the negative control group (I, Table 1).

Oxidative stress is the most widely recognized instrument in organ injury. Oxygen is the primary particle for all cells for the creation of ATP, but it might, likewise can change into harmful species, for example reactive oxygen species. During aerobic respiration, the creation of free radicals could bring about aging and cell death. Oxygen molecules are reduced by mitochondria to create superoxide ions or hydrogen peroxide (H₂O₂). The superoxide and peroxide further respond with metal ions and produce hydroxyl radicals, which react with cell components including DNA and proteins. Polyphenolic curcumin is essentially appended to its antioxidant properties. CUR is seen as ten times more

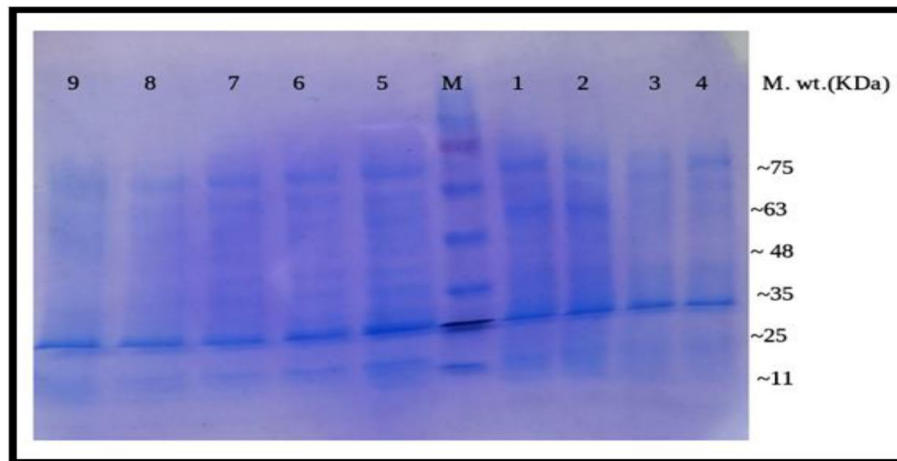
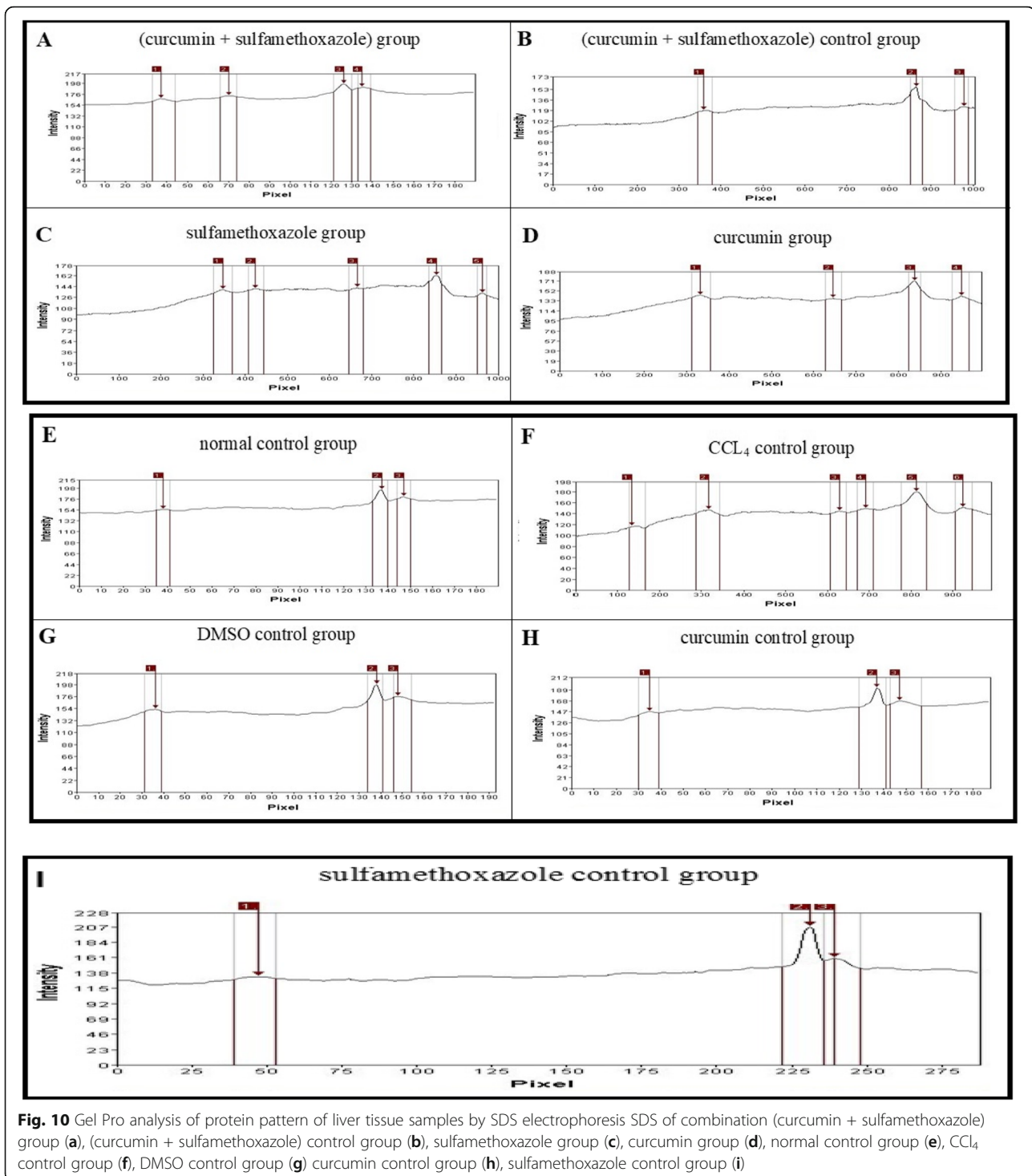


Fig. 9 SDS-Polyacrylamide gel of protein pattern of liver tissue samples. M = Marker 11–75 KDa, lanes 1–9: groups 1–9. Lane 1 represents the electrophoretic pattern of CCl_4 group, lane 2 represents the electrophoretic pattern of sulfamethoxazole group, lane 3 represents the electrophoretic pattern of combination (curcumin + sulfamethoxazole) group, lane 4 represents the electrophoretic pattern of curcumin group, lane 5 represents the electrophoretic pattern of the DMSO control group, lane 6 represent the electrophoretic pattern of combination (curcumin + sulfamethoxazole) control group, lane 7 represents the electrophoretic pattern of sulfamethoxazole control group, lane 8 represents the electrophoretic pattern of curcumin control group, and lane 9 represent the electrophoretic pattern of the normal control group.

antioxidants than vitamin E [73]. CUR causes an increase in GSH concentration and activity of glutathione peroxidase and SOD. The glutathione and glutathione peroxidase act synergistically to scavenge free radicals. SOD scavenges superoxide radicals by changing over superoxide free radicals into H_2O_2 while staying away from the development of hydroxyl radicals. Thus, the H_2O_2 formed is expelled by the job of catalase or glutathione peroxidase. In this manner, SOD protects against free radical damage [74]. CUR has antioxidant properties that protect against CCl_4 -induced hepatic damage. It can repair all biomarkers against hepatic damage, i.e., decreasing level of ALT and AST, suppressing lipid peroxidation, decreasing MDA level, recovery of redox balance, and increasing level of reduced GSH [75].

Our results revealed that curcumin-treated group (IV, Table 1) had an increase in SOD, GSSG, TAO, GSH, total protein, and albumin, while it had a decrease in ALT, AST, MDA, and NO in comparison to CCl_4 group (III, Table 1) which agreed with Zhao et al. [76], who reported that there was an increase in serum biomarkers of ALT, AST, and a decrease in the levels of albumin and the total protein, after treatment with CUR [76]. Indicators in liver disease, ALT and AST are hepatocyte cytosolic enzymes. An increase in levels of ALT and AST usually confirm liver injury. Albumin and total protein levels tend to be reduced in chronic liver injury because of the impaired ability of liver cells to synthesize proteins [76, 77]. Peng et al. [78] showed that curcumin pre-treatment at the doses of 50, 100, and 200 mg/kg markedly alleviated the expansion of MDA level brought

about by CCl_4 and it can up-manage the activities of SOD and levels of GSH. Momeni and Eskandari [79] showed that the use of curcumin alone significantly increased the total antioxidant capacity of serum in comparison with the control. Its direct antioxidant activity, CUR may enhance the synthesis of glutathione and improve the antioxidant defense system, a significant increase in the serum concentration of MDA. Curcumin affected the levels of peripheral blood parameters through increasing HGB, RBCs, PLT, and decreasing WBCs, which agreed with the results of Yin et al. [80]; however, the combination between CUR and SMX group (VIII, Table 1) had a significant increase in HGB, RBCs, and PLT and a significant decrease in WBCs, so the combination was more effective than curcumin alone. Sulfamethoxazole-treated group (VI, Table 1) caused an increase in SOD, GSSG, GSH, total protein, and albumin but caused a decreased in ALT, AST, MDA, and NO compared to the CCl_4 group (III, Table 1) which was in agreement with Sahyon et al. [47]. Gupta et al. [81] reported that (sulfamethoxazole + selenium) treatment resulted in an increase in the activities of SOD, but caused a decrease ($p < 0.001$) in the levels of GSH when compared to diethylnitrosamine-treated animals and showed an increase in the levels of MDA. Also, Bottari et al. [40] reported that the treatments with SMX + trimethoprim, resveratrol, and inclusion complex in free forms or co-administered were able to reduce the total oxidation status and oxidation protein products levels in hepatic tissue of infected animals. In comparison, our results showed that curcumin and sulfamethoxazole combination have significantly, decreased MDA



and NO levels, and increased SOD, GSSG, TAO, and GSH levels compared to the corresponding levels of the CCl₄ control group.

The present data demonstrated an increase in protein synthesis in the CCl₄ group with a corresponding decrease in the curcumin and/or sulfamethoxazole treated groups. This agreed with Thaloor et al. [82],

who reported that the synthesis of proteins (including 60, 36, and 30.7 kDa proteins) was inhibited in the presence of 25 μ M of curcumin. In a comparable study, Qin et al. [83] showed that the protein levels were significantly decreased in the CUR-treated groups. This, again, is in concurrence with our results.

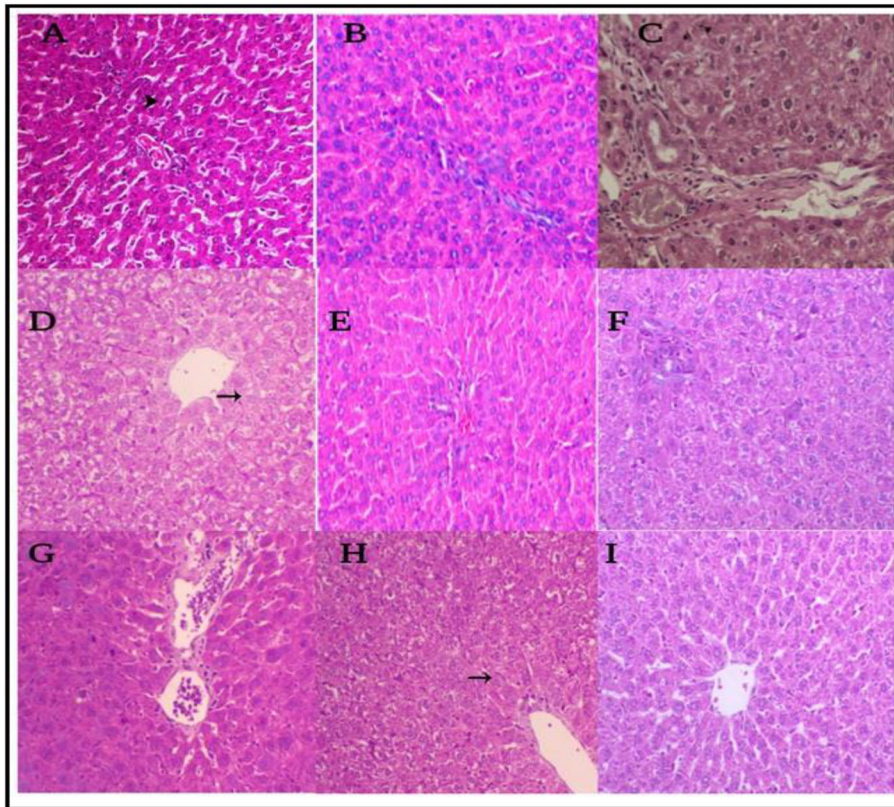


Fig. 11 A photomicrograph of the effects of CUR and SMX on CCl_4 -induced liver fibrosis in Swiss mice, H&E, $\times 200,400$. **a** Normal hepatocytes around the portal area. **b** Normal liver structures. **c** Degenerative changes with an increased number of fibroblast and fibrosis. **d** Swelling of hepatocytes within the centrilobular area (arrow) in addition to a moderate degree of vacuolization of hepatocytes within the periportal area. **e** Normal liver structure. **f** Cloudy swelling and vacuolar degeneration of hepatocytes and mononuclear cells infiltration. **g** Normal liver structure. **h** Swelling and mild vacuolation of hepatocytes. **i** Normal liver structure

The histological examination of liver tissues showed that the liver of the control mice exhibited normal lobular architecture around the portal area. Treatment with CCl_4 alone caused an increased number of fibroblasts and fibrosis. This agreed with Ahmad et al. [84] who reported that CCl_4 treated group showed heavy cell infiltration, across the board vacuolated cytoplasm, darkly stained pyknotic and peripheral placed nuclei. Our results, also, agreed with Zhaoa et al. [21] which showed that the liver in CCl_4 treated mice have a large number of hepatocytes necrosis, leukocytes infiltration, and damaged lobule structure and the liver in CUR treated mice have reduce leukocytes infiltration and reduced hepatocytes necrosis compared to the mice of the CCl_4 -positive control group, which agreed with our CUR treated group and showed cell swelling of hepatocytes within the centrilobular area (arrow), in addition to moderate degree of vacuolation of hepatocytes within the periportal area. The liver of the mice, in the curcumin and sulfamethoxazole combination group (CUR + SMX), showed cell swelling and mild vacuolation of hepatocytes. While the mice group that was treated with

sulfamethoxazole (SMX) alone showed cloudy swelling, vacuolar degeneration of hepatocytes, and mononuclear cells infiltration. The above-mentioned results, clearly demonstrated the highly significant effect of curcumin and/or sulfamethoxazole against the harmful effect of CCl_4 in dealing with Swiss mice group. However, further studies with different dosages and/or concentrations of curcumin and sulfamethoxazole will be done.

Conclusions

Treatment with curcumin and sulfamethoxazole either separately or together can reduce CCl_4 hepatotoxicity in mice. Each of curcumin and sulfamethoxazole could be considered a promising candidate in the prevention and treatment of liver fibrosis.

Abbreviations

ALT: Alanine transaminase; AST: Aspartate transaminase; br: Broad; CCl_4 : Carbon tetrachloride; CUR: Curcumin; DMSO: Dimethyl sulfoxide; d: Doublet; EI: Electron impact; ECM: Extracellular matrix; GSSG: Glutathione reductase; HCT: Hematocrit value; HE: Hematoxylin-eosin; HGB: Hemoglobin concentration; HSC: Hepatic stellate cells; IR: Infrared; MDA: Malondialdehyde; MS: Mass spectral; NO: Nitric oxide; NMR: Nuclear magnetic resonance; PLT: Platelets count; KBr: Potassium bromide; RBCs: Red blood cells count;

GSH: Reduced glutathione; s: Single; SDS-PAGE: Sodium dodecyl sulphate polyacrylamide gel electrophoresis; SMX: Sulfamethoxazole; SOD: Superoxide dismutase; TMS: Tetramethylsilane; m.p.: The melting point; TAO: Total antioxidant activity

Acknowledgments

We would like to thank Amira Ragheb, CT, ASCP for her effort in editing the final paper.

Authors' contributions

R.Z, Z.G, and M.M conceived and designed experiments; R.Z, Z.B, A.T, and M.M contributed to the analysis and/or interpretation of data. R.Z and Z.G drafted the manuscript and R.Z, Z.G, M.M, and A.T revised it critically for important intellectual content. All authors have read the manuscript and approved the submission.

Funding

This research did not receive any specific grant from funding agencies in the public, commercial, or not-for-profit sectors.

Availability of data and materials

Authors declare that all generated and analyzed data are included in the article.

Ethics approval and consent to participate

All animal experiments conformed to the British Home Office Regulations (Animal Scientific Procedures Act 1986) and associated guidelines, EU Directive 2010/63/EU for animal experiments.

The Experimental research on mice approved by the international recommendations for the care and use of animals, and both maintenance and feeding were similar for all animals and remained in accordance with proper animal welfare guidelines for the care and use of mice. This work launched after attaining a permission of scientific and ethical committees from Damietta University, research approval code is 3.2.3.3. Biochemical studies on liver diseases.

Ethics committee reference numbers

Research approval code is 3.2.3.3. Biochemical studies on liver diseases and this is the available in our university.

Consent for publication

Not applicable

Competing interests

The authors declare that they have no competing interests.

Author details

¹Department of Chemistry (Biochemistry division), Faculty of Science, Damietta University, New Damietta, Egypt. ²Department of Microbial Biotechnology, Division of Genetic Engineering and Biotechnology, National Research Centre, Cairo 12622, Egypt. ³Department of Chemistry, Faculty of Science, Damietta University, New Damietta, Egypt.

Received: 19 January 2020 Accepted: 30 March 2020

Published online: 04 May 2020

References

1. Adewusi EA, Afolayan AJ (2010) A review of natural products with hepatoprotective activity. *J Med Plants Res* 4(13):1318–1334
2. Wang FS, Fan JG, Zhang Z, Gao B, Wang HY (2014) The global burden of liver disease: the major impact of China. *Hepatology* 60:2099–2108
3. Gines P, Cardenas A, Arroyo V, Rodes J (2004) Management of cirrhosis and ascites. *N Engl J Med* 350(16):1646–1654
4. Friedman SL (2003a) Liver fibrosis from bench to bedside. *J Hepatol* 38:38–53
5. Wells RG (2006) Mechanisms of liver fibrosis: new insights into an old problem. *Drug Disco Today Dis Mech* 3(4):489–495
6. Friedman SL (2000b) Molecular regulation of hepatic fibrosis, an integrated cellular response to tissue injury. *J Biol Chem* 275(4):2247–2250
7. Scholten D, Trebicka J, Liedtke C, Weiskirchen R (2015) The carbon tetrachloride model in mice. *Lab Anim* 49(1):4–11
8. Uehara T, Pogribny I, Rusyn I (2014) The DEN and CCl₄-induced mouse model of fibrosis and inflammation-associated hepatocellular carcinoma. *Curr Protoc Pharmacol* 66:14.30.1–14.30.10
9. Juarez FJ, Vazquez MLR, Sanchez ARR, Martínez MC, Ortiz GG, Llamas J, Posadas FA, Reyes JL (2008) Acute renal failure induced by carbon tetrachloride in rats with hepatic cirrhosis. *Ann Hepatol* 7(4):331–338
10. Shaker ME, Zalata KR, Mehal WZ, Shiha GE, Ibrahim TM (2011) Comparison of imatinib, nilotinib, and silymarin in the treatment of carbon tetrachloride-induced hepatic oxidative stress, injury, and fibrosis. *Toxicol App Pharmacol* 252(2):165–175
11. Weber L, Boll M, Stampfl M (2003) Hepatotoxicity and mechanism of action of haloalkanes: carbon tetrachloride as a toxicological model. *Crit Rev Toxicol* 33(2):105–136
12. Teiten M, Dicato M, Diederich M (2014) Hybrid curcumin compounds: a new strategy for cancer treatment. *Molecules* 19(12):20839–20863
13. Aggarwal BB, Sundaram C, Malani N, Ichikawa H (2007) Curcumin: the Indian solid gold. *Adv Exp Med Biol* 595:1–75
14. Tien LH, Soon HY (2018) Anticancer effect of curcumin on breast cancer and stem cells. *Food Sci Hum Wellness* 7(2):134–137
15. Benzer F, Kandemir F, Kucukler S, Comakl S, Caglayan C (2018) Chemoprotective effects of curcumin on doxorubicin-induced nephrotoxicity in wistar rats: by modulating inflammatory cytokines, apoptosis, oxidative stress and oxidative DNA damage. *Arch Physiol Biochem* 124(5):448–457
16. Ameida M, Sampaio G, Basstos D, Villavicencia A (2018) Effect of gamma radiation processing on turmeric: Antioxidant activity and curcumin content. *Radiat Phys Chem* 152:12–16
17. Khwaja S, Fatima K, Hassanain BC, Kour A, Singh A, Luqman S, Sarkar J, Chanda D, Shanker K, Gupta A, Mondhe D, Negi A (2018) Antiproliferative efficacy of curcumin mimics through microtubule destabilization. *Eur J Med Chem* 10:51–61
18. Afolayan F, Erinwusi B, Oyeyemi O (2018) Immunomodulatory activity of curcumin-entrapped poly D,L-lactic-co-glycolic acid nanoparticles in mice. *Integr Med Res* 7(2):168–175
19. Reyes-Gordillo K, Shah R, Lakshman M, Flores-Beltran R, Muriel P (2017) Chapter 49 Hepatoprotective properties of curcumin. *Liver Pathophysiology Therapies and Antioxidants*:687–704
20. Sun J, Chen F, Braun C, Zhou Y, Rittner H, Tian Y, Cai X, Ye D-W (2018) Role of curcumin in the management of pathological pain. *Phytomedicine* 48: 129–140
21. Zhao X, Cheng G, Liu Y, Chen Y, Wud H, Xiong Y, Wange G, Jia B, Lie Y, Xie J, Wange J, Yang X, Zhang Z, Huang R, Wu C (2018) Curcumin reduces Ly6Chi monocyte infiltration to protect against liver fibrosis by inhibiting Kupffer cells activation to reduce chemokines secretion. *Biomed Pharmacother* 106:868–878
22. Fier P, Maloney K (2019) NHC-Catalyzed deamination of primary sulfonamides: a platform for late-stage functionalization. *J Am Chem Soc* 141(4):1441–1445
23. Brunton LL, Lazo JS, Parken KL (eds) (2006) Goodman & Gilman's: The pharmacological bases of therapeutics, 11th edn. New York: McGraw-Hill, pp 1111–1119
24. Buğday N, Küçükbay FZ, Küçükbay H, Bua S, Bartolucci G, Leitans J, Kazaks A, Tars K, Supuran CT (2018) Synthesis of novel dipeptide sulfonamide conjugates with effective carbonic anhydrase I, II, IX, and XII inhibitory properties. *Bioorg Chem* 81:311–318
25. Mizdal C, Stefanello S, da Costa FV, Agertt V, Bonez P, Rossi G, da Silva T, FéAlexandre A, de Lourenço ML, de Campos MMA (2018) The antibacterial and anti-biofilm activity of gold-complexed sulfonamides against methicillin-resistant *Staphylococcus aureus*. *Microb Pathogenesis* 123:440–448
26. Kumar K, Vedavathi P, Subbaiah K, Reddy D, Raju C (2017) Design, synthesis, spectral characterization and bioactivity evaluation of new sulfonamide and carbamate derivatives of 5-Nitro-1H-indazole. *Org Commun* 10(3):239–249
27. Okolotowicz K, Dwyera M, Ryana D, Chenga J, Cashmana E, Moorea S, Mercolab M, Cashman J (2018) Novel tertiary sulfonamides as potent anti-cancer agents. *Bioorgan Med Chem* 26:4441–4451
28. Abdel-Maksoud M, El-Gamal M, El-Din M, Choi Y, Choi J, Shin J, Kang S, Yoo K, Lee K, Baek D, Oh C (2018) Synthesis of new triarylpyrazole derivatives possessing terminal sulfonamide moiety and their inhibitory effects on PGE2 and nitric oxide productions in lipopolysaccharide-induced RAW 264.7 macrophages. *Molecules* 23(10):2556

29. Sonpavde G, Hutson TE (2007) Pazopanib: a novel multitargeted tyrosine kinase inhibitor. *Curr Oncol Rep* 9(2):115–119
30. Talley JJ, Brown DL, Carter JS, Graneto MJ, Koboldt CM, Masferrer JL, Perkins WE, Rogers RS, Shaffer AF, Zhang YY, Zweifel BS, Seibert K (2000) 4-[5-Methyl-3-phenylisoxazol-4-yl]-benzenesulfonamide, valdecoxib: a potent and selective inhibitor of COX-2. *J Med Chem* 43(5):775–777
31. Engelhardt EL, Thominet ML (1969) Sulpiride synthesis. U.S. Patent, 3342826
32. Ozawa Y, Kusano K, Owa T, Yokoi A, Asada M, Yoshimatsu K (2012) Therapeutic potential and molecular mechanism of a novel sulfonamide anticancer drug, indisulam (E7070) in combination with CPT-11 for cancer treatment. *Cancer Chemother Pharmacol* 69(5):1353–1362
33. Penning T, Tally J, Bertenshaw S, Carter J, Collins P, Doctor S, Graneto M, Lee L, Malecha J, Miyashiro J, Rogers R, Rogier D, Yu S, Anderson G, Burton E, Cogburn J, Gregory S, Koboldt C, Perkins W, Seibert K, Veenhuizen A, Zhang Y, Isakson P (1997) Synthesis and biological evaluation of the 1,5-diarylpyrazole class of cyclooxygenase-2 inhibitors: identification of 4-[5-(4-methyl phenyl)-3-(trifluoromethyl)-1H-pyrazol-1-yl] benzenesulfonamide (SC-58635, celecoxib). *J Med Chem* 40:1347–1365
34. Stams T, Chen Y, Boriack-Sjodin P, Hurt J, Liao J, May J, Dean T, Laipis P, Silverman D, Christianson D (1998) Structures of murine carbonic anhydrase IV and human carbonic anhydrase II complexed with brinzolamide: molecular basis of isozyme-drug discrimination. *Protein Sci* 7(3):556–563
35. Mizuno C, Chittiboyina A, Kurtz T, Pershadsingh H, Avery M (2008) Type 2 diabetes and oral antihyperglycemic drugs. *Curr Med Chem* 15(1):61–74
36. Ward K, Gill J (1997) Dofetilide: first of a new generation of class III agents. *Exp Opin Invest Drugs* 6(9):1269–1281
37. Van Berkel MA, Elefritz JL (2018) Evaluating off-label uses of acetazolamide. *Am J Health Syst Pharm* 75:524–531
38. Fernstrom J, Munger S, Sclafani A, de Araujo I, Roberts A, Molinary S (2012) Mechanisms for Sweetness. *J Nutr* 142(6):1134S–1141S
39. Dodd M, Huang C (2004) Transformation of the antibacterial agent sulfamethoxazole in reactions with chlorine: kinetics, mechanisms, and pathways. *Environ Sci Technol* 38:5607–5615
40. Bottari N, Baldissera M, Tonin A, Rech V, Alves C, D'Avila F, Thomé G, Guarda N, Moresco R, Camillo G, Vogel F, Lucchese C, Schetinger M, Morsch V, Tochetto C, Figuera R, Nishihira V, Da Silva A (2016) Synergistic effects of resveratrol (free and inclusion complex) and sulfamethoxazole-trimethoprim treatment on pathology, oxidant/antioxidant status and behavior of mice infected with *Toxoplasma gondii*. *Microb Pathogenesis* 95:166–174
41. Nakashima K, Aoshima M, Nakashita T, Hara M, Otsuki A, Noma S, Misawa M, Otsuka Y, Motojima S (2018) Low-dose trimethoprim-sulfamethoxazole treatment for pneumocystis pneumonia in non-human immunodeficiency virus-infected immunocompromised patients: A single-center retrospective observational cohort study. *J Microbiol. Immunol* 51(6):810–820
42. Ahmed M, Abdul Qadir M, Shafiq M, Muddassar M, Hameed A, Arshad M, Asiri A (2017) Curcumin: synthesis optimization and in silico interaction with cyclin-dependent kinase. *Acta Pharm* 67:385–395
43. Wichitnithad W, Nimmanit U, Wacharasindhu S, Rojsitthisak P (2011) Synthesis, characterization and biological evaluation of succinate prodrugs of curcuminoids for colon cancer treatment. *Molecules* 16:1888–1900
44. Pabon H (1964) A synthesis of curcumin and related compounds. *Recueil* 83:379
45. Den Hartogh DJ, Gabriel A, Tsiani E (2019) Antidiabetic properties of curcumin II: evidence from in vivo studies. *Nutrients* 12(1):58
46. Kabirifara R, Ghoshia Z, Rezaifar A, Binesh F, Bamdadd K, Moradia A (2018) Curcumin, quercetin and atorvastatin protected against the hepatic fibrosis by activating AMP-activated protein kinase. *J Funct Foods* 40:341–348
47. Sahyon H, Ramadan E, Mashaly M (2019) Synergistic effect of quercetin in combination with sulfamethoxazole as new antibacterial agent: invitro and invivo study. *J Pharm Chem* 53(9):803–813
48. Montgomery H, Dymock J (1961) The determination of nitrate in water. *Analyst* 86:414–416
49. Goldberg D, Spooner R (1983) In: Bergmeyer HV (ed) *Assay of glutathione reductase. Methods of Enzymatic Analysis*. Verlag Chemie: Weinheim, Germany, pp 258–265
50. Reitman S, Frankel S (1957) A colorimetric method for the determination of serum glutamic oxalacetic and glutamic pyruvic transaminases. *Am J Clin Pathol* 28(1):56–63
51. Gornall A, Bardawill C, David M (1949) Determination of serum proteins by means of the biuret reaction. *J Biol Chem* 177(2):751–766
52. Dumas B, Watson W, Biggs H (1971) Albumin standards and the measurement of serum albumin with promocresol green. *Clin Chim Acta* 31(1):87–96
53. Nishikimi M, Appaji N, Yogi K (1972) The occurrence of superoxide anion in the reaction of reduced phenazine methosulfate and molecular oxygen. *Biochem Biophys Res Commun* 46(2):849–854
54. Beutler E, Duro O, Kelly B (1963) Improved method for the determination of blood glutathione. *J Lab Clin Med* 61:882–890
55. Koracevic D, Koracevic G, Djordjevic V, Andrejevic S, Cosic V (2001) Method for the measurement of antioxidant activity in human fluids. *J Clin Pathol* 54(5):356–361
56. Satoh K (1978) Serum lipid peroxide in cerebrovascular disorders determined by a new colorimetric method. *Clin Chim Acta* 90(1):37–43
57. Rubio C, Hernández-Ruiz J, Martínez-Subiela S, Tvarijonavičute A, Ceron J (2016) Spectrophotometric assays for total antioxidant capacity (TAC) in dog serum: an update. *BMC Vet Res* 12:166
58. Laemmli U (1970) Cleavage of structural proteins during the assembly of the head of bacteriophage T4. *Nature*. 227(5259):680–685
59. Andrews A (1986) *Electrophoresis: theory, techniques, and biochemical and clinical application*. Oxford Science Publications Clarendon Press, Oxford, p 452
60. Oner-Iyidogan Y, Kocak H, Seyidhanogiu M, Gurdol F, Gulcubuk A, Yildirim F, Cevik A, Uysal M (2013) Curcumin prevents liver fat accumulation and serum fetuin-A increase in rats fed a high-fat diet. *J Physiol Biochem* 69(4): 677–686
61. Feng J, Liu Z (2009) Phenolic and enolic hydroxyl groups in curcumin: which plays the major role in scavenging radicals? *J Agric Food Chem* 57: 11041–11046
62. Anderson A, Mitchell M, Mohan R (2000) Isolation of curcumin from turmeric. *J Chem Educ* 77(3):359
63. Rohman A, Sudjadi D, Ramadhani D, Nugroho A (2015) Analysis of curcumin in curcuma longa and curcuma xanthorrhiza using FTIR spectroscopy and chemometrics. *J Med Plants Res* 9(4):179–186
64. Youssef K, Ezzo A, El-Sayed M, Hazzaa A, El-Medany A, Arafa M (2015) Chemopreventive effects of curcumin analogs in DMH-induced colon cancer in albino rats model. *J Pharm Sci* 1:57–72
65. Valand N, Manishkumar P, Menon S (2015) Curcumin-p-sulfonatocalix [4] resorcinarene (p-SC [4] R) interaction: thermo-physico chemistry, stability, and biological evaluation. *RSC Adv* 5:8739–8752
66. Mohan PR, Sreelakshmi G, Mureledharan CV, Joseph R (2012) Water soluble complexes of curcumin with cyclodextrins: characterization by FT-Raman spectroscopy. *Vib spectrosc* 62:77–84
67. Silverstein R, Bassler G, Morrill T (1981) *Spectrometric identification of organic compounds*, 4th edn. Wiley, New York, p 442
68. Williams D, Fleming I (1980) *Spectroscopic methods in organic chemistry*. London, New York, McGraw-Hill, p 251.
69. Jamwal R (2018) Bioavailable curcumin formulations: a review of pharmacokinetic studies in healthy volunteers. *J Integr Med* 16(6):367–374
70. Nouredin S, El-Shishtawy R, Al-Footy K (2019) Curcumin analogues and their hybrid molecules as multifunctional drugs. *Eur J Med Chem* 182: 111631
71. Ramya PVS, Angapelly S, Angeli A, Digwal C, Arifuddin M, Babu B, Supuran CT, Kamal A (2017) Discovery of curcumin inspired sulfonamide derivatives as a new class of carbonic anhydrase isoforms I, II, IX, and XII inhibitors. *J Enzym Inhib Med Ch* 32(1):1274–1281
72. Oyinloye B, Osunsanmi F, Ajilboye B, Ojo O, Kappo A (2017) Modulatory effect of methanol extract of piper guineense in CCl₄-induced hepatotoxicity in male rats. *Int J Env Res Pub He* 14:955
73. Jaeschke H, McGill M, Ramachandran A (2012) Oxidant stress, mitochondria, and cell death mechanisms in drug-induced liver injury: lessons learned from acetaminophen hepatotoxicity. *Drug Metab Rev* 44:88–106
74. Jagetia G, Rajanikant G (2015) Curcumin stimulates the antioxidant mechanisms in mouse skin exposed to fractionated γ -irradiation. *Antioxidants* 4:25–41
75. Khan H, Ullah H, Nabavi S (2019) Mechanistic insights of hepatoprotective effects of curcumin: Therapeutic updates and future prospects. *Food Chem Toxicol* 124:182–191
76. Zhao Y, Ma X, Wang J, He X, Hu Y, Zhang P, Wang R, Li R, Gong M, Luo S, Xiao X (2014) Curcumin protects against CCl₄-induced liver fibrosis in rats by inhibiting HIF-1 α through an ERK-dependent pathway. *Molecules* 19: 18767–18780

77. Devi SL, Viswanathan P, Anuradha CV (2009) Taurine enhances the metabolism and detoxification of ethanol and prevents hepatic fibrosis in rats treated with iron and alcohol. *Environ Toxicol Phar* 27:120–126
78. Peng X, Dai C, Liu Q, Li J, Qiu J (2018) Curcumin attenuates on carbon tetrachloride-induced acute liver injury in mice via modulation of the Nrf2/HO-1 and TGF- β 1/Smad3 pathway. *Molecules* 23(1):215
79. Momeni H, Eskandari N (2017) Effect of curcumin on kidney histopathological changes, lipid peroxidation and total antioxidant capacity of serum in sodium arsenite-treated mice. *Exp Toxicol Pathol* 69(2):93–97
80. Yin H, Guo R, Xu Y, Zheng Y, Hou Z, Dai X, Zhang Z, Zheng D, Xu H (2012) Synergistic antitumor efficiency of docetaxel and curcumin against lung cancer. *Acta Bioch Bioph Sin* 44:147–153
81. Gupta R, Anwar F, Khosa RL (2013) The effect of sulfamethoxazole and selenium on antioxidant defense system in the blood of rats treated with DEN. *IOSR JPBS* 8:29–37
82. Thaloor D, Singh A, Sidhu G, Prasad P, Kleinman H, Maheshwari R (1998) Inhibition of angiogenic differentiation of human umbilical vein endothelial cells by curcumin. *Cell Growth Differ* 9:305–312
83. Qin L, Qin J, Zhen X, Yang Q, Huang L (2018) Curcumin protects against hepatic stellate cells activation and migration by inhibiting the CXCL12/CXCR4 biological axis in liver fibrosis: A study in vitro and in vivo. *Biomed Pharmacother* 101:599–607
84. Ahmad S, Rehman M, Fatima B, Ahmad B, Hussain I, Ahmad S, Farooq A, Muzamil S, Razzaq R, Rashid S, Bhat S, Mir M (2018) Antifibrotic effects of D-limonene (5(1-methyl-4-[1-methylethenyl]) cyclohexane) in CCl₄ induced liver toxicity in Wistar rats. *Environ Toxicol* 33:361–369

Publisher's Note

Springer Nature remains neutral with regard to jurisdictional claims in published maps and institutional affiliations.

Submit your manuscript to a SpringerOpen[®] journal and benefit from:

- Convenient online submission
- Rigorous peer review
- Open access: articles freely available online
- High visibility within the field
- Retaining the copyright to your article

Submit your next manuscript at ► [springeropen.com](https://www.springeropen.com)
