

Mammography with a fully automated breast volumetric software as a novel method for estimating the preoperative breast volume prior to mastectomy

Jin Sung Kim¹, Kyoungkyg Bae², Eun Ji Lee¹, Minseo Bang²

¹Department of Surgery, Ulsan University Hospital, University of Ulsan College of Medicine, Ulsan, Korea

²Department of Radiology, Ulsan University Hospital, University of Ulsan College of Medicine, Ulsan, Korea

Purpose: Increasing interest in maintaining a positive body image following breast cancer surgery has become an important aspect of reconstruction surgery. Volume matching of the reconstructed breast to natural breasts is the most important consideration. This study aimed to explore the feasibility of using mammography with a fully automated breast volumetric software to measure the preoperative breast volume in patients with breast cancer.

Methods: We evaluated patients who underwent a total mastectomy between July 2016 and February 2021. The specimen volume following total mastectomy was compared with breast volume estimates using a fully automated volumetric software (Quantra ver. 2.1.1) and 4 other previously described mammography-based prediction methods. The association between the estimates and mastectomy specimen volume was assessed using Pearson correlation and Bland-Altman analysis.

Results: Sixty-six patients were included. Compared with previously described mammography-based methods, Quantra estimates were more strongly correlated with mastectomy specimen volume in the entire, fatty, and dense breast groups ($r = 0.920, 0.921, \text{ and } 0.915$, respectively; $P < 0.001$). In applying Quantra estimates for measuring preoperative breast volume, we adjusted a simple equation: mastectomy specimen volume = Quantra estimate \times 0.8.

Conclusion: Mammography with a fully automated breast volumetric software can be useful for measuring preoperative breast volume in patients with breast cancer who undergo reconstruction surgery.

[Ann Surg Treat Res 2021;100(6):313-319]

Key Words: Breast density, Breast neoplasms, Mammography, Mastectomy, Organ size, Software

INTRODUCTION

With increasing interest in maintaining a positive body image following breast cancer surgery, reconstruction surgery has become an important topic. To achieve balanced breast symmetry with reconstruction surgery, volume matching of the reconstructed breast to natural breasts is the most important consideration [1]. As such, various methods including

Archimedes' method, plastic casting, anthropomorphic measurements, use of a Grossman-Rounder cone, and 3-dimensional (3D) surface imaging techniques have been evaluated for breast volume measurement [2-9].

Another method that has been proposed for preoperative breast volume measurement is mammography [10-14]. Because mammography is commonly used for breast cancer diagnosis, mammographic measurement is a readily available option

Received January 27, 2021, Revised March 22, 2021,
Accepted April 9, 2021

Corresponding Author: Minseo Bang

Department of Radiology, Ulsan University Hospital, University of Ulsan College of Medicine, 877 Bangeojinsunhwando-ro, Dong-gu, Ulsan 44033, Korea

Tel: +82-52-250-7257, Fax: +82-52-230-1155

E-mail: bangms@uuh.ulsan.kr

ORCID: https://orcid.org/0000-0001-8933-1444

Copyright © 2021, the Korean Surgical Society

© Annals of Surgical Treatment and Research is an Open Access Journal. All articles are distributed under the terms of the Creative Commons Attribution Non-Commercial License (<http://creativecommons.org/licenses/by-nc/4.0/>) which permits unrestricted non-commercial use, distribution, and reproduction in any medium, provided the original work is properly cited.

for which no additional equipment is needed [7,10]. In most studies, volume measurement in mammography involved the use of geometric formulae to transform measurements into 3D breast shapes [11-14]. However, the applicability of this method is limited by observer subjectivity and inconsistencies in accuracy [2,3,11-15].

A fully automated volumetric software has been developed for objective evaluation and control of interobserver variability in measuring breast density [16-19]. The software assesses the breast as a 3D structure and automatically quantifies the entire breast and fibroglandular volume and mammographic densities for both breasts [19]. Previous studies involving a fully automated volumetric software have focused on evaluating the reliability of density measurements, comparisons of software-based versus visual assessments, and the usefulness of software as stratification tools in evaluating the risk of breast cancer [16-21]. However, to the best of our knowledge, no studies have evaluated entire breast volume data estimated using a fully automated volumetric software nor applied software in clinical practice for estimating breast volume.

Thus, this study aimed to explore the feasibility of using mammography with a fully automated breast volumetric software for measuring the preoperative breast volume in patients with breast cancer who undergo reconstruction surgery.

METHODS

Study design and patients

This retrospective study was approved by Institutional Review Board of Ulsan University Hospital (No. UUH-2019-06-038) and was conducted according to the tenets of the Declaration of Helsinki and its later amendments. The requirement for informed consent was waived due to the retrospective nature of the study.

Participants underwent total mastectomy between July 2016 and February 2021 at Ulsan University Hospital in Ulsan, Korea. Patients were included if data from preoperative mammography analyzed with a fully automated volumetric software and specimen weight were available from the medical records. Male patients with breast cancer, patients with clinical T3 or T4 stage, those with incomplete medical records, those receiving neoadjuvant chemotherapy, and those experiencing recurrence at the time of surgery were excluded.

Throughout the study period, mammography was performed using a full-field digital mammography machine (Selenia Dimensions, Hologic, Bedford, MA, USA). Standard craniocaudal and mediolateral oblique views were routinely obtained.

Mammographic volume analysis by fully automated volumetric software

For fully automated volumetric analysis, we used Quantra version 2.1.1 (Hologic) from the raw full-filled digital mammography. The Quantra software is based on a verified method that accounts for imaging parameters used to acquire an image, such as kVp (kilovolt peak), mAs (milliampere-second), and characteristics of the filter and target materials [22]. The software separates the breast region from the background to estimate tissue composition, including fatty and fibroglandular tissue, by computing X-ray attenuation. Following analysis on a pixel-by-pixel basis, the software aggregates single pixel values into an estimate volume of fibroglandular tissue and the breast provided in cubic centimeters [19]. This process is performed separately for each breast; the final result includes a separate estimate for each breast and an average of both breasts. When Quantra processing was complete, processing data was displayed as Digital Imaging and Communications in Medicine (DICOM) capture images relaying the breast composition information (Fig. 1).

Mammographic volume measurement using an established equation

We searched related literature from the PubMed database and found 4 equations that used standard mammography (craniocaudal and mediolateral oblique view) for breast volume estimation.

$$(a) \text{ Breast volume} = 1/3\pi R_{cc}^2 H_{cc} \quad [11]$$

$$(b) \text{ Breast volume} = 1/3\pi r_{mlo}^2 h_{mlo} \quad [12]$$

$$(c) \text{ Breast volume} = 1/3\pi R_{cc} r_{mlo} h_{mlo} \quad [13]$$

All 3 of these equations assume that a breast on the craniocaudal or mediolateral oblique view approximates a cone shape.

$$(d) \text{ Breast volume} = 1/4\pi H_{cc} W_{cc} C_{cc} \quad [14]$$

This equation described by Kalbhen et al. [14] is based on the shape of a compressed breast in the craniocaudal view, which is assumed to be a half-elliptic cylinder.

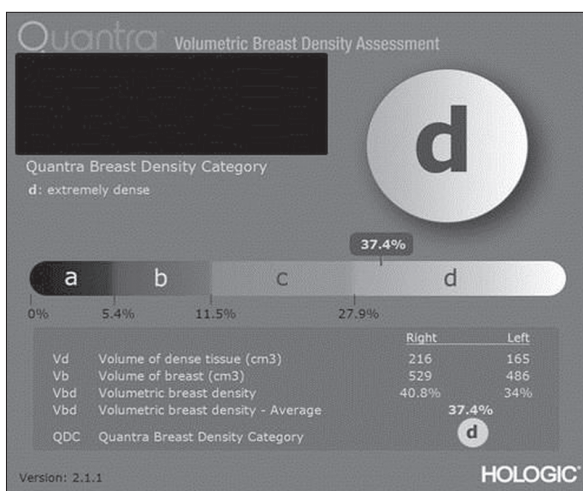


Fig. 1. Quantra processing.

A breast radiologist (7 years of experience) blinded to the specimen weight measured H, R, and W on the craniocaudal view and r and h on the mediolateral oblique view of preoperative mammography. The C indicated the automatically measured values on the craniocaudal view of mammography. Representations of each of these measurements are shown in Fig. 2. In cases where measurements were difficult to confirm, a breast-imaging specialist with over 20 years of experience was consulted.

Surgical procedure

In this study, only patients with total mastectomy, excluding skin-sparing or nipple-sparing mastectomy, were included. For the total mastectomy, transverse or oblique elliptical incision was performed on the skin around the nipple. The extent of the mastectomy was to dissect from the medial side to the lateral border of the sternum, from the upper side to the lower side of the clavicle, from the lower side to the inframammary fold, and from the lateral side to the mid axillar line. Furthermore, axilla lymph node dissection was performed for sentinel lymph node biopsy or for axilla lymph node. Even where the axilla lymph node dissection was performed *en bloc*, the specimen weight was measured excluding the axilla lymph node and soft tissue.

Standard reference

Quantra- and mammography-based estimates are expressed as volumes; therefore, we used volume for comparisons

throughout this study. However, volume information was not provided in the patients' medical records due to our hospital's standard practice of recording only the weight of the specimen during surgery. Thus, volume was calculated based on mammographic density (ρ) using the following equation: breast volume = breast weight/ ρ ($\rho = 0.916$ g/mL for pattern A, $\rho = 0.944$ g/mL for pattern B, $\rho = 0.972$ g/mL for pattern C, and $\rho = 1.0$ g/mL for pattern D) [14]. The patterns were set to account for the variability in breast tissue composition including differences in water and fat density between patients [17]. Mammographic density was determined according to the percentage volumetric breast density in the report of Quantra analysis: pattern A, <5.4%; pattern B, <11.5%; pattern C, <27.9%; and pattern D, $\geq 27.9\%$.

Statistical analysis

Pearson correlation analysis was performed to assess the degree of linear association in breast volume measurement methods and specimen volume. Linear regression analysis was used for adjusting Quantra estimates to derive a mathematical formula. Bland-Altman analysis was performed to assess agreement between adjusted Quantra estimates and specimen volume. The 95% limit of agreement was formed using the mean difference in volume ± 1.96 standard deviation (SD) of the difference in volumes. Fixed and proportional bias was assessed using the 95% confidence interval for the mean difference. All statistical analyses were performed using IBM SPSS Statistics ver. 21.0 (IBM Corp., Armonk, NY, USA). A P-value of <0.05 was considered statistically significant.

RESULTS

A total of 66 patients were included in this study. The mean age was 63.9 years (range, 45–87 years), and the mean body mass index was 23.92 kg/m² (range, 17.91–31.68 kg/m²). Tumor presentation types of mammography were as follows: calcification only in 14 patients, mass only in 35 patients, and

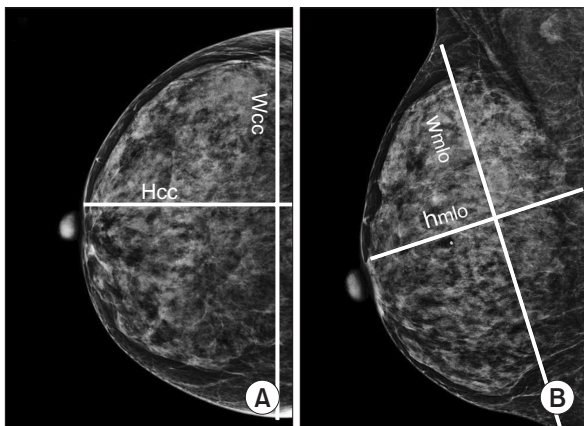


Fig. 2. Sample mammography measurements in a 51-year-old woman with invasive ductal carcinoma. (A) Craniocaudal view shows representations of measurements. W = medial to lateral width, R = W/2, H = posterior to anterior height, perpendicular from the posterior film edge to the most anterior portion of the breast. (B) Mediolateral oblique view shows representations of measurements. w = superolateral to inferomedial width, measured as a distance from the most acute portion of axillary concavity to the inframammary fold; r = w/2; h = posterior to anterior height, perpendicular to the pectoralis muscle from the anterior border of the muscle to the most anterior portion of the breast.

Table 1. Breast volume estimates calculated using Quantra and conventional mammographic methods

Variable	Equation	Estimated volume (cm ³)
Adjusted Quantra ^{a)}		434.36 (96.0–814.4)
Quantra		542.95 (120.0–1,018.0)
Katariya et al. [11]	$1/3\pi R_{cc}^2 H_{cc}$	642.0 (160.9–1,132.0)
Cochrane et al. [12]	$1/3\pi r_{mlo}^2 h_{mlo}$	682.2 (197.2–1,367.8)
Fung et al. [13]	$1/3\pi R_{cc} r_{mlo} h_{mlo}$	688.8 (177.4–1,305.1)
Kalbhen et al. [14]	$1/4\pi H_{cc} W_{cc} C_{cc}$	512.96 (96.5–927.2)

Values are presented as mean (range). Mean (range) of specimen weight is 421.22 g (96.0–830.0 g) and specimen volume is 438.83 cm³ (98.7–879.23 cm³). ^{a)}Quantra-based estimates $\times 0.8$.

both mass and calcification in 17 patients. Mammographic density patterns were fatty breast (A or B) in 23 patients and dense breast (C or D) in 43 patients. The clinical T stage was 0 in 7 patients, 1 in 30 patients, and 2 in 29 patients. All patients had unilateral breast cancer (right side, 40 patients and left side, 26 patients). The mean specimen weight was 421.22 g (range, 96–830 g). The mean specimen volume calculated from weight and adjusted density, used as a standard reference, was 438.83 cm³ (range, 98.70–879.23 cm³).

Table 1 shows the estimated volume from Quantra and 4 other conventional mammography-based prediction methods. There was a strong correlation between specimen volume and breast volume calculated using Quantra: $r = 0.920$ for the entire breast group, $r = 0.921$ in the fatty breast group, and $r = 0.915$ in the dense breast group. Compared to conventional mammographic methods, Quantra-based estimates had a stronger correlation with the specimen volume of the entire, fatty, and dense breast groups (Table 2). However, both Quantra-

Table 2. Pearson correlations of breast volume estimates calculated using Quantra- and mammography-based methods with specimen volume

Variable	Breast volume calculated from specimen weight					
	Quantra	Adjusted Quantra ^{a)}	$1/3\pi R_{cc}^2 H_{cc}$	$1/3\pi r_{mlo}^2 h_{mlo}$	$1/3\pi R_{cc} r_{mlo} h_{mlo}$	$1/4\pi H_{cc} W_{cc} C_{cc}$
All breasts (n = 66)	0.920	0.920	0.839	0.808	0.844	0.898
Fatty breast (A + B) (n = 23)	0.921	0.921	0.824	0.799	0.816	0.909
Dense breast (C + D) (n = 43)	0.915	0.915	0.854	0.811	0.859	0.889

A–D, patterns of mammographic breast density.

P < 0.001 for all.

^{a)}Quantra-based estimates × 0.8.

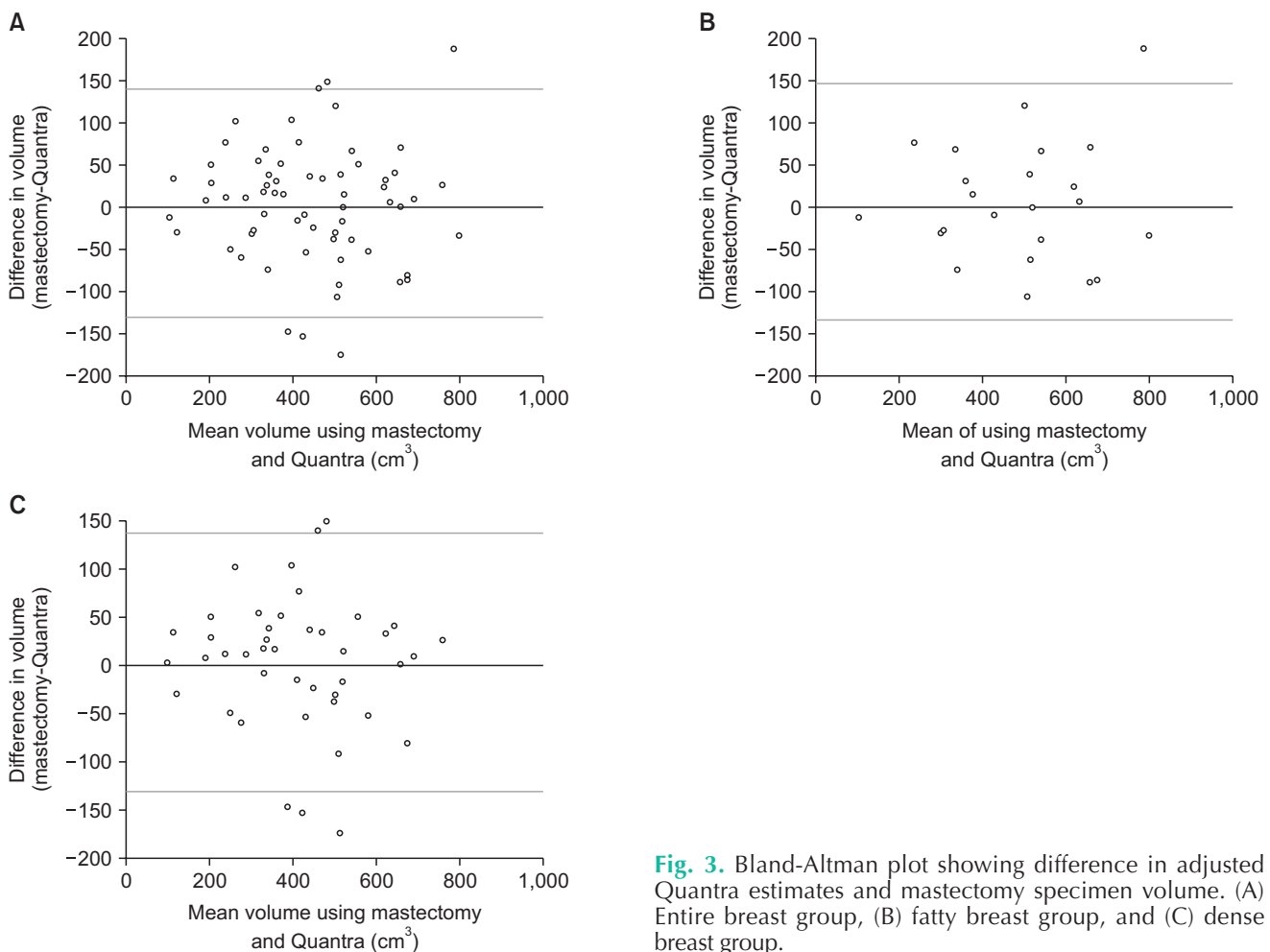


Fig. 3. Bland-Altman plot showing difference in adjusted Quantra estimates and mastectomy specimen volume. (A) Entire breast group, (B) fatty breast group, and (C) dense breast group.

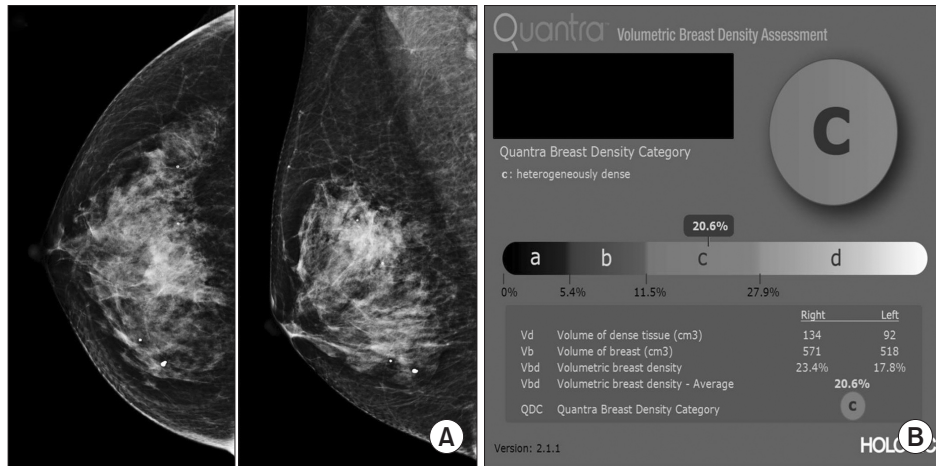


Fig. 4. Sample image for Quantra-based estimation of preoperative breast volume. A 57-year-old woman with invasive ductal carcinoma of the right breast underwent a total mastectomy. (A) Preoperatively, the patient underwent routine mammography with fully automated breast volumetric software (Quantra). (B) The Quantra- and adjusted Quantra-based breast volume was 571 cm³ and 456.8 cm³, respectively. After total mastectomy, the weight of the actual mastectomy specimen was 460 g, and the converted specimen volume was 447.2 cm³.

and other mammography-based prediction methods tended to overestimate the mastectomy specimen volume.

For the application of Quantra-based estimates in measuring preoperative breast volume, we adjusted a simple equation using linear regression analysis: mastectomy specimen volume = Quantra-based estimate × 0.8. There was also a strong correlation between specimen volume and adjusted Quantra-based estimates: $r = 0.920$ for the entire breast group, $r = 0.921$ in the fatty breast group, and $r = 0.915$ in the dense breast group (Table 2). Bland-Altman scatter plots show that the difference between mastectomy specimen volume and adjusted Quantra-based estimates remained acceptable (mean ± 1.96 SD), indicating high reliability for the prediction of preoperative breast volume. There was no proportional or fixed bias (Fig. 3). An example of how adjusted Quantra-based estimates were applied to the patient is provided in Fig. 4.

DISCUSSION

This study investigated the feasibility of using breast mammography combined with a fully automated breast volumetric software for measuring preoperative breast volume. Compared to estimates using conventional mammography-based calculations, Quantra-based estimates obtained in this study correlated more strongly with mastectomy specimen volume. However, there was a tendency to overestimate the mastectomy specimen volume, which had to be adjusted for and then applied to measure the preoperative breast volume. To predict breast volume from raw data of Quantra, we used the following formula; adjusted Quantra-based estimates = Quantra-based estimates × 0.8.

In this study, a fully automated breast volumetric software for preoperative measurements tended to overestimate the actual breast volume, which can be explained by the fact that the tissue captured by mammography did not completely match the tissue removed during mastectomy. All breast tissue should be removed in total mastectomy; however, some parts of the skin, subcutaneous fat, and axillae are left for postoperative skin closure and cosmesis. In addition, before the operation, the breast also contains blood, water, and secretions such as milk, that are removed during resection, reducing the overall weight [23,24]. Thus, the estimates derived from Quantra should be adjusted so that they can be applied to reconstructive surgery.

Quantra-based estimates better correlated with mastectomy specimen volume than previously described mammography-based calculation estimates. Quantra segments the breast region from the background of mammography and uses volumetric values to derive information about the X-ray attenuation properties of the column of breast tissue above that pixel. Thus, Quantra-based calculations may be more accurate than previously described mammography-based calculation methods that are derived under the assumption that the breast is either a cone or half-elliptical cylinder shape to transform 2-dimensional measurements made from the mammography into 3D shapes [11-14,18,19].

Among the previously described mammography-based calculation methods, the formula of Kalbhen et al. [14] (breast volume = $1/4\pi H_{cc} W_{cc} C_{cc}$) yielded results most closely correlated with breast specimen volumes. With the development of the mammography machine, breast compressions are now performed at a higher pressure, which violates the assumption of the cone shape, creating conditions more suitable for the

half-elliptical cylinder shape assumption considered by Kalbhen et al. [2,14]. Several studies have investigated the most suitable equation for calculating the breast volume by mammography [2,11-15], but the results have differed among them mainly due to the differences in the size and density of target breasts by race. The optimal method that yields measurements similar to the actual volume is still controversial.

In reconstructive and aesthetic breast surgery, accurate volume estimation is an important component of preoperative planning for achieving breast symmetry and cosmesis outcome. Most classic methods such as Archimedes' method, plastic casting, and anthropomorphic measurements have been unreliable, difficult to execute, and lacked practicability [2,3,7]. Preoperative MRI is known to be a relatively accurate and reproducible method to measure breast volume [2]. MRI is a 3D imaging modality; however, it does not provide precise information regarding breast shape that can occur with conditions, such as ptosis, because MRI requires patients to be examined lying face down. The volumetric software mentioned in previous studies using MRI was reported to be diverse and unstandardized [25-27]. Additionally, MRI techniques and associated software require extensive effort because the inspector measures the volume by specifying the area directly for each slice of the image [25]. 3D surface imaging modalities are a recently developed innovative method for estimating breast volume that is easy to use, reliable, fast, and portable [4-6,8]. However, this technique is costly, motion-sensitive, and cannot differentiate the posterior surface of the breast from the chest wall [5].

A fully automated breast volumetric software has a relatively high degree of reproducibility and reliability [16,18]. Additionally, if data are extracted directly from a software-equipped mammography machine, the estimates can be obtained automatically without any additional effort required from the patient or treating physician. Nevertheless, this method has some drawbacks. The software is currently available only for digital mammography machines and is expensive [19]. Further, the software does not provide information on breast appearances such as the shape, trunk width, or presence of ptosis.

Unfortunately, this was a small, single-center study. To improve the accuracy of the study, only patients who underwent total mastectomy were included. There are also several problems associated with using the specimen volume as a standard for comparison. We used the volume estimated based on the specimen weight and not the exact measured specimen volume. Additionally, as the specimens were obtained from patients with breast cancer, the specimen volume included the tumor volume. To reduce this difference, cases of T3 and T4 cancer were excluded from this study. However, if the tumor is large, the volume of the breast can be overestimated or underestimated even though it is a T2 tumor.

This study demonstrated the usefulness of Quantra for

preoperative volume measurement by comparing it with previously described mammography-based estimates. A previous study showed that mammography-based methods might be more accurate than classic techniques including casting, Archimedes' method, anthropometry, or using the Grossman-Roudner device [3]. Recently developed 3D surface imaging technology and MRI measurement software were not available in our lab; therefore comparisons to this technique were not possible. However, we compared the estimated volume from Quantra with the actual volume from the total mastectomy specimen and obtained meaningful results. This study did not aim to determine whether a fully automated breast volumetric software is the optimal method to predict preoperative breast volume, but rather to investigate whether mammography with a fully automated breast volumetric software could be another feasible method to predict preoperative breast volume.

In conclusion, the estimated breast volume from a fully automated breast volumetric software, although overestimated, was strongly correlated with the actual mastectomy specimen volume. Thus, using a fully automated breast volumetric software with mammography can be helpful for measuring the preoperative breast volume for patients with breast cancer who will undergo reconstruction surgery.

ACKNOWLEDGEMENTS

This study was performed using Quantra version 2.1.1 (Hologic, Bedford, MA, USA) provided by the National R&D Program for Cancer Control, Ministry of Health & Welfare, Republic of Korea(1520200) program.

Conflict of Interest

No potential conflict of interest relevant to this article was reported.

ORCID iD

Jin Sung Kim: <https://orcid.org/0000-0002-5927-4909>

Kyoungkyg Bae: <https://orcid.org/0000-0003-2503-7718>

Eun Ji Lee: <https://orcid.org/0000-0001-8756-4287>

Minseo Bang: <https://orcid.org/0000-0001-8933-1444>

Author Contribution

Conceptualization, Methodology, Project Administration: MB

Formal Analysis: MB, JSK, EJJ

Investigation: JSK, KB

Writing – Original Draft: MB, JSK

Writing – Review & Editing: KB, EJJ

REFERENCES

1. Utsunomiya H, Kusano T, Sato N, Yoshimoto S. Estimating implant volume and mastectomy-specimen volume by measuring breast volume with a 3-dimensional scanner. *Ann Plast Surg* 2017;79:79-81.
2. Choppin SB, Wheat JS, Gee M, Goyal A. The accuracy of breast volume measurement methods: a systematic review. *Breast* 2016;28:121-9.
3. Kayar R, Civelek S, Cobanoglu M, Gungor O, Catal H, Emiroglu M. Five methods of breast volume measurement: a comparative study of measurements of specimen volume in 30 mastectomy cases. *Breast Cancer (Auckl)* 2011;5:43-52.
4. Kovacs L, Eder M, Hollweck R, Zimmermann A, Settles M, Schneider A, et al. Comparison between breast volume measurement using 3D surface imaging and classical techniques. *Breast* 2007;16:137-45.
5. Yip JM, Mouratova N, Jeffery RM, Veitch DE, Woodman RJ, Dean NR. Accurate assessment of breast volume: a study comparing the volumetric gold standard (direct water displacement measurement of mastectomy specimen) with a 3D laser scanning technique. *Ann Plast Surg* 2012;68:135-41.
6. Losken A, Seify H, Denson DD, Paredes AA Jr, Carlson GW. Validating three-dimensional imaging of the breast. *Ann Plast Surg* 2005;54:471-6.
7. Bulstrode N, Bellamy E, Shrotria S. Breast volume assessment: comparing five different techniques. *Breast* 2001;10:117-23.
8. Howes BH, Watson DL, Fosh B, Dean NR. Efficacy of an external volume expansion device and autologous fat grafting for breast reconstruction following breast conserving surgery and total mastectomy: small improvements in quality of life found in a prospective cohort study. *J Plast Reconstr Aesthet Surg* 2020;73:27-35.
9. Chae MP, Rozen WM, Spychal RT, Hunter-Smith DJ. Breast volumetric analysis for aesthetic planning in breast reconstruction: a literature review of techniques. *Gland Surg* 2016;5:212-26.
10. Itsukage S, Sowa Y, Goto M, Taguchi T, Numajiri T. Breast volume measurement by recycling the data obtained from 2 routine modalities, mammography and magnetic resonance imaging. *Eplasty* 2017;17:e39.
11. Katariya RN, Forrest AP, Gravelle IH. Breast volumes in cancer of the breast. *Br J Cancer* 1974;29:270-3.
12. Cochrane RA, Valasiadou P, Wilson AR, Al-Ghazal SK, Macmillan RD. Cosmesis and satisfaction after breast-conserving surgery correlates with the percentage of breast volume excised. *Br J Surg* 2003;90:1505-9.
13. Fung JT, Chan SW, Chiu AN, Cheung PS, Lam SH. Mammographic determination of breast volume by elliptical cone estimation. *World J Surg* 2010;34:1442-5.
14. Kalbhen CL, McGill JJ, Fendley PM, Corrigan KW, Angelats J. Mammographic determination of breast volume: comparing different methods. *AJR Am J Roentgenol* 1999;173:1643-9.
15. Hoe AL, Mullee MA, Royle GT, Guyer PB, Taylor I. Breast size and prognosis in early breast cancer. *Ann R Coll Surg Engl* 1993;75:18-22.
16. Gweon HM, Youk JH, Kim JA, Son EJ. Radiologist assessment of breast density by BI-RADS categories versus fully automated volumetric assessment. *AJR Am J Roentgenol* 2013;201:692-7.
17. Ciatto S, Bernardi D, Calabrese M, Durando M, Gentilini MA, Mariscotti G, et al. A first evaluation of breast radiological density assessment by QUANTRA software as compared to visual classification. *Breast* 2012;21:503-6.
18. Youk JH, Gweon HM, Son EJ, Kim JA. Automated volumetric breast density measurements in the era of the bi-rads fifth edition: a comparison with visual assessment. *AJR Am J Roentgenol* 2016;206:1056-62.
19. Skippage P, Wilkinson L, Allen S, Roche N, Dowsett M, A'hern R. Correlation of age and HRT use with breast density as assessed by Quantra™. *Breast J* 2013;19:79-86.
20. Alonzo-Proulx O, Mawdsley GE, Patrie JT, Yaffe MJ, Harvey JA. Reliability of automated breast density measurements. *Radiology* 2015;275:366-76.
21. Rahbar K, Gubern-Merida A, Patrie JT, Harvey JA. Automated volumetric mammographic breast density measurements may underestimate percent breast density for high-density breasts. *Acad Radiol* 2017;24:1561-9.
22. Boone JM, Fewell TR, Jennings RJ. Molybdenum, rhodium, and tungsten anode spectral models using interpolating polynomials with application to mammography. *Med Phys* 1997;24:1863-74.
23. Wilson CB, Lammertsma AA, McKenzie CG, Sikora K, Jones T. Measurements of blood flow and exchanging water space in breast tumors using positron emission tomography: a rapid and noninvasive dynamic method. *Cancer Res* 1992;52:1592-7.
24. Shaheed SU, Tait C, Kyriacou K, Linforth R, Salhab M, Sutton C. Evaluation of nipple aspirate fluid as a diagnostic tool for early detection of breast cancer. *Clin Proteomics* 2018;15:3.
25. Herold C, Reichelt A, Stieglitz LH, Dettmer S, Knobloch K, Lotz J, et al. MRI-based breast volumetry-evaluation of three different software solutions. *J Digit Imaging* 2010;23:603-10.
26. Herly M, Müller FC, Ørholt M, Hansen J, Sværke S, Hemmingsen MN, et al. The current gold standard breast volumetry technique seems to overestimate fat graft volume retention in the breast: a validation study. *J Plast Reconstr Aesthet Surg* 2019;72:1278-84.
27. Rha EY, Choi IK, Yoo G. Accuracy of the method for estimating breast volume on three-dimensional simulated magnetic resonance imaging scans in breast reconstruction. *Plast Reconstr Surg* 2014;133:14-20.