

Diagnostic and Therapeutic Challenges of Chronic Portal Vein Thrombosis Secondary to Myeloproliferative Neoplasm in Sub-Saharan Region: A Series of Cases and Literature Review

Abdu Mohammed¹, Abate Bane Shewaye^{1,2}, Fozia Abdela^{1,2}, Zebeaman Tibebe Gorfu¹, Ahmed Adem^{1,2}

¹Department of Internal Medicine, Adera Medical Center, Addis Ababa, Ethiopia; ²Department of internal Medicine, Addis Ababa University, College of Health Sciences, Addis Ababa, Ethiopia

Correspondence: Abdu Mohammed, Tel +251-913-103-656, Email abdumohammed7@gmail.com

Abstract: Myeloproliferative neoplasms (MPN) are the commonest causes of non-cirrhotic abdominal vein thrombosis. MPN was observed in 30–40% with Budd Chiari Syndrome (BCS) and portal vein thrombosis (PVT), whereas this is the cause in only a minority of other types of venous thrombosis. Herein, we report 10 cases of chronic PVT secondary to Janus Kinase 2 gene (Jak 2) positive myeloproliferative neoplasm (MPN). The median age was 35 years with M:F 1:1. Portal hypertension was present at presentation in all of them. Nine patients have esophageal varices, of which 6 have bleeding at presentation. Classical MPN phenotype on complete blood count (CBC) was not present in 6 of them. Management of patients with anticoagulation was difficult with 4 patients experiencing bleeding during anticoagulation, and bleeding occurring despite the target international normalized ratio (INR) in 2 of them. Portal hypertension leading to hypersplenism and hemodilution may mask erythrocytosis and thrombocytosis, which are the main criteria used to diagnose MPN. The resulting absence of a typical MPN phenotype in routine laboratory studies alongside accessibility issues, and the need for a multidisciplinary treatment approach imparts a diagnostic as well as a therapeutic challenge for chronic PVT associated with Jak 2 positive MPN in sub-Saharan patients.

Keywords: portal cavernoma, cholangiopathy, Jak 2 mutation, MPN, Ethiopia, sub-Sahara

Introduction

Cavernous transformation of the portal vein or portal cavernoma is the formation of venous channels within or around a previously thrombosed portal vein.¹ It occurs 6–20 days after the thrombotic event, even after the development of partial recanalization of the thrombus.² Chronic Thrombosis of Portal Vein (CTPV) is the most common cause of extrahepatic Portal Vein Obstruction (EHPVO) in adults with underlying prothrombotic conditions. The most frequent cause are BCR-ABL-1 negative MPNs. Among these, the pooled prevalence of thrombosis is highest for Polycythemia Vera (PV), at 28.6%, followed by Essential Thrombocythemia (ET) at 20.7%, and lowest for Primary Myelofibrosis (PMF) at 9.5%.³ Main complications of chronic EHPVO are portal hypertension and portal cavernoma cholangiopathy.⁴ The primary diagnostic modality of choice is Doppler ultrasound followed by computed tomography (CT) scan for confirmation and further evaluation. Management of patients is aimed at preventing complications, as better control of hemorrhagic and thrombotic complications substantially improves life span and clinical outcomes.^{5,6}

The asymptomatic presentation of patients alongside the lack of access to specialist care and superior diagnostic modalities like the JAK2 mutation test renders a challenge for diagnosis in the sub-Saharan region where most patients already present with complications to point of care. Furthermore, the proper therapy could not be instituted straightaway

as correct management necessitates a follow-up by a multidisciplinary team and a series of laboratory investigations. Consequently, management is not optimized in most cases.

Methods

This case series is a retrospective analysis of CTPV with Jak 2 Positive MPN patients having follow-up at Adera Medical center, Addis Ababa, Ethiopia. All patients with positive JAK2V617F mutation alongside CT or ultrasound diagnosis of chronic portal vein thrombosis were enrolled into this case series. Complete sociodemographic, clinical, biochemical, pathological, and endoscopic values were collected from patient charts.

Case Presentation

Case I

A 51-year-old male presented to our outpatient department (OPD) with a three-year history of progressive abdominal distention with recent worsening. He also complains of intermittent abdominal pain and tenesmus with associated bright red per rectal bleeding. For these complaints, he was put on diuretics therapy by primary care physicians. On physical examination, he had a mildly pale conjunctiva. Abdominal examination revealed a protuberant abdomen with shifting dullness and a reducible umbilical hernia along with a ballotable spleen. Bilateral pedal and pretibial edema were also appreciated. Investigations revealed; leukocytosis (White Blood Cell count (WBC) of 21,900/l), mild anemia (Hemoglobin (Hgb) – 11.4 gm/dl), and Platelet (PLT) – 416,000/l), moderate hypoalbuminemia (Albumin- 2.1gm/dl). Ultrasound examination of the abdomen identified splenomegaly with ascites, otherwise, normal liver parenchyma. CT Scan further identified Portal hypertension with intra-abdominal collaterals (periportal, peri gastric, and splenorenal) secondary to chronic Portal vein thrombosis (Figure 1), alongside cholelithiasis, umbilical hernia, and bilateral pleural effusion. The liver vascular study indicated that the portal vein has a normal caliber with a patent lumen having a monophasic spectral pattern and peak velocity of Portal vein (V peak) was 6.2cm/s. Histologic evaluation of the liver was unremarkable for cirrhosis (Figures 2 and 3). The endoscopic evaluation revealed Grade II esophageal varices with no red color sign. Diagnostic paracentesis showed Serum Ascites Albumin gradients (SAAG) of 1.2 with a cell count of 1400/l (Neutrophil-72.7% and lymphocyte-27.3%). It was negative for Acid-fast Bacilli.

Bone marrow biopsy was non-revealing; however, he was positive for Jak 2 mutation test.

With the diagnosis of non-cirrhotic portal hypertension secondary to extra-hepatic portal vein obstruction secondary to Jak 2 positive MPN with Portal hypertension (PHTN) complications (Spontaneous bacterial peritonitis (SBP), Esophageal varices (EVs), and Ascites) the patient was treated for SBP, diuretics optimized, beta blocker initiated. Anticoagulation with warfarin was instituted upon discharge. Two weeks after the initiation of warfarin the patient

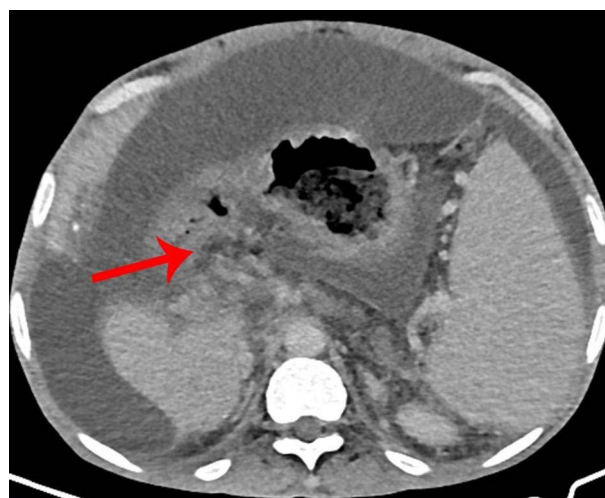


Figure 1 Collateral Portal Vessels are seen at the hilum of the liver in a 51-year-old male CTPV patient (NB: the red arrow shows several collateral portal vessels).

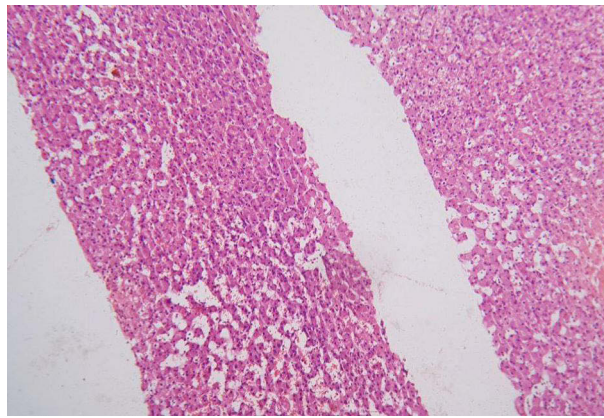


Figure 2 Normal Liver histology in 51-year-old male CTPV patient showing no fibrosis (seen at 100 × magnification).

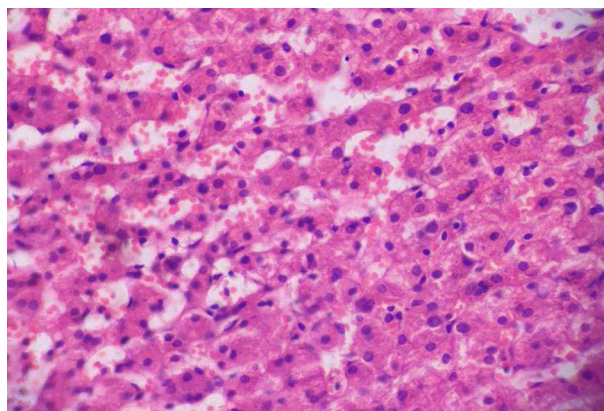


Figure 3 Normal Liver histology in 51-year-old male CTPV patient showing no fibrosis (seen at 400× magnification).

presented with hematochezia with a supra-therapeutic INR of 6. Warfarin was then discontinued and the patient was put on Peroral (PO) vitamin K, after which the bleeding subsided. Warfarin was then reinitiated 6 weeks later with a lower dose. He is currently stable and under follow-up.

Case 2

A 35 years old male patient presented five years back to our OPD with a one-month history of left upper quadrant abdominal pain. Physical examinations were unremarkable. Abdominal ultrasound revealed normal sized liver with a normal echo pattern with splenomegaly and chronic portal vein thrombosis. Endoscopy revealed esophageal varices. JAK 2 mutation was positive. He was not started on anticoagulation. He was then lost to follow-up for the past four years.

Six months back he presented to the emergency department with episodes of coffee ground vomiting and passage of tarry stool of three days duration. Associated with this, he has fatigue and light-headedness of the same duration. On physical examination, the vital signs were; BP=100/65 mmHg, PR = 81bpm, RR = 18breath/minute, SpO₂ = 94% on atmospheric oxygen and T^o =36.3°C. He has a mildly pale conjunctiva. The spleen is palpable 5cm from the left lower costal margin along the line of growth. Dark red fecal material was appreciated per rectal examination. Blood cell count at presentation was; WBC = 18,000/l with Neutrophil (Neut.) = 84%, Hgb=16gm/dl, and PLT-404,000/l. Subsequently, the Hgb dropped to 7.6 gm/dl due to the ongoing bleeding. Bone marrow was normocellular for age with trilineage hematopoiesis and a mild increase in megakaryocytopoiesis (Figure 4).

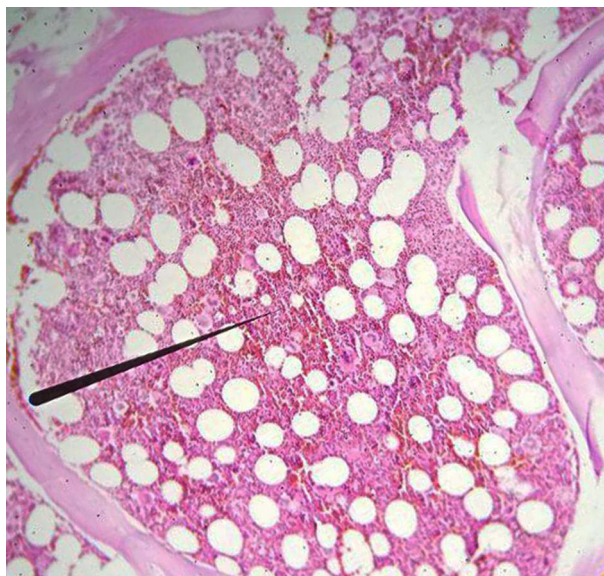

Figure 4 Normal bone marrow histology with trilineage hematopoiesis seen in a 35-year-old male CTPV patient showing no fibrosis (seen at 100 × magnification) (NB: the black pointer is an artifact).

Upon ultrasound examination, peri-portal fibrosis with massive splenomegaly and chronic PV thrombosis was visualized. Endoscopic revealed multiple big tortuous lower two-third bleeding varices, with mosaic gastric mucosa. Immediate esophageal variceal ligation was done and hemostasis of bleeding varices was achieved. Considering high-risk polycythemia vera as the underlying prothrombotic disease treatment with warfarin and hydroxyurea was initiated alongside propranolol.

Five months later, he presented with coffee-ground vomitus and a dark tarry stool. At presentation, he was hypotensive (80–90/60 mmHg) and tachycardia (PR- 120–150 bpm). His respiratory rate and saturation were normal. ECG revealed sinus tachycardia. His INR was in the therapeutic range (1.34). His hemoglobin, at presentation, was 10 gm/dl which later drops to 7.6 gm/dl due to the ongoing blood loss. During his stay, he was transfused with 3 units of packed RBC (PRBC). His hemoglobin showed improvement (9.6 gm/dl). The endoscopic evaluation revealed actively bleeding fundal varices with dark red clotted blood in the fundus of the stomach. Warfarin was discontinued. Cyanoacrylate glue injection of the fundal varices was performed and hemostasis of bleeding varices was achieved. The patient was then admitted to the ward and closely monitored.

He was discharged with oral medications (pantoprazole and propranolol). Warfarin was resumed later on. He is currently stable with symptomatic improvement.

Case 3

A 35 years old male patient presented with a one-month history of abdominal discomfort. Upon evaluation, he has a mildly pale conjunctiva. Abdominal examination revealed an enlarged spleen measuring 6 cm from the left lower costal margin along the line of growth. Serological and hematological investigations were all in the normal range except for raised bilirubin (TB –1.9 mg/dl, DB-0.4 mg/dl).

On ultrasound examination, the liver was normal-sized with normal homogenous echotexture. Spleen was enlarged (20.3cm) with periportal collaterals. The endoscopic evaluation revealed grade III EV with a red color sign and white nipple sign.

Prophylactic Esophageal Variceal Ligation (EVL) was done; the patient was admitted for close follow-up. Upon discharge, he was started on propranolol and linked to a hematology clinic. He was found to have JAK 2 mutation and was started on anticoagulation (warfarin).

He was admitted once for upper gastrointestinal bleeding (UGIB) 5 months after the commencement of warfarin, for which emergency EVL was done. The patient was discharged upon improvement. On his last follow-up, the patient was relatively well and his vitals are all in the normal range.

Case 4

A 29 years old known male polycythemia-vera patient on treatment (hydroxyurea and warfarin) who developed cortical visual loss secondary to retinal vein thrombosis (5 years back) and cavernous sinus thrombosis (3 years back) presented to the OPD with a 4-day history of crampy abdominal pain. Upon evaluation, his vitals were stable and his physical examination was remarkable for visual loss.

Laboratory studies were all in the normal range. CT scan showed chronic portal vein thrombosis. The endoscopic evaluation identified multiple columns of tortuous non-bleeding varices with red spots on the distal third of the esophagus with gastric mucosal changes consistent with portal hypertensive gastropathy (PHG).

Prophylactic EVL was done and the patient was admitted for close follow-up. He was started on propranolol, and other medications continued. He currently underwent 3rd cycle of EVL and is stable.

Case 5

A 53-year-old female patient presented to the emergency department with a history of vomiting of ingested matter and passage of dark tarry stool of one-day duration with associated abdominal pain. At presentation, her vital signs were stable. Physical examination revealed mild pallor and an enlarged spleen (5cm below the left costal margin).

Her investigations revealed a leukocytosis of 17, 500/l (neutrophil - 85.5%), moderate anemia (10.5 gm/dl) with a platelet count of 325,000/l and raised bilirubin (TB-2.9mg/dL DB-0.98mg/dL). Otherwise, laboratory studies were all in the normal range. Abdominal ultrasound identified normal-sized liver and normal liver echo pattern with splenomegaly (23.4cm) secondary to portal hypertension secondary to chronic portal vein thrombosis. The endoscopic evaluation revealed grade three esophageal varices without red spots and PHG. EVL was done and the patient was started on propranolol. On follow-up visits, the patient had consistent leukocytosis ranging from 16,300/l–26,200/l without any sign of infection. Her hemoglobin ranged from 11.8 gm/dl – 13.8 gm/dl, while her platelet count ranged 183,000/l–243,000/l. Thus, the patient was linked to a hematologist for further workup and management. Peripheral morphology revealed leukocytosis mainly of band cells and neutrophils and a few basophils. The patient refused BM examination. Jak 2 mutation screening turned out to be positive, BCR-ABL was not done for financial reasons. Hence, with diagnosis of JAK2-positive MPN, the patient was started on Hydroxyurea and warfarin. She, later on, had a smooth course except that she discontinued medications for social reasons two times and experienced episodes of UGIB which required EVL. She currently is adherent to her medications and her symptoms are well controlled.

Case 6

A 32 years old female known Non-Cirrhotic Portal hypertension patient on propranolol presented to our OPD with worsening abdominal discomfort and associated fatigue. She had taken praziquantel for the diagnosis of hepatosplenic schistosomiasis at another center (empirical treatment). Physical examination was remarkable for splenomegaly (10cm BLCM). WBC was 5300/l (66% neutrophil), Hgb – 14.3 gm/dl, PLT – 287, 000/l, MCV – 77.3fL, MCH – 25.5pg. Other laboratory studies were normal. The stool examination was negative for schistosomiasis. Ultrasound evaluation of the abdomen showed the liver has a normal echo pattern and smooth contour with splenomegaly (21.4cm), and periportal collaterals. The peak velocity of the portal vein was 10.1cm/s (normal 20 cm/sec - 40 cm/sec). Further evaluation with CT revealed chronic portal vein thrombosis with cavernous transformation. She was positive for JAK 2 mutation. Endoscopy evaluation revealed grade III esophageal varices and gastric changes consistent with portal hypertension gastropathy. Prophylactic EVL was done and she was started on propranolol, PO iron supplementation, and warfarin. She is on follow-up at Gastrointestinal (GI) and hematology clinics. She has symptomatic improvement on subsequent follow-ups.

Case 7

A 32-year-old female patient presented to our OPD with a history of left-side abdominal discomfort and bloating sensation of 3 months duration. Physical examination was unremarkable. On further history, she claimed that she was told to have an intraabdominal blood clot elsewhere around 2 years back after presenting with a similar complaint. She was by then started on anticoagulation with warfarin, discontinued it after 6 months (physicians' decision), and was off anticoagulation for the last 1 year. Laboratory investigation revealed raised Bilirubin (TB-1.6 mg/dl and DB-0.9 mg/dl). Other investigations were in the normal range. Ultrasound evaluation revealed liver has a normal echo pattern, while the Portal vein cavernous transformation with splenomegaly (16.5cm). Abdominal CT revealed chronic portal and spleno-mesenteric vein thrombosis with a cavernous transformation of PV and portal biliopathy. Three columns of distended tortuous esophageal varices (Grade III) with PHG were seen upon endoscopy. On our evaluation for the underlying cause, JAK 2 mutation turned positive. Prophylactic EVL was done. Propranolol and warfarin were resumed. She currently is stable with INR in the target.

Case 8

A 46 years old male patient, who is a known T2 diabetes mellitus (DM) (poorly controlled) patient over the last 5 years on glimepiride and metformin, was referred to our OPD after he presented with abdominal pain of one-week duration. Physical examination was unremarkable. Laboratory studies revealed ALP was four times raised (1143 IU), hypoalbuminemia (3.1 gm), and thrombocytosis (548, 000/l–684,000/l). His fasting blood level was in the range of 199–234 gm/dl. Otherwise, laboratory studies were in the normal range. On abdominal ultrasound, the liver has a homogenous echo pattern with smooth contours, the portal vein is obliterated with periportal collaterals, and the spleen is enlarged (15.8 cm). The endoscopic evaluation revealed multiple tense tortuous lower third varices with diffuse gastric mucosal congestion, for which EVL was done. The patient was admitted and glycemic control was optimized. Warfarin, propranolol, and diuretics were commenced upon discharge. Seven months after initiation of anticoagulation the patient presented with hematemesis and melena (last INR- not known then). At presentation, his vitals were stable. Physical examination was unremarkable. CBC was normal (WBC –9200/l (74.4%) Hgb –15.7gm/dl, PLT - 578,000/l). ALP was two times raised (84 IU). Warfarin was discontinued. Therapeutic EVL was done and the patient was discharged. Upon further evaluation abroad, JAK 2 mutation was identified. However, anticoagulation was not resumed.

Updated abdominal ultrasound revealed worsening of splenomegaly (16.7 cm). Abdominal CT identified chronic portal and spleno-mesenteric vein thrombosis (Figure 5) with cavernous transformation and splenomegaly with Portal hypertensive biliopathy (Figure 6). TB was raised (1.5 mg/dl –2.2 mg/dl). PLT was persistently elevated. Peripheral morphology revealed thrombocytosis. He has taken several sessions of prophylactic EVL. With the diagnosis of non-cirrhotic portal hypertension secondary to portal vein thrombosis secondary to high-risk PV, he was put on propranolol, hydroxyurea, and aspirin, with intermittent prophylactic sessions of EVL.

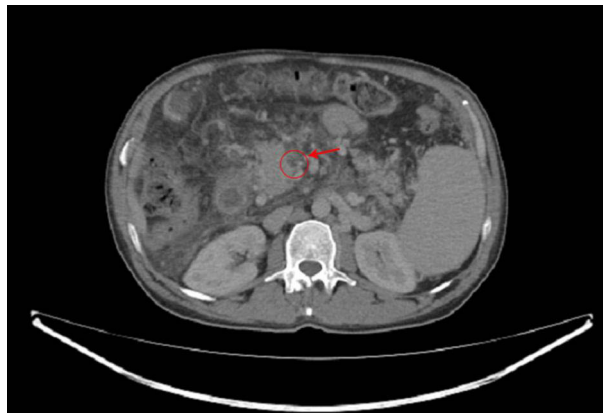


Figure 5 Contrast filling defect is seen at the main trunk of the superior mesenteric vein seen in a 46 years old male chronic Portal Vein Thrombosis patient (NB: the filling defect of the superior mesenteric vein is seen with in the red circle).

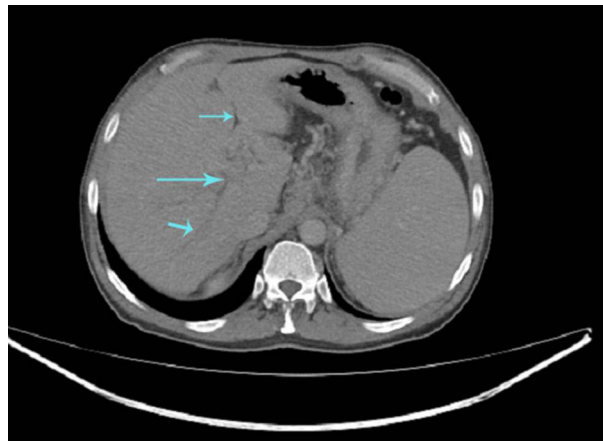


Figure 6 Dilated intrahepatic bile ducts secondary to Chronic occlusion of the portal vein seen in a 46 years old male chronic Portal Vein Thrombosis patient (NB: blue arrows indicate dilated intrahepatic bile ducts).

During the course of his treatment, he had several admissions for prophylactic and therapeutic EVL. Upon follow up his hematocrit level was significantly raised (52.9%) which necessitated two sessions of 1-unit phlebotomy, one month apart. His post-phlebotomy hematocrit level dropped to 48.1%. Currently, his symptoms are well controlled.

Case 9

A 27-year-old female patient presented to OPD with a history of stabbing type of abdominal pain 8 hours duration with associated two episodes of non-bloody vomiting of ingested matter and passage of loose stool. She claimed to have had a history of abdominal discomfort for the last one year. Upon presentation, vital signs were stable and physical examination was unremarkable. Laboratory studies were normal. Ultrasound examination revealed a normal echo pattern of the liver with splenomegaly secondary to portal hypertension secondary to chronic portal vein thrombosis. Further evaluation with CT confirmed this finding. Endoscopy evaluation revealed antral mucosal mottling with an inflamed and edematous duodenal bulb with a 2mm clean-based duodenal ulcer (Forrest class II). Jak 2 mutation test was positive. The patient was then started on propranolol and warfarin. She currently is doing fine within a target INR.

Case 10

A 35 years old female patient presented with a one-year history of abdominal discomfort, with a recent worsening of 2 weeks duration. Screening EGD was done 5 months back and grade 3 esophageal varices were seen. She was sent for EVL but she deferred endoscopic treatment. She was initially started on Aspirin with the diagnosis of acute portal vein thrombosis which later was discontinued after one month of treatment. She was put on propranolol for the past year. She has had no bleeding episodes in the past year. She was referred to our OPD for prophylactic variceal ligation. The coagulation profile was PTT –49.2 seconds, INR-1.35, and PT-16.9 seconds, otherwise, laboratory investigations were all normal. Abdominal ultrasound indicated normal-sized liver with normal echo pattern and peri portal collaterals. The spleen was enlarged (19.0 cm). Further imaging with CT revealed Chronic PVT with cavernous transformation and Portal biliopathy. Upper GI endoscopy revealed grade 3 esophageal varices with minimal bleeding which was ligated immediately. On workup for the underlying hypercoagulable state, JAK 2 mutation was detected. She was started on an anticoagulant rivaroxaban. Propranolol was resumed. She was discharged upon improvement. On her next, follow up the symptoms were controlled and stable.

Case Summary

We reported ten chronic PVT cases with Jak2-positive MPN as an underlying etiology (Table 1). The age ranges from 27 to 53 years with a median age of 35 years. The male-to-female ratio is 1:1. The commonest initial presentation in most patients is abdominal pain. Only two patients presented initially with upper GI bleeding. However, delay in treatment or

Table 1 Summary of Cases of Chronic Portal Vein Thrombosis Cases Secondary to JAK2 Positive MPN

		Case 1	Case 2	Case 3	Case 4	Case 5	Case 6	Case 7	Case 8	Case 9	Case 10
Age (years)		51	35	35	29	53	32	32	46	29	35
Sex		Male	Male	Male	Male	Female	Female	Female	Male	Female	Female
Initial presentation	Abdominal distension	Yes	No	No	No	No	No	No	No	No	No
	UGIB	No	No	No	No	Yes	No	No	Yes	No	No
	Abdominal pain	Yes	Yes	Yes	Yes	Yes	Yes	Yes	Yes	Yes	Yes
Physical Examination	Vital signs	Stable	Stable	Stable	Stable	Stable	Stable	Stable	Stable	Stable	Stable
	Abdomen	Protuberant abdomen Ballotable spleen	No	Splenomegaly	None	Splenomegaly	Splenomegaly	No	No	No	No
	Edema	Yes	No	No	No	No	No	No	No	No	No
WBC ($10^9/l$)		21.9	7.5	6.3	5.6	17.5	5.3	4.6	5.7	5.5	6.6
Neutrophil (%)		88.8	60	70	72.1	85.5	66	63	73	55.6	
Hemoglobin (gm/dl)		11.4 gm/dl	16	14.5	17.8	10.5	14.3	14.4	14	17.8	16
Hematocrit (%)		31.2	51.8	40.9	52	30.1	43.2	42.2	40.9	51.1	44
Platelet ($10^9/l$)		$416 \times 10^9/l$	233	289	285	325	287	459	204	236	411
Creatinine (gm /dl)		0.8 gm/dl	0.5	1.0	1.1	0.5	0.62	0.4	1.0	0.4	0.4
Aspartate Amino transferase (IU)		29 IU	30	29.9	42	33.5	34	35	41	23	31
Alanine Amino transferase (IU)		21 IU	31	26.2	30	10.8	62	26	44	29	23
Alkaline Phosphatase (IU)		131 IU	61	155	258	182	190	117	1143	57	105
Gamma-glutamyl Transferase (IU)		65	13	31	20	33	32	16.6	25	19	27
Total Bilirubin		0.9	1.0	1.9	1.1	2.9	1.6	1.6	0.96	0.7	1.1
Direct Bilirubin		0.1	0.1	0.4	0.3	0.98	0.9	0.9	0.18	0.1	0.3

Albumin(gm/dl)		2.1 gm/dl	4	4.16	4.4	3.5	4.3	3.9	3.1	4.9	4.5	
Viral Markersa		Negative	Negative	Negative	Negative	Negative	Negative	Negative	Negative	Negative	Negative	
Stool Exam for schistosomiasis		Negative	Negative	Negative	Negative	Negative	Negative	Negative	Negative	Negative	Negative	
Abdominal U/s	Liver echo pattern	Normal	Normal	Normal	Normal	Normal	Normal	Normal	Normal	Normal	Normal	
	Liver size(cm)	15.4	15.2	14.8	14.2	14	15.2	15	14.9	15.2	14.5	
	Spleen size (cm)	17.5	23.1	20.3	15.7	23.4	21.4	16.5	15.8	11.1	19	
	Portal vein	1.0	0.9	0.9	1.0	0.6	0.8	0.7	0.8	0.9	0.6	
	Peak velocity of portal vein (cm/s)	6.2	8.3	9.2	5.5	7.8	10.1	7.8	8.4	9.0	6.4	
	Collaterals	Yes	Yes	Yes	Yes	Yes	Yes	Yes	Yes	Yes	Yes	Yes
	Ascites	No	Yes	No	No	No	No	No	No	No	No	No
Abdominal CT	Biliopathy	No	No	Yes	No	No	No	Yes	Yes	No	Yes	
	Liver size and attenuation	Normal	Normal	Normal	Normal	Normal	Normal	Normal	Normal	Normal	Normal	
	Spleen size	Enlarged	Enlarged	Enlarged	Enlarged	Enlarged	Enlarged	Enlarged	Enlarged	Enlarged	Enlarged	
	Cavernoma	Yes	Yes	Yes	Yes	Yes	Yes	Yes	Yes	Yes	Yes	
	Superior Mesenteric vein Thrombosis	No	No	No	No	No	No	Yes	Yes	No	No	
	Ascites	No	No	No	No	No	No	No	No	No	No	

(Continued)

Table I (Continued).

		Case 1	Case 2	Case 3	Case 4	Case 5	Case 6	Case 7	Case 8	Case 9	Case 10
Endoscopy	Varices	Grade II	Grade II	Grade III	Grade III	Grade III	Grade III	Grade III	Grade III	No	Grade III
	Portal hypertensive gastropathy	Yes	Yes	Yes	Yes	Yes	Yes	Yes	Yes	No	Yes
	Other	Hemorrhoid	Hemorrhoid	No	No	No	No	No	No	Antral gastropathy	No
Liver Histology		Normal	Not done	Not done	Not done	Not done	Not done	Not done	Not done	Not done	Not done
Bone marrow histology		Normal	Trilineage hematopoiesis + mild megakaryocytopoiesis	Not done	Not done	Not done	Not done	Not done	Not done	Not done	Not done
Jak 2 V167 Mutation		Positive	Positive	Positive	Positive	Positive	Positive	Positive	Positive	Positive	Positive
Management	Propranolol	Yes	Yes	Yes	Yes	Yes	Yes	Yes	Yes	Yes	Yes
	Esophageal Variceal Ligation	No	Yes	Yes	Yes	Yes	Yes	Yes	Yes	No	Yes
	Anticoagulant	Warfarin	Warfarin	Warfarin	Warfarin	Warfarin	Warfarin	Warfarin	Warfarin	Warfarin	rivaroxaban
	Hydroxyurea	No	No	No	Hydroxyurea	Hydroxyurea	No	Yes	No	No	No
Duration of Treatment (months)		6	6	12	48	6	12	5	5	6	3
Delay in Diagnosis (months)		36	48	5	0	6	96	14	64	1	1

Note: ^aHBsAg/HBeAg/ HBsAb/ HCvAb.

late initiation of anticoagulation presentation with upper GI bleeding is frequent in most patients during follow-up. CBC was indicative of underlying pathology only in three patients (thrombocytosis, leukocytosis, and high hemoglobin). Peripheral morphology, as well as a histologic examination of the liver and bone marrow, were unremarkable in all of them. The MPN feature has completely differentiated into the subtypes (PV, ET, and/or MF) only in three of the patients. The rest has features of early Jak 2 + MPN. Concurrent splenic vein thrombosis was seen in two patients, while 4 patients have signs of cholangiopathy (increased bilirubin and/or CT diagnosis). Splenomegaly was present in 8 out of 9 patients. Only one patient presented early with a relatively normal clinical profile and is initiated early on treatment. There was a delay in diagnosis and treatment in most of them. Treatment with warfarin was immediately followed by upper GI bleeding in 5–7 months in four of the patients (only 1 had supra-therapeutic INR and she was not adherent to medication). Once multidisciplinary management is initiated the patient's conditions have improved in all of them.

Discussion

Our finding agrees with the previous reports which indicates CTPV patients with Jak 2 mutation are found to younger than the classic MPN patients. However, it differs from the previous reports of female predominance.^{7,8}

The main presenting symptoms of chronic EHPVO are signs of portal hypertension and cavernoma cholangiopathy, while 1/3rd of the cases are incidentally diagnosed during imaging studies for unrelated evaluation.⁴ Portal Hypertension (PHTN) manifests with esophageal/gastric varices, gastrointestinal bleeding, portal hypertensive gastropathy, ascites, and splenomegaly. Nine of our 10 cases had varices at presentation and variceal bleeding was the initial presenting symptom in half of them. This is higher than other reports of 15%.⁹ This may reflect the late presentation in our setup as the development of varices is a time-dependent phenomenon. Portal cavernoma cholangiopathy, which is due to pressure imparted by dilated collaterals on the bile ducts and the biliary tree, is symptomatic in only 21% of the patients.¹⁰ The symptoms include long-standing intermittent jaundice or biliary pain with or without cholangitis due to biliary stones. Consistent with this, four of our cases had evidence of cavernoma cholangiopathy on imaging but none of them were symptomatic.

In six of the ten cases, CBC did not show a classical MPN phenotype. This is consistent with previous findings of the absence of typical MPN features at presentation in Jak 2 positive cases of chronic PVT. One retrospective analysis of a case series of 14 patients presenting with splanchnic vein thrombosis based on underlying JAK2 V617F positive MPN has reported a normal presenting CBC & an absence of meeting the diagnostic criteria for one of the MPNs in 42.8% of the analyzed cases.⁷ Another report showed JAK2 positivity in 15.4% of PVT patients without characteristic hematologic features of MPNs.¹¹ Several reasons have been suggested to account for this including; hypersplenism, hemodilution related to portal hypertension, and/or iron deficiency related to blood loss. In these patients, qualitative changes in the blood cells, secretion of inflammatory cytokines, expression of adhesion molecules, and upregulation of endothelial adhesion receptors contribute to the increased risk of thrombosis to a different extent.¹² Our findings substantiate the recommendations of JAK2V617F screening for all Superior mesenteric vein thrombosis (SVT) patients, regardless of the absence of MPN hallmarks, such as elevated peripheral blood cell counts.

The treatment of MPN-associated PVT is complex and needs a multidisciplinary approach. Treatment strategies include anticoagulation, cytoreduction, management of portal hypertension through trans jugular intrahepatic portosystemic shunts (TIPS), and cirrhosis with liver transplant. Anticoagulation is the cornerstone of MPN-associated PVT management once varices are controlled with beta-blocker therapy or by endoscopy. Evidence shows that anticoagulation prevents recurrent thrombosis in SVT-associated MPN. One report showed that Vitamin K-antagonists (VKA) decrease recurrence risk by half (OR 0.48), while another study showed a recurrence per 100 patient-years with VKA versus without VKA of 3.7 (95% CI: 2.3–5.5) versus 7.2 (95% CI: 3.1–14.3), respectively ($p = 0.09$).^{13,14} We used anticoagulation with warfarin in all of our patients after screening for and controlling varices. Four of our cases experienced GI bleeding during anticoagulation therapy, with 2 of the patients experiencing the bleeding while INR was on target. Studies have shown EVs to be the only independent predictors of major bleeding (OR 17.4) and that VKA is not associated with increased overall or gastrointestinal bleeding among MPN-SVT patients.^{13,15} In consistent with this, all of our patients who experienced bleeding during AC had EVs. Though we used warfarin in all of our patients' newer data showing the effectiveness and safety of Direct oral anticoagulants (DOACs) in non-cirrhotic PVT is coming which may make them the agents of choice in this setup in the future.¹⁶

Molecular profiling can help identify high-risk patients with dismal outcome.¹⁷ Cytoreduction therapy is an important treatment strategy in these patients and the current guidelines from European LeukemiaNet (ELN) and National Comprehensive Cancer Network (NCCN) recommend, hydroxyurea (HU) or pegylated interferon alpha as the first-line therapies for cytoreduction in ET and PV. However, the benefit of cytoreductive therapy in SVT has been questioned after a recent study failed to show a positive effect of hydroxyurea in preventing recurrent SVT.¹⁸ The authors hypothesized that hyperthermia plays less role in the pathogenesis of thrombosis in these sights and so that cytoreduction could be less crucial. The ultimate recommendation from this study was only to use HU in the presence of hypercythemia or progressive disease. Accordingly, we used HU in only the patients with hypercythemia.

Conclusion

Complications of CTPV might be the first presenting symptoms in patients with BCR-ABL negative MPNs. The asymptomatic presentations, the relatively normal laboratory investigations, as well as the need for multidisciplinary treatment, impart diagnostic and therapeutic challenges in the sub-Saharan region. Thus, a high index of suspicion is mandatory for early identification and treatment of these cases before the development of complications.

Ethical Statement

The study was approved by the research ethics committee of Adera Medical Center. Consent to publish the cases and accompanying images has been obtained from all patients. The research is conducted in accordance with the Declaration of Helsinki.

Acknowledgments

We would like to extend our deepest thanks to the patients, their families, and our dear colleagues who participated in the care of the patients.

Disclosure

The authors report no conflicts of interest in this work.

References

1. De Gaetano AM, Lafortune M, Patriquin H, De Franco A, Aubin B, Paradis K. Cavernous transformation of the portal vein: patterns of intrahepatic and splanchnic collateral circulation detected with Doppler sonography. *Am J Roentgenol.* 2013;165(5):1151–1155. doi:10.2214/AJR.165.5.7572494
2. Wei B, Huang Z, Tang C. Optimal treatment for patients with cavernous transformation of the portal vein. *Front Med.* 2022;9:657. doi:10.3389/FMED.2022.853138/BIBTEX
3. Kelliher S, Falanga A. Thrombosis in myeloproliferative neoplasms: a clinical and pathophysiological perspective. *Thrombosis Update.* 2021;5:100081. doi:10.1016/J.TRU.2021.100081
4. Elkrief L, Houssel-Debry P, Ackermann O, et al. Portal cavernoma or chronic non cirrhotic extrahepatic portal vein obstruction. *Clin Res Hepatol Gastroenterol.* 2020;44(4):491–496. doi:10.1016/J.CLINRE.2020.03.016
5. Garcia-Pagán JC, Buscarini E, Janssen HLA, et al. EASL clinical practice guidelines: vascular diseases of the liver. *J Hepatol.* 2016;64(1):179–202. doi:10.1016/j.jhep.2015.07.040
6. Hajdu CH, Murakami T, Diffo T, et al. Intrahepatic portal cavernoma as an indication for liver transplantation. *Liver Transplant.* 2007;13(9):1312–1316. doi:10.1002/LT.21243
7. Greenfield G, McMullin MF. Splanchnic venous thrombosis in JAK2 V617F mutation positive myeloproliferative neoplasms - long term follow-up of a regional case series. *Thromb J.* 2018;16(1):33. doi:10.1186/s12959-018-0187-z
8. How J, Trinkaus KM, Oh ST. Distinct clinical, laboratory and molecular features of myeloproliferative neoplasm patients with splanchnic vein thrombosis. *Br J Haematol.* 2018;183(2):310–313. doi:10.1111/bjh.14958
9. Noronha Ferreira C, Marinho RT, Cortez-Pinto H, et al. Incidence, predictive factors and clinical significance of development of portal vein thrombosis in cirrhosis: a prospective study. *Liver Int.* 2019;39(8):1459–1467. doi:10.1111/liv.14121
10. Dhiman RK, Saraswat VA, Valla DC, et al. Portal cavernoma cholangiopathy: consensus statement of a working party of the Indian National Association for study of the liver. *J Clin Exp Hepatol.* 2014;4(Suppl 1):S2. doi:10.1016/J.JCEH.2014.02.003
11. Smalberg JH, Arends LR, Valla DC, Kiladjian JJ, Janssen HLA, Leebeek FWG. Myeloproliferative neoplasms in Budd-Chiari syndrome and portal vein thrombosis: a meta-analysis. *Blood.* 2012;120(25):4921–4928. doi:10.1182/blood-2011-09-376517
12. Barbui T, Finazzi G, Falanga A. Myeloproliferative neoplasms and thrombosis. *Blood.* 2013;122(13):2176–2184. doi:10.1182/BLOOD-2013-03-460154
13. Sedhom WG, Stein BL. Anticoagulation for splanchnic vein thrombosis in myeloproliferative neoplasms: the drug and the duration. *Hemato.* 2021;2(2):255–263. doi:10.3390/hemato2020015

14. de Stefano V, Vannucchi AM, Ruggeri M, et al. Splanchnic vein thrombosis in myeloproliferative neoplasms: risk factors for recurrences in a cohort of 181 patients. *Blood Cancer J.* 2016;6(11):e493–e493. doi:10.1038/bcj.2016.103
15. Riva N, Ageno W, Poli D, et al. Safety of vitamin K antagonist treatment for splanchnic vein thrombosis: a multicenter cohort study. *J Thrombosis Haemostasis.* 2015;13(6):1019–1027. doi:10.1111/jth.12930
16. Naymagon L, Tremblay D, Zubizarreta N, et al. The efficacy and safety of direct oral anticoagulants in noncirrhotic portal vein thrombosis. *Blood Adv.* 2020;4(4):655–666. doi:10.1182/bloodadvances.2019001310
17. Debureau PE, Cassinat B, Soret-Dulphy J, et al. Molecular profiling and risk classification of patients with myeloproliferative neoplasms and splanchnic vein thromboses. *Blood Adv.* 2020;4(15):3708–3715. doi:10.1182/BLOODADVANCES.2020002414
18. de Stefano V, Rossi E, Carobbio A, et al. Hydroxyurea prevents arterial and late venous thrombotic recurrences in patients with myeloproliferative neoplasms but fails in the splanchnic venous district. Pooled analysis of 1500 cases. *Blood Cancer J.* 2018;8(11). doi:10.1038/s41408-018-0151-y

International Medical Case Reports Journal

Dovepress

Publish your work in this journal

The International Medical Case Reports Journal is an international, peer-reviewed open-access journal publishing original case reports from all medical specialties. Previously unpublished medical posters are also accepted relating to any area of clinical or preclinical science. Submissions should not normally exceed 2,000 words or 4 published pages including figures, diagrams and references. The manuscript management system is completely online and includes a very quick and fair peer-review system, which is all easy to use. Visit <http://www.dovepress.com/testimonials.php> to read real quotes from published authors.

Submit your manuscript here: <https://www.dovepress.com/international-medical-case-reports-journal-journal>