

Received: 2014.05.06
Accepted: 2014.05.06
Published: 2014.09.13

Usefulness of Magnetic Resonance Imaging as a Prognostic Variable in Myelodysplastic Syndromes

Authors' Contribution:
Study Design A
Data Collection B
Statistical Analysis C
Data Interpretation D
Manuscript Preparation E
Literature Search F
Funds Collection G

ABCDF 1,2 **Ewa Ziółko**
ABCDEF 1,2 **Anna Kwiatkowska-Pamuła**
ADEF 3 **Tomasz Adamczyk**
CD 4 **Jerzy Walecki**
CD 1 **Małgorzata Muc-Wierzoń**

1 Clinical Department of Internal Diseases, Silesian Medical University, Bytom, Poland
2 Department of Hematology, Silesian Medical University, Bytom, Poland
3 Magnetic Resonance Unit, Medical Diagnostic Centre Voxel, Bytom, Poland
4 Institute of Experimental and Clinical Medicine, M. Mossakowski Polish Academy of Sciences, Warsaw, Poland

Corresponding Author: Tomasz Adamczyk, e-mail: t.adamczyk@voxel.pl
Source of support: Departmental sources

Background: Myelodysplastic syndromes are clonal disorders of stem cells, characterized by heterogeneous clinical presentation. Hematopoiesis is ineffective, characterized by abnormal differentiation, maturation and survival of hematopoietic cells.





Material/Methods: The examinations were conducted in the Hematology Ward and the Internal Medicine Ward of the Specialist Hospital No. 1 in Bytom in the years 2006–2011. The study group included 53 patients with diagnosed myelodysplastic syndrome. The results of magnetic resonance imaging (MRI) of the spine were obtained from the medical documentation of patients.

Results: In the group of patients diagnosed with RT (refractory thrombocytopenia) and in the group diagnosed with RA (refractory anemia), 100% of lumbar spine images in T1- and T2-weighted sequences assessed together showed increased signal intensity. In patients diagnosed with RAEB (refractory anemia with excess blasts), MRI showed decreased signal intensity in 76.5% of subjects in the sequences analyzed together. In the group of patients with increased LDH (lactate dehydrogenase), 22 patients (55%) showed decreased signal intensity in the combined analysis of T1- and T2-weighted sequences. Among transfusion-dependent patients, 20 scans (60.6%) showed decreased signal intensity.

Conclusions: As the risk category of MDS increases towards high – bad risk, decreased signal intensity is observed in lumbar spine MRI in T1- and T2-weighted images in all studied stratification scales. There is a positive correlation between decreased signal intensity in lumbar spine MRI examinations and increased LDH level in blood serum, as well as dependence on blood product transfusions, especially packed red blood cells.

MeSH Keywords: **Bone Marrow • Magnetic Resonance Imaging • Myelodysplastic Syndromes**

Full-text PDF: <http://www.medscimonit.com/abstract/index/idArt/890978>

 2649  —  6  43



Background

Myelodysplastic syndromes (MDS) are clonal disorders of stem cells, characterized by heterogeneous clinical presentation. Hematopoiesis in myelodysplastic syndrome is ineffective, characterized by abnormal differentiation, maturation, and survival of hematopoietic cells [1–4]. Characteristic features of myelodysplastic syndrome include dysplasia of cell lines (which is manifested by disorders of maturation) and differentiation visible in bone marrow images and peripheral blood smears, as well as dysplasia causing the non-uniform appearance of cells being on the same level of development and their architectural abnormalities [5,6]. The risk of transformation into acute myeloid leukemia is an important aspect of the course of MDS [7,8].

Chromosomal aberrations are detected in 40–70% of patients with primary MDS and 80–95% of patients with secondary MDS. Unbalanced chromosomal aberrations, which are not pathognomonic for MDS and occur also in acute myeloid leukemias, prevail [5].

Studies have proved the role of angiogenesis in the development of solid tumors, hematological malignancies, and myelodysplastic syndromes. A much higher capillary density was detected in bone marrow trephine biopsies of patients with diagnosed myelodysplastic syndromes than in biopsy specimens of patients not affected by these disease entities [9–11].

Factors contributing to the occurrence of myelodysplastic syndrome are numerous chemical substances like benzene, toluene, herbicides, pesticides, tobacco smoke, hair dyes, silica fume, and heavy metal compounds [12,13]. Cytostatic drugs such as alkylating, topoisomerase II inhibitors, purine analogues, and hydroxycarbamides, as well as physical factors in the form of ionizing radiation, may also cause the disease [12,13]. The studies confirmed cases of disease occurrence among family members [14,15].

The MDS classification system proposed in 2008 by the WHO (World Health Organization) takes into account the median survival of patients and the incidence of transformation to acute myeloid leukemia. This classification distinguished 4 entities: refractory cytopenias with a single dysplasia (RA – refractory anemia, RN – refractory neutropenia, RT – refractory thrombocytopenia), refractory anemia with ringed sideroblasts present (RARS), refractory cytopenia with multilineage dysplasia (RCMD), and refractory anemia with excess blasts (RAEB1 and RAEB2), where the criterion for the diagnosis is the presence of 10% or more blast cells in the bone marrow [7].

Magnetic resonance imaging (MRI) uses signal changes in sequences dependent on time constants for particular tissue

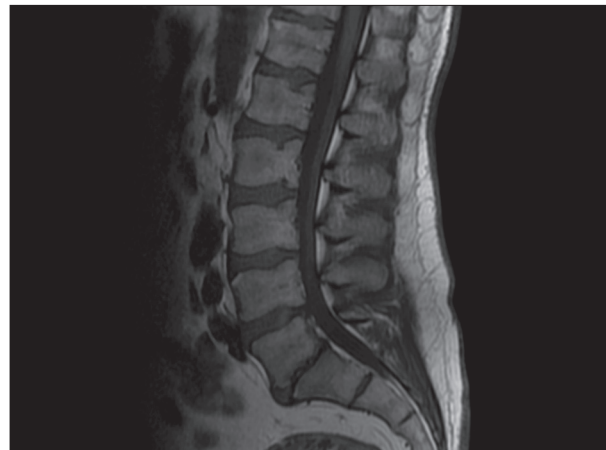


Figure 1. T1-weighted magnetic resonance scan obtained in sagittal plane in patient without hematological disorders.

structures to generate images, thus making it possible to assess soft tissues [16], fluid structures, and adipose tissue remodeling. Because this method also allows us to locate and analyze infiltrative and nodular lesions in the spinal canal area [17–21], it is useful in hematology and oncology. The ability of MRI to assess bone marrow and determine its remodeling in proliferative diseases caused it to become the only imaging method for diagnosing hematological diseases.

MRI of bone marrow is based on detecting the difference between signal intensities of adipose tissue and water, which are components of yellow and red marrow [22,23]. Hematopoietic elements constitute 60% of the cellular composition of red bone marrow, while adipocytes account for as much as 95% of all yellow bone marrow cells [24]. Water constitutes approximately 15% of yellow marrow and 40% of red marrow content, while adipose tissue accounts for approximately 80% of yellow bone marrow and 40% of red bone marrow content. This structure is best visualized in spin echo sequences and selective fat saturation sequences [24,25]. In T1-weighted spin echo sequences, which are most often used in bone marrow imaging, adipose tissue of yellow bone marrow has signal intensity similar to that of subcutaneous adipose tissue, while red bone marrow (containing more water) is hypointense in comparison with yellow bone marrow. Imaging also makes use of the relation of the hyperintensity of red marrow signals to these of muscle tissue [23,24,26]. Figure 1 illustrates the images described. In T2-weighted sequences, tissues containing more water show higher signal intensity than the less hydrated ones [25]. In the T2-weighted sequence, just like in the T1-weighted one, the intensity of yellow bone marrow image resembles that of subcutaneous adipose tissue and the signal intensity of red bone marrow is higher than in the T1-weighted sequence and similar to the intensity of yellow bone marrow [23]. The changes are illustrated in Figure 2. The T2-weighted

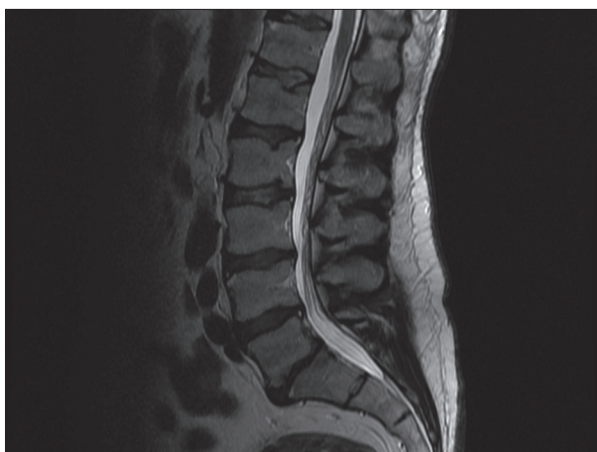

Figure 2. T2-weighted magnetic resonance scan obtained in sagittal plane in patient without hematological disorders.

sequence is less useful in assessing bone marrow pathologies because differences between relaxation times of yellow and red bone marrow are smaller, differences between signal intensities are less significant, and ability to diagnose infiltrative lesions is worse [25]. Remodeling and infiltration of bone marrow visible in MRI are detectable earlier than lesions visualized in conventional radiographs.

The aim of the present study was to assess the relationship between MRI of the lumbar spine and clinical signs of disease in patients diagnosed with myelodysplastic syndrome, prognostic variables, and certain risk categories for survival and AML transformation in the scale of stratification based on IPSS.

Material and Methods

The examinations were conducted in the Hematology Ward and the Internal Medicine Ward of the Specialist Hospital No. 1 in Bytom in the years 2006–2011. The study group included 53 patients with diagnosed myelodysplastic syndrome in different stages of the disease. The study consisted of patients aged 50–77 years, including 22 women (41.5%) and 31 men (58.5%). Patients were divided into subgroups according to the diagnosed type of myelodysplastic syndrome. There were no significant differences between the groups in terms of sex or age.

Based on the medical records of patients, the disease was classified in accordance with the WHO standards. The prognosis with regard to survival time and the possibility of transformation into AML were assessed using the prognostic classifications of the IPSS (International Prognostic Scoring System). The analysis was based on the results of bone marrow aspiration, peripheral blood count with the evaluation of leukogram (or

peripheral blood smear), LDH (lactate dehydrogenase) values, and dependence on blood product transfusions.

The results of MRI of the spine were obtained from the medical documentation of patients. These examinations were performed during hospitalization or on an outpatient basis. In 27 patients (50.9%) examinations were performed during a stay at the Department of Hematology, Department of Internal and Specialist Hospital No. 1 in Bytom. Indication for MRI in 9 patients (33.3%) was suspicious for neoplastic infiltration within the lumbar spine, while in 18 patients (66.7%) there was suspicion of pathological fracture in this region. All patients presented pain and associated neurological symptoms. In the outpatient group, which included 26 patients (49.1%), 18 patients (69.2%) underwent MRI at the request of a neurologist, 6 (23.1%) at the request of an orthopedist, and 2 (7.7%) at the request of a GP.

MRI scans of the lumbar spine were performed in the “Voxel” Magnetic Resonance Laboratory in the Specialist Hospital No. 1 in Bytom with a 1.5 T GE SIGNA LX HS and SIGNA EXCITE scanners using a dedicated quadrature coil. Fast spin echo (FSE), fast recovery fast spin echo (frFSE), and fast recovery fast spin echo with fat saturation (frFSE+fs) sequences were used to obtain T1- and T2-weighted images in sagittal, transverse, and frontal planes. T1- and T2-weighted images in sagittal, transverse, and frontal planes were analyzed for all patients (100%). Signal intensity and homogeneity in the studied sequences were assessed. Regions of interest (ROIs) comprising vertebral bodies with the exclusion of endplates were specified to calculate relative signal intensity.

The obtained results were collected in an Excel spreadsheet and then exported to STATISTICA, where statistical calculations were made. Mean values and standard deviation of age were calculated for patients in the subgroups studied. Because the distribution did not comply with the normal character, a non-parametric Mann-Whitney U test was used to make comparisons between the subgroups. The frequency of signals in MRI examinations was calculated depending on the factors studied. The obtained frequencies were compared using a chi-square test. $P < 0.05$ was assumed to be statistically significant.

The study was designed as a retrospective analysis.

All subjects provided written informed consent for the MRI examination.

Results

The study included 53 patients aged 50–77 years (mean age 65.4 ± 6.9) including 22 (41.5%) women and 31 (58.5%) men.

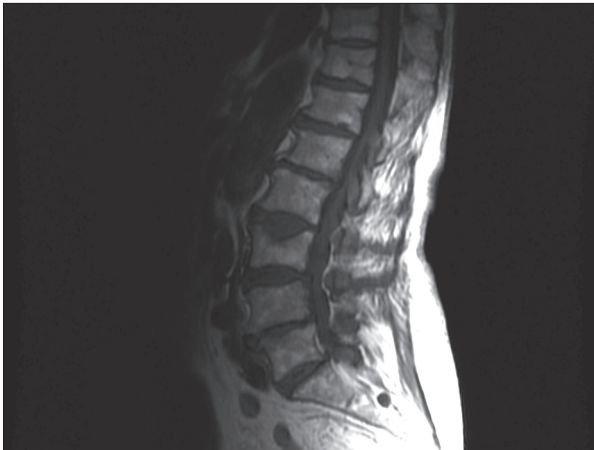

Figure 3. T1-weighted magnetic resonance scan obtained in sagittal plane in patient diagnosed with the RA subtype of myelodysplastic syndrome.

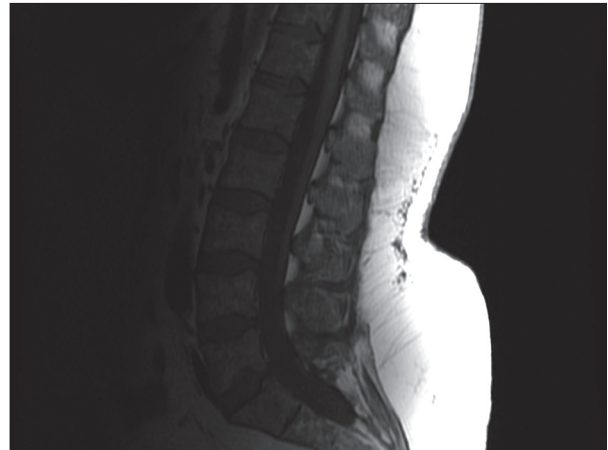


Figure 5. T1-weighted magnetic resonance scan obtained in sagittal plane in patient diagnosed with the RAEB subtype of myelodysplastic syndrome.

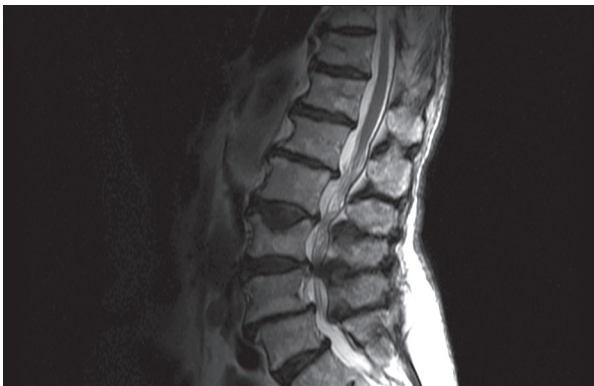

Figure 4. T2-weighted magnetic resonance scan obtained in sagittal plane in patient diagnosed with the RA subtype of myelodysplastic syndrome.

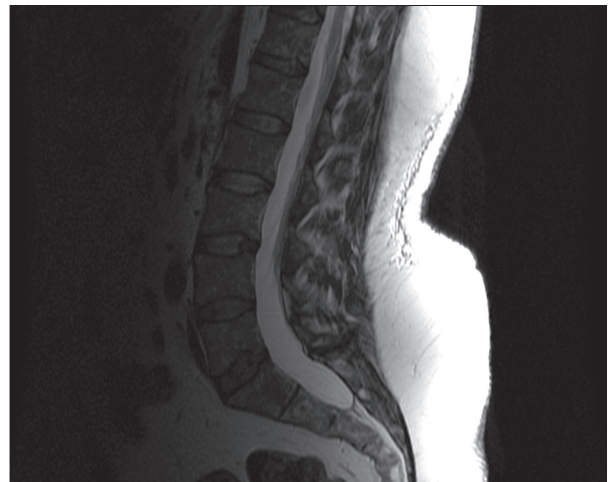


Figure 6. T2-weighted magnetic resonance scan obtained in sagittal plane in patient diagnosed with the RAEB subtype of myelodysplastic syndrome.

In the study group, patients with diagnosed RAEB (I, II) constituted the largest group of 17 individuals (32.1%), followed by 16 patients (30.2%) with diagnosed RCMD, 11 individuals (20.7%) with refractory thrombocytopenia, and 9 patients (17.0%) with RA subtype.

In the MRI scan of the lumbar spine using T1-weighted sequence, the reduction of the signal intensity was observed in 22 patients (41.5%). The increase in signal intensity occurred in 23 patients (43.4%) and non-uniform signal intensity was observed in 8 patients (15.1%).

In T2-weighted sequence, increased signal intensity was observed in 23 patients (43.4%), reduced signal intensity was observed in 21 patients (39.6%), and non-uniform signal intensity was observed in 9 patients (17.0%).

Images in T1- and T2-weighted sequences were analyzed together. In doubtful cases, when decreased signal intensity

was obtained in one sequence but the other showed heterogeneous signal intensity, all images acquired during MRI examinations of the patient were analyzed 1 more time to get the final classification.

Increased signal intensity was seen in 11 patients (20.7%) with a diagnosed RT and 9 patients (17.0%) with a diagnosed RA, and 100% of lumbar spine images in T1- and T2-weighted sequences assessed together (Figures 3 and 4). Among 16 patients (30.2%) diagnosed with RCMD, decreased signal intensity was observed in 7 (43.8%), increased signal intensity in 3 (18.7%), and heterogeneous signal integrity in 6 (37.5%). In the group with RAEB – 7 patients (32.1%), MR images showed decreased signal intensity in 13 subjects (76.5%) and 4 (23.5%) – had heterogeneous signal intensity in the sequences analyzed together (Figures 5 and 6).

All patients included in the study were classified with regard to risk category, survival time, and the rate of transformation into acute myeloid leukemia on the basis of the IPSS score. The correlation with the bone marrow signal intensity in lumbar spine MRI analyzed in T1- and T2-weighted sequences together was studied for scale.

According to the IPSS score, 36 patients (67.9%) had scores in the so-called low-risk prognostic group category, 7 patients (13.2%) were at intermediate –1 risk, 8 patients (15.1%) were at intermediate –2 risk, and 2 patients (3.8%) were at high risk.

In low-risk patients, MRI scans most often showed increased signal intensity. The same result was observed in 63.9% (23 patients) in the combined analysis of T1- and T2-weighted sequences. Decreased signal intensity was observed in 7 patients (19.4%) and heterogeneous signal intensity was observed in 6 patients (16.7%). In the group of patients with intermediate –1 risk, heterogeneous signal intensity in the combined analysis of both sequences was observed most often, reported in 4 patients (57.1%); and 42.9% (3 patients) were characterized by decreased signal intensity. Patients with intermediate –2 risk showed decreased signal intensity in MRI scans in 100% of examinations (8 patients). Decreased signal intensity was found in 100% (2 patients) of high-risk patients.

For 42 patients whose LDH values were obtained from the medical records, a correlation with MRI signal was analyzed. LDH values determined the division of these patients into 2 groups: 2 patients (4.8%) were in the normal LDH level group and 40 patients (95.2%) were in the increased LDH level group. All patients from the first group showed increased signal intensity in lumbar spine MRI scanning. In the group of patients with increased LDH, 22 (55%) showed decreased signal intensity in the combined analysis of T1- and T2-weighted sequences, 11 patients (27.5%) presented heterogeneous signal intensity, and 7 individuals (17.5%) had increased signal intensity.

Dependence on blood product transfusions was analyzed in all patients: 33 patients (62.3%) had frequent transfusions and 20 patients (37.7%) did not require transfusion. Among transfusion-dependent patients, 20 scans (60.6%) showed decreased signal intensity, 11 scans (33.3%) revealed heterogeneous signal intensity, and 2 patients (6.1%) had increased signal intensity. In the group of patients without transfusions, 11 (55%) showed increased signal intensity, 7 scans (35%) showed decreased signal intensity, and 2 patients (10%) had heterogeneous signal intensity.

Discussion

The differences in clinical presentation and the course of the disease in subtypes of myelodysplastic syndrome resulted in

prognostic scales, which define survival time and the possibility of transformation into acute myeloid leukemia. Risk category is important when choosing a therapeutic option and in the follow-up of the patient [27,28].

Prognostic factors can be divided into 4 groups. The first group comprises changes to tumor masses (related to leukemic infiltration), including subtype of MDS, the abnormal location of immature precursors, and *in vitro* culture growth pattern. The second group of changes is characterized as involvement and damage with regard to maturation and differentiation of cell lines, analyzing cytopenias, dysplasias, and fraction of CD34+ cells. Genetic abnormalities are considered as a separate group of factors. The last group includes clinical and pathological features of the disease: primary or secondary MDS, features of myelofibrosis, or simultaneous occurrence of myeloid sarcoma [29,30].

The IPSS is most popular prognostic scale, and divides patients into 2 therapeutic groups: low risk (comprising IPSS low and intermediate –1 risk patients) and high risk (IPSS intermediate –2 and high-risk patients). This scale shows a weak correlation with survival time and transformation into acute myeloid leukemia in patients with secondary myelodysplastic syndrome, constituting a substantial proportion of patients [31].

An additional observation of LDH value (correct or increased) depending on the risk category makes it possible to state that survival time of low-risk patients with increased LDH value was not longer than that of intermediate risk patients with the correct value of lactate dehydrogenase [32,33].

MRI is a valuable source of information about bone marrow changes, especially in regions inaccessible to biopsy, and thus complements diagnostics and enables monitoring of patients diagnosed with myelodysplastic syndrome or AML [34]. MRI in myelodysplastic syndromes is difficult to analyze, particularly that it may resemble other hematological diseases [35].

The literature shows that the best places for bone marrow imaging in adults are vertebral bodies and some long bones, because large quantities of red bone marrow stay there throughout the lifespan [21,23,26,36].

Increased demand for hematopoietic processes leading to reverse transformation of yellow marrow into red marrow is an important aspect of change in the course of some hematological diseases, including chronic anemia, advanced and chronic concomitant diseases, and diseases connected with bone marrow displacement or infiltration [24,34,37].

In patients with refractory anemia, who require frequent blood transfusions, the excess iron accumulates in the reticuloendothelial system of the spleen, liver, and bone marrow. In MRI

it is reflected in decreased signal intensity of red bone marrow in all imaging sequences. The changes in signal intensity mostly relate to the axial skeleton [22,38,39].

Leukemic infiltrations in MRI are mostly diffuse and located in the axial skeleton, because they involve red bone marrow. In T1-weighted sequences, images with leukemic infiltrations show decreased signal intensity, but in T2-weighted sequence the image may vary, and increased signal intensity occurs as well [40,41].

Based on MRI in T1-weighted sequence, it is possible to conclude that the response to chemotherapy is good as it is visible in bone marrow images that becomes correct again (i.e., characterized by increased signal intensity) [42]. This relationship allows for the conclusion that MRI can be a complementary technique in assessing remission of the disease [43].

Data in the literature allows us to state that MRI has great potential importance in diagnosing and monitoring patients

with myelodysplastic syndromes. Its application as a prognostic factor should be considered.

Conclusions

1. Because the risk category of MDS increases towards high risk, decreased signal intensity is observed in lumbar spine MRI in T1- and T2-weighted images in the studied stratification scales.
2. There is a positive correlation between decreased signal intensity in lumbar spine MRI examinations and increased LDH level in blood serum, as well as dependence on blood product transfusions (especially packed red blood cells).
3. The results indicate possibilities for MR imaging as an additional diagnostic tool in the assessment of dynamics of myelodysplastic syndromes and in evaluating further prognosis regarding survival time and transformation into AML.

References:

1. Kuliczkowski K, Podolak-Dawidziak M, Urbaniak-Kujda D: Diagnostic and therapeutic advances in myelodysplastic syndromes. *Post N Med*, 2000; 4: 40–43
2. Nishino HT, Chung-Che C: Myelodysplastic Syndromes. *Clinicopathologic Features, Pathobiology, and Molecular Pathogenesis*. *Arch Pathol Lab Med*, 2005; 129(10): 1299–310
3. Maryniak R: Histopathological classification of myelodysplastic syndromes according to WHO 2008. *Acta Haematol Pol*, 2011; 42(2): 165–69
4. Hoffbrand AV, Pettit JE: *Atlas of clinical hematology*. Lublin (Poland), Czelej, 2003
5. Skotnicki AB, Śledziowski P: Myelodysplastic syndromes. [In:] Dmoszyńska A, Robak T (eds.), *Basics of hematology*. 11. Il: Czelej, 2008
6. Maryniak RK, Podchorec-Sobieszek M, Pałynyczko G et al: Multicenter retrospective study of histopathological and clinical features in 85 patients with the diagnosis of MDS. *Acta Haematol Pol*, 2001; 32(3): 277–85
7. Heleniak H, Król M, Świeboda-Sadej A, Dwilewicz-Trojaczek J: Differences of blast cells immunophenotype in myelodysplastic syndromes. *Acta Haematol Pol*, 2009; 40(4): 813–21
8. Shi J, Shao Z H, Liu H et al: Transformation of myelodysplastic syndromes into acute myeloid leukemias. *Chin Med J (Engl)*, 2004; 117(7): 963–67
9. Woźniacka M, Wierzbowska A: Angiogenesis in myelodysplastic syndromes. *Acta Haematol Pol*, 2007; 38(2): 163–76
10. Mangi MH, Newland AC: Angiogenesis and angiogenic mediators in hematological malignancies. *Br J Haematol*, 2000; 111: 43–51
11. Matuszewski L, Persigehl T, Wall A et al: Assessment of bone marrow angiogenesis of patients with acute myeloid by using contrast-enhanced MR imaging with clinically approved iron oxides: initial experience. *Radiology*, 2007; 242(1): 217–24
12. Sawczuk-Chabin J, Seferyńska I: Treatment of myelodysplastic syndromes. *Post N Med*, 2003; 3–4: 93–98
13. Warlick ED, Smith BD: Myelodysplastic Syndromes: Review of Pathophysiology and Current Novel Treatment Approaches. *Curr Cancer Drug Targets*, 2007; 7: 541–58
14. Wróbel T, Mazur G, Pyszel A et al: Familial incidence of myelodysplastic syndromes. *Wiad Lek*, 2006; 61: 3–4
15. Brandwien JM, Horsman DE, Eaves AC et al: Childhood myelodysplasia: suggested classification as myelodysplastic syndromes based on laboratory and clinical findings. *Am J Pediatr Hematol Oncol*, 1990; 12(1): 63–70
16. Wehrli FW, MacFall JR, Breger R, Herfkens JR: Mechanisms of contrast in NMR imaging. *J Comput Assist Tomogr*, 1984; 8(3): 369–83
17. Harel R, Angelov L: Spine metastases: current treatments and future directions. *Eur J Cancer*, 2010; 46: 2696–707
18. Walker R, Barlogi B, Haessler J, Tricot G et al: Magnetic resonance imaging in multiple myeloma: diagnostic and clinical implications. *J Clin Oncol*, 2007; 5(5): 327–35
19. Husband JE, Guy R: Magnetic resonance imaging in oncology. *Gut*, 1992; 33: 1587–89
20. Tokuda O, Hayashi N, Matsunaga N: MRI of bone tumors: Fast STIR imaging as a substitute for T1-weighted contrast-enhanced fat-suppressed spin-echo imaging. *J Magn Reson Imaging*, 2004; 19(4): 475–81
21. Stäbler A: Bone Marrow Disorders. [In:] Hodler, Schulthess G K, Zollikofer Ch L. *Musculoskeletal Diseases. Diagnostic Imaging and International Techniques*. IDKD, 2005; 73–82
22. Carrol KW, Feller JF, Tirman PE: Distinguishing Infiltrative Marrow Pathology From Hematopoietic Marrow at MRI. *J Magn Reson Imaging*, 1997; 7(2): 394–98
23. Burgener FA, Meyers SP, Tan RK et al. (eds.), *Differential diagnosis in magnetic resonance imaging*. MediPage; 2010; 571–80
24. Hwang S, Panicek DM: Magnetic resonance imaging of bone marrow in oncology, Part 1. *Skeletal Radiol*, 2007; 36: 913–20
25. Dytfeld D, Sosnowski P, Czyż A, Komarnicki M: The role of magnetic resonance in diagnosis of multiple myeloma. *Pol Merkuriusz Lek*, 2007; 23(134): 85–88
26. Vanel D, Dromain C, Tardivon A: MRI of bone marrow disorders. *Eur Radiol*, 2000; 10(2): 224–29
27. Warzocha K: Practical recommendations on the management of myelodysplastic syndromes with special emphasis on the use of lenalidomide in del(5q). *Hematologia*, 2010; 1: 71–79
28. Cheson BD, Bennett JM, Kantarjian H et al: Report of an international working group to standardize response criteria for myelodysplastic syndromes. *Blood*, 2000; 96: 3671–74
29. Sułek K, Sawicki W, Sułek-Piątkowska A et al: Hematooncologist tool-kit. *Via Medica*, 2010; 76–97
30. Greenberg P, Cox C, Le Beau MM et al: International scoring system for evaluating prognosis in myelodysplastic syndromes. *Blood*, 1997; 36: 2079–88
31. Guerci AP, Feldmann L, Humbert JC, Guerci O: Refractory anemia with excess of blasts: a multivariate analysis of prognostic factors in 91 patients and a simplified scoring system for predicting survival. *Eur J Haematol*, 1995; 54(4): 241–44
32. Mufti GJ, Stevens JR, Oscier DG et al: Myelodysplastic syndromes: a scoring system and its prognostic significance. *Br J Haematol*, 1985; 59: 425–33

33. Harel R, Angelov L: Spine metastases: current treatments and future directions. *Eur J Cancer*, 2010; 46: 2696–707
34. Takagi S, Tanaka O: The Role of Magnetic Resonance Imaging in the Diagnosis and Monitoring of Myelodysplastic Syndromes or Leukemia. *Leuk Lymphoma*, 1996; 23(5–6): 443–50
35. Mizuno H: Object analysis of bone marrow MR imaging using double echo STIR sequence in hematological diseases. *Nihon Igaku Hoshasen Gakkai Zasshi*, 1995; 55(8): 569–75
36. Feller JF: MRI of Bone Marrow. *Advances MRI*, 2002; 1–3. Available from: http://mri.cpson.com/pdf/MRI_of_the_Bone_Marrow.pdf
37. Takagi S, Tanaka O, Miura Y: Magnetic Resonance Imaging of Femoral Marrow in Patients With Myelodysplastic Syndromes or Leukemia. *Blood*, 1995; 86(1): 316–22
38. Baert AL, Knauth M, Davies AM et al. (eds.), *Imaging of bone tumors and tumor-like lesions: Techniques and applications*. Springer, 2009; 354
39. Lewis S, Wainscoat JS, Moore NR, Golding SJ: Magnetic resonance imaging in myelodysplastic syndromes. *Br J Radiol*, 1995; 68(806): 121–27
40. Ross JS, Brant-Zawadzki M, Moore KR et al: *Diagnostic Imaging. Spine*. 1st ed. Amirsys; 2004; IV(1): 58–61
41. Olson DO, Shields AF, Scheurich CJ et al: Magnetic resonance imaging of the bone marrow in patients with leukemia, aplastic anemia, and lymphoma. *Invest Radiol*, 1986; 21(7): 540–46
42. Tanaka O, Takagi S, Kobayashi Y et al: MR imaging of the femoral marrow in adult acute leukemia: correlation of MRI patterns with FAB subtype and prognosis. *Nihon Igaku Hoshasen Gakkai Zasshi*, 1996; 56(13): 967–73
43. Takagi S, Tanaka O: Magnetic resonance imaging of femoral marrow predicts outcome in adult patients with acute myeloid leukaemia in complete remission. *Br J Haematol*, 2002; 117(1): 70–75