

Case Series

Rituximab, Mycophenolic Acid, and Calcineurin Inhibitors Achieve Long-Term Remission in Pediatric Focal Segmental Glomerulosclerosis with Steroid-Resistant and Frequently Relapsing Nephrotic Syndrome: A Report of Two Cases

Cahyani Gita Ambarsari^{a, b, c} Meilania Saraswati^d Genta Syaifrin Laudza^a

^aDepartment of Child Health, Faculty of Medicine Universitas Indonesia – Cipto Mangunkusumo Hospital, Jakarta, Indonesia; ^bSchool of Medicine, University of Nottingham, Nottingham, UK; ^cPediatric Centre, Pondok Indah Bintaro Jaya Hospital, South Tangerang, Indonesia; ^dDepartment of Pathology Anatomy, Faculty of Medicine Universitas Indonesia – Cipto Mangunkusumo Hospital, Jakarta, Indonesia

Keywords

B-lymphocytes · Children · Cyclosporine · Immunosuppression · Prednisolone · Steroids · Tacrolimus

Abstract

Studies investigating the effect of rituximab in children with nephrotic syndrome (NS) due to focal segmental glomerulosclerosis (FSGS) have reported conflicting results, with some concluding that patients may require additional immunosuppressive therapy to achieve and/or maintain long-term remission. We report successful treatment of pediatric FSGS with rituximab infusions, followed by maintenance immunosuppression with mycophenolic acid (MPA) and a calcineurin inhibitor (CNI) in 1 patient with refractory steroid-resistant NS (SRNS), and one with frequently relapsing NS (FRNS). Case 1 is a patient with refractory SRNS due to FSGS. MPA and tacrolimus induced complete remission within 6 months following rituximab treatment. Remission was maintained for over 2 years, and the patient's kidney function and body height also returned to normal ranges within this time. Case 2 is a patient with FRNS due to FSGS, who was treated with rituximab followed by MPA and cyclosporine, which successfully prevented relapses for 18 months, that is, at the end point of the observation. Our case report

demonstrates that rituximab and a combination of CNIs and MPA can be effective in achieving complete remission in pediatric refractory SRNS and sustaining remission in pediatric FSGS with FRNS and SRNS for several years. This treatment regimen has the advantage of eliminating the need for long-term high-dose steroid treatments, allowing 1 patient to achieve normal growth and recover from other adverse steroid effects.

© 2022 The Author(s).
Published by S. Karger AG, Basel

Introduction

Idiopathic nephrotic syndrome (NS) in children is one of the leading causes of end-stage kidney disease, both in Indonesia and worldwide [1–5]. Focal segmental glomerulosclerosis (FSGS) is a histopathologic lesion identified as a consolidation and accumulation of extracellular matrix in a segment or subset of glomeruli and often presents as a severe steroid-resistant NS (SRNS) [6, 7]. Rituximab has emerged as a potential treatment for treatment-resistant NS [8, 9]. To date, studies on the effect of rituximab in children with NS resulting from FSGS have yielded conflicting results [8–11]. In this paper, we report successful treatment of pediatric FSGS with rituximab, followed by immunosuppression in a case of SRNS who was refractory to mycophenolate mofetil (MMF), cyclosporine (CyA), and cyclophosphamide (CPA), and a case of frequently relapsing NS (FRNS).

Case Presentation

Case 1

A 14-month-old boy presented to a remote hospital in Indonesia with generalized edema. He was initially diagnosed with steroid-sensitive NS and went into remission following initial treatment with full-dose methylprednisolone (48 mg/m²). Treatment was subsequently continued with 4 weeks of alternate-day methylprednisolone (32 mg/m²). He relapsed 2 months later and, failing to achieve remission with another full dose of oral methylprednisolone, developed secondary steroid resistance at the age of 20 months. Moon face, striae, and growth retardation were observed following the steroid treatment. He was then treated with MMF, CyA, and CPA, while methylprednisolone was tapered. Unfortunately, the proteinuria persisted (Fig. 1a, b), and he was subsequently referred to a tertiary hospital in Jakarta.

Laboratory examination revealed nephrotic proteinuria and diminished kidney function (estimated glomerular filtration rate [eGFR] 39 mL/min per 1.73 m²) suggesting CKD stage 3b (Table 1; Fig. 1a, b). Kidney biopsy showed evidence of FSGS with chronic changes, including global glomerulosclerosis in 7/58 glomeruli, and moderate interstitial fibrosis (Fig. 2a–c). Steroid treatment was discontinued due to adverse effects, and oral mycophenolic acid (MPA) was commenced. Rituximab was also administered, due to the persistent proteinuria and deterioration of kidney function. Two doses of rituximab (750 mg/m²) were given with an interval of 14 days. Peripheral blood B cells (CD19+) absolute count (67 × 10⁹/L) and serum IgG (2.41 g/L) and IgM (0.31 g/L) were reduced following rituximab treatment. However, as proteinuria did not improve 1 month following rituximab therapy, tacrolimus was subsequently added. The patient's kidney function gradually improved, despite episodes of acute decreases in kidney function requiring tacrolimus dosage adjustments (Fig. 1a, b). He was maintained on a low dose of tacrolimus and optimal dose of MPA and achieved complete remission 6 months after rituximab. After 2 years without relapse, tacrolimus was discontinued. No side effects

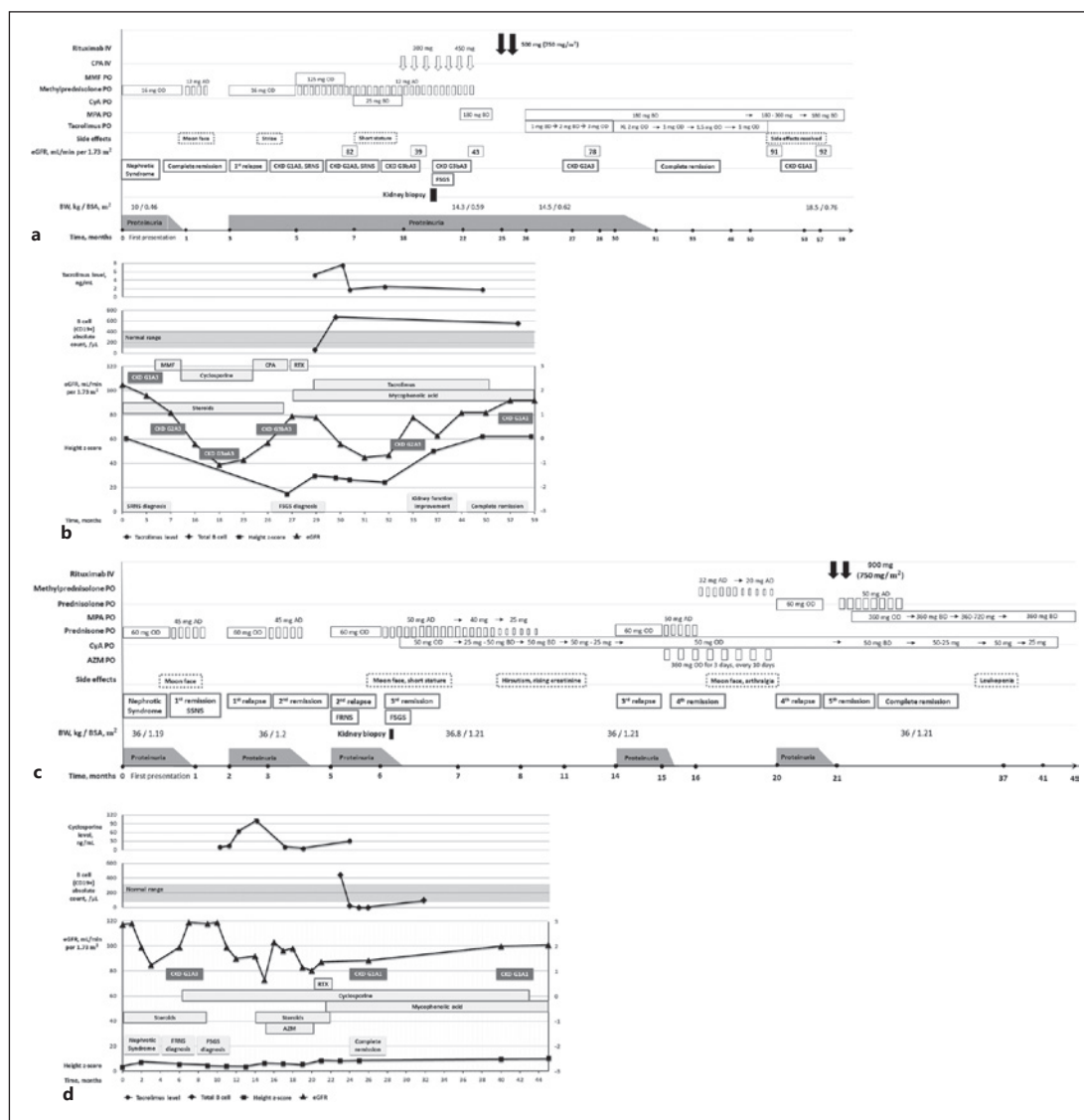


Fig. 1. **a** Timeline of case 1. AD, alternate day; BD, bi-daily; BSA, body surface area; BW, body weight; CKD, chronic kidney disease; CPA, cyclophosphamide; CyA, cyclosporine; eGFR, estimated glomerular filtration rate; FSGS, focal segmental glomerulosclerosis; IV, intravenous; MMF, mycophenolate mofetil; MPA, mycophenolic acid; OD, once a day; PO, per ore; SRNS, steroid-resistant nephrotic syndrome; XL, extended-release. **b** Course of disease and treatment of case 1. CKD, chronic kidney disease; CPA, cyclophosphamide; eGFR, estimated glomerular filtration rate; FSGS, focal segmental glomerulosclerosis; MMF, mycophenolate mofetil; RTX, rituximab; SRNS, steroid-resistant nephrotic syndrome. **c** Timeline of case 2. AD, alternate day; AZM, azithromycin; BD, bi-daily; BSA, body surface area; BW, body weight; CyA, cyclosporine; FRNS, frequently relapsing nephrotic syndrome; FSGS, focal segmental glomerulosclerosis; IV, intravenous; MPA, mycophenolic acid; PO, per ore; OD, once a day; SSNS, steroid-sensitive nephrotic syndrome. **d** Course of disease and treatment of case 2. AZM, azithromycin; CKD, chronic kidney disease; eGFR, estimated glomerular filtration rate; FRNS, frequently relapsing nephrotic syndrome; FSGS, focal segmental glomerulosclerosis; RTX, rituximab.

were noted from rituximab. His kidney function normalized 28 months after rituximab and was maintained within normal range until the end of follow-up. Within 1 year of rituximab treatment, normal height was attained (Fig. 1b), and the moon face appearance resolved.

Table 1. Laboratory results of case 1

Parameter	Units	Normal value	Results	
			first presentation	2 years after rituximab
Blood test				
Albumin	g/L	36–52	12	46
Creatinine	μmol/L	44.2–97.2	81.3	50.4
eGFR (new Schwartz)	mL/min per 1.73 m ²	≥90	40	81.9
Total cholesterol	mmol/L	2.66–4.76	9.90	4.55
HDL	mmol/L	0.67–1.76	2.38	1.50
LDL	mmol/L	<2.59	5.14	2.38
Triglycerides	mmol/L	0.34–1.24	8.07	1.21
B cell (CD19+) absolute count	10 ⁹ /L	0.10–0.43	0.07	0.56
IgA	g/L	0.35–2	1.16	1.33
IgG	g/L	4.2–12	3.29	7.96
IgM	g/L	0.45–2	0.59	0.46
C3	g/L	0.9–2.07	1.95	1.06
Tacrolimus level	nmol/L	6.2–18.6	N/A	<1.86
Urine test				
Protein creatinine ratio	mg/mg	<0.2	40.03	0.2

The bold values are the abnormal results. eGFR, estimated glomerular filtration rate; HDL, high-density lipoprotein; LDL, low-density lipoprotein.

Case 2

A 14-year-old girl was admitted to our hospital following a second relapse of NS. She first presented 6 months before admission with palpebral edema and was diagnosed with idiopathic NS. She achieved remission following treatment with full-dose oral prednisone and was categorized as steroid-sensitive NS but relapsed 1 month following completion of steroid therapy. She went into remission within 1 month after the relapse. However, within less than 4 months, she developed another relapse and was recategorized as FRNS (Fig. 1c).

On examination, she had a moon face appearance due to the steroids and short stature consistent with her genetic potential. Laboratory results confirmed hypoalbuminemia, hypercholesterolemia, and massive proteinuria (Table 2). Histopathology demonstrated FSGS with very minimal interstitial fibrosis (Fig. 3a, b). She was treated with oral prednisone 60 mg/m² once daily for 6 weeks, followed by 40 mg/m², 30 mg/m², and 20 mg/m² alternate-day prednisone for 4 weeks each. She attained remission at the 5th week of full-dose prednisone (Fig. 1c, d). Oral CyA was added, while the prednisone was tapered, but this caused hirsutism and increased serum creatinine levels. Subsequent dose reduction of CyA resulted in a relapse. Another full dose of prednisone was given and resulted in remission, and oral azithromycin (AZM) was introduced for maintenance. Due to emerging side effects of prednisone (arthralgia and moon face), she was switched to methylprednisolone instead. The patient subsequently suffered another relapse on the alternate-day methylprednisolone and AZM regimen, and a course of full dose prednisolone was commenced. Once her proteinuria ceased, two rituximab infusions (750 mg/m²) were administered with a 14-day interval. Oral MPA was initiated a week following the second rituximab infusion (Fig. 1c, d). Lymphocyte subset analysis at 1 week after each infusion

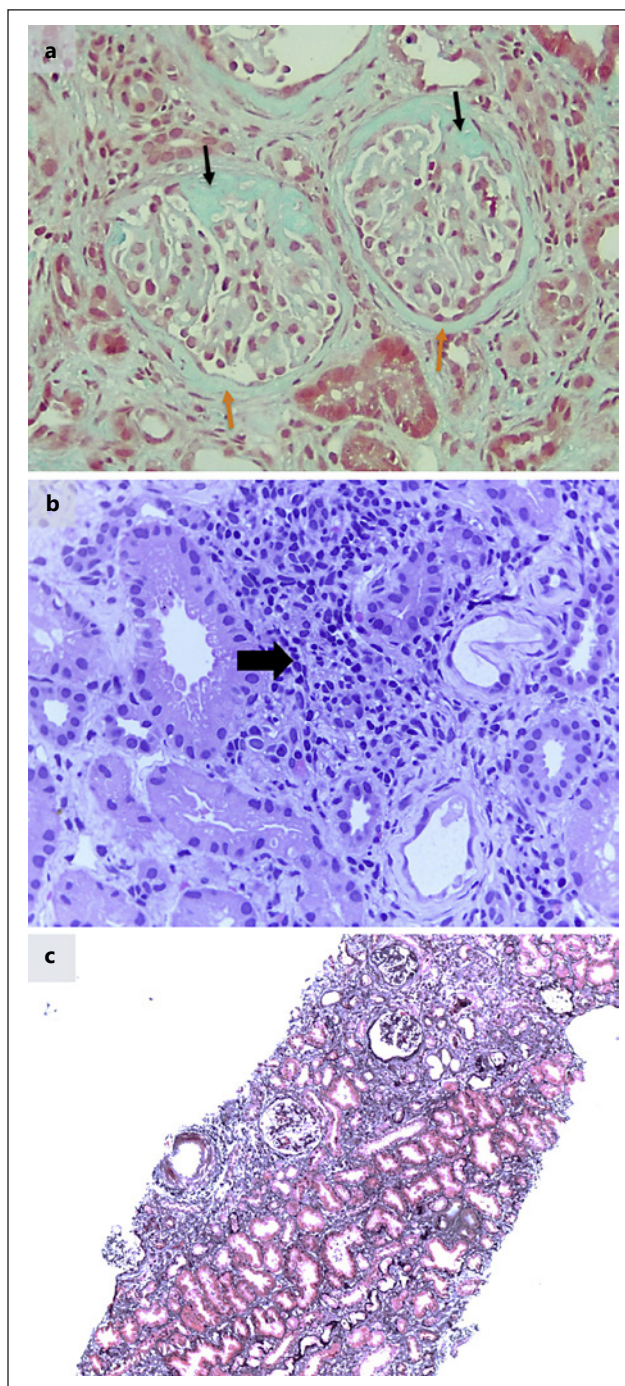


Fig. 2. **a** Histopathologic findings of case 1. Two of the nine glomeruli showing partial sclerosis (black arrows), out of a total of 58 glomeruli identified at all levels (Masson's trichrome, $\times 400$ magnification). Thickening of Bowman's capsule can also be seen (orange arrows). **b** Histopathologic findings of case 1. Interstitial infiltration of mononuclear inflammatory cells (black arrow, H&E, $\times 400$ magnification). **c** Histopathologic findings of case 1. Geographical fibrosis is also present (Silver trichrome, $\times 100$ magnification).

demonstrated a reduction in B cell (CD19+) absolute count to 0 cells/ μL . Seven months after rituximab, the patient had not experienced any associated side effects and was negative for proteinuria on oral CyA and MPA (Fig. 1c; Table 2). We attempted to increase the dose of MPA to discontinue CyA; however, leukopenia was subsequently noted ($2.1 \times 10^9/\text{L}$). CyA was therefore continued at a sufficient dose for maintenance; however, the patient developed gingival hyperplasia requiring CyA discontinuation. She was then maintained with low dose of MPA until the last follow-up (Fig. 1c, d).

Table 2. Laboratory results of case 2

Parameter	Units	Normal value	Results	
			first presentation	18 months after rituximab
Blood test				
Albumin	g/L	36–52	9	36
Creatinine	μmol/L	44.20–97.24	44.2	53.04
eGFR (new Schwartz)	mL/min per 1.73 m ²	≥90	117	100.5
Total cholesterol	mmol/L	2.66–4.76	16.14	5.59
IgA	g/L	0.35–2	1.72	1.47
IgG	g/L	4.20–12	10.51	10.28
IgM	g/L	0.45–2	1.72	1.46
C3	mg/Dl	0.90–2.07	0.97	1.03
Urine test				
Protein creatinine ratio	mg/mg	<0.2	1.34	<0.1

The bold values are the abnormal results. eGFR, estimated glomerular filtration rate.

Discussion/Conclusion

Some studies have suggested that rituximab is effective for treatment of FSGS in children [8, 9]. For FRNS and steroid-dependent NS (SDNS), Ruggenti et al. [9] concluded that rituximab reduces the risk of recurrence and the number of immunosuppressive agents required in children with FSGS. Zachwieja et al. [12] reported the efficacy of rituximab in steroid-resistant FSGS patients and found that it was effective in inducing and maintaining remission. In a recent review, Kamei et al. [13] concluded that 41.5% of refractory pediatric SRNS patients who received rituximab achieved FSGS remission. Conversely, the single series reported by Sinha et al. [8] found a remission rate of only 19.5% in children with SRNS and FSGS given rituximab. Moreover, a randomized controlled trial showed that rituximab did not reduce proteinuria after 3 months in children with steroid-resistant idiopathic NS [10].

The underlying mechanism by which rituximab, MMF, and calcineurin inhibitors (CNIs) induce and maintain remission in FSGS remains unclear, although depletion of B cells and circulating autoantibodies have been suggested [14]. Rituximab may also preserve the expression of sphingomyelin phosphodiesterase acid-like 3B (SMPDL-3b) in podocytes, which prevents podocyte apoptosis and disruption of the actin cytoskeleton that could result in podocyte injury and proteinuria [15]. Similarly, CNIs have a protective effect on the actin cytoskeleton of podocytes, which could reduce proteinuria [15]. MMF may also contribute to the depletion of immune cells by inhibiting T and B cell proliferation [16].

Dosage is an important factor affecting clinical response to rituximab in FSGS, but no internationally standardized dosage is available to date. A range of doses have been used in recent studies, including a single dose of 375 mg/m², two doses of 375 mg/m² with a 14-day interval, four doses of 375 mg/m² per week, and two doses of 750 mg/m² per week. In children with difficult-to-treat NS receiving 2–4 doses of 375 mg/m², remission was achieved in only 19.5% of steroid-resistant cases [8]. Another study comparing rituximab doses of 100 mg/m², 375 mg/m², and 750 mg/m² in FRNS and SDNS patients found that a lower dose of 100 mg/m² was associated with a shorter B cell depletion period, increasing the risk of relapses [17]. We therefore believe that rituximab (two doses of 750 mg/m² separated by a 14-day interval),

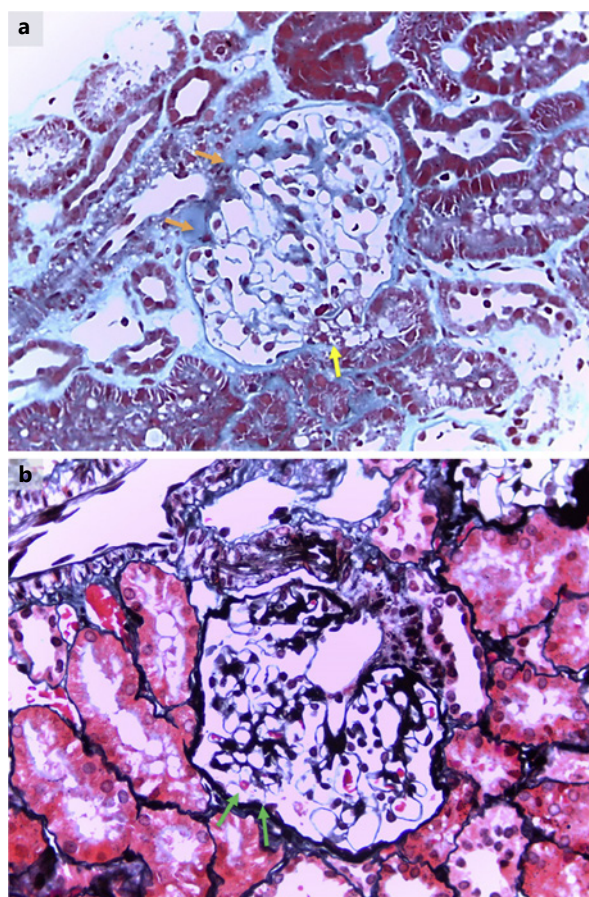


Fig. 3. a Histopathologic findings of case 2. A small area of hyalinization in one glomerulus (orange arrow) and adhesion of glomerular tuft to the tubular pole (yellow arrow) can also be seen (Masson's trichrome; $\times 400$). These features represent early focal segmental glomerulosclerosis. **b** Histopathologic findings of case 2. There is a subtle adhesion of the glomerulus to Bowman's capsule near the tubular pole (green arrows), suggesting early segmental glomerulosclerosis (Silver trichrome, $\times 400$ magnification).

followed by immunosuppressive agents (CNI and MPA) may successfully induce remission in refractory SRNS children with FSGS and prolong remission in FRNS children with FSGS.

Both cases in this report responded positively to rituximab therapy with concomitant maintenance immunosuppression. Rituximab followed by long-term use of tacrolimus and MPA in case 1 induced remission within 6 months and prevented relapses for 2 years (Fig. 1a). Moreover, case 2 remained proteinuria-negative for 2 years following rituximab (Fig. 1c). Some studies have recommended repeated administration of rituximab when the B cell count recovers or the patient relapses [18–20]. Kim et al. [19] reported that the mean interval to relapse requiring a repeat dose of rituximab was 5.9 ± 0.5 months. However, as the remission achieved in our cases was likely due to the positive effects of oral immunosuppressive maintenance medications, repeated doses of rituximab were not required.

Researchers have reported variation in the average time required for reduction in proteinuria in SRNS children receiving rituximab and CNIs, with a median time of 6 months following rituximab infusions [21]. In contrast, children with SRNS treated with tacrolimus have shown improvement earlier, with a reduction in the urine protein to creatinine ratio achieved within 27 days of tacrolimus initiation [22]. Additionally, overall remission rate was reported to be as high as 94.7% in the first month of tacrolimus treatment [23]. Case 1 achieved remission within 6 months following rituximab infusions; however, this was also 1 month after tacrolimus initiation. The patient remained free of relapses for 2 years on low-dose tacrolimus. It is therefore uncertain whether the relapse-free period resulted from rituximab treatment or commencement of tacrolimus.

Another factor contributing to the favorable clinical response of NS with FSGS was the use of immunosuppressive drugs following rituximab. Maintenance therapy after rituximab infusion is given in anticipation of unwanted B cell recovery that could lead to relapse. Chan et al. [24] investigated the relapse-free survival time of children with FRNS on different rituximab regimens, with or without maintenance immunosuppressant therapy. Their results showed that administration of maintenance immunosuppression led to similar relapse-free survival times between patients receiving low- and high-dose rituximab [24]. Furthermore, Suyama et al. [25] reported a case series of steroid-resistant FSGS treated with rituximab, followed by maintenance immunosuppression with low-dose CyA. The mean number of relapses 1 year after rituximab and CyA was significantly lower than before rituximab and CyA (0.7 ± 0.6 vs. 3.3 ± 3.6 , $p < 0.01$). It is therefore clear that maintenance immunosuppression is beneficial following rituximab treatment in SRNS and FRNS with FSGS. However, there is no consensus on the choice of immunosuppressant(s) used for maintenance.

Ito et al. [26] conducted a prospective cohort study evaluating the effects of MMF following rituximab in children with refractory SDNS or FRNS. Compared to rituximab alone, maintenance immunosuppression with MMF produced longer remission and reduced both the relapse rate and the required steroid dose. We used MPA to maintain remission due to its better gastrointestinal side-effect profile compared to MMF [27]. Use of CNIs as maintenance therapy following rituximab has previously been shown to prolong the relapse-free interval in steroid-resistant FSGS [25]. Although the majority of studies utilize only one immunosuppressive drug following rituximab, we added tacrolimus in case 1 as heavy proteinuria continued 1 month after rituximab, despite an optimal dose of MPA. In case 2, we maintained the dose of CyA given before rituximab and added a low dose of MPA to prevent relapses (Fig. 1c).

Our case management was constrained by delayed diagnosis due to limited biopsy facilities and pathology expertise – common problems in Indonesia [28, 29]. The patient in case 1 lives in a very remote area and therefore did not undergo a kidney biopsy after SRNS diagnosis. As a result, the kidney biopsy in case 1 showed greater disease progression than case 2 (Fig. 2a–c, 3a, b). Case 1 was also treated with IV CPA, despite it no longer being recommended for the treatment of pediatric SRNS [3], as rituximab was unavailable at his local hospital.

Before commencing rituximab in case 2, AZM was given in conjunction with corticosteroids for 5 months. Randomized controlled trials have reported a significantly lower relapse rate in SDNS children treated with AZM and corticosteroids, compared with corticosteroids alone [30, 31]. Moreover, Hara and Hirano [32] reported that a 2-year-old boy with FRNS treated with AZM achieved a relapse-free period of 1 year. However, the use of AZM in case 2 failed to prevent further relapses, and rituximab was therefore given.

A surprising aspect of our report was the improvement in kidney function following rituximab therapy in case 1. This patient had reduced kidney function prior to rituximab therapy and met the criteria for CKD G3 for 1 year (Fig. 1a, b). Studies have shown that reduction of protein loss through the glomerulus is associated with slower decline of kidney function and improved eGFR [33, 34]. In case 1, the improvement in eGFR could be due to reduction in proteinuria caused by gradual tapering of the tacrolimus dose, thus reversing its nephrotoxicity and allowing for recovery of kidney function (Fig. 1b) [35]. Moreover, the growth of the patient may have influenced the pharmacokinetics of tacrolimus, thus contributing to the improved eGFR [36].

Case 1 also highlighted another positive effect of achieving long-term remission with maintenance immunosuppression following rituximab, as steroids were no longer required to treat relapses. The patient, who was previously of abnormally short stature, was of normal height by the end of the observation period (Fig. 1b). Rituximab has previously been associated with an improved height standard deviation score in children with difficult-to-treat NS [8].

The International Pediatric Nephrology Association (2020) suggested that immunosuppressive treatment with CNIs should be started immediately for SRNS cases in countries where genetic testing is not available. Genetic testing is also not recommended in SRNS patients with a history of steroid sensitivity [37]. For these reasons, genetic testing was not performed for case 1.

Our case report suggests that rituximab followed by maintenance immunosuppression is effective in treating pediatric NS with FSGS, not only to achieve complete remission in refractory SRNS but also to sustain long-term remission in both SRNS and FRNS. Use of two immunosuppressants following rituximab can maintain long-term positive outcomes and avoid the need for further doses of rituximab.

Acknowledgment

We would like to express our gratitude to Etty Widyastuti, MD, for her care of the patient in Bandar Lampung.

Statement of Ethics

The study was ethically conducted in accordance with the World Medical Association Declaration of Helsinki. Ethical approval is not required for this study in accordance with local guidelines. Written informed consent was obtained from the parents/legal guardians of the patients for publication of the details of their medical case and any accompanying images. Copies of the written consents are available for review from the editor of this journal.

Conflict of Interest Statement

The authors have no conflicts of interest to report.

Funding Sources

The authors received no specific funding for this work.

Authors Contributions

Cahyani Gita Ambarsari performed the literature search; data collection, analysis, and interpretation; wrote the first draft of the manuscript; critically revised the manuscript; and approved the final version of the manuscript. Genta Syaifrin Laudza performed the literature search; data collection and analysis; wrote the first draft of the manuscript; critically revised the manuscript; and approved the final version of the manuscript. Meilania Saraswati performed data collection and analysis and read and approved the final version of the manuscript.

Data Availability Statement

All data generated or analyzed during this study are included in this article. Further inquiries can be directed to the corresponding author.

References

- 1 Ambarsari CG, Hidayati EL, Trihono PP, Saraswati M, Rodjani A, Wahyudi I, et al. Experience of the first 6 years of pediatric kidney transplantation in Indonesia: a multicenter retrospective study. *Pediatr Transplant*. 2020 Dec;24(8):e13812.
- 2 Kidney Disease: Improving Global Outcomes (KDIGO) Glomerular Diseases Work Group. KDIGO 2021 clinical practice guideline for the management of glomerular diseases. *Kidney Int*. 2021 Oct;100(4S):S1–S276.
- 3 Roccatello D, Sciascia S, Rossi D, Alpa M, Naretto C, Radin M, et al. High-dose rituximab ineffective for focal segmental glomerulosclerosis: a long-term observation study. *Am J Nephrol*. 2017 Jul;46(2):108–13.
- 4 Palupi-Baroto R, Hermawan K, Murni IK, Nurlitasari T, Prihastuti Y, Sekali DRK, et al. High fibroblast growth factor 23 as a biomarker for severe cardiac impairment in children with chronic kidney disease: a single tertiary center study. *Int J Nephrol Renovasc Dis*. 2021 Jun;14:165–71.
- 5 Wentze-Schulz S, Aksenova M, Awan A, Ambarsari CG, Becherucci F, Emma F, et al. Aetiology, course and treatment of acute tubulointerstitial nephritis in paediatric patients: a cross-sectional web-based survey. *BMJ Open*. 2021 May;11(5):e047059.
- 6 De Vriese AS, Wetzels JF, Glassock RJ, Sethi S, Fervenza FC. Therapeutic trials in adult FSGS: lessons learned and the road forward. *Nat Rev Nephrol*. 2021 Sep;17(9):619–30.
- 7 Chen YM, Liapis H. Focal segmental glomerulosclerosis: molecular genetics and targeted therapies. *BMC Nephrol*. 2015 Jul;16(1):101.
- 8 Sinha A, Bhatia D, Gulati A, Rawat M, Dinda AK, Hari P, et al. Efficacy and safety of rituximab in children with difficult-to-treat nephrotic syndrome. *Nephrol Dial Transplant*. 2015 Jan;30(1):96–106.
- 9 Ruggenti P, Ruggiero B, Cravedi P, Vivarelli M, Massella L, Marasa M, et al. Rituximab in steroid-dependent or frequently relapsing idiopathic nephrotic syndrome. *J Am Soc Nephrol*. 2014 Apr;25(4):850–63.
- 10 Magnasco A, Ravani P, Edefonti A, Murer L, Ghio L, Belingheri M, et al. Rituximab in children with resistant idiopathic nephrotic syndrome. *J Am Soc Nephrol*. 2012 Jun;23(6):1117–24.
- 11 Iijima K, Sako M, Nozu K, Mori R, Tuchida N, Kamei K, et al. Rituximab for childhood-onset, complicated, frequently relapsing nephrotic syndrome or steroid-dependent nephrotic syndrome: a multicentre, double-blind, randomised, placebo-controlled trial. *Lancet*. 2014 Oct;384(9950):1273–81.
- 12 Zachwieja J, Silska-Dittmar M, Żurowska A, Drożyńska-Duklas M, Hyla-Klekot L, Kucharska G, et al. Multicenter analysis of the efficacy and safety of a non-standard immunosuppressive therapy with rituximab in children with steroid-resistant nephrotic syndrome. *Clin Exp Pharmacol Physiol*. 2019 Apr;46(4):313–21.
- 13 Kamei K, Ishikura K, Sako M, Ito S, Nozu K, Iijima K, et al. Rituximab therapy for refractory steroid-resistant nephrotic syndrome in children. *Pediatr Nephrol*. 2020 Jan;35(1):17–24.
- 14 Delville M, Sigdel TK, Wei C, Li J, Hsieh SC, Fornoni A, et al. A circulating antibody panel for pretransplant prediction of FSGS recurrence after kidney transplantation. *Sci Transl Med*. 2014 Oct;6(256):256ra136.
- 15 Cravedi P, Kopp JB, Remuzzi G. Recent progress in the pathophysiology and treatment of FSGS recurrence. *Am J Transplant*. 2013 Feb;13(2):266–74.
- 16 Hackl A, Ehren R, Weber LT. Effect of mycophenolic acid in experimental, nontransplant glomerular diseases: new mechanisms beyond immune cells. *Pediatr Nephrol*. 2017 Aug;32(8):1315–22.
- 17 Hogan J, Dossier C, Kwon T, Macher MA, Maisin A, Couderc A, et al. Effect of different rituximab regimens on B cell depletion and time to relapse in children with steroid-dependent nephrotic syndrome. *Pediatr Nephrol*. 2019 Feb;34(2):253–9.
- 18 Takahashi T, Okamoto T, Sato Y, Yamazaki T, Hayashi A, Aoyagi H, et al. Periodically repeated rituximab administrations in children with refractory nephrotic syndrome: 2-year multicenter observational study. *Pediatr Nephrol*. 2019 Jan;34(1):87–96.
- 19 Kim JH, Park E, Hyun HS, Cho MH, Ahn YH, Choi HJ, et al. Long-term repeated rituximab treatment for childhood steroid-dependent nephrotic syndrome. *Kidney Res Clin Pract*. 2017 Sep;36(3):257–63.
- 20 Counsilman CE, Jol-van der Zijde CM, Stevens J, Cransberg K, Bredius RGM, Sukhai RN. Pharmacokinetics of rituximab in a pediatric patient with therapy-resistant nephrotic syndrome. *Pediatr Nephrol*. 2015 Aug;30(8):1367–70.
- 21 Sinha R, Banerjee S, Mukherjee A, Pradhan S, Akhtar S. Early use of rituximab in calcineurin inhibitor-refractory and steroid-resistant nephrotic syndrome. *Kidney Int Rep*. 2020 Oct;5(12):2354–7.
- 22 Butani L, Ramsamooj R. Experience with tacrolimus in children with steroid-resistant nephrotic syndrome. *Pediatr Nephrol*. 2009 Apr;24(8):1517–23.
- 23 Chen HX, Cheng Q, Li F, He QN, Cao Y, Yi ZW, et al. Efficacy and safety of tacrolimus and low-dose prednisone in Chinese children with steroid-resistant nephrotic syndrome. *World J Pediatr*. 2020 Apr;16(2):159–67.
- 24 Chan EYH, Webb H, Yu E, Ghiggeri GM, Kemper MJ, Ma ALT, et al. Both the rituximab dose and maintenance immunosuppression in steroid-dependent/frequently-relapsing nephrotic syndrome have important effects on outcomes. *Kidney Int*. 2020 Feb;97(2):393–401.
- 25 Suyama K, Kawasaki Y, Miyazaki K, Kanno S, Ono A, Suzuki Y, et al. Rituximab and low-dose cyclosporine combination therapy for steroid-resistant focal segmental glomerulosclerosis. *Pediatr Int*. 2016 Mar;58(3):219–23.
- 26 Ito S, Kamei K, Ogura M, Sato M, Fujimaru T, Ishikawa T, et al. Maintenance therapy with mycophenolate mofetil after rituximab in pediatric patients with steroid-dependent nephrotic syndrome. *Pediatr Nephrol*. 2011 Oct;26(10):1823–8.

- 27 Lopez-Solis R, DeVera M, Steel J, Fedorek S, Sturdevant M, Hughes C, et al. Gastrointestinal side effects in liver transplant recipients taking enteric-coated mycophenolate sodium vs. mycophenolate mofetil. *Clin Transplant*. 2014 Jul;28(7):783–8.
- 28 Ambarsari CG, Sindih RM, Saraswati M, Trihono PP. Delayed admission and management of pediatric acute kidney injury and multiple organ dysfunction syndrome in children with multiple wasp stings: a case series. *Case Rep Nephrol Dial*. 2019 Sep–Dec;9(3):137–48.
- 29 Ambarsari CG, Cahyadi D, Sari L, Satria O, Sahli F, Darmadi TL, et al. Late diagnosis of Lesch-Nyhan disease complicated with end-stage renal disease and tophi burst: a case report. *Ren Fail*. 2020 Nov;42(1):113–21.
- 30 Sawires H, Abdelaziz H, Ahmed HM, Botrous O, Agban M. Randomized controlled trial on immunomodulatory effects of azithromycin in children with steroid-dependent nephrotic syndrome. *Pediatr Nephrol*. 2019 Sep;34(9):1591–7.
- 31 Zhang B, Liu T, Wang W, Zhang X, Fan S, Liu Z, et al. A prospective randomly controlled clinical trial on azithromycin therapy for induction treatment of children with nephrotic syndrome. *Eur J Pediatr*. 2014 Apr;173(4):509–15.
- 32 Hara H, Hirano D. Azithromycin suppressed relapses of idiopathic nephrotic syndrome in a child. *Clin Kidney J*. 2018 Feb;11(1):54–5.
- 33 Cravedi P, Remuzzi G. Pathophysiology of proteinuria and its value as an outcome measure in chronic kidney disease. *Br J Clin Pharmacol*. 2013 Oct;76(4):516–23.
- 34 Hu B, Gadegbeku C, Lipkowitz MS, Rostand S, Lewis J, Wright JT, et al. Kidney function can improve in patients with hypertensive CKD. *J Am Soc Nephrol*. 2012 Apr;23(4):706–13.
- 35 Choudhry S, Bagga A, Hari P, Sharma S, Kalaivani M, Dinda A, et al. Efficacy and safety of tacrolimus versus cyclosporine in children with steroid-resistant nephrotic syndrome: a randomized controlled trial. *Am J Kidney Dis*. 2009 May;53(5):760–9.
- 36 Lancia P, Jacqz-Aigrain E, Zhao W. Choosing the right dose of tacrolimus. *Arch Dis Child*. 2015 Apr;100(4):406–13.
- 37 Trautmann A, Vivarelli M, Samuel S, Gipson D, Sinha A, Schaefer F, et al. IPNA clinical practice recommendations for the diagnosis and management of children with steroid-resistant nephrotic syndrome. *Pediatr Nephrol*. 2020 Aug;35(8):1529–61.