

The Evaluation and Observation of “Hidden” Hypertrophy of Cervical Ligamentum Flavum, Cervical Canal, and Related Factors Using Kinetic Magnetic Resonance Imaging

Cheng Zeng¹ Jian Xiong² Jeffrey C. Wang³ Hirokazu Inoue⁴ Yanlin Tan⁴ Haijun Tian⁴ Bayan Aghdasi⁴

¹ Department of Spine Surgery, Beijing Jishuitan Hospital, Beijing, China

² Department of Trauma and Orthopaedics, Peking University People’s Hospital, Beijing, China

³ Orthopaedic Surgery and Neurosurgery, USC Spine Center, Los Angeles, California, United States

⁴ Department of Orthopaedic Surgery, University of California at Los Angeles, Los Angeles, California, United States

Address for correspondence Jian Xiong, MD, Department of Trauma and Orthopaedics, Peking University People’s Hospital, 11 Xizhimen South Street, Xicheng District, Beijing, China (e-mail: mark.xiong3000@gmail.com).

Global Spine J 2016;6:155–163.

Abstract

Study Design Retrospective cohort study.

Objective The objective was to measure the change of flavum ligament diameter during positional changes of the cervical spine using kinetic magnetic resonance imaging (MRI) and to examine the correlational diameter changes of the flavum ligament, disk bulging, and the spinal canal from extension to flexion positions.

Methods One hundred eight-nine patients underwent kinetic MRI in neutral, extension, and flexion positions. The diameters of cervical ligamentum flavum, disk bulging, and cervical spinal canal and the disk degeneration grade and Cobb angles were measured from C2–C3 to C7–T1.

Results In all, 1,134 cervical spinal segments from 189 patients were included. There was a 0.26 ± 0.85 -mm average increase in the diameter of the ligamentum flavum from flexion to extension, and 62.70% of the segments had increased ligamentum flavum diameter from flexion to extension. For all segments of the 189 patients, the cervical spinal canal diameters had an average decrease at the disk level of 0.56 ± 1.21 mm from flexion to extension. For all segments with cervical spinal canal narrowing ≥ 1 mm from flexion to extension view, the ligamentum flavum diameters at C3–C4 to C5–C6 had significant increases compared with patients with spinal canal narrowing < 1 mm ($p < 0.05$). For patients with ligamentum flavum hypertrophy of ≥ 1 mm from the flexion to extension view, the cervical spinal canal diameters at C2–C3, C4–C5, and C5–C6 had significant decreases compared with patients with ligamentum flavum hypertrophy of < 1 mm ($p < 0.05$).

Conclusion The “hidden” hypertrophy of ligamentum flavum was significant at C4–C5 and C5–C6 and significantly contributes to the stenosis of cervical spinal canal in the extension position.

Keywords

- ▶ cervical spine
- ▶ ligamentum flavum
- ▶ kinematic analysis
- ▶ kinetic MRI
- ▶ disk herniation
- ▶ spinal canal

received
June 18, 2014
accepted after revision
May 11, 2015
published online
July 9, 2015

DOI <http://dx.doi.org/10.1055/s-0035-1557140>.
ISSN 2192-5682.

© 2016 Georg Thieme Verlag KG
Stuttgart · New York

License terms



Introduction

Magnetic resonance imaging (MRI) is the most sensitive technique for showing the structure of soft tissue in the cervical spine, such as intervertebral disk and ligamentum flavum. The increasing use of kinetic (positional) MRI (k-MRI) for the cervical spine has resulted in a greater understanding of the pathogenic mechanisms of cervical spinal canal stenosis. In healthy individuals, the space around the cervical spinal cord protects the spinal cord during normal movement. However, in patients with spinal canal stenosis, the space around the spinal cord is reduced or lost, such that the stenosis of spinal canal may be increased if the cervical spine suffers a hyperextension-compression force.^{1,2} Given that in these cases radiographic abnormalities may be absent, k-MRI evaluations of the cervical spine in flexion and extension can help elucidate the etiology of cervical spinal stenosis.

Several published studies have focused on “hidden” herniation of the disk during flexion and extension,^{3,4} whereas changes in the ligamentum flavum during sagittal movement of the cervical spine have largely been ignored. Thus, the purpose of this study was to use k-MRI to measure changes in the diameter of the ligamentum flavum during positional changes of the cervical spine and to determine the correlations between these changes, disk bulging, and narrowing of the spinal canal during flexion and extension.

Methods

Patient Sample

This study was based on the data obtained from 189 patients who underwent k-MRI examination in 10 outpatient MRI facilities (TrueMRI, Anaheim, California, United States) from April to September of 2011. The study was approved by the Institutional Review Board of our institution. The age of the 94 men and 95 women ranged from 19 to 61 years; the mean age was 52.90 years.

The inclusion criteria were: (1) symptoms of neck or shoulder pain and (2) no evidence of cervical disk herniation and/or spinal canal stenosis causing cervical spondylosis, as clinically determined on MRI with the spine in the neutral position.

Exclusion criteria were: (1) patients with serious spinal diseases (such as spinal tumor), spinal fracture, spinal cord infection, ankylosing spondylitis, or cervical stenosis with the spine in the neutral position; (2) patients with a history of spinal surgery; (3) patients with serious heart diseases, arrhythmia, or hypertension, or who were elderly and infirm, with systemic diseases causing poor health, or those with serious internal medical diseases such as cardiac, pulmonary, hepatic, or renal dysfunction or tumor; (4) patients who were not suitable for MRI due to an implanted heart pacemaker, artificial tooth, or other reason; (5) patients with a mental disorder or history of noncooperation; (6) pregnant women; (7) men with age > 65 years and women with age > 60 years.

Imaging Examination

A 0.6-T upright multiposition MRI scanner (Fonar, Melville, New York, United States) was used in the study. Two vertically

orientated opposing magnetic doughnuts were used in the MRI unit to ensure that the patients were scanned in an upright, axially loaded position. T1-weighted sagittal spin-echo images (repetition time, 671 milliseconds; echo time, 17 milliseconds; thickness, 3.0 mm; field of view, 24 cm; matrix, 256 × 200; number of excitations, two) and T2-weighted sagittal fast spin-echo images (repetition time, 3,432 milliseconds; echo time, 160 milliseconds; thickness, 3.0 mm; field of view, 24 cm; matrix, 256 × 224; number of excitations, two) were obtained using a flexible surface coil. All images were obtained with the patient seated and the spine in extension (20 degrees), neutral, and flexion (30 degrees) positions.

Measurement Method

The measurements were made directly from the digital images using digital imaging software (MRAnalyzer, TrueMRI, Bellflower, California, United States) and were obtained at six different segments of the spine from C2–C3 to C7–T1. The basic measurements involved the diameter of the spinal canal (at the level of the disk), the disk bulge diameter, the Cobb angle, and the vertebral translational motion in flexion, neutral, and extension positions (► Fig. 1).

The thickness of the ligamentum flavum (at the level of the disk) and the degree of disk degeneration were measured manually.⁵ The ligament thickness was the mean of the values measured by two physicians independently. The values were compared using reliability analysis on SPSS20.0 software (SPSS Inc., Chicago, Illinois, United States), and the reliability was accepted (Cronbach $\alpha = 0.910$). The degree of disk degeneration was determined independently by two physicians using a modification of the system described by Pfirrmann et al.⁵ If these measurements (grade 1 to 5) were not in agreement, the advice of a senior physician with more experience was obtained and a consensus was reached.

Statistical Analysis

Statistical analyses were performed using SPSS20.0 software. Analyses of whether the data was normally distributed were

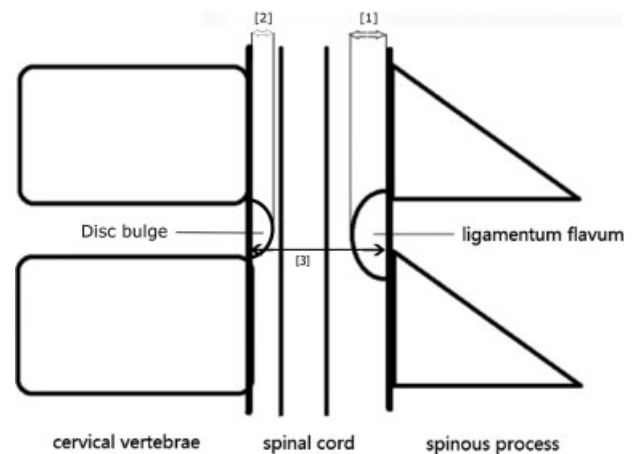


Fig. 1 Abridged overview of the method used to measure the diameter of cervical spinal canal, disk bulge, and ligamentum flavum on magnetic resonance images. [1] Ligamentum flavum thickness; [2] diameter of disk bulge; [3] diameter of spinal canal.

Table 1 Diameters (mm) of the spinal canal, ligamentum flavum, and disk bulge

	C2	C3	C4	C5	C6	C7
Spinal canal						
Extension	12.30 ± 1.77	10.47 ± 1.93	10.12 ± 1.84	10.04 ± 1.77	10.68 ± 1.83	12.21 ± 1.77
Flexion	12.29 ± 1.63	11.09 ± 1.71	11.19 ± 1.76	10.96 ± 1.89	11.36 ± 1.83	12.29 ± 1.80
p Value	0.900	<0.001	<0.001	<0.001	<0.001	0.418
Ligamentum flavum						
Extension	2.58 ± 0.75	2.59 ± 0.73	2.51 ± 0.74	2.52 ± 0.67	2.81 ± 0.81	3.20 ± 0.75
Flexion	2.40 ± 0.69	2.31 ± 0.56	2.25 ± 0.59	2.29 ± 0.69	2.47 ± 0.70	2.95 ± 0.69
p Value	0.004	<0.001	<0.001	<0.001	<0.001	<0.001
Disk bulge						
Extension	2.18 ± 0.62	2.56 ± 0.75	2.61 ± 0.81	2.69 ± 0.79	2.67 ± 0.81	2.02 ± 0.60
Flexion	2.31 ± 0.71	2.38 ± 0.61	2.27 ± 0.73	2.38 ± 0.83	2.26 ± 0.84	1.82 ± 0.62
p Value	<0.001	<0.001	<0.001	<0.001	<0.001	<0.001

Note: Results are mean ± standard deviation.

performed with the Kolmogorov-Smirnov test. The measurement data was expressed as mean ± standard deviation when the data was normally distributed, and expressed as mean (25th percentile, 75th percentile) when the data was not normally distributed. Analyses were performed using the independent samples *t* test and the paired *t* test when data was normally distributed, and the Mann-Whitney rank test when data was not normally distributed. A *p* value of <0.05 was considered statistically significant.

Results

► **Table 1** shows the mean diameters of the spinal canal, ligamentum flavum, and disk bulge at the different segments in extension and flexion positions. The data in all segments was normally distributed (*p* > 0.05). The diameter of ligamentum flavum was not significantly different between male and female subjects (*p* = 0.893). For all segments, the mean increase in the diameter of the ligamentum flavum from flexion to extension was 0.26 ± 0.85 mm, the mean decrease in the diameter of the spinal canal was 0.56 ± 1.21 mm, and the mean increase in the diameter of the disk bulge was 0.22 ± 0.77 mm (*n* = 1134). In 62.7% (*n* = 711) of the patients, the diameter of the ligamentum flavum was increased in extension versus flexion, and in 17.65% (*n* = 200), the increase was >1 mm. In 59.61% (*n* = 676), the bulge diameter increased between extension and flexion, and in 13.05% (*n* = 148), the increase was >1 mm.

Relationships among the Diameters of the Ligamentum Flavum, Disk Bulge, and Spinal Canal

Spinal Canal Diameter

The trend in the mean diameter of the spinal canal with the spine in different positions was: extension < neutral < flexion (except C2–C3). The mean diameter of the spinal canal from C3–C4 to C6–C7 was significantly smaller in extension than in flexion (*p* < 0.05), whereas at C2–C3 and at C7–T1, the differences were not significant (*p* > 0.05).

For each segment, patients with cervical spinal canal narrowing ≥1 mm (from flexion to extension) were assigned to group CVI, and those with cervical spinal canal narrowing < 1 mm (from flexion to extension) were assigned to group CVII (► **Table 2**). The increased diameters of the ligamentum flavum (from flexion to extension) in the two groups were subjected to an independent sample *t* test. For all segments with cervical spinal canal narrowing, the increased diameter of the ligamentum flavum at C4–C5 (*p* < 0.001) and C5–C6 (*p* < 0.001) was significantly different between patients in group CVI and those in group CVII. By contrast, the changes in the ligamentum flavum diameters at C2–C3, C3–C4, C6–C7, and C7–T1 between the two groups were not significantly different (*p* > 0.05). The mean increases in the diameter of the ligamentum flavum are shown in ► **Fig. 2**.

The increases in the diameter of disk bulges (from extension to flexion) in the two groups were also subjected to an independent sample *t* test. For all segments with cervical

Table 2 Spinal canal diameter narrowing (*n*)

Group	C2–C3	C3–C4	C4–C5	C5–C6	C6–C7	C7–T1
CVI (≥1 mm)	25	57	90	78	63	39
CVII (<1 mm)	164	132	99	111	126	150

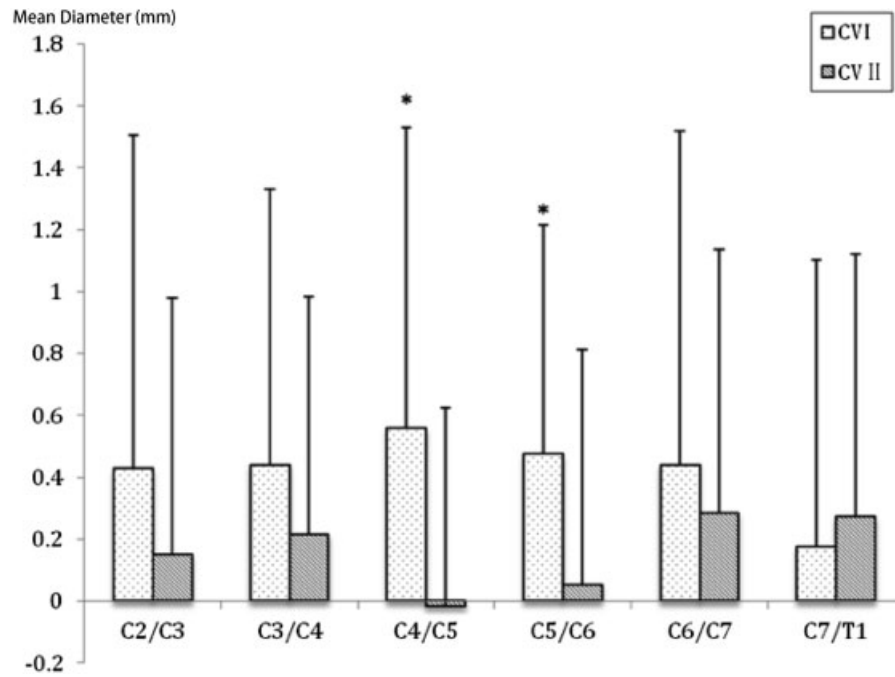


Fig. 2 Bar graph shows the dynamic changes in ligamentum flavum diameter (mean ± standard deviation) during flexion and extension of the cervical spine in groups defined according to differences in spinal canal diameter. Changes in the diameter of the ligamentum flavum between group CVI (patients with cervical spinal canal narrowing ≥1 mm from flexion to extension) and group CVII (patients with cervical spinal canal narrowing < 1 mm from flexion to extension) were compared. **p* < 0.05.

spinal canal narrowing, the increased diameter of the disk bulge at C2–C3 (*p* = 0.031), C3–C4 (*p* = 0.011), C4–C5 (*p* = 0.002), C5–C6 (*p* = 0.004), and C6–C7 (*p* = 0.007) was significantly different between group CVI and group CVII, whereas at C7–T1 the difference between the two groups was not significant (*p* = 0.874). The mean increases in the diameters of the disk bulge are shown in **Fig. 3**.

Ligamentum Flavum Thickness

The trend in the mean diameter of the ligamentum flavum in different positions was: extension > neutral > flexion (except C7–T1). The mean diameter of the ligamentum flavum from C2–C3 to C7–T1 was significantly larger during extension than during flexion (*p* < 0.05). The mean diameters of the ligamentum flavum at the different segments of

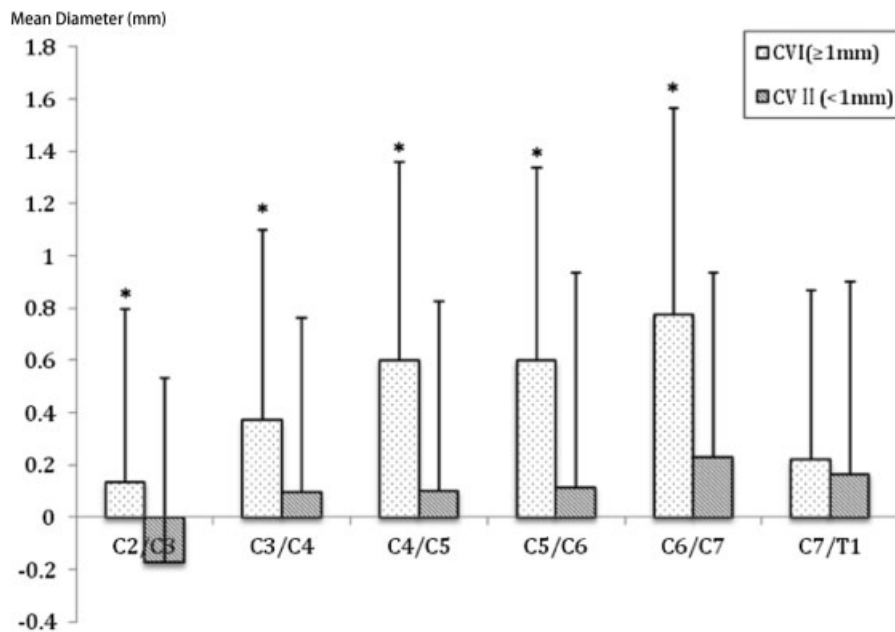


Fig. 3 Bar graph shows the dynamic changes in cervical disk bulge (mean ± standard deviation) during extension and flexion of the cervical spine in groups defined according to differences in spinal canal diameter. Changes in cervical disk bulge were compared between group CVI (patients with cervical spinal canal narrowing ≥1 mm from flexion to extension) and group CVII (patients with cervical spinal canal narrowing <1 mm from flexion to extension). **p* < 0.05.

Table 3 Ligamentum flavum variation (n)

Group	C2–C3	C3–C4	C4–C5	C5–C6	C6–C7	C7–T1
FVI (≥1 mm)	29	37	34	24	39	35
FVII (>0 to < 1 mm)	85	81	85	98	85	78
FVIII (≤0 mm)	75	71	70	67	65	75

the spine and in extension and flexion positions are shown in ►Table 1.

For each segment, patients with ligamentum flavum hypertrophy ≥1 mm (from flexion to extension) were assigned to group FVI; those with hypertrophy < 1 mm and > 0 mm were assigned to group FVII, and those with hypertrophy ≤0 mm were assigned to group FVIII (►Table 3). The decreases in the diameter of the spinal canal (from flexion to extension) in the three groups were compared in an independent sample *t* test. The decrease in the diameter of the spinal canal at C4–C5 significantly (*p* = 0.009) differed between group FVI and group FVII. For group FVIII, the decrease in the diameter of the spinal canal at C2–C3 (*p* = 0.048), C4–C5 (*p* = 0.003), and C5–C6 (*p* = 0.001) was significantly different from the decrease in group FVI. At other segments, the changes in spinal canal diameter did not differ significantly between the three groups (*p* > 0.05). The decreases in spinal canal diameters are shown in ►Fig. 4.

The increase in the diameters of the disk bulge (from flexion to extension) in the three groups was also analyzed using an independent sample *t* test. In a comparison between group FVII and group FVIII, the decrease in the diameter of the disk bulge at C3–C4 was significantly different (*p* = 0.026). At other segments, the differences in the changes in disk bulge

diameter between the three groups were not significant (*p* > 0.05). The increases in the disk bulge diameters are shown in ►Fig. 5.

Disk Bulge

The trend in the mean diameter of the disk bulge with the spine in different positions was: extension > neutral > flexion (except C2–C3). The mean diameter of the disk bulge from C3–C4 to C7–T1 was significantly larger with the spine in extension than in flexion (*p* < 0.05).

For each segment, patients with a disk bulge increase ≥1 mm (from flexion to extension) were assigned to group DVI and those with a disk bulge increase < 1 mm and > 0 mm to group DVII. Patients with a disk bulge increase ≤0 mm in the same segments were assigned to group DVIII (►Table 4). The decreases in the diameter of the spinal canal (from flexion to extension) in the three groups were then compared using an independent sample *t* test. At C3–C4 (*p* = 0.043), C4–C5 (*p* = 0.029), C5–C6 (*p* = 0.004), and C6–C7 (*p* = 0.002), the decrease in the diameter of the spinal canal differed significantly between group DVI and group DVII. Decreases in the diameter of the spinal canal at C2–C3 (*p* = 0.001), C3–C4 (*p* = 0.005), C4–C5 (*p* < 0.001), C5–C6 (*p* < 0.001), and C6–C7 (*p* < 0.001) were significantly different (*p* < 0.05) between group DVIII and group DVI. For the

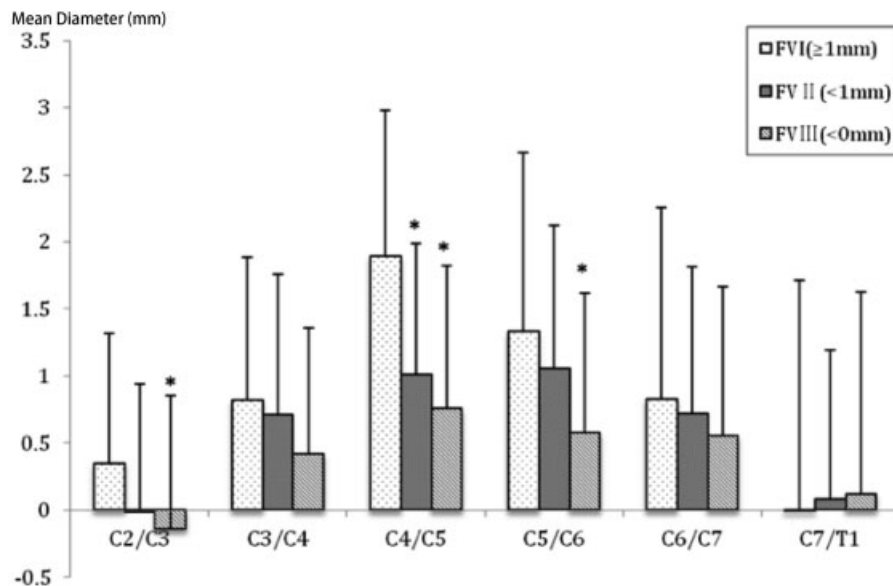


Fig. 4 Bar graph shows the dynamic changes in spinal canal diameter (mean ± standard deviation) during flexion and extension of the cervical spine in group FVI (patients with ligamentum flavum hypertrophy ≥1 mm from flexion to extension), group FVII (patients with ligamentum flavum hypertrophy < 1 mm and > 0 mm from flexion to extension), and group FVIII (patients with ligamentum flavum hypertrophy < 1 mm and > 0 mm from flexion to extension). Changes in spinal canal diameter in group FVI were compared with those in groups FVII and FVIII. **p* < 0.05.

This document was downloaded for personal use only. Unauthorized distribution is strictly prohibited.

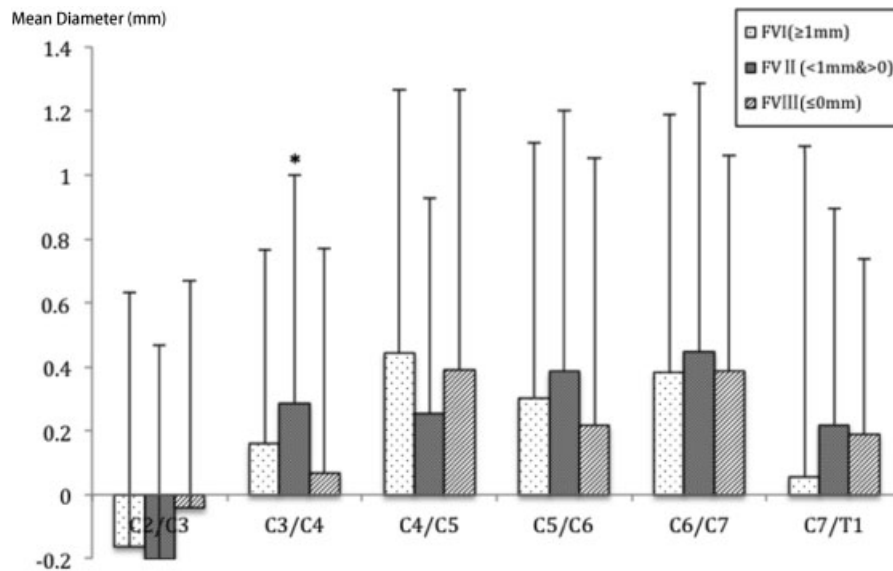


Fig. 5 Bar graph shows the dynamic changes in disk bulge diameter (mean ± standard deviation) during flexion and extension of the cervical spine in group FVI (patients with ligamentum flavum hypertrophy ≥ 1 mm from flexion to extension), group FVII (patients with ligamentum flavum hypertrophy < 1 mm and > 0 mm from flexion to extension), and group FVIII (patients with ligamentum flavum hypertrophy < 1 mm and > 0 mm from flexion to extension). Changes in spinal canal diameter in group FVIII were compared with those in groups FVI and FVII. **p* < 0.05.

changes in the spinal canal diameters at other segments, there were no significant differences (*p* > 0.05) between the three groups. The decreases in the diameter of the spinal canal are shown in ► **Fig. 6**.

The increases in the diameter of the ligamentum flavum (from flexion to extension) measured in the three groups were also compared in an independent sample *t* test. The increased diameter of the ligamentum flavum at C6–C7 was significantly different (*p* = 0.039) between groups DVI and DVIII, and the increased diameter of the ligamentum flavum at C5–C6 was significantly different (*p* = 0.008) between groups DVII and DVIII. At the other segments, the changes in ligamentum flavum diameter did not differ significantly (*p* > 0.05) between the three groups. The increases in the diameters of the ligamentum flavum are shown in ► **Fig. 7**.

Other Factors Affecting Ligamentum Flavum Hypertrophy

Translational Motion

For all segments with vertebral translational motion from flexion to extension, hypertrophy of the ligamentum flavum at C3–C4 was significantly different between patients with

vertebral translational motion ≥ 1 mm and < 1 mm (*p* = 0.029). The increases in the diameter of the ligamentum flavum at C3–C4 were 0.40 ± 0.84 (*n* = 102) and 0.15 ± 0.77 (*n* = 87), respectively. At other segments, the changes in ligamentum flavum diameter did not differ significantly between the two groups (*p* > 0.05).

Cobb Angle

For all segments with a variation in the Cobb angle from flexion to extension, ligamentum flavum hypertrophy at C4–C5 was significantly greater in patients with variations < 45 degrees than in those with variations ≥ 45 degrees (*p* = 0.033). The increased diameters of the ligamentum flavum in the two groups at C4–C5 were 0.12 ± 0.71 (*n* = 86) and 0.37 ± 0.95 (*n* = 103), respectively. The changes in ligamentum flavum diameter at other segments did not differ significantly between the two groups (*p* > 0.05).

The Degree of Disk Degeneration

Five groups (I–V) were defined according to the degree of disk degeneration. At all segments, there were no significant differences between the five groups regarding the changes in ligamentum flavum diameter (*p* > 0.05).

Table 4 Disk bulge variation (*n*)

Group	C2–C3	C3–C4	C4–C5	C5–C6	C6–C7	C7–T1
DVI (≥ 1 mm)	12	22	31	29	34	20
DVII (< 1 mm)	68	98	99	106	101	113
DVIII (≤ 0 mm)	109	69	59	54	54	55

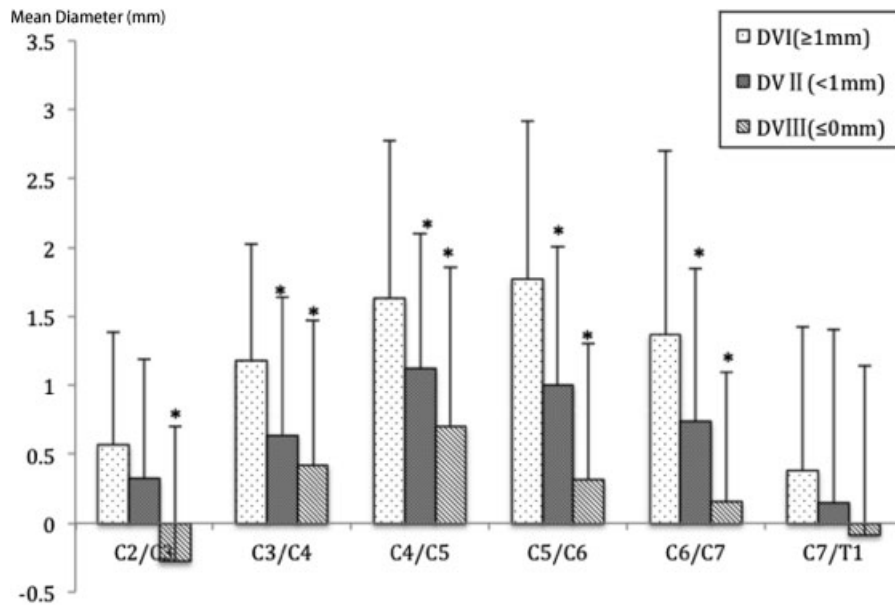


Fig. 6 Bar graph shows the dynamic changes in spinal canal diameter (mean ± standard deviation) during flexion and extension of the cervical spine in group DVI (patients with a disk bulge increase ≥ 1 mm from flexion to extension), group DVII (patients with a disk bulge increase < 1 mm and > 0 mm from flexion to extension), and group DVIII (patients with a disk bulge increase ≤ 0 mm from flexion to extension). Changes in the spinal canal diameter variation of group DVIII were compared with those in groups DVI and DVII. **p* < 0.05.

Ligamentum Flavum Diameter in Neutral Position

For each segment, patients with a ligamentum flavum diameter ≤ 2 mm (in neutral view) were assigned to group FDI, those with ligamentum flavum diameter ≤ 3 mm and > 2 mm to group FDII, and those with ligamentum flavum diameter > 3 mm to group FDIII. The increase in ligamentum flavum diameter from flexion to extension at C7–T1 did not differ significantly (*p* < 0.05) between groups FDI and FDII, but at C3–C4 (*p* = 0.046) and C7–T1 (*p* = 0.021), the difference between group FDI and group FDIII was significant. At

C3–C4, the increase in the diameter of the ligamentum flavum between group FDII and group FDIII was significantly different (*p* = 0.017). The increases in the diameter of the ligamentum flavum in the three groups were: C3–C4 (0.22 ± 0.68, *n* = 51; 0.21 ± 0.78, *n* = 113; 0.73 ± 1.06, *n* = 25), C7–T1 (−0.33 ± 1.09, *n* = 12; 0.24 ± 0.76, *n* = 73; 0.33 ± 0.89, *n* = 104, for groups FDI, FDII, and FDIII, respectively). At the other segments, the changes in ligamentum flavum diameter did not differ significantly (*p* > 0.05) between the three groups.

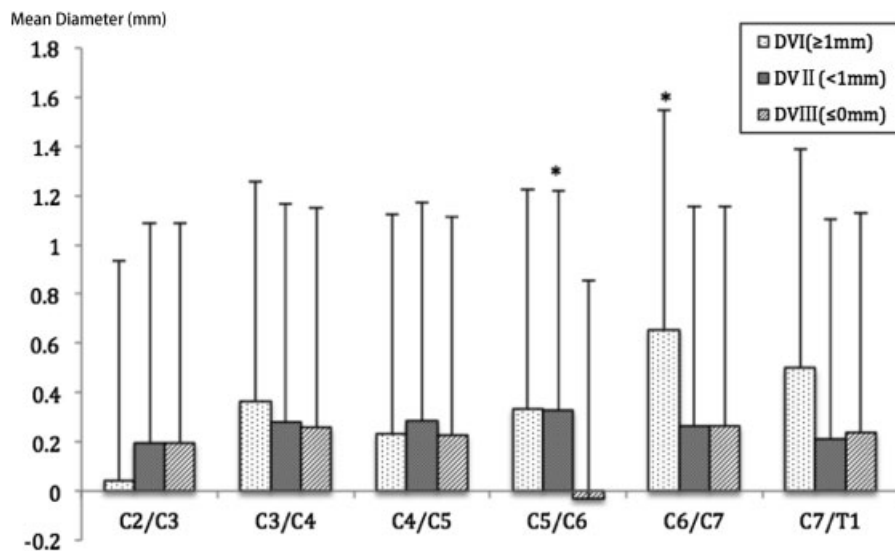


Fig. 7 Bar graph shows the dynamic changes in ligamentum flavum diameter (mean ± standard deviation) during flexion and extension of the cervical spine in group DVI (patients with a disk bulge increase ≥ 1 mm from flexion to extension), group DVII (patients with a disk bulge increase < 1 mm and > 0 mm from flexion to extension), and group DVIII (patients with a disk bulge increase ≤ 0 mm from flexion to extension). Changes in the ligamentum flavum diameter of group DVIII were compared with those of groups DVI and DVII. **p* < 0.05.

Spinal Canal Diameters

For each segment, patients with a spinal canal diameter ≤ 10 mm (in neutral view) were assigned to group CDI, those with a canal diameter ≤ 12 mm and > 10 mm to group CDII, and those with a canal diameter > 12 mm to group CDIII. At C3–C4, the increase in the diameter of the ligamentum flavum from flexion to extension view was significantly different ($p < 0.05$) between group CDI and group CDIII ($p = 0.026$). The increases in the diameter of the ligamentum flavum in the three groups at C3–C4 were 0.34 ± 0.85 ($n = 77$), 0.38 ± 0.81 ($n = 66$), and 0.04 ± 0.71 ($n = 46$), for groups CDI, CDII, and CDIII, respectively. At other segments, the changes in ligamentum flavum diameters did not differ significantly ($p > 0.05$) between the three groups.

Discussion

The volume and diameter of the cervical spinal canal are not constant; rather, the shape of the spinal canal changes from extension to flexion as the diameter of the osseous canal narrows during extension and widens during flexion.⁶ The spinal cord, spinal dura mater, vertebral disks, and ligamentum flavum also change during movement of the cervical spine. In patients with cervical spondylosis, the diameter of the osseous canal is reduced, but there are also abnormal alterations in the associated soft tissue elements, including the vertebral disks and ligamentum flavum. These changes are not normally visualized when imaging is performed at different positions of the neck. Moreover, in patients with cervical spondylosis, plain radiographs in flexion and extension fail to show the dynamic soft tissue changes. Thus, in the past 10 years, k-MRI has been increasingly used in the imaging of the cervical spine as it also demonstrates soft tissue pathologies.⁷

Previous studies have demonstrated that dynamic change in disk bulge was a major factor in cervical spinal stenosis,³ especially in patients without typical symptoms but with cervical canal stenosis or cervical disk bulge detected with conventional neutral MRI or computed tomography. But the influence of dynamic ligamentum flavum thickness in those patients was always neglected. In this study, we demonstrated that “hidden” hypertrophy of the ligamentum flavum indeed exists (from flexion to extension). The increase in cervical disk bulge and in the diameter of the ligamentum flavum had significant effects on the spinal canal diameter, especially at C4–C5 and C5–C6, the segments most vulnerable to cervical canal stenosis.^{8,9} The results of this study showed that the diameter of the ligamentum flavum had similar dynamic changes as intervertebral disks during cervical movement. Although the dynamic change of the disk bulge was greater than the change of ligamentum flavum thickness, it still indicates that the dynamic “hidden” ligamentum flavum hypertrophy could be an independent factor besides dynamic disk bulge in some patients with cervical canal stenosis. Furthermore, with the increased application of non-fusion surgery (such as cervical artificial disk replacement) for cervical disk herniation in recent years, the postoperative cervical movement could be much greater than anterior fixation surgery, and the posterior compression caused by

dynamic ligamentum flavum hypertrophy may still remain, even though the posterior compression was not severe on neutral MRI.

The mean diameter changes of the ligamentum flavum in this study were small (< 0.5 mm), compared with the mean diameter of spinal canal (> 10 mm). However, the data was collected from individuals without severe cervical disease, not patients with spinal canal stenosis. For patients with severe spinal canal stenosis, even a tiny change in spinal canal volume may lead to the development of myelopathy, and the long-term repeated stimulation of the thickened ligamentum flavum may also aggravate the existing disease. Furthermore, although the mean change of ligamentum flavum thickness was small, diameter changes in 17.65% of individuals were more than 1 mm, which could be clinically meaningful.

Our study also showed that both spinal canal diameter (in neutral view) and translational motion have significant effects regarding the increased diameter of the ligamentum flavum at C3–C4 but not at other levels. Patients with spinal spondylosis, congenital spinal canal stenosis, or cervical instability are more vulnerable to trauma,¹⁰ which according to our findings may be explained by the “hidden” hypertrophy of the ligamentum flavum. The change in the diameter of the ligamentum flavum is mainly due to physical buckling, induced by the extent of the movement (as measured by variations in the Cobb angle), cervical spine instability (as measured by translational motion), and physical factors related to the ligamentum flavum itself, including its diameter, shape, and pliability. Although our study provides evidence of a relationship between these factors and the change in ligamentum flavum diameter, there was no significant universal trend for every cervical level. Instead, alterations in ligamentum flavum diameter may involve the interaction of Cobb angle variation, vertebral translational motion, ligamentum flavum thickness, and spinal canal diameter (in neutral position). There was no evidence of relation between “hidden” ligamentum flavum hypertrophy and cervical disk degeneration.

The thickness of the ligamentum flavum was the same in patients with cervical spondylosis as in healthy individuals. However, in cervical spondylosis, the ligamentum flavum becomes thicker, harder, and longer and loses elasticity.¹¹ Thus, during movement of the cervical vertebrae, the longer and harder ligamentum flavum may crease and protrude into the spinal canal causing compression of the spinal cord, which can be demonstrated on MRI as an increased diameter of the ligamentum flavum.¹² For some patients, movement from flexion to extension causes significant compression of the spinal cord and therefore clinical symptoms. However, MRI in the neutral position may not demonstrate compression.¹³ For these patients, additional k-MRI in extension and flexion views could provide the information necessary for a correct diagnosis.

Our study had several limitations. First, all of the patients in this study had symptoms of neck or arm pain, and there was no control group. Therefore, our results may not be applicable to patients with asymptomatic cervical spondylosis or with disk herniation. Second, disk bulge and ligamentum flavum diameters were measured on sagittal rather than on axial images. Thus, the diameter may not have been the

widest one as determined from all imaging planes. However, the inclusion criteria were patients with symptoms of neck or shoulder pain and with no evidence of cervical disk herniation and spinal canal stenosis. Thus, the lack of sagittal images may not have been problematic given the large sample size of this study. Third, although statistically significant changes in measurements were found, the actual changes are small (in many cases < 0.5 mm) and may not be clinically relevant. And because this study was only a retrospective review of radiographic data, a prospective study of clinical data to confirm that these changes were related to clinical findings is needed in subsequent studies. Indeed, it may be beneficial to compare k-MRI and long-term clinical trials pertaining to cervical spondylosis and spinal cord injury. In addition, research into the risk factors of “hidden” ligamentum flavum hypertrophy is needed.

In conclusion, the “hidden” hypertrophy of ligamentum flavum exists during cervical movement. It was significant at C4–C5 and C5–C6 and significantly contributes to the stenosis of the cervical spinal canal in the extension position.

Disclosures

Jian Xiong, none

Cheng Zeng, none

Jeffrey C. Wang, Royalties: Biomet, Armedica, Osprey, Aesculap, Synthes, Seaspine, Stryker, Alphatec; Personal investments: Fziomed, Promethean Spine, Paradigm Spine, Benevenue, NexGen, Pioneer, Amedica, Vertiflex, Electrocore, Surgitech, Axiomed, VG Innovations, Core-spine, Expanding Orthopaedics, Syndicom, Osprey, Bone Biologics, Curative Biosciences, Pearldiver, Pioneer; Reimbursement for travel: board meeting/activities for AO-Spine, NASS, CSRF, CSRS; Fellowship support: AO Foundation; Editorial board: *Global Spine Journal*, *The Spine Journal*, *JAAOS*, *The Journal of Spinal Disorders and Techniques*, *Journal of Orthopaedic Trauma*

Hirokazu Inoue, none

Yanlin Tan, none

Haijun Tian, none

Bayan Aghdasi, none

References

- 1 Miura J, Doita M, Miyata K, et al. Dynamic evaluation of the spinal cord in patients with cervical spondylotic myelopathy using a kinematic magnetic resonance imaging technique. *J Spinal Disord Tech* 2009;22(1):8–13
- 2 Fukui K, Kataoka O, Sho T, Sumi M. Pathomechanism, pathogenesis, and results of treatment in cervical spondylotic myelopathy caused by dynamic canal stenosis. *Spine (Phila Pa 1976)* 1990; 15(11):1148–1152
- 3 Fei Z, Fan C, Ngo S, Xu J, Wang J. Dynamic evaluation of cervical disc herniation using kinetic MRI. *J Clin Neurosci* 2011;18(2):232–236
- 4 Daffner SD, Xin J, Taghavi CE, et al. Cervical segmental motion at levels adjacent to disc herniation as determined with kinetic magnetic resonance imaging. *Spine (Phila Pa 1976)* 2009; 34(22):2389–2394
- 5 Pfirrmann CWA, Metzdorf A, Zanetti M, Hodler J, Boos N. Magnetic resonance classification of lumbar intervertebral disc degeneration. *Spine (Phila Pa 1976)* 2001;26(17):1873–1878
- 6 Bartlett RJ, Hill CA R, Rigby AS, Chandrasekaran S, Narayanamurthy H. MRI of the cervical spine with neck extension: is it useful? *Br J Radiol* 2012;85(1016):1044–1051
- 7 Abitbol JJ, Hong SW, Khan S, et al. *Dynamic MRI of the spine. In: Surgery for Low Back Pain*. Berlin, Heidelberg, Germany: Springer; 2010:39–45
- 8 Jinkins JR, Dworkin JS, Damadian RV. Upright, weight-bearing, dynamic-kinetic MRI of the spine: initial results. *Eur Radiol* 2005; 15(9):1815–1825
- 9 Hinck VC, Sachdev NS. Developmental stenosis of the cervical spinal canal. *Brain* 1966;89(1):27–36
- 10 Jia LS, Shen QA, Chen DY, Zhang WM. Dynamic changes of the cervical ligamentum flavum in hyperextension–hyperflexion movement and their measurements. *Chin Med J (Engl)* 1990; 103(1):66–70
- 11 Gu R, Zhu Q, Lin Y, Yang X, Gao Z, Tanaka Y. Dynamic canal encroachment of ligamentum flavum: an in vitro study of cadaveric specimens. *J Spinal Disord Tech* 2006;19(3):187–190
- 12 Sairyo K, Biyani A, Goel V, et al. Pathomechanism of ligamentum flavum hypertrophy: a multidisciplinary investigation based on clinical, biomechanical, histologic, and biologic assessments. *Spine (Phila Pa 1976)* 2005;30(23):2649–2656
- 13 Miyazaki M, Hong SW, Yoon SH, et al. Kinematic analysis of the relationship between the grade of disc degeneration and motion unit of the cervical spine. *Spine (Phila Pa 1976)* 2008;33(2): 187–193