

# A nitrous oxide abuser presenting with cerebral venous thrombosis: A case report

SHUM-SHIN LIN<sup>1</sup>, I-WEI FAN<sup>1</sup>, CHUN-YU CHEN<sup>2</sup> and YU-JANG SU<sup>3-6</sup>

<sup>1</sup>Department of Emergency Medicine, Tao-Yuan General Hospital, Taoyuan City 330; <sup>2</sup>Department of Neurology, Neurological Institute, Taipei Veterans General Hospital, Taipei 112201; <sup>3</sup>Department of Emergency Medicine, Mackay Memorial Hospital, Taipei 10449; <sup>4</sup>Department of Medicine, Mackay Medical College, New Taipei City 252; <sup>5</sup>Department of Nursing, Mackay Junior College of Medicine, Nursing, and Management, Taipei 11260; <sup>6</sup>Department of Nursing, Yuanpei University of Medical Technology, Hsinchu 30015, Taiwan, R.O.C.

Received April 6, 2022; Accepted June 6, 2022

DOI: 10.3892/mi.2022.45

**Abstract.** The present study describes the case of a 25-year-old male patient who presented to the emergency department with severe headache and vertigo lasting for 3 days. The patient did not have a recent history of trauma. He was vaccinated with a second dose of the AstraZeneca COVID-19 vaccine ~1 month prior, and he suffered from a vitamin B12 deficiency due to nitrous oxide abuse. Upon an examination of his vital signs, he was found to have a body temperature of 36.4°C, a pulse rate of 64 beats per minute, a respiratory rate of 18 breaths per minute and a blood pressure of 119/68 mmHg. A neurological examination only revealed left homonymous upper quadrantanopia. The serum platelet count of the patient was 361x1,000/ $\mu$ l and he had elevated D-dimer levels (0.98  $\mu$ g/ml). A provisional clinical diagnosis of acute cerebrovascular accident was made. A computed tomography scan of the head revealed an abnormal hyperattenuation in the straight sinus and bilateral transverse sinuses. A diagnosis of cerebral sinovenous thrombosis (CSVT) was made following a consultation with a neurologist. The patient was treated with enoxaparin at 6,000 IU, levetiracetam at 1,000 mg and mannitol at 100 ml via an intravenous drip. After admission, magnetic resonance venography revealed the absence of flow in the straight sinus and bilateral transverse sinuses. A thrombophilic investigation revealed a plasma homocysteine level of 59.03  $\mu$ mol/l (upper normal limit, 15.39  $\mu$ mol/l), a vitamin B12 level of <148 (lower normal limit, 187 pg/ml). CSVT secondary to homocystinemia was diagnosed. The treatment included anticoagulation and vitamin B12 supplementation. The patient was administered vitamin B12 at 500 mcg twice per day, pyridoxine at 50 mg per day, folic acid at 5 mg two times per day and edoxaban at 60 mg per

day. After 7 days of treatment, his headache and quadrantanopia were improved, and the patient was discharged.

## Introduction

In the coronavirus 2019 era, individuals who suffer from headaches and neurologic deficits may have an increased risk of developing acute cerebrovascular disease, particularly after receiving the COVID-19 vaccine (1). In a previous study performed in Mexico in May 2022 found that patients vaccinated with the AstraZeneca-Oxford vaccine with vaccination-induced immune thrombotic thrombocytopenia (VITT) were more likely to be young females (aged 21 to 77 years), who were administered the vaccine 5-14 days prior to the presentation of symptoms (2). The patients' signs, symptoms and imaging findings were consistent with those of cerebral sinovenous thrombosis (CSVT), or with thrombosis of the deep vein, lung and other sites. The laboratory findings of that study revealed thrombocytopenia, low fibrinogen levels and elevated D-dimer levels, while antibodies against platelet factor 4 were positive in the majority of assays performed (2). However, it should be noted that sometimes, in certain age groups of patients, these symptoms may be associated with congenital vascular anomalies or drug abuse (3,4). Carbon monoxide, viper envenomation, methylenedioxyamphetamine have been reported to lead to acute cerebral venous thrombosis (5-7).

The present study described the case of a young male who was a nitrous oxide (N<sub>2</sub>O) abuser with CSVT. The patient had received the second dose of the AstraZeneca COVID-19 vaccine at ~1 month prior to his presentation to the emergency department. His laboratory findings was not compatible with VITT.

## Case report

A 25-year-old male patient presented to the Emergency Department of Tao-Yuan General Hospital (Taoyuan City, Taiwan) with a severe headache and vertigo lasting for 3 days. He had a history of recurrent pulmonary embolism without regular medical follow-up and vitamin B12 deficiency due to N<sub>2</sub>O abuse. He had no recent trauma history. He had been

---

*Correspondence to:* Dr Yu-Jang Su, Department of Emergency Medicine, Mackay Memorial Hospital, No. 92, Sec 2, North Chung Shan Road, Taipei 10449, Taiwan, R.O.C.  
E-mail: yjsu.5885@mmh.org.tw

*Key words:* cerebral sinovenous thrombosis, homocysteine, nitrous oxide, neuropathy, vitamin B12

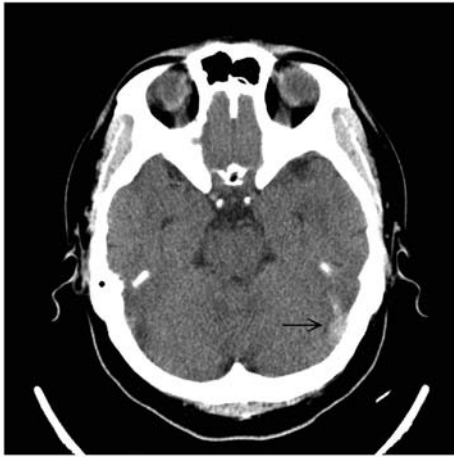


Figure 1. Computed tomography scan of the head illustrating an abnormal hyperattenuation (arrow) in the straight sinus and bilateral transverse sinuses.

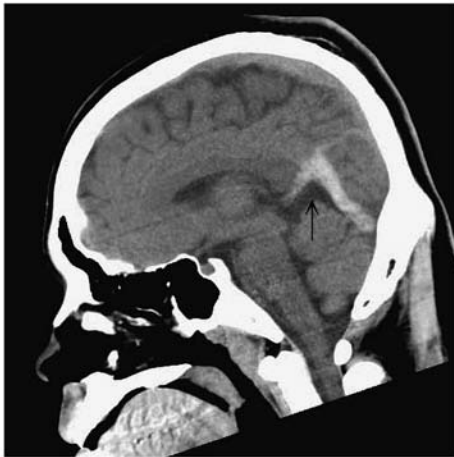

Figure 2. Lateral view of the computed tomography scan of the head illustrating an abnormal hyperattenuation (arrow) in the straight sinus and bilateral transverse sinuses.

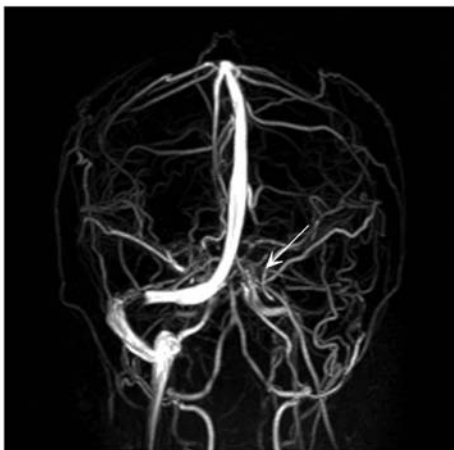

Figure 3. Magnetic resonance venography illustrating the absence of flow in the straight sinus and bilateral transverse sinuses (white arrow).

vaccinated with the second dose of the AstraZeneca COVID-19 vaccine at ~1 month prior to his admission.

Upon an examination of his vital signs, he was found to have a body temperature of 36.4°C, a pulse rate of 64 beats per minute, a respiratory rate of 18 breaths per minute and a blood pressure of 119/68 mmHg. A neurological examination only revealed left homonymous upper quadrantanopia. His serum white blood cell count was  $12.58 \times 10^3/\mu\text{l}$  with a neutrophil percentage of 68.7%, C-reactive protein level of 1.34 mg/l, a platelet count of  $361 \times 10^3/\mu\text{l}$  and elevated D-dimer levels ( $0.98 \mu\text{g/ml}$ ). A provisional clinical diagnosis of acute cerebrovascular accident was thus made.

A computed tomography (CT) scan of the head revealed an abnormal hyperattenuation in the straight sinus and bilateral transverse sinuses (Figs. 1 and 2). A diagnosis of CSVT was made following a consultation with a neurologist. The patient was treated with enoxaparin at 6,000 IU, levetiracetam at 1,000 mg and mannitol at 100 ml via an intravenous drip. Following admission, a magnetic resonance venography revealed the absence of flow in the straight sinus and bilateral transverse sinuses (Fig. 3). A thrombophilic investigation revealed a plasma homocysteine level of  $59.03 \mu\text{mol/l}$  (upper normal limit,  $15.39 \mu\text{mol/l}$ ) and a vitamin B12 level of  $<148$  (lower normal limit,  $187 \text{ pg/ml}$ ). The levels of protein C (70-140%), protein S (60-130%) and antithrombin III (75-125%) were within the normal range. CSVT secondary to homocystinemia was diagnosed, which is an unusual, yet treatable condition.

The treatment administered included anticoagulation and vitamin B12 supplementation. The patient was administered vitamin B12 at 500 mcg twice per day, pyridoxine at 50 mg per day, folic acid at 5 mg two times per day and edoxaban at 60 mg per day. After 7 days of treatment, his headache and quadrantanopia were improved, and the patient was discharged.

## Discussion

$\text{N}_2\text{O}$  is a recreational inhalant which exerts euphoric and hallucinatory effects and has recently become popular among adolescents and young adults in Taiwan. Previous studies have found several adverse effects related to the dysfunction of vitamin B12 metabolism, such as macrocytic anemia, peripheral neuropathy, skin hyperpigmentation, subacute combined degeneration of the spinal cord, deep vein thrombosis, pulmonary embolism, aortic thrombosis and bone marrow suppression. CSVT has an estimated incidence of 3-4 per million adults and 7 per million children per year, with a predominance among younger individuals (8).  $\text{N}_2\text{O}$  irreversibly oxidizes the cobalt atom of vitamin B12 and inhibits the methionine synthase, leading to an increased blood homocysteine level. Hyperhomocysteinemia and vitamin B12 deficiency are considered as risk factors for venous thrombosis (9-11).

During the COVID-19 era, post-vaccination cerebral venous thrombosis is the most common manifestation of VITT. In particularly, individuals who received the vaccine were found to suffer from headache with the acute onset of neurological deficits such as weakness, visual loss and hypotonia (1).

VITT commonly occurs at 7-10 days after the first dose of the vaccine; however, in the patient described herein, it occurred at 1 month after the second dose of the vaccine. The blood test did not meet the diagnostic criteria for VITT (platelet count  $<15 \times 10^3/\text{UI}$  and D-dimer levels  $>2 \mu\text{g/ml}$ ); thus, the consumption of  $\text{N}_2\text{O}$  was considered the leading cause

of cerebral venous thrombosis rather than the COVID-19 vaccine (12). The treatment of the patient included anticoagulation and vitamin B12 supplementation (13). In the present study, the patient was administered vitamin B12 at 500 mcg twice per day, pyridoxine at 50 mg per day, folic acid at 5 mg two times per day and edoxaban at 60 mg per day. After 7 days of treatment, his headache and quadrantanopia were improved, and the patient was discharged.

Apart from CSVT, nitrous oxide can damage multiple systems, particularly the nervous system; however, the exact mechanisms of N<sub>2</sub>O-induced toxicity remain controversial. The discontinuation of N<sub>2</sub>O use and the timely supplementation of vitamin B12 are essential for a good prognosis (14).

### Acknowledgements

Not applicable.

### Funding

No funding was received.

### Availability of data and materials

The datasets used and/or analyzed during the current study are available from the corresponding author on reasonable request.

### Authors' contributions

SSL was involved in the writing of the manuscript and in obtaining patient data. IWF was involved in obtaining patient data and in the treatment of the patient. CYC was involved in editing of the manuscript and in obtaining patient data. YJS was involved in the writing and editing of the manuscript, in the conception of the study and in the revision of the manuscript and correspondence. SSL and IWF confirm the authenticity of all the raw data. All authors have read and approved the final manuscript.

### Ethics approval and consent to participate

The patient provided written informed consent for his participation in the present case report.

### Patient consent for publication

The patient provided written informed consent for his data to be published.

### Competing interests

The authors declare that they have no competing interests.

### References

1. Qureshi MIA, Azam B, Waheed MA and Imran A: Venous sinus thrombosis after the first dose of Pfizer BioNTech vaccine. *BMJ Case Rep* 15: e247493, 2022.
2. Ornelas-Aguirre JM, Gómez-Alcalá AV and Ramírez-Leyva DH: Increment of D-dimer Associated with Immune Thrombotic Thrombocytopenia in ChAdOx1 nCoV-19 Vaccinated Individuals. *Arch Med Res* 53: 341-351, 2022.
3. Rasyid A, Mesiano T, Kurniawan M, Hidayat R, Mulyadi R, Nugroho SW, Yolanda S, Wiyarta E and Harris S: Spontaneous subarachnoid hemorrhage due to arteriovenous malformation mimicking migraine: A case report. *Radiol Case Rep* 17: 790-793, 2021.
4. Ohta K, Mori M, Yoritaka A, Okamoto K and Kishida S: Delayed ischemic stroke associated with methamphetamine use. *J Emerg Med* 28: 165-167, 2005.
5. Phinney TA, Gibb GJ and Laghari FJ: CO poisoning as an associated risk factor for CVT. *Am J Emerg Med* 36: 1123.e1-1123.e3, 2018.
6. Senthilkumaran S, Balamurugan N and Thirumalaikolandusubramanian P: Viper envenomation and cerebral venous thrombosis. *J Postgrad Med* 59: 171-172, 2013.
7. Goldstein LH, Mordish Y, Abu-Kishak I, Toledano M and Berkovitch M: Acute paralysis following recreational MDMA (Ecstasy) use. *Clin Toxicol (Phila)* 44: 339-341, 2006.
8. Alvis-Miranda HR, Milena Castellar-Leones S, Alcalá-Cerra G and Rafael Moscote-Salazar L: Cerebral Sinus venous thrombosis. *J Neurosci Rural Pract* 4: 427-438, 2013.
9. Gatt A and Makris M: Hyperhomocysteinemia and venous thrombosis. *Semin Hematol* 44: 70-76, 2007.
10. Farhat W, Pariente A and Mijahed R: Extensive cerebral venous thrombosis secondary to recreational nitrous oxide abuse. *Cerebrovasc Dis* 51: 114-117, 2022.
11. de Valck L, Defelippe VM and Bouwman NAMG: Cerebral venous sinus thrombosis: A complication of nitrous oxide abuse. *BMJ Case Rep* 14: e244478, 2021.
12. Perry RJ, Tamborska A, Singh B, Craven B, Marigold R, Arthur-Farraj P, Yeo JM, Zhang L, Hassan-Smith G, Jones M, *et al*: Cerebral venous thrombosis after vaccination against COVID-19 in the UK: A multicentre cohort study. *Lancet* 398: 1147-1156, 2021.
13. Pratt DN, Patterson KC and Quin K: Venous thrombosis after nitrous oxide abuse, a case report. *J Thromb Thrombolysis* 49: 501-503.
14. Xiang Y, Li L, Ma X, Li S, Xue Y, Yan P, Chen M and Wu J: Recreational nitrous oxide abuse: Prevalence, neurotoxicity, and treatment. *Neurotox Res* 39: 975-985, 2021.



This work is licensed under a Creative Commons Attribution-NonCommercial-NoDerivatives 4.0 International (CC BY-NC-ND 4.0) License.