

Contents lists available at [ScienceDirect](https://www.sciencedirect.com)

Respiratory Medicine Case Reports

journal homepage: <http://www.elsevier.com/locate/rmcr>

EBV-associated lymphoid interstitial pneumonia in IBD patient: Case report and literature review

Thaninee Prasoppokakorn^a, Thammathorn Assanasen^b, Poonchavist Chantranuwatana^b, Chusana Suankratay^{c,*}^a Department of Medicine, Faculty of Medicine, Chulalongkorn University, Bangkok, Thailand^b Department of Pathology, Chulalongkorn University, Bangkok, Thailand^c Division of Infectious Diseases, Department of Medicine, Faculty of Medicine, Chulalongkorn University, Bangkok, Thailand

ARTICLE INFO

Keywords:

Epstein-barr virus
EBV-Associated lymphoid interstitial pneumonia
Pulmonary lymphoproliferative disorder
Inflammatory bowel disease

ABSTRACT

Background: Lymphoid interstitial pneumonia (LIP) is categorized as a rare form of interstitial lung disease. Most cases are associated with autoimmune disease.

Case report: A 78-year-old male with Crohn's disease, presented with progressive dyspnea and dry cough for few weeks. The pathology of transbronchial lung biopsy was compatible with LIP and positive cells on EBER in situ hybridization. Blood EBV viral load was 85,715 copies/mL, compatible with EBV-associated LIP. All immunosuppressive agents were discontinued, but unfortunately the patient died due to hospital-acquired infections. In addition, we reviewed all reported cases of EBV-associated LIP in literature.

Conclusions: To our knowledge, we report herein the first case of EBV-associated LIP in an IBD patient. We postulate that LIP was the consequence from EBV reactivation, probably due to immunosuppressive agents and/or IBD itself. The physician should aware of this disease when taking care of immunosuppressive patients who present with acute interstitial pneumonitis.

1. Introduction

Lymphoid interstitial pneumonia (LIP) is categorized as a rare form of interstitial lung disease according to the classification of American Thoracic Society/European Respiratory Society [1]. The definite diagnosis requires both imaging and pathology. Chest computed tomogram reveals the presence of ground glass attenuation, centrilobular and subpleural nodules, and thickening of bronchovascular bundles. The pathologic are characterized by the presence of dense polyclonal interstitial lymphocytic infiltrates with widening interlobular and alveolar septa [2,3]. Most cases are associated with autoimmune disease or lymphoproliferative disorder [4].

EBV, a double-stranded DNA virus, belongs to the Herpesviridae family [5]. EBV is able to cause latent infection, and reactivation occurs when infected individuals develop immunosuppressive state. Primary EBV infection causes infectious mononucleosis syndrome, and chronic infection/reactivation can cause lymphoma, and lymphoproliferative disorder including post transplant lymphoproliferative disease (LPD) [6]. In latent phase of infection, viral protein has the ability to transform

mature B lymphocyte, resulting in uncontrolled its proliferation, as LPD [7].

Inflammatory bowel diseases (IBDs), including Crohn's disease and ulcerative colitis, have been reported to be associated with LPD [8,9]. However, to date, there have been no reports of EBV-associated LIP in IBD patients.

2. Case report

A 78-year-old male was hospitalized at King Chulalongkorn Memorial Hospital, Thailand, due to progressive dyspnea, dry cough, and fever for few weeks; and acute confusion for 1 day. He was diagnosed with Crohn's disease 2 years prior to admission due to chronic abdominal pain with watery diarrhea, and colonoscopy revealed multiple ulcers at ileocecal valve and ascending colon with pathology compatible with Crohn's disease. He had received prednisolone, azathioprine, and mesalazine. Prednisolone was tapered down to 7.5 mg for maintenance clinical remission.

Ten weeks prior to admission, he was hospitalized due to

* Corresponding author.

E-mail addresses: thanineeve@gmail.com (T. Prasoppokakorn), csuankratay@gmail.com (C. Suankratay).<https://doi.org/10.1016/j.rmcr.2020.101059>

Received 6 January 2020; Received in revised form 3 April 2020; Accepted 11 April 2020

Available online 18 April 2020

2213-0071/© 2020 The Authors.

Published by Elsevier Ltd.

This is an open access article under the CC BY-NC-ND license

<http://creativecommons.org/licenses/by-nc-nd/4.0/>.

hematochezia, and colonoscopy revealed multiple ulcers at terminal ileum, and ascending colon. The pathology exhibited severe colitis with negative results of owl's cells and CMV-infected cells on immunohistochemistry. However, his blood Cytomegalovirus (CMV) viral load was 595 copies/mL. A diagnosis of CMV colitis was made, and ganciclovir was given for 6 weeks to maintain undetectable viremia. Unfortunately one month prior to admission, he developed hematochezia again, colonoscopy revealed some healed ulcers at terminal ileum, and ascending colon despite new multiple clean-based ulcer at ileocaecal valve. The pathological exhibited moderate chronic active ileitis despite CMV viral load suppression. The diagnosis of active Crohn's disease was made, oral prednisolone of 60 mg/day and infliximab were then given in accompanying with azathioprine of 50 mg and mesalazine of 3000 mg.

His past medical history included hypertension, dyslipidemia, and old ischemic stroke.

Upon admission, the patient had bitemporal throbbing headache and sudden onset of altered mentation, cranial computed tomogram (CT) revealed diffuse brain atrophy with small intraventricular hemorrhage in occipital horns of lateral ventricles without evidence of obvious aneurysm. Lumbar puncture revealed xanthochromic cerebrospinal fluid (CSF) with white blood cell (WBC) of 9 cells/ μ L, red blood cell (RBC) of 51,000 cells/ μ L, glucose of 51 mg/dL, protein of 48 mg/dL, and negative results of herpes simplex virus (HSV), varicella zoster virus (VZV), and CMV polymerase chain reaction (PCR). Chest X-ray showed bilateral interstitial infiltrates. Complete blood count analysis revealed hemoglobin (Hb) of 8.4 g/dL, WBC of 3460/ μ L (neutrophil 87.5%, lymphocyte 6.2%, monocyte 5.7%), and platelet of 138,000/ μ L. Peripheral blood smear exhibited moderate polychromasia and microspherocytes, and direct Coombs' test was strongly positive, compatible with autoimmune hemolytic anemia (AIHA). Blood CMV and EBV viral loads were 21,709 and 85,715 copies/mL, respectively. There were negative CMV viral capsid antigen (VCA) IgM, positive CMV VCA IgG, negative EBV VCA IgM, positive EBV VCA IgG, and positive EBV nuclear antigen (EBNA) IgG in the serum. Bone marrow aspiration and biopsy showed hypocellularity, no abnormal cell infiltrates, and negative result of EBV-encoded RNA (EBER) in situ hybridization. A presumptive diagnosis of CMV syndrome was made, and intravenous ganciclovir was given. Nevertheless, during hospitalization, his clinical condition had gradually worsened and he finally developed acute respiratory failure

requiring ventilator support. Chest CT revealed diffuse interstitial mixed with multifocal irregular consolidation infiltrates (Fig. 1). Bronchoscopy and bronchoalveolar lavage showing WBC of 139 cells/ μ L (neutrophils 53%). The pathology of transbronchial biopsy exhibited diffuse interstitial infiltrates with lymphocytes and plasma cells, without viral inclusion bodies. CMV immunohistochemistry was negative, but EBER in situ hybridization (ISH) exhibited 10 positive cells per total 100 lymphocytes by processing automated chromogenic ISH was performed using EBER Probe, known prediagnosed cases of EBER-positive cell were taken as positive controls, as well as nonneoplastic cells were taken as negative controls (Fig. 2). Two weeks after treatment, his blood CMV viral load was down to 214 copies/mL and eventually undetectable in three weeks course of ganciclovir, whereas EBV viral load was still 549,697 copies/mL. Hence, a final diagnosis of EBV-associated lymphocytic interstitial pneumonitis was made, and all immunosuppressive agents were discontinued. Unfortunately, the patient developed multiple hospital-acquired infections, including of *Pneumocystis jiroveci* pneumonia, pulmonary aspergillosis, and multidrug-resistant bacteria infection, and eventually expired 5 weeks after hospitalization.

3. Discussion

To our knowledge, we reported the first case of EBV-associated LIP in an IBD patient. We postulate that LIP in our patient was the consequence from EBV reactivation, probably due to immunosuppressive state from immunosuppressive agents and/or IBD itself.

LIP is a rare interstitial lung disease. It represents a nonspecific response to stimuli, and has been reported to be associated with systemic disorders including autoimmune, lymphoproliferative, and infectious diseases [2]. To date, there have been handful cases of EBV-associated LIP. Our case had both CT and pathological findings compatible with LIP. CT revealed diffuse interstitial mixed with multifocal irregular consolidation infiltrates, and the pathology exhibited diffuse interstitial infiltrates of lymphocytes and plasma cells. There were also 10 positive cells per total 100 lymphocytes on EBER in situ hybridization testing which are very high in comparison with normal individuals. In addition, blood EBV viral load was persistently high during the course of his illness. We postulate that LIP in our case should be in association with EBV infection. The immunopathogenesis of EBV-associated LIP has been

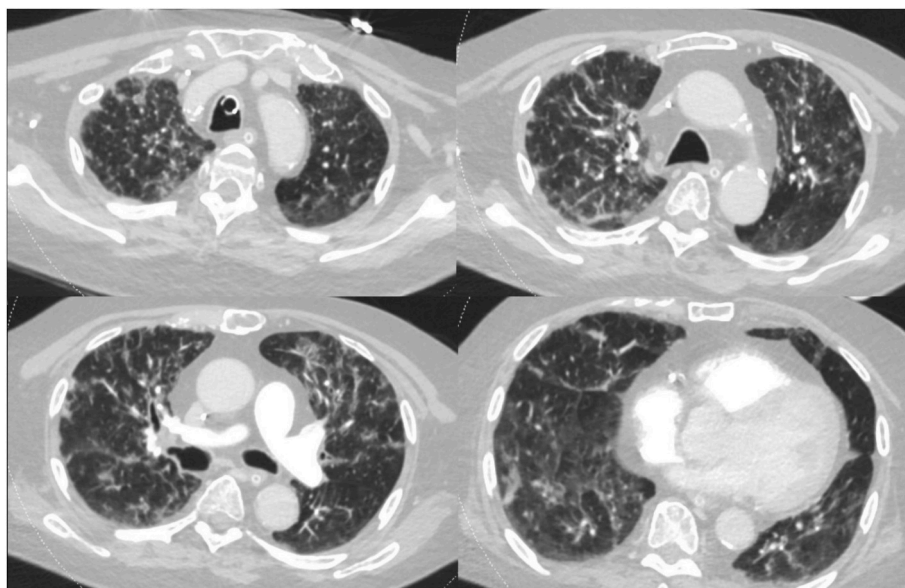


Fig. 1. Chest computed tomography revealed diffuse interstitial mixed with multifocal irregular consolidation infiltrates.

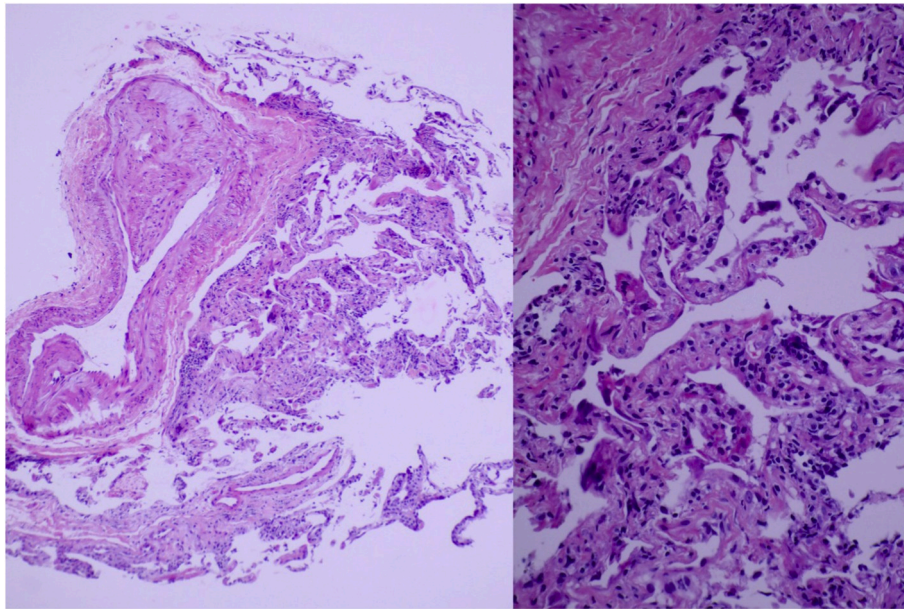


Fig. 2. Haematoxylin and eosin stain pathology of transbronchial biopsy (left) low power field revealed diffuse interstitial infiltrates with lymphocytes and plasma cells, and (right) high power field revealed florid lymphocytic interstitial infiltrates predominantly.

proposed [4]. Chronic EBV infection can drive the proliferation and probably transformation of B lymphocytes in bronchus-associated lymphoid tissue which subsequently progresses to LIP [4]. Among normal individuals, EBV is in the latency phase of infection due to the host's immune surveillance against the virus. In contrast, latent EBV infection can be reactivated to become chronic infection leading to LPD in individuals with immunosuppressive state [5]. Notably, the prototype of pathogenesis in EBV-driven LPD is PTLD [10]. In our case, there had been many immunosuppressive agents. CMV colitis, one of the opportunistic infection, is the strong evidence that our case had immunosuppressive state.

To our knowledge, the association between EBV infection and AIHA has not been reported. We postulate that the development of AIHA in our case should be due to the dysregulation of host immune response driven by chronic EBV infection.

4. Literature review

We reviewed all 16 patients with EBV-associated LIP published in English literature from 1986 to 2019 (Table 1 [11–20]). There were 5 males and 11 females with the mean age of 39.9 ± 17.3 (range: 17–78) years; our patient was the oldest patient in the literature. There were 5 Asians and 11 Caucasians. Of 16 patients, AIDS was the most common comorbidity (5 patients, 31.2%), followed by post splenectomy (2, 12.5%), and heart/lung transplantation, bone marrow transplantation, systemic lupus erythematosus, Sjogren's syndrome, polymyositis, chronic active EBV disease, and Crohn's disease (1 each, 6.2%). Cough was the most common clinical presentation (10, 62.5%), followed by fever (8, 50.0%), dyspnea (3, 18.7%), pleurisy (2, 12.5%), and respiratory failure (1, 6.2%). The duration of symptoms ranged from 5 days to 18 months. Of 16 patients, tachypnea was the most common signs (9,

56.2%), followed by abnormal lung sounds (5, 31.2%), lymphadenopathy (4, 25.0%), hepatomegaly, splenomegaly, hepatosplenomegaly (2 each, 12.5%). Of 5 patients with abnormal lung sounds, crepitation was the most common signs (3, 60.0%), followed by wheezing and decreased breath sound (1 each, 20.0%). In addition, the findings from imagings either chest X-ray or computed tomogram, reticulonodular pattern was the most common infiltration (5, 31.2%), followed by interstitial pattern (4, 25.0%), consolidation (3, 18.7%), septal thickening (3, 18.7%), and pleural effusion (1, 6.2%). All 16 patients had bilateral lung infiltrates, predominantly at the lower lung zone (10, 62.5%). Regarding the pathology, of 13 patients, diffuse interstitial lymphocytic infiltrate was the common finding (12, 92.3%), followed by peribronchial infiltration (6, 46.1%), vasculitis (2, 15.4%), and granulomatous inflammation (1, 7.7%). Of 13 patients, EBER hybridization was positive in 3 (23.0%) patients including our patient. Regarding EBV serology, 1 (6.2%), 12 (75.0%), 0 (0%), and 12 (75.5%) patients had positive VCA IgM, VCA IgG, early antigen-diffuse component (EA-D) IgM, and EA-D IgG, respectively. From the evidence of EBV serology, EBV-associated LIP develops from EBV reactivation. Due to no specific antiviral treatment for EBV infection/disease, discontinuation or dose reduction of immunosuppressive agents was done in 1 (6.5%) patients. Four (25.0%) patients had received immunomodulating agent including corticosteroid, cyclophosphamide, rituximab, subcutaneous interferon alpha. Complications reported acute respiratory distress syndrome, pulmonary hypertension, and bacterial septicemia (1 each, 6.2%). Of 10 patients, there were complete resolution (5, 50%), partial resolution (2, 20.0%), and fatal outcome (3, 30.0%); 6 patients had unknown outcome (37.5%).

Table 1
A summary of all 16 cases with EBV-associated lymphocytic interstitial pneumonitis reported from 1986 to 2019.

Patient	Gender/ age (year)	Race	Other medical problems	Clinical presentations	Duration	Physical findings*	Imaging/chest X- ray* (CXR)/CT	Histological finding	Anti VCA IgM/ IgG, anti EA-D IgM/IgG	Treatment	Complication	Outcome
1 [11] (1986)	F/18	Caucasian	None	Nonproductive cough, pleuritic chest pain	5 days	Lymphadenopathy, splenomegaly	CXR - Bilateral interstitial infiltrates of lower lungs	NA	1-160/ 1:40,960, 1:40/ 1:10,240	IV acyclovir	Mild restrictive lung disease, pulmonary hypertension	Complete resolution
2 [11] (1986)	F/17	India	None	Fever, pharyngitis	18 months	Splenomegaly	CXR - Bilateral patchy, nodular infiltrates	Interstitial infiltrate of mature lymphocytes in interalveolar septa, no EBV by DNA hybridization	NA/1:10,240, NA/1:>640	IV acyclovir	Virritis, <i>Pseudomonas</i> septicemia	Died
3 [12] (1992)	M/33	Haitian	AIDS	Nonproductive cough	NA	Tachypnea	CXR - Bilateral diffuse reticulonodular infiltrates prominent at basal lungs	Diffuse lymphocytic infiltrates in interstitium, peribronchial infiltration	-/+, -/+	NA	NA	NA
4 [12] (1992)	F/28	Haitian	AIDS	Nonproductive cough	NA	Tachypnea	CXR - Bilateral diffuse reticulonodular infiltrates prominent at basal lungs	Diffuse lymphocytic infiltrates in interstitium, peribronchial infiltration, vasculitis	-/+, -/+	NA	NA	NA
5 [12] (1992)	F/36	Caucasian	AIDS	Nonproductive cough	NA	Tachypnea	CXR - Bilateral diffuse reticulonodular infiltrates prominent at basal lungs	Diffuse lymphocytic infiltrates in interstitium, peribronchial infiltration	-/+, -/+	NA	NA	NA
6 [12] (1992)	M/35	Caucasian	AIDS	Nonproductive cough	NA	Tachypnea	CXR - Bilateral diffuse reticulonodular infiltrates prominent at basal lungs	Diffuse lymphocytic infiltrates in interstitium, peribronchial infiltration	-/+, -/+	NA	NA	NA
7 [12] (1992)	F/48	Caucasian	AIDS	Nonproductive cough	NA	Tachypnea	CXR - Bilateral diffuse reticulonodular infiltrates prominent at basal lungs	Diffuse lymphocytic infiltrates in interstitium, peribronchial infiltration	-/+, -/+	NA	NA	NA
8 [13] (1998)	F/39	Caucasian	Heart-lung transplant	NA	N	NA	CT - Multiple nodules and distributed consolidation, pleural and septal thickening	Polyclonal LPD, perivascular lymphocytic infiltrate extends into interstitium of alveolar walls, atypical large lymphoid cells	NA	Decrease in immunosuppression	NA	Partial resolution
9 [14] (1999)	M/65	Caucasian	Chronic lymphocytic leukemia	Fever, nonproductive cough	NA	Lymphadenopathy, hepatosplenomegaly	CT - Diffuse interstitial pneumonia in both lungs	In situ hybridization disclosed EBV-encoded small RNA in lymphoma cells (Richter's syndrome)	NA/1:2,560, NA/1:640	Chemotherapy	None	Died
10 [15] (2002)	F/50	Korean	SLE, Sjogren's syndrome	20 days	20 days	20 days	CXR - Bilateral consolidations in	Lymphoplasmacytic infiltrates in interstitial, In situ	NA	Corticosteroid cyclophosphamide	None	Complete resolution (continued on next page)

Table 1 (continued)

Patient	Gender/ age (year)	Race	Other medical problems	Clinical presentations	Duration	Physical findings*	Imaging/chest X- ray# (CXR)/CT	Histological finding	Anti VCA IgM/ IgG, anti EA-D IgM/IgG	Treatment	Complication	Outcome
11 [16] (2005)	F/27	Caucasian	Post splenectomy	Fever, dyspnea, cough, pleuritic chest pain	1 day	Unremarkable	Tachypnea, bibasilar crackling rales, hepatomegaly	lower lungs, pleural effusion	pleura foaming reactive lymphoid follicles with germinal centers, multifocal areas of vasculitis	Supportive	None	NA
12 [17] (2007)	M/53	Japanese	AML post bone marrow transplantation	Fever, fatigue, nonproductive cough	14 days	Unremarkable	CXR - Bilateral infiltration in lower lungs CT - Bilateral interstitial infiltration	Diffuse nonspecific interstitial pneumonitis with poorly defined granulomatous inflammation	<1:10/ 1:37,690, 1:20/ 1:40,960	Rituximab	None	Complete resolution
13 [18] (2009)	F/62	Caucasian	Polymyositis	Dyspnea	1 month	Tachypnea, crepitation middle lungs	CT - Widespread marked ground glass opacity with intra and interlobular septal thickening	Large lymphocytes infiltrate sub-bronchial lesion, in situ hybridization for EBER positive	NA detectable copy number 28,420/ml on quantitative PCR	IV acyclovir	None	Complete resolution
14 [19] (2011)	F/28	Korean	None	Fever, flu-like symptoms	21 days	Tachypnea, decrease breath sounds lower lungs, lymphadenopathy hepatosplenomegaly	CT - Diffuse ground glass opacities in both lower lungs, pleural effusion, interlobular septal thickening	Small to large lymphocytes infiltrates in the alveolar septum and peribronchial interstitium, in situ hybridization for EBER positive	-/+,-/+	Supportive	None	Complete resolution
15 [20] (2018)	F/22	Caucasian	Chronic active EBV disease, post splenectomy	Fever, productive cough, weakness	1 month	Tachypnea, wheezing middle and lower lungs, lymphadenopathy hepatomegaly	CT - Disseminated maculate infiltrates both lungs	NA	-/+,-/+	Subcutaneous interferon alpha	None	Partial resolution
16 (our case, 2019)	M/78	Thai	Crohn's disease, CMV colitis	Fever, respiratory failure	14 days	Tachypnea, coarse crepitation lower lungs	CT - Diffuse multifocal irregular consolidation and ground glass opacities scattered in both lungs	Large amount of usual lung parenchymal cells, several foamy materials, without viral inclusion, in situ hybridization for EBER positive	NA, viral load 549,697 copies/mL (log 5.74)	IV acyclovir, supportive	ARDS	Died

VCA, viral capsid antigen; EA-D, early antigen-diffuse component; EBER, Epstein-Barr virus-encoded RNA; LPD, lymphoproliferative disease; AIDS, acquired immune deficiency syndrome; SLE, systemic lupus erythematosus; ARDS, acute respiratory distress syndrome; CT, computed tomography; IV, intravenous; NA, not applicable; F, female; M, male.

5. Conclusions

To date, EBV has rarely been reported as a causative agent or an association of LIP. To our knowledge, we report the first case of EBV-associated LIP in an IBD patient. We postulate that LIP was the consequence from EBV reactivation probably due to immunosuppressive state from immunosuppressive agents and/or IBD itself. The physician should be aware of EBV-associated LIP when taking care of immunosuppressive patients presenting with interstitial pneumonitis.

Financial disclosure

None declared.

Declaration of competing interest

None declared.

References

- [1] W.D. Travis, U. Costabel, D.M. Hansell, et al., An official American Thoracic Society/European Respiratory Society statement: update of the international multidisciplinary classification of the idiopathic interstitial pneumonias, *Am. J. Respir. Crit. Care Med.* 188 (6) (2013) 733–748.
- [2] T.S. Panchabhai, C. Farver, K.B. Highland, Lymphocytic interstitial pneumonia, *Clin. Chest Med.* 37 (3) (2016) 463–474.
- [3] S.I. Cha, M.B. Fessler, C.D. Cool, et al., Lymphoid interstitial pneumonia: clinical features, associations and prognosis, *Eur. Respir. J.* 28 (2) (2006) 364–369.
- [4] J.J. Swigris, G.J. Berry, T.A. Raffin, et al., Lymphoid interstitial pneumonia: a narrative review, *Chest* 122 (6) (2002) 2150–2164.
- [5] J.I. Cohen, Epstein-Barr virus infection, *N. Engl. J. Med.* 343 (7) (2000) 481–492.
- [6] Hem C. Jha, Yonggang Pei, S. Erle, Robertson, Epstein-Barr virus: diseases linked to infection and transformation, *Fro'nt. Microbiol.* 7 (2016) 1602.
- [7] G.Y. Lam, B.P. Halloran, A.C. Peters, et al., Lymphoproliferative disorders in inflammatory bowel disease patients on immunosuppression: lesson from other inflammatory disorders, *World J. Gastrointest. Pathophysiol.* 6 (4) (2015) 181–192.
- [8] C. Bernardes, P. Russo, D. Carvalho, et al., Lymphoproliferative disorders in inflammatory bowel disease patients: is it the drugs or the disease, *GE Port Gastroenterol* 25 (4) (2018) 175–178.
- [9] R. Borie, M. Wislez, M. Antoine, et al., Lymphoproliferative disorders of the lung, *Respiration* 94 (2) (2017) 157–175.
- [10] D. Dierickx, T.M. Habermann, Post-transplantation lymphoproliferative disorders in adults, *N. Engl. J. Med.* 378 (6) (2018) 549–562.
- [11] R.T. Schooley, R.W. Carey, G. Miller, et al., Chronic Epstein-Barr virus infection associated with fever and interstitial pneumonitis. Clinical and serologic features and response to antiviral chemotherapy, *Ann. Intern. Med.* 104 (5) (1986) 636–643.
- [12] M.R. Kramer, M.J. Saldana, M. Ramos, et al., High titers of Epstein-Barr virus antibodies in adult patients with lymphocytic interstitial pneumonitis associated with AIDS, *Respir. Med.* 86 (1) (1992) 49–52.
- [13] J. Collins, N.L. Müller, A.N. Leung, et al., Epstein-Barr-virus-associated lymphoproliferative disease of the lung: CT and histologic findings, *Radiology* 208 (3) (1998) 749–759.
- [14] E. Otsuka, Y. Miyazaki, K. Moriyama, et al., Epstein-Barr virus associated Richter's syndrome accompanied by interstitial pneumonia, [Rinsho Ketsueki] *The Japanese journal of clinical hematology* 40 (5) (1999) 402–407.
- [15] H.K. Yum, E.S. Kim, K.S. Ok, et al., Lymphocytic interstitial pneumonitis associated with Epstein-Barr virus in systemic lupus erythematosus and Sjogren's syndrome. Complete remission with corticosteroid and cyclophosphamide, *Korean J Intern Med* 17 (3) (2002) 198–203.
- [16] K. Marzouk, L. Corate, S. Saleh, et al., Epstein-Barr-virus-induced interstitial lung disease, *Curr. Opin. Pulm. Med.* 11 (5) (2005) 456–460.
- [17] A. Kunitomi, N. Arima, T. Ishikawa, Epstein-Barr virus-associated post-transplant lymphoproliferative disorders presented as interstitial pneumonia; successful recovery with rituximab, *Haematologica* 92 (4) (2007) e49–52.
- [18] T.E. McManus, P.V. Coyle, J. Lawson, et al., Epstein-barr virus pneumonitis, *Ulster Med. J.* 78 (2) (2009) 137–138.
- [19] E.J. Joo, Y.E. Ha, D.S. Jung, et al., An adult case of chronic active Epstein-Barr virus infection with interstitial pneumonitis, *Kor. J. Intern. Med.* 26 (4) (2011) 466–469.
- [20] J. Rolinski, E. Grywalska, A. Pyzik, et al., Interferon alpha as antiviral therapy in chronic active Epstein-Barr virus disease with interstitial pneumonia – case report, *BMC Infect. Dis.* 18 (1) (2018) 190.