



Case Report

Hemiparesis resulting from an unusual C1 fracture: A case report and literature review

Sung-Joo Yuh^{1,2}, Zhi Wang³, Ghassan Boubez³, Daniel Shedid²

¹Department of Neurosurgery, Hopital Maisonneuve-Rosemont, Departments of ²Neurosurgery, ³Orthopedics, Centre Hospitalier de l'Université de Montréal, Montréal, Québec, Canada.

E-mail: *Sung-Joo Yuh - syuh071@gmail.com; Zhi Wang - spinegyu88@hotmail.com; Ghassan Boubez - gboubez@gmail.com; Daniel Shedid - danielshedid@gmail.com



***Corresponding author:**

Sung-Joo Yuh,
Department of Neurosurgery,
Hopital Maisonneuve-
Rosemont, Montréal, Québec,
Canada.

syuh071@gmail.com

Received : 30 July 2020

Accepted : 01 December 2020

Published : 22 December 2020

DOI

10.25259/SNI_479_2020

Quick Response Code:



ABSTRACT

Background: Jefferson fractures are burst fractures involving both the anterior and posterior arches of C1. They typically result from axial compression or hyperextension injuries. Most are stable, and neurological deficits are rare. They are often successfully treated with external immobilization, but require surgery (e.g., fusion/stabilization).

Case Description: An 89-year-old male presented with a left-sided hemiplegia following a trivial fall. The cervical computed tomography scan revealed a left-sided displaced comminuted C1 fracture involving the arch and lateral mass. The MR revealed posterior cord compression and focal myelomalacia. Six months following an emergent C1–C3 decompression with occiput to C4 instrumented fusion, the patient was neurologically intact and pain-free.

Conclusion: An 89-year-old male presented with a left-sided hemiplegia due to a Type 3/4 C1 Jefferson fracture. Following posterior C1–C3 surgical decompression with C0–C4 instrumented fusion, the patient sustained a complete bilateral motor recovery.

Keywords: C1, Central cord syndrome, Cervical fracture, Jefferson fracture

INTRODUCTION

Jefferson fractures are burst fractures involving both the anterior and posterior arches of C1; they account for 2–13% of all cervical fractures.^[6,7] Although they classically result from traumatic axial compression/hyperextension injuries, violent rotation of the head and neck may also rarely contribute to/cause these C1 lesions.

The majority of C1 fractures are stable (e.g., with unruptured transverse ligaments) in neurologically intact patients and can be treated with external immobilization alone.^[2] Alternatively, unstable C1 fractures and those with accompanying neurological deficits may require decompression/fusion surgery (e.g., occiput C0–C2).

Here, we present an 89-year-old male, who following trivial trauma, sustained a left-sided C1 Jefferson fracture, resulting in hemiplegia. This was successfully managed with a C1–C3 surgical decompression and C0–C4 instrumented fusion.

This is an open-access article distributed under the terms of the Creative Commons Attribution-Non Commercial-Share Alike 4.0 License, which allows others to remix, tweak, and build upon the work non-commercially, as long as the author is credited and the new creations are licensed under the identical terms.

©2020 Published by Scientific Scholar on behalf of Surgical Neurology International

CASE REPORT

Following a trivial fall, an 89-year-old right handed male with hypertension, chronic renal failure, and orthostatic hypotension, acutely presented with a flaccid left-sided hemiplegia. He complained of severe neck pain, a limited range of cervical motion, and left lower extremity Lhermitte's signs (e.g., "electric-like/lightning sensations"). On examination, he was hemiplegic in the left upper (0/5) and lower extremity (1/5) (e.g. the right sided weakness was mild (4/5) in these distributions) and had intact sensory and sphincter function. After 1 hour in the emergency room, his left upper extremity paralysis improved to a 1–2/5 strength level.

Radiologic imaging

The cervical CT revealed a displaced comminuted C1 arch fracture on the left that involved the left lateral mass of C1 there was an accompanying diathesis of 10 mm [Figures 1 and 2]. There were also multiple bone fragments in the spinal canal. A single fracture of the posterior arch of C1 was also noted on the right side (e.g., diathesis of 3 mm), accompanied by an additional fracture of the left occipital condyle. The CT angiogram did not reveal a vertebral artery dissection, and/or thrombosis. The MR posterior cord compression at the C1 level; there was also focal myelomalacia and/or a high intrinsic cord signal (T2W study) with severe cord compression at C3/4 [Figures 3 and 4].

Surgery

The patient underwent an emergent C1–C3 laminectomy with occiput (CO)–C4 instrumented fusion. Under fluoroscopy, bilateral C1 lateral mass screws, bilateral C2 pars interarticular screws, and C4 lateral mass screws were applied; no C3 lateral mass screws could be placed due to technical interference from the C2 screw heads. Occipital plates/rods were placed bilaterally from C0–C4 [Figures 5 and 6].

Postoperative course

Immediately postoperatively, the patient regained strength in both his upper and lower extremities (4/5). He was discharged to a rehabilitation facility 14 days later without any residual deficits. Six months postoperatively, his neck pain resolved, and X-rays showed no subsequent instrument-related complications.

DISCUSSION

C1 atlas fractures can be divided into five different types based on the fracture location patterns^[1] [Table 1]. The classical Jefferson fracture, Type III, is a four part fracture, where both

the anterior and the posterior arches are fractured twice. Note, C1 fractures with two or three fracture parts may also occur.

Here, the initial CT scan showed a fracture of the left lateral mass involving the anterior arch, and a single fracture of the right-sided posterior arch. There was also an associated left occipital condyle fracture. This constituted a Type 3/4 C1 fracture [Figure 1].

Table 1: Jefferson classification.

Type 1	Fracture of the posterior arch only
Type 2	Fracture of the anterior arch only
Type 3	Fracture of both the anterior and posterior arches (i.e., a burst or Jefferson's fracture)
Type 4	Fracture of the lateral mass(es) of C1
Type 5	Transverse fracture through anterior arch

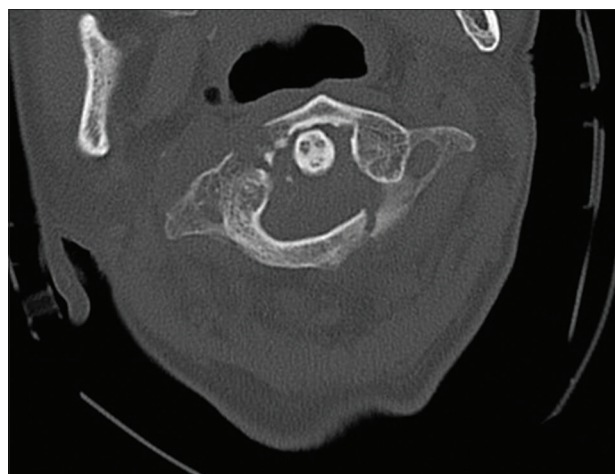


Figure 1: Preoperative cervical axial computed tomography scan demonstrating C1 fracture pattern of the anterior and posterior arches, involving also the right lateral mass.

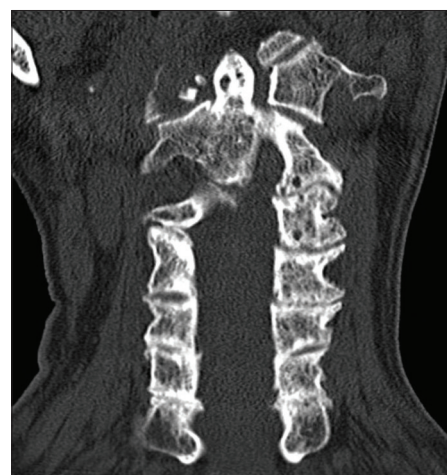

Figure 2: Preoperative coronal computed tomography scan demonstrating the C1 fracture pattern of the lateral mass.

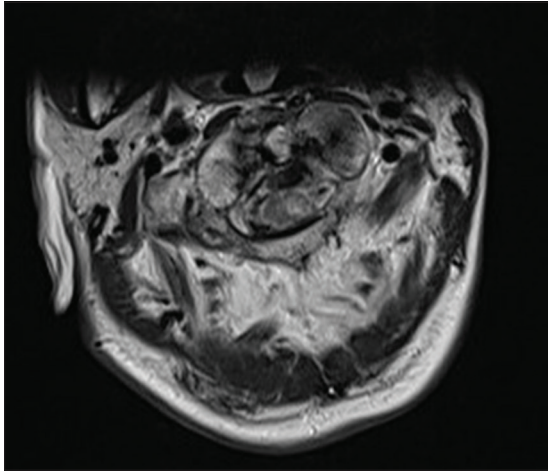


Figure 3: Preoperative cervical axial magnetic resonance imaging demonstrating cord compression from the fracture pattern with myelomalacia.

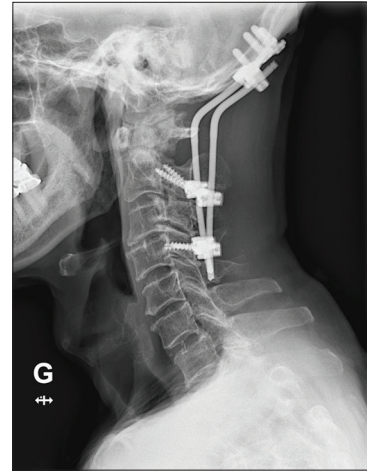


Figure 5: Lateral cervical X-ray done postoperatively at 6 months' time showing intact hardware.

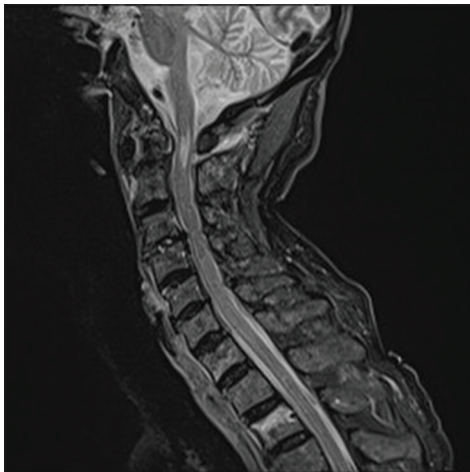


Figure 4: Preoperative sagittal magnetic resonance imaging short-TI inversion recovery sequence demonstrating myelomalacia at C1 and severe stenosis at C3/4 level.

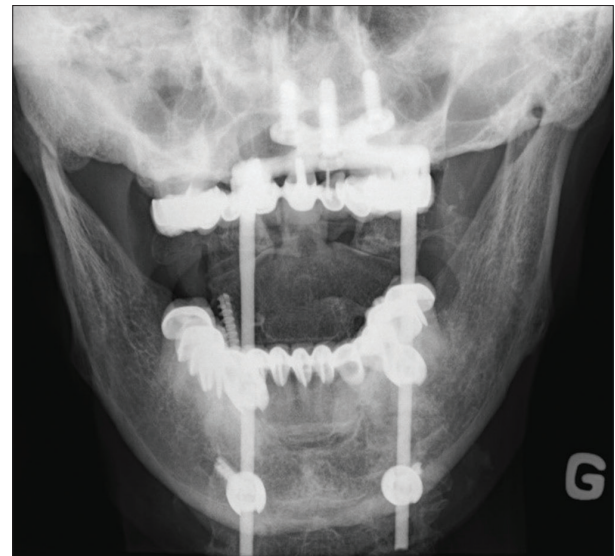


Figure 6: Open mouth view X-ray done postoperatively at 6 months' time showing reduction of C1C2 lateral mass displacement.

Neck pain is the most common presentation for C1 Jefferson fractures, as these fractures typically do not present with neurological deficits; the large diameter of the spinal canal is further widened by the centrifugal displacement of the fragments.^[3] As such, a high degree of suspicion for a C1 fracture must be maintained, especially when a patient presents with a trivial trauma and neck pain.

The integrity of the transverse ligament determines the stability of Jefferson fractures.^[7] Although nonoperative management may be appropriate with slight C1 displacement in the presence of an intact transverse ligament, unstable Jefferson fractures typically warrant surgery. Surgical options include C1–C2 fixation, with occipitocervical fusion reserved for those with the most complex findings. Although there have been reports of direct fixation of C1 only,^[4]

pseudoarthrosis is not a viable option in our opinion. Our case of an unstable Type III fracture involving both anterior, posterior, and lateral mass is cited to have a 33.3% prevalence of nonunion with either operative and nonoperative management.^[5] Furthermore, with ongoing compression both the C1–C2, and C3–C4 levels, the patient warranted a multilevel (C1–C3) posterior cervical decompression with occipitocervical fusion (C0–C4).

CONCLUSION

After a fall, an 89-year-old male presented with a Type 3/4 C1 Jefferson fracture that resulted in an acute left-sided flaccid hemiplegia. Following a C1–C3 laminectomy and C0–C4 fusion, the patient fully recovered.

Declaration of patient consent

Patient's consent not required as patients identity is not disclosed or compromised.

Financial support and sponsorship

Nil.

Conflicts of interest

There are no conflicts of interest.

REFERENCES

1. Bransford R, Falicov A, Nguyen Q, Chapman J. Unilateral C-1 lateral mass sagittal split fracture: An unstable Jefferson fracture variant. *J Neurosurg Spine* 2009;10:466-73.
2. Haus BM, Harris MB. Case report: Nonoperative treatment of an unstable Jefferson fracture using a cervical collar. *Clin Orthop Relat Res* 2008;466:1257-61.
3. Hu Y, Yuan ZS, Kepler CK, Dong WX, Sun XY, Zhang J. Comparison of occipitocervical and atlantoaxial fusion in treatment of unstable Jefferson fractures. *Indian J Orthop* 2017;51:28-35.
4. Kumar A, Onggo J, Fon LH, Oh J. Direct fixation of C1 Jefferson fracture using C1 lateral mass screws: A case report. *Int J Spine Surg* 2019;13:345-9.
5. Lleu M, Charles YP, Blondel B, Barresi L, Nicot B, Challier V, *et al.* C1 fracture: Analysis of consolidation and complications rates in a prospective multicenter series. *Orthop Traumatol Surg Res* 2018;104:1049-54.
6. Marcon RM, Cristante AF, Teixeira WJ, Narasaki DK, Oliveira RP, de Barros Filho TE. Fractures of the cervical spine. *Clinics (Sao Paulo)* 2013;68:1455-61.
7. Ryken TC, Aarabi B, Dhall SS, Gelb DE, Hurlbert RJ, Rozzelle CJ, *et al.* Management of isolated fractures of the atlas in adults. *Neurosurgery* 2013;72 Suppl 2:127-31.

How to cite this article: Yuh SJ, Wang Z, Boubez G, Shedid D. Hemiparesis resulting from an unusual C1 fracture: A case report and literature review. *Surg Neurol Int* 2020;11:449.