

Innovative CAD/CAM Guide for Mandibular Reconstruction with Metallic Condylar Head and Free Fibular Flap

Ryo Yamochi, MD
Toshiaki Numajiri, MD, PhD
Hiroko Nakamura, MD
Daiki Morita, MD
Yoshihiro Sowa, MD, PhD

Summary: In reconstructions of mandibles and condyles, free fibular flaps and metallic condylar heads (CH) are often used after resection. However, in conventional reconstructions, it is difficult to fix the metallic CH on the same preoperative position because the position is determined visually. Therefore, we have made an original computer-aided design and manufacture (CAD/CAM) guide for mandibular condyle reconstruction, combining a metallic CH with a free fibular flap. A 71-year-old woman with gingival carcinoma underwent hemimandibulectomy. We reconstructed the mandible and condyle with a metallic CH and a free fibular flap. We placed a mark on the CAD/CAM guide showing the correct position for fixing the CH to the fibular blocks. We also designed a surface for attaching to the healthy edge of the mandible. The fibular blocks and metallic CH were fixed as 1 unit before separating the flap from the leg and replacing the diseased tissue. Reconstruction was completed by fixing the attachment surface to the healthy side of the mandible. The guide marks solved the difficulty of conventional reconstruction; during surgery, we fixed the metallic CH to the same position as the original bone using these marks. The postoperative deviation of the condyle from the virtual plan was 4.3 mm, whereas the reported deviation of such prostheses was 3.8 mm (range 1.3–6.7); so our guide was acceptably accurate. Furthermore, it appears that the CAD/CAM guide is more useful for reconstruction after hemimandibulectomy including the condyle than after segmental resection without including condyle. (*Plast Reconstr Surg Glob Open* 2020;8:e3088; doi: [10.1097/GOX.0000000000003088](https://doi.org/10.1097/GOX.0000000000003088); Published online 23 September 2020.)

The mandible and its condyle maintain the facial profile and function of the jaw.¹ Moreover, condylar position and ramus length are well known to be associated with articular disorders.² Therefore, replacement of a mandibular condyle (MC) and its head with an alloplastic material, such as metal, is required after resection.³ However, such surgery is rare,⁴ and so surgeons have limited opportunities to gain experience.² In addition, if the position of the condylar replacement is not acceptable, it needs to be repositioned and refixed.³ Furthermore, such replacements have yielded mixed results for correct condylar positioning.⁵ Consequently, conventional replacement of the MC with an alloplastic material remains surgically

challenging.⁵ Mandibular reconstruction using a fibular flap (FF) and a computer-aided design and manufacture (CAD/CAM) guide now facilitates such reconstruction.^{6,7} Therefore, we used CAD/CAM to design a guide for MC reconstruction with a metallic condylar head (CH) and a free FF after hemimandibulectomy including the condyle. Using this guide, fibular blocks and a metallic CH were fixed together, completely mirroring the diseased mandible before detachment of the FF from the leg. We completed the reconstruction by fixing the attachment surface of the guide onto the healthy side of the mandible. Here we report such a case.

CASE PRESENTATION

A 71-year-old woman with carcinoma of the lower gingiva (T4N0) underwent hemimandibulectomy. To maintain the function of the temporomandibular joint, we constructed a free FF with a metallic CH (DePuy Synthes, Tokyo, Japan).

Disclosure: The authors have no financial interest to declare in relation to the content of this article.

Related Digital Media are available in the full-text version of the article on www.PRSGlobalOpen.com.

From the Departments of Plastic and Reconstructive Surgery, Kyoto Prefectural University of Medicine, Kyoto, Japan.

Received for publication April 27, 2020; accepted July 14, 2020.

Copyright © 2020 The Authors. Published by Wolters Kluwer Health, Inc. on behalf of The American Society of Plastic Surgeons. This is an open-access article distributed under the terms of the [Creative Commons Attribution-Non Commercial-No Derivatives License 4.0 \(CCBY-NC-ND\)](https://creativecommons.org/licenses/by-nc-nd/4.0/), where it is permissible to download and share the work provided it is properly cited. The work cannot be changed in any way or used commercially without permission from the journal.

DOI: [10.1097/GOX.0000000000003088](https://doi.org/10.1097/GOX.0000000000003088)

Before surgery, we simulated the reconstruction virtually. First, we determined the osteotomy plane and CAD/CAM construction points. These included the tip of the patient's CH and the angle of the mandible to model the original bone. We then created a virtual CH that matched the size of the metallic CH and placed the virtual metallic CH and FF to pass through each point (Fig. 1) (see figure, Supplemental Digital Content 1, which displays the actual metallic CH and the virtual CH, <http://links.lww.com/PRSGO/B459>) (see Video [online], which displays the virtual planning).

After the simulation, we designed and constructed 3 guides for mandible cutting, fibula cutting, and fixation using a 3-dimensional printer. Using the mandible and fibula cutting guides, we could simulate cutting them using virtual planning. Similarly, using the fixation guide, we could place the metallic CH and each fibular block virtually. This guide fits the outer surface of the fibula used; so we could reproduce the same angles at junctions as in the virtual planning. In addition, this guide showed the true attachment position of the metallic CH. The guide has a surface designed for attachment to the healthy side of the mandible (Fig. 1). During surgery, using these guides, the reconstruction was nearly completed in the leg in situ. Thus, we finished cutting and fixing the FF and attaching the metallic CH along with the CAD/CAM guide before separating the complete FF from the leg. The condylar and mandibular positions were reproduced by attaching the designed surface of the guide to the healthy side of the mandible. We then reinforced it with a thin titanium

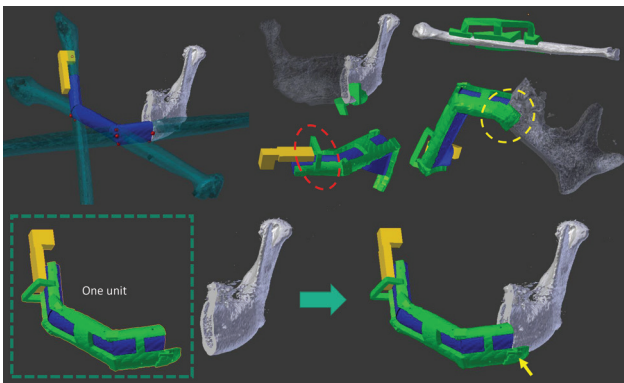


Fig. 1. Image of virtual planning. We created a yellow structure matching the size of the metallic CH. Using the green cutting guides, we used virtual planning to simulate cutting the mandible and fibula. The fixation guide was designed to fit the outer surface of the source fibula, reproducing the same angles at junctions as in the virtual plan. Using this guide, the fibular blocks and metallic CH were fixed as 1 unit, completely replacing the diseased side of the patient's mandible before detachment of the fibular flap (FF) from the leg. The red dashed circle indicates the position of attachment of the metallic CH on the FF. The surface indicated by the yellow dashed circle was designed to fit the surface of the healthy side of the mandible. After detachment of the FF, fixation was completed simply by attaching the attachment surface to the healthy side of the mandible. The fibular blocks and metallic CH were fixed as 1 unit, completely modeling the diseased side of the patient's mandible before detachment of the FF. We completed the reconstruction by fixing the attachment surface of the guide onto the healthy side of the mandible.

plate. Finally, we removed the guide and anastomosed the feeding vessels (Fig. 2).

To prevent ankylosis, we preserved the articular disc during tumor resection. In addition, to prevent dislocation, we wrapped the metallic CH and the fossa with the surrounding soft tissue after the CH was positioned on the articular disc within the temporal fossa.

Six months after the operation, the patient had correct occlusion stability. The mouth opening range was 32 mm postoperatively. The patient does not complain of static or dynamic pain (Fig. 3).

DISCUSSION

In mandibular reconstruction using an FF after segmental mandibular resection, a guide constructed using CAD/CAM enabled more accurate reconstruction.⁷ Such prostheses had an average postoperative deviation of the condyle from the preoperative position of 3.8 mm (range 1.3–6.7).⁸ However, for reconstructions not including the condyle using a CAD/CAM guide, the postoperative deviations from the virtual plan were 2.4 mm⁹ and 2.7 mm.¹⁰ Thus, it seems that the deviations between postoperative data and the virtual plan in the reconstruction of the mandible including its condyle are larger than those for reconstructions not including the condyle. To evaluate the accuracy of our CAD/CAM guide, we compared postoperative computed tomography data with the virtual plan data by superimposing the 2 images. The postoperative deviation of the MC was 4.2 mm and the deviation of the ramus length was 1.1 mm (Fig. 4). Compared with previous reports, our results are acceptable even though we used an existing metallic CH.

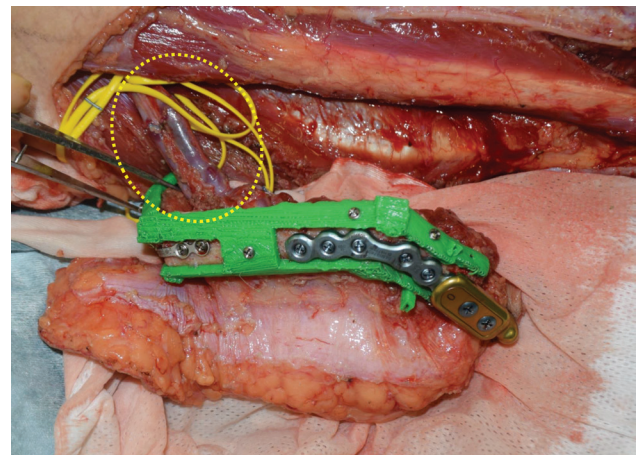


Fig. 2. We cut the mandible and fibula along the cutting guide. We placed fibular fragments along the fixation guide. The artificial head was also fixed as a guide. Before separating the FF, we finished fixing it and attached the metallic CH. The fibular blocks and the metallic CH were fixed as one unit before detachment of the flap, completely modeling the diseased side of the patient's mandible. After separating the FF, the fixation guide was attached to the healthy side of the mandible. Finally, we removed the guide and reinforced the reconstruction using a thin titanium plate.

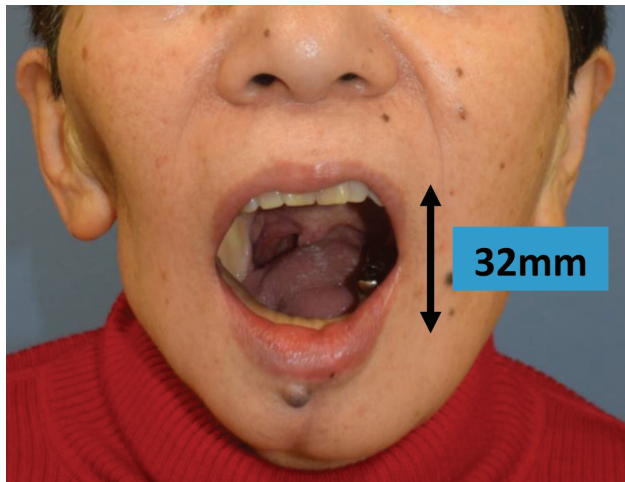


Fig. 3. Image of the patient six months after the operation. The patient had correct occlusion stability using dentures. The patient did not complain of limitations in opening her mouth. The mouth opening range was 33 mm (preoperatively) and 32 mm (postoperatively).

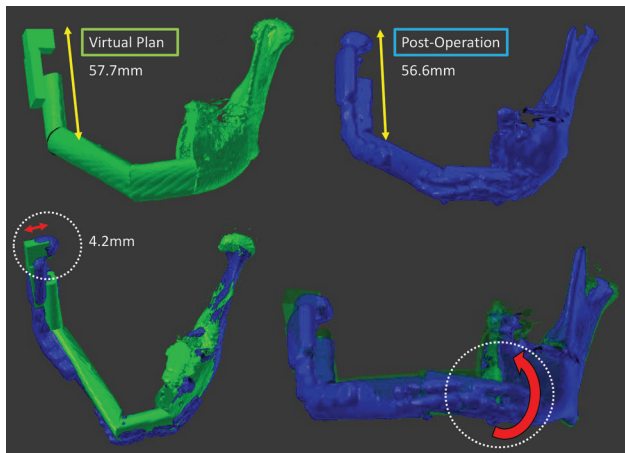


Fig. 4. The green image shows the mandible in virtual planning, and the blue image is the desired postoperative configuration. The ramus lengths were 57.7 mm and 56.6 mm, respectively. The postoperative deviation of the ramus from the virtual plan was 1.1 mm, and the postoperative deviation of the condyle was 4.2 mm. By superimposing postoperative computed tomographic image data and virtual plan data, the FF had rotated counterclockwise (red arrow) at its junction with the healthy mandible.

It appears that the CAD/CAM guide is more useful for reconstruction after hemimandibulectomy including the condyle than after segmental resection without including condyle. The advantage of using a CAD/CAM guide for the latter operation has been reported.^{7,9} In such mandibular reconstructions, even if surgeons do not use the CAD/CAM guide, they can image the reproduction position easily by intermaxillary fixation because both ends of the mandible are retained. However, when reconstructing the mandible after hemimandibulectomy including the condyle, it is more difficult to image the final position even when setting intermaxillary fixation because there are few landmarks, and there is only the healthy side of the mandible remaining. Using our CAD/CAM guide,

by attaching the attachment surface of the guide onto the remaining healthy mandible, the condylar position is reproduced correctly. Therefore, the use of this CAD/CAM guide facilitated the reconstruction. However, the attachment surface of the guide left a 4.2 mm gap in condylar positioning. By superimposing postoperative computed tomography and virtual plan images, the FF was found to have rotated counterclockwise between it and the remaining mandible (Fig. 4). We designed the attachment surface, in this case, to be of the same size as if both ends of the mandible could be retained. In addition, after hemimandibulectomy, the reconstructed condyle was pulled toward the healthy side because the surrounding muscles were resected. Thus, it appears that the rotation at the junction was caused by the small attachment surface of our CAD/CAM guide, and so we should have designed a larger surface to prevent this rotation.

Ryo Yamochi, MD

Department of Plastic and Reconstructive Surgery
Kyoto Prefectural University of Medicine
Kawaramachi-Hirokoji Kajii-cho 465
Kamigyo-ku
Kyoto 602-8566, Japan
E-mail: yamochi@koto.kpu-m.ac.jp

PATIENT CONSENT

The patient provided written consent for the use of her image.

REFERENCES

- Chim H, Salgado CJ, Mardini S, et al. Reconstruction of mandibular defects. *Semin Plast Surg.* 2010;24:188–197.
- Ciocca L, Tarsitano A, Marchetti C, et al. A CAD–CAM-prototyped temporomandibular condyle connected to a bony plate to support a free fibular flap in patients undergoing mandibulectomy: A pilot study with 5 years of follow up. *J Craniomaxillofac Surg.* 2015;43:1785–1791.
- Marx RE, Gillo JE Jr, Broumand V, et al. Outcome analysis of mandibular condylar replacements in tumor and trauma reconstruction: a prospective analysis of 131 cases with long-term follow-up. *J Oral Maxillofac Surg.* 2008;66:2515–2523.
- Carlson ER. Disarticulation resections of the mandible: a prospective review of 16 cases. *J Oral Maxillofac Surg.* 2002;60:176–181.
- Patel A, Maisel R. Condylar prostheses in head and neck cancer reconstruction. *Arch Otolaryngol Head Neck Surg.* 2001;127:842–846.
- Roser SM, Ramachandra S, Blair H, et al. The accuracy of virtual surgical planning in free fibula mandibular reconstruction: comparison of planned and final results. *J Oral Maxillofac Surg.* 2010;68:2824–2832.
- Ritschl LM, Mücke T, Fichter A, et al. Functional outcome of CAD/CAM-assisted versus conventional microvascular, fibular free flap reconstruction of the mandible: a retrospective study of 30 cases. *J Reconstr Microsurg.* 2017;33:281–291.
- Tarsitano A, Battaglia S, Ramieri V, et al. Short-term outcomes of mandibular reconstruction in oncological patients using a CAD/CAM prosthesis including a condyle supporting a fibular free flap. *J Craniomaxillofac Surg.* 2017;45:330–337.
- Hanasono MM, Skoracki RJ. Computer-assisted design and rapid prototype modeling in microvascular mandible reconstruction. *Laryngoscope.* 2013;123:597–604.
- Foley BD, Thayer WP, Honeybrook A, et al. Mandibular reconstruction using computer-aided design and computer-aided manufacturing: an analysis of surgical results. *J Oral Maxillofac Surg.* 2013;71:e111–e119.