

RESEARCH ARTICLE

Vestibular syncope: clinical characteristics and mechanismHanim Kwon¹ , Eunjin Kwon² , Hyo-Jung Kim³ , Jeong-Yoon Choi^{4,5}  & Ji-Soo Kim^{4,5} ¹Department of Neurology, Korea University Ansan Hospital, Ansan, South Korea²Department of Neurology, Chungnam National University Hospital, Daejeon, South Korea³Research Administration Team, Seoul National University Bundang Hospital, Seongnam, South Korea⁴Dizziness Center, Clinical Neuroscience Center, and Department of Neurology, Seoul National University Bundang Hospital, Seongnam, South Korea⁵Department of Neurology, Seoul National University College of Medicine, Seoul, South Korea**Correspondence**

Jeong-Yoon Choi, Department of Neurology, Seoul National University Bundang Hospital, 173-82 Gumi-ro, Bundang-gu, Seongnam-si, Gyeonggi-do 13620, South Korea. E-mail: saideiju@gmail.com

Received: 3 June 2022; Revised: 14 August 2022; Accepted: 16 August 2022

Annals of Clinical and Translational Neurology 2022; 9(10): 1616–1625

doi: 10.1002/acn3.51661

Abstract

Background and Objectives: Vestibular syncope is a condition in which vertigo-induced hemodynamic changes cause syncope. This study investigated the clinical and laboratory findings of vestibular syncope and tried to refine our knowledge of the mechanism underlying this newly recognized entity. **Methods:** This study retrospectively analyzed 53 patients (33 women, median age = 63 years [interquartile range = 54–71 years]) with vestibular syncope from January 2017 to December 2021. To explain the mechanism of vestibular syncope, we incorporated a velocity-storage model into the dual reflex pathways comprising the vestibulo-sympathetic reflex and baroreflex and predicted the cardiovascular responses. **Results:** Twenty (37.7%) patients had multiple episodes of vestibular syncope, and seven (13.2%) had potentially life-threatening injuries. Meniere's disease (20.8%) and benign paroxysmal positional vertigo (9.4%) were the most common underlying vestibular disorders. Abnormal vestibular function tests included impaired cervical vestibular-evoked myogenic potentials (57.5%) and positive head impulse tests (31.0%). Orthostatic hypotension was found in 19.5% of patients. Dyslipidemia (30.2%) and hypertension (28.3%) were common medical comorbidities. The dual reflex pathways incorporating the function of the velocity-storage circuit in the brainstem and cerebellum suggest that vestibular syncope is a neurally mediated reflex syncope associated with a sudden hemodynamic change during vertigo. This change can be arterial hypertension triggered by a false downward inertial cue, as suggested previously, or hypotension driven by a false upward inertial cue. **Conclusions:** Vestibular syncope is associated with various vestibular disorders and requires careful evaluation and intervention to prevent recurrent falls and significant injuries.

Introduction

The vestibular system, together with the baroreflex pathway, plays a substantial role in maintaining cardiovascular homeostasis during motion.^{1,2} Neurons in the caudal part of the vestibular nuclear complex, including the inferior and medial vestibular nuclei, regulate sympathetic activity through various connections with brainstem autonomic nuclei.^{1–3} Given the stimulus characteristics (head motion) and short-latency action of 100 to 200 msec, this vestibular-driven reflex regulates autonomic activity in a

feed-forward manner.^{1–3} In contrast, the baroreflex system operates with a feedback mechanism that controls the autonomic activity.^{1–3}

Recent research has introduced the concept of vestibular syncope, which refers to syncope as a result of a vertigo spell. It mostly occurs during Meniere's attacks and is ascribed to erroneous otolithic information during the spell, which may affect the cardiovascular system.^{3,4} In our prior study, we considered vestibular syncope to be a form of neurally mediated syncope and explained the mechanism as an excessive increase in blood pressure

attributed to dyssynergia of the vestibulo-sympathetic reflex and baroreflex system, owing to non-physiologic vestibular stimulation (vertigo attack).⁵ Accordingly, vestibular syncope may occur in association with other vestibular disorders, but its clinical features and relationships with underlying disorders remain to be elucidated.

In the present study, we investigated the clinical characteristics of vestibular syncope in terms of patients' demographic findings, underlying vestibular disorders, and the status of audio-vestibular function. In addition, we refined the mechanism of vestibular syncope by adding vertigo-induced hemodynamic changes other than ictal hypertension.

Methods

Standard protocol approvals, registrations, and patient consent

This is a case-series study based on a single hospital's medical records. The Institutional Review Board of Seoul National University Bundang Hospital approved the study and waived the requirement of consent for each individual (IRB number: B-2205-755-111).

Study population and evaluation

We analyzed 53 patients treated from January 2017 to December 2021 who had reported one or more episodes of syncope with a close temporal relationship with paroxysmal vertigo attack and suffered from episodic or persistent dizziness and imbalance before and after syncope. We did not include patients with known cardiac dysfunction reducing the cardiac output, seizures, or other degenerative neurological disorders involving the autonomic system, such as multiple system atrophy or spinocerebellar ataxia.

We adopted a multi-layered diagnostic method to assess underlying vestibular disorders. The primary diagnosis was defined as the vestibular disorder that triggered syncope, and the secondary diagnoses were vestibular disorders associated with the primary disorder or related to persistent dizziness before and after syncope attack. The diagnoses of definite Meniere's disease, vestibular paroxysmia, benign paroxysmal positional vertigo, vestibular migraine, and persistent perceptual postural dizziness were made according to the international classification of vestibular disorders.^{6–10} However, cases of Meniere's disease, vestibular paroxysmia, and vestibular migraine that did not fulfill the definite criteria were classified as single paroxysmal vertigo or recurrent episodic vertigo from undetermined etiology.

For patients who were willing to undergo an evaluation for dizziness, the laboratory audio-vestibular function tests

were evaluated selectively using three-dimensional (3D) video-oculography, video head impulse tests (video-HITs), cervical and ocular vestibular evoked myogenic potentials (VEMPs), active orthostatic blood pressure, the tilt table test, and pure tone audiometry. The protocols of 3D video-oculography, video-HITs, and cervical and ocular VEMPs have been presented elsewhere.^{11–14} For the active orthostatic blood pressure test, we measured the baseline pressure and heart rate in the supine position after a 3-min rest and at 1, 3, and 5 min after standing up.¹⁵ Abnormalities in the active blood pressure test and tilt table test were defined as a drop in systolic and diastolic pressure of at least 20 and 10 mmHg, respectively, and a heart rate increase of more than 30 beats per minute.¹⁵

Mechanism based on the velocity-storage model

To explain the vertigo-induced cardiovascular alterations that eventually cause syncope, we integrated the velocity-storage circuit into the dual reflex pathways (the baroreflex and vestibulo-sympathetic reflex) controlling cardiovascular homeostasis.⁵ We then predicted the cardiovascular responses associated with syncope by implementing an inertial cue generated in the velocity-storage circuit during vertigo attacks. The mechanism of vestibular syncope is described in the Discussion section, and the details of our model for velocity-storage circuit and dual neural reflex mechanisms for cardiovascular homeostasis have been reported in a previous study.⁵

Results

Features of vestibular syncope: learning from a case

A 72-year-old man with hypertension and dyslipidemia had constant dizziness and recurrent syncope. He reported dizziness that had lasted for 10 years, initially characterized by an intermittent floating sensation lasting about 1 to 2 weeks per year but lasting all day long in recent months. In addition, he reported an intense spinning sensation lasting for 1–2 h at intervals of about 3 months, frequently resulting in rightward falls. Along with dizziness, he had gradual left-side hearing loss and tinnitus. The first instance of syncope occurred 9 months ago, which was associated with spinning vertigo while getting out of bed, resulting in a right clavicular fracture. Four months later, he lost consciousness while walking on a crosswalk, just after a sensation of falling for 2–3 sec. Within a few seconds, he immediately regained consciousness, but lost consciousness again shortly after walking out of the crosswalk. After syncope, the floating

and swaying sensation became stronger and continued all day.

On a neurological examination, there was neither spontaneous nor gaze-evoked nystagmus. Head-shaking and positional maneuvers did not evoke abnormal eye movement, and bedside horizontal head impulse tests were normal. During the Romberg test, his body swayed to the right. Limb coordination in both arms and legs was normal. He had undergone repetitive Holter electrocardiography monitoring and transthoracic echocardiography, as well as electroencephalography and brain magnetic resonance imaging with cervicocranial artery angiography. However, no causative condition provoking persistent dizziness and syncope was identified. The orthostatic blood pressure test showed a marginal systolic pressure drop, from 123 to 103 mmHg, but he did not report any symptoms. In video-HITs, the gain decreased to 0.57 and 0.58 in the left and right posterior canals. The gains in other canals were normal, but there were asynchronous small amplitude corrective saccades in the horizontal canal video-HITs. Bithermal caloric testing showed left side canal paresis of 77%. Cervical VEMPs were normal, while ocular VEMPs were absent bilaterally. Pure tone audiometry showed severe (65 dB) left-side sensorineural hearing loss. The results of audio-vestibular function tests are presented in Figure 1. With a diagnosis of Meniere's disease with vertigo-related syncope, he continued to receive 12.5 mg of hydrochlorothiazide and 48 mg of betahistine per day. He had no further syncope, recurrent vertigo spells, or falls during 2 years of follow-up.

Baseline characteristics

The findings of the 53 enrolled patients are summarized in Table 1. The median age was 63 years (interquartile range = 54–71 years), and 33 (62.3%) were women. Medical comorbidities other than vestibular disorders were found in about half of the patients ($n = 27$, 50.9%); the most common comorbidity was dyslipidemia (30.2%), followed in descending order by hypertension (28.3%) and diabetes (13.2%). Medications that could possibly affect the cardiovascular system were administered in 28 patients (52.8%), in the following order: beta-blockers (26.4%), calcium-channel blockers (20.7%), diuretics (16.9%), angiotensin II receptor antagonists (9.4%), and alpha-blockers (5.6%). Twenty-seven (50.9%) and 23 (42.5%) patients underwent transthoracic echocardiography and 24-h Holter electrocardiography monitoring, respectively, but none of them had significant cardiac disorders causing syncope such as mitral or aortic valve stenosis, heart failure, sick sinus syndrome, and atrioventricular tachyarrhythmia or conduction block.

Thirty-three (62.3%) patients had a single syncopal attack, while the remaining 20 (37.7%) had multiple syncopal attacks. All patients had syncope within tens of seconds after a vertigo attack. As a result of syncope, seven (13.2%) patients had significant injuries, including three with intracranial hemorrhage and one each of drowning-induced aspiration pneumonia, femur neck fracture, clavicular fracture, and acromion fracture.

The primary diagnosis-triggered syncope was Meniere's disease in 11 (20.8%) patients, benign paroxysmal positional vertigo in five (9.4%), and vestibular paroxysmia, vestibular schwannoma, labyrinthine concussion, and inflammatory multiple cranial neuropathies in one each. Of the remaining patients, 23 (43.4%) were symptomatically diagnosed with recurrent episodic vertigo from an undetermined etiology and 10 (18.9%) with single spontaneous vertigo from an undetermined etiology. As the secondary diagnoses associated with the primary disorder, 30 (56.6%) patients met the criteria for persistent postural perceptual dizziness (PPPD). Two had Meniere's disease, and one each had benign paroxysmal positional vertigo and labyrinthine concussion.

Vestibular function and orthostatic blood pressure tests

Of 42 patients who underwent video-HITs, four (9.5%) had abnormal gain with large corrective saccades. Nine (21.4%) had gains above the reference value (>0.8), but there were covert corrective saccades during video-HITs, suggesting the compensation of canal function from previous pathologies.^{16,17} In 40 patients with cervical VEMPs, 23 (57.5%) had abnormal findings: 15 with unilateral abnormalities and eight with bilateral abnormalities. Four (11.4%) of 35 patients had abnormal ocular VEMPs, of which three were unilateral and one was bilateral. Overall, 87.8% patients had at least one abnormality on vestibular function testing, and cervical VEMPs were the most frequent abnormality. Of the 41 patients who underwent orthostatic blood pressure testing, only eight (19.5%) showed a significant pressure drop or heart rate increase. The baseline and orthostatic blood pressures and pulse rates are shown in Figure 2.

Discussion

In this study, we summarized the clinical features of vestibular syncope. The main observation was that patients with vestibular syncope had various vestibular disorders. Many patients had abnormal vestibular function but not enough to account for specific vestibular disorders. The orthostatic blood pressure test was abnormal in some patients but was generally insensitive in revealing

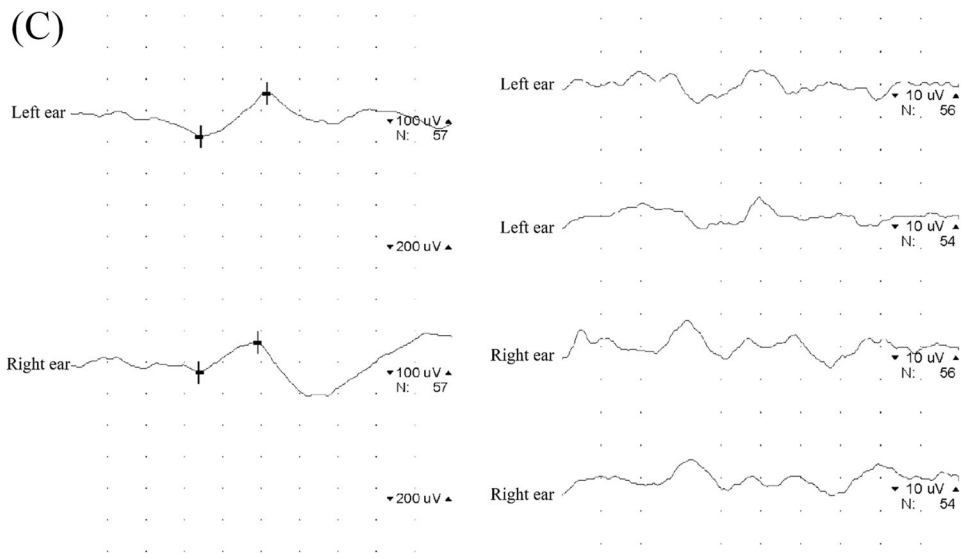
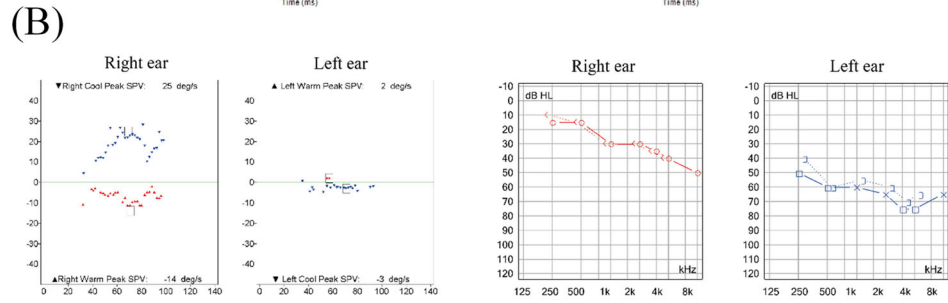
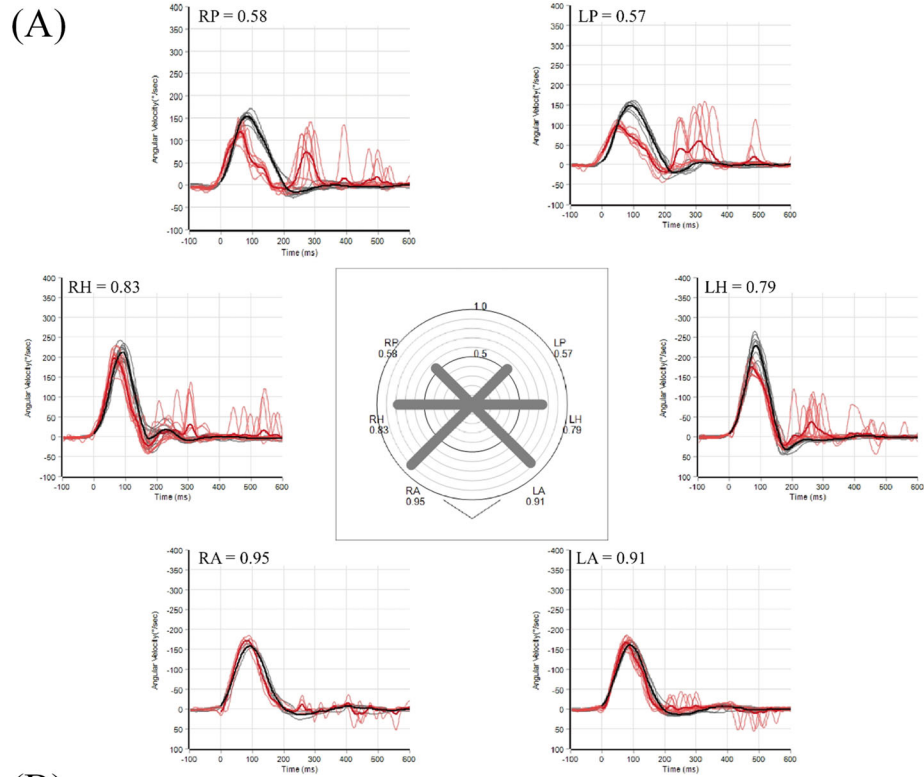


Figure 1. Clinical findings of the illustrated case. (A) In video-head impulse tests, the gain (the ratio of total eye rotation in degrees to total head rotation in degrees) is 0.57 and 0.58 in the left and right posterior canals, respectively. In addition, there are asynchronous small amplitude corrective saccades during the horizontal and posterior canal head impulse tests. (B) Bithermal caloric test and pure tone audiometry show left side canal paresis of 77% and severe left-side sensorineural hearing loss. (C) Cervical vestibular evoked myogenic potentials are normal, but ocular vestibular evoked myogenic potentials are absent.

Table 1. Baseline characteristics and results of vestibular function tests in enrolled patients.

Baseline characteristics (n = 53)	
Age	63 (54–71)
Female	33 (62.3)
Diabetes	7 (13.2)
Hypertension	15 (28.3)
Dyslipidemia	16 (30.2)
Coronary heart disease	5 (9.4)
Stroke	6 (11.3)
Primary vestibular disorders (n = 53)	
Meniere's disease	11 (20.8)
Benign paroxysmal positional vertigo	5 (9.4)
Vestibular paroxysmia	1 (1.9)
Vestibular schwannoma	1 (1.9)
Labyrinthine concussion	1 (1.9)
Inflammatory multiple cranial neuropathy	1 (1.9)
Undetermined	33 (62.3)
Vestibular function tests	
Abnormal video-HITs	13/42 (31.0)
Decreased gain with corrective saccades	4/42 (9.5)
Normal gain with corrective saccades	9/42 (21.5)
Abnormal cervical VEMPs	23/40 (57.5)
Unilateral abnormality	15/40 (37.5)
Bilateral abnormality	8/40 (20.0)
Abnormal ocular VEMPs	4/35 (11.4)
Unilateral abnormality	3/35 (8.6)
Bilateral abnormality	1/35 (2.8)
Overall abnormalities ¹	43/49 (87.8%)
Orthostatic blood pressure test (n = 41)	
Abnormal pressure drops	8 (19.5)
Postural orthostatic tachycardia syndrome	0 (0.0)
Overall abnormalities	8 (19.5)

Values are median (with interquartile range) or number (with percentage, %).

HIT, head impulse test; VEMP, vestibular-evoked myogenic potential.

¹Of 53 patients, four had not undergone vestibular function test so the denominator is 49. Six were normal in all tested evaluations; therefore, the numerator is 43.

significant hemodynamic changes. In addition, a non-negligible number of patients had significant syncope-related injuries.

Previously, Meniere's attacks were suggested to provoke vestibular syncope by generating erroneous otolithic information.^{3,4} However, in a recent study, we detailed a theory proposing a mechanism wherein false downward inertia estimated in the central vestibular system disturbs the interaction of neural reflexes participating in

cardiovascular homeostasis; this phenomenon is referred to as dyssynergia between the vestibulo-sympathetic reflex and baroreflex.⁵ Moreover, the false downward inertia in the central vestibular system was shown to arise from false canal cues as well as false otolith cues.⁵ Through this mechanism, vestibular syncope can develop during an attack of any vestibular disorder. Indeed, our study showed a broad spectrum of vestibular disorders, ranging from Meniere's disease to benign paroxysmal positional vertigo and other disorders involving the vestibular system. Furthermore, more than half of the patients (62.3%) had single or multiple episodic vertigo attacks not satisfying the criteria for specific vestibular disorders. Therefore, along with our previous proposal, our study suggests that vestibular syncope should not be treated as an extraordinary event confined to Meniere's disease; instead, it could be the main clinical presentation in diverse vestibular disorders causing dysfunction of the canal, otolith, or both.

Interestingly, the proportion of patients with undetermined etiology was non-negligible, possibly due to limitations in evaluation at the interictal or postictal stage and the study design only accepting a definite diagnosis. However, as revealed in patients with a definite diagnosis, patients with undetermined etiology were likely to have benign paroxysmal positional vertigo or early stage of Meniere's disease. Indeed, it has been known that otolith dysfunction is frequently impaired in both disorders.^{18,19} The high frequency of abnormal VEMPs results in our study could support this idea further. Though we observed vestibular syncope in diverse vestibular disorders, these findings may imply that the risk of syncope during vertigo attack is not homogenous across vestibular disorders but higher in vestibular disorders involving the otolith.

In our observations, approximately 13% of patients had serious complications related to vestibular syncope, including intracranial hemorrhage, limb fracture, and drowning. These complications can seriously impair quality of life and may even be life-threatening. Syncope occurred multiple times in about 40% of patients, and the risk of being injured is obviously increased among those who experience multiple episodes of syncope. In addition, unlike the neurally mediated (reflex) syncope from other provoking conditions,^{20,21} 30 of 53 patients had a diagnosis of persistent postural perceptual dizziness (PPPD). Though PPPD is a secondary condition

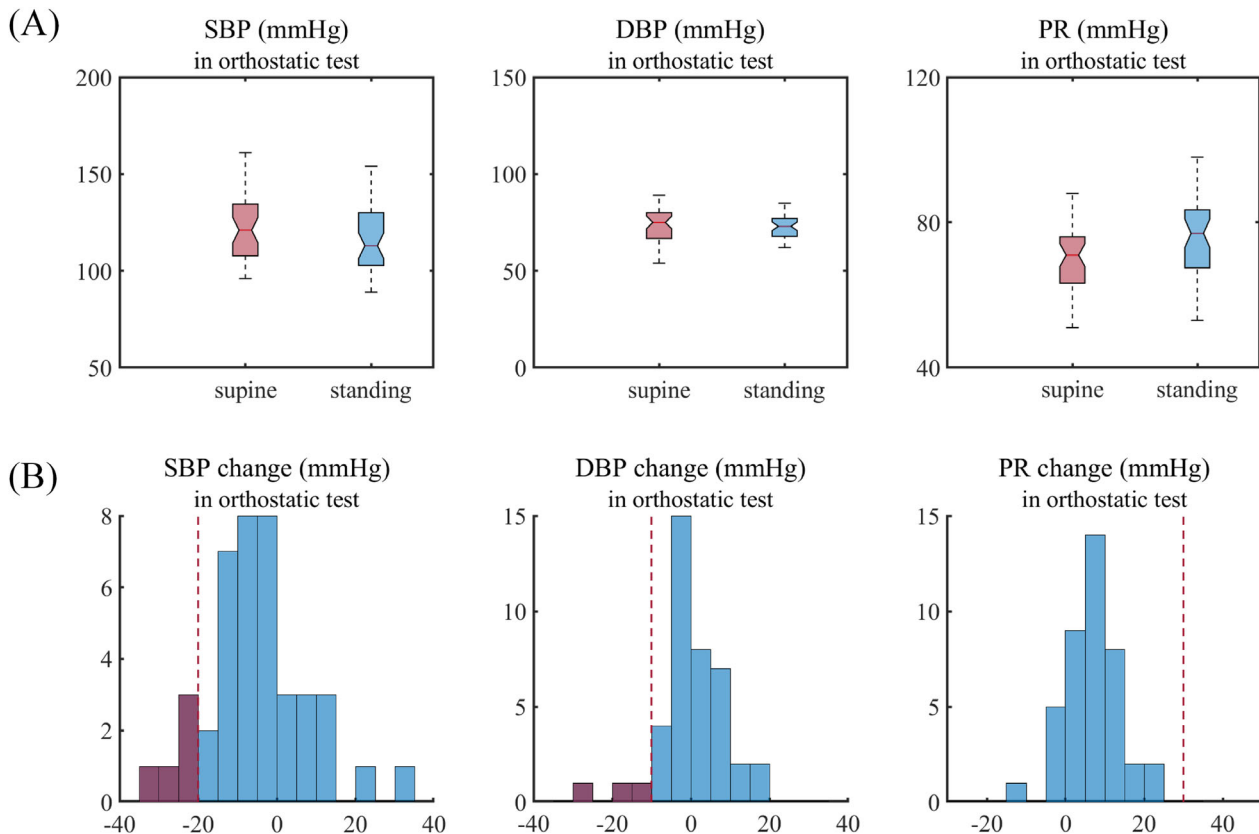


Figure 2. Orthostatic blood pressure tests in patients with vestibular syncope. (A) Box plots (upper row) show the systolic and diastolic blood pressures and pulse rate in the supine position and the lowest systolic and diastolic blood pressures and highest pulse rate during a 5-min orthostatic test. (B) Bar plots (lower row) show the distribution of changes in systolic and diastolic pressures and pulse rate during a 5-min orthostatic test. The vertical red dot lines in each plot indicate the boundary of reference values, and the purple-filled boxes represent the number of patients with abnormal values. DBP, diastolic blood pressure; PR, pulse rate; SBP, systolic blood pressure.

associated with primary vestibular disorders that caused syncope, this finding suggests that more than half of the patients continued to suffer from persistent dizziness after the syncope. These observations emphasize the need to identify, evaluate, and manage patients with syncope related to vestibular disorders, which may reduce paroxysmal vertigo attacks, control persistent dizziness, and prevent further syncope and related injuries.

The question then arises of how we can diagnose vestibular syncope in clinical practice? In our study, the results of vestibular function testing showed that 87.8% of patients had one or more abnormalities. In accordance with the mechanism we proposed,⁵ otolith function sensing linear acceleration upon the head was impaired in more than half of the patients. Additionally, about one-third of patients had impaired canal function. However, these abnormalities are not able to characterize patients with vestibular syncope because they are frequently present in patients with vestibular disorders who do not have syncopal attacks. The orthostatic blood pressure tests

seemed not to be sensitive for the diagnosis of vestibular syncope, although there were a small number of patients with significant hemodynamic changes. However paradoxically, these findings may reflect the characteristics of vestibular syncope that occur related to paroxysmal vertigo attack. In most paroxysmal neurologic disorders, the attacks arise unpredictably, and the evaluation in the interictal or resting stage has limited diagnostic sensitivity, thereby warranting repetitive multimodal testing.^{22,23} Hence, as with other paroxysmal disorders, we suggest that the diagnosis of vestibular syncope depends on a detailed interview about syncope attacks and associated vestibular symptoms. It is also essential to understand the mechanism of vestibular syncope. To this end, we briefly introduce here the mechanism of vestibular syncope, which was refined to explain the hemodynamic changes during vertigo attacks, including not only ictal hypertension but also hypotension linked to syncope.

As inferred from its name, the vestibulo-sympathetic reflex senses gravitation and head motion in space and

then mainly modulates sympathetic activity to counteract the changes in fluid distribution within the body.^{1,2} When the head moves upward (e.g., standing), the fluid is momentarily shifted to the lower body and extremities, leading to a decrease in cardiac preload and blood pressure. In this circumstance, vestibular signals associated with head motion increase the sympathetic outflow. When the head moves downward (e.g., sitting), the fluid is now momentarily pumped toward the upper body, increasing the preload and blood pressure. Vestibular signals decrease sympathetic tone, thereby enabling the resumption of a normotensive state.^{1,2} This vestibulo-sympathetic reflex is fast but imprecise, as it is an antecedent autonomic response implemented through a feed-forward open-loop system.^{24,25} Therefore, even in normal conditions, the complementary role of the baroreflex is essential (Fig. 3A).^{24,25} However, the vestibular signal during vertigo (i.e., the false motion cue) does not reflect the actual head motion and fluid change within the body, and the outcome of the vestibulo-sympathetic reflex would be inappropriate.⁵ For instance, with the development of false downward inertia, increased sympathetic activity would cause hypertension. When excessive, the ensuing baroreflex causes parasympathetic hyperactivity, which in turn can cause significant hypotension and syncope. Along with arterial hypertension, as we suggested previously, sudden hypotension may occur. When false upward inertia develops, the sympathetic activity decreases, which in turn leads to hypotension and syncope in conditions without a prompt reduction of the baroreflex tone.⁵ Based on this neural mechanism, several predisposing factors such as neurologic, cardiac, or renal disorders, antihypertensive medications, and nutritional conditions determine the vulnerability to syncope during vertigo attacks in patients with vestibular disorders (Fig. 3A). Vertigo-induced nausea and vomiting, another consequence of the vestibular-autonomous interaction, may also promote syncope by increasing parasympathetic outflow, either by itself or through activation of the baroreflex.

Last, the role of the central vestibular system should be noted. The cerebellar nodulus/uvula forms a neural circuit with the bilateral vestibular nuclei, named the velocity-storage circuit,^{26–28} which is engaged in refining the rotational cue from an inaccurate canal signal and sorting the gravito-inertial acceleration relayed from the otolith into constant gravitational and transient inertial accelerations.^{29,30} To ensure the proper vestibulo-sympathetic reflex, an accurate estimation of gravitational and inertial accelerations is essential, which depends on the functional fidelity of the velocity-storage circuit as well as the peripheral vestibular system. The involvement of the velocity-storage circuit is supported by the velocity-storage model,

in which a false downward inertia cue can arise when a false rotational cue not aligning to the gravity axis develops (Fig. 3B). This situation easily occurs in patients with benign paroxysmal positional vertigo,³¹ rotational Meniere's attack,³² or inferior vestibular neuritis.³³ Hence, along with the previous report, our observations of five patients with vestibular syncope during benign paroxysmal positional vertigo attacks may solidify the role of the velocity-storage circuit in generating the vestibulo-sympathetic reflex. In addition, the mechanism we suggest here would be partly able to explain orthostatic hypotension or hypertension in patients with neurological disorders involving the cerebellum and brainstem, such as multisystem atrophy and parkinsonism,^{34–37} in which inappropriate inertia estimation by the velocity-storage circuit would cause incongruity of the dual reflex mechanism.

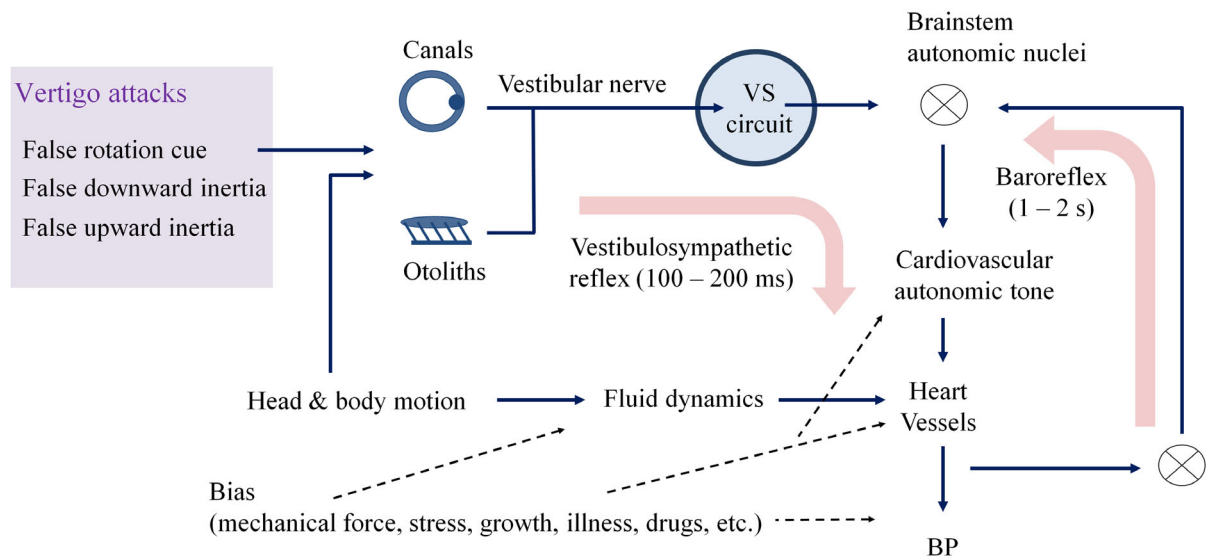
This study has several limitations. First, a retrospective study from a single institution is inherently subject to selection bias. Second, the prevalence of vestibular syncope was unavailable in this study, although previous studies have reported a prevalence of 4% in patients with Meniere's disease.³ In addition, it is difficult to completely exclude other possible causes of syncope since the evaluations were not homogeneous and were incomplete for some patients. Third, this study had limitations in revealing orthostatic hypotension, especially within the initial 30 sec, because beat-to-beat pressure monitoring was not adopted during the orthostatic blood pressure test. Therefore, the relationship between vestibular syncope and initial orthostatic hypotension should be elucidated in further studies. Nevertheless, a strength is that this is the first study to investigate vestibular syncope in various vestibular conditions with objective data from vestibular function tests.

In conclusion, we found that vestibular syncope can develop in patients with various vestibular disorders. Syncope in the setting of vertigo attacks requires careful evaluation as managing underlying vestibular disorders can alleviate vertigo and dizziness and may prevent further syncope. Given its paroxysmal nature and the absence of standard diagnostic tests, the diagnosis of vestibular syncope is primarily based on an interview about the context in which the syncope occurred. In addition, it would be helpful to understand the role of the velocity-storage circuit and vestibulo-sympathetic reflex in maintaining cardiovascular homeostasis. A study with a larger number of patients and a more detailed design would be required to assess vestibular syncope.

Conflict of Interest

Dr. J. Y. Choi serves as an associate editor of *Journal of Clinical Neurology*. Dr. J. S. Kim serves as an associate

(A) Schematic of the dual neural reflex with the VS model for cardiovascular homeostasis



(B) Output of the VS model during a vertigo attack and expected cardiovascular response

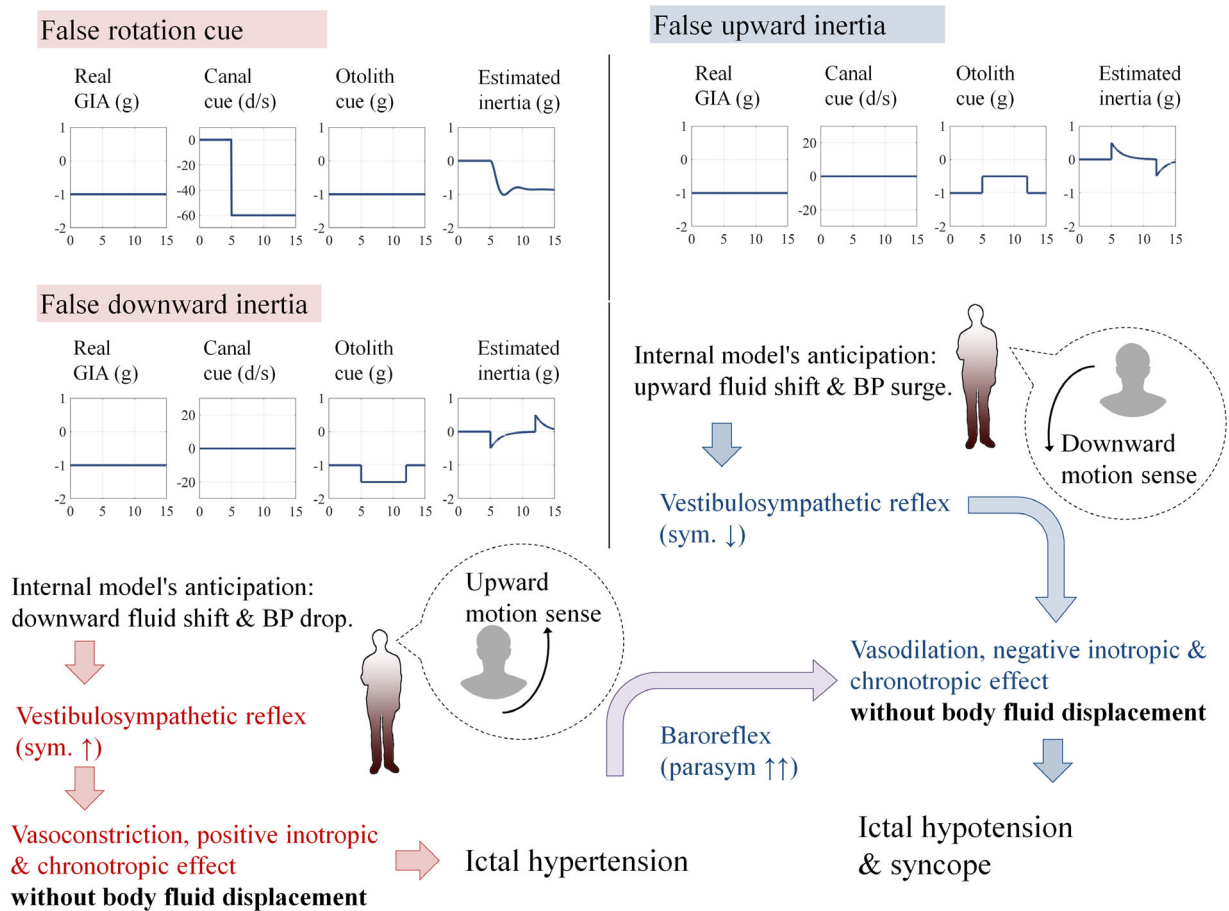


Figure 3. Schematic mechanism of vestibular syncope. (A) Dual neural reflex pathways for cardiovascular homeostasis. The vestibulo-sympathetic reflex has a short (100–200 msec) latency and operates in a feed-forward manner. The information on the head position from the canal and otolith is further refined in the velocity storage (VS) circuit and then relayed to the brainstem autonomic nuclei controlling cardiovascular tone. Of note, vertigo attacks (purple box) can change the vestibulo-sympathetic reflex tone without postural changes. In contrast, the baroreflex, activated by blood pressure changes in the heart and major vessels, has relatively a long latency (1–2 sec) and uses a feedback strategy. (B) The VS model shows that both false rotational cues and false downward inertia can generate a downward inertial cue (left column). In this situation, the vestibulo-sympathetic reflex increases the sympathetic outflow to counteract the preload and blood pressure drop during upward motion. However, since vertigo attacks provoke downward inertia without actual body fluid displacement, increased sympathetic activity may cause sudden ictal hypertension. As a result, baroreflex increases parasympathetic flow, which in turn causes hypotension and eventually syncope in some cases. On the contrary, when the VS circuit generates an upward inertial cue (right column), the vestibulo-sympathetic reflex decreases sympathetic outflow to compensate for the body fluid changes associated with actual motion. However, since the body fluid remains unchanged during vertigo, ictal hypotension (a well-known cause of reflex syncope) may follow.

editor of *Frontiers in Neurootology* and on the editorial boards of *Frontiers in Neuroophthalmology*, *Journal of Neuroophthalmology*, *Journal of Vestibular Research*, *Journal of Neurology*, and *Medicine*. The other authors have nothing to disclose.

Author Contributions

H. Kwon analyzed and interpreted the data and wrote the manuscript. E. Kwon and H. J. Kim acquired data and revised the manuscript. J. Y. Choi designed and conceptualized the study, interpreted the data, and revised the manuscript. J. S. Kim interpreted the data and revised the manuscript.

Funding Information

This research was supported by a grant from the Basic Science Research Program through the National Research Foundation of Korea (NRF) funded by the Ministry of Science and ICT (2020R1A2C4002281).

References

1. Yates BJ, Bolton PS, Macefield VG. Vestibulo-sympathetic responses. *Compr Physiol*. 2014;4(2):851.
2. Bogle JM, Benarroch E, Sandroni P. Vestibular-autonomic interactions: beyond orthostatic dizziness. *Curr Opin Neurol*. 2022;35(1):126-134.
3. Pyykkö I, Manchaiah V, Zou J, Levo H, Kentala E. Vestibular syncope: a disorder associated with drop attack in Ménière's disease. *Auris Nasus Larynx*. 2018;45(2):234-241.
4. Pyykkö I, Manchaiah V, Zou J, Levo H, Kentala E. Do patients with Meniere's disease have attacks of syncope? *J Neurol*. 2017;264(1):48-54.
5. Kwon E, Lee JY, Kim H-J, Choi J-Y, Kim J-S. Can dyssynergia of Vestibulosympathetic and baroreflexes cause vestibular syncope? The hypothesis based on the velocity-storage function. *Cerebellum*. 2022;21(2):244-252.
6. Lopez-Escamez JA, Carey J, Chung W-H, et al. Diagnostic criteria for Menière's disease. *J Vestib Res*. 2015;25(1):1-7.
7. Strupp M, Lopez-Escamez JA, Kim J-S, et al. Vestibular paroxysmia: diagnostic criteria. *J Vestib Res*. 2016;26(5-6):409-415.
8. Von Brevern M, Bertholon P, Brandt T, et al. Vértigo posicional paroxístico benigno: criterios diagnósticos. Documento de consenso del Comité para la Clasificación de los Trastornos Vestibulares de la Bárány Society. *Acta Otorrinolaringol Esp*. 2017;68(6):349-360.
9. Lempert T, Olesen J, Furman J, et al. Vestibular migraine: diagnostic criteria. *J Vestib Res*. 2012;22(4):167-172.
10. Staab JP, Eckhardt-Henn A, Horii A, et al. Diagnostic criteria for persistent postural-perceptual dizziness (PPPD): consensus document of the committee for the classification of vestibular disorders of the Bárány society. *J Vestib Res*. 2017;27(4):191-208.
11. Choi J-Y, Kim JH, Kim HJ, Glasauer S, Kim J-S. Central paroxysmal positional nystagmus: characteristics and possible mechanisms. *Neurology*. 2015;84(22):2238-2246.
12. Kim H-J, Lee JH, Kim J-S. Ocular vestibular evoked myogenic potentials to head tap and cervical vestibular evoked myogenic potentials to air-conducted sounds in isolated internuclear ophthalmoplegia. *Clin Neurophysiol*. 2014;125(5):1042-1047.
13. Kim H-J, Park S-H, Kim J-S, et al. Bilaterally abnormal head impulse tests indicate a large cerebellopontine angle tumor. *J Clin Neurol*. 2016;12(1):65-74.
14. Jung I, Ahn S-H, Lee J, et al. Age-related deterioration of saccule-related neural function is associated with decreased estimated glomerular filtration rate and increased free thyroxine. *Clin Neurophysiol*. 2019;130(5):795-801.
15. Brignole M, Moya A, de Lange FJ, et al. 2018 ESC guidelines for the diagnosis and management of syncope. *Kardiologia Polska*. 2018;76(8):1119-1198.
16. Lee J-Y, Kwon E, Kim H-J, et al. Dissociated results between caloric and video head impulse tests in dizziness: prevalence, pattern, lesion location, and etiology. *J Clin Neurol*. 2020;16(2):277.
17. Yang CJ, Cha EH, Park JW, et al. Diagnostic value of gains and corrective saccades in video head impulse test in

- vestibular neuritis. *Otolaryngol Head Neck Surg.* 2018;159(2):347–53.
18. Chen G, Yu G, Li Y, Zhao X, Dai X, Wang G. Cervical vestibular evoked myogenic potentials in benign paroxysmal positional vertigo: a systematic review and meta-analysis. *Front Neurol.* 2019;10:1043.
 19. Lee SU, Kim HJ, Choi JY, Koo JW, Kim JS. Abnormal cervical vestibular-evoked myogenic potentials predict evolution of isolated recurrent vertigo into Meniere's disease. *Front Neurol.* 2017;8:463.
 20. Wieling W, Thijs RD, Van Dijk N, Wilde AA, Benditt DG, Van Dijk JG. Symptoms and signs of syncope: a review of the link between physiology and clinical clues. *Brain.* 2009;132(10):2630–2642.
 21. Saklani P, Krahn A, Klein G. Syncope. *Circulation.* 2013;127(12):1330–1339.
 22. Smith SJ. EEG in the diagnosis, classification, and management of patients with epilepsy. *J Neurol Neurosurg Psychiatry.* 2005;76(suppl 2):ii2–ii7.
 23. Stafstrom CE, Carmant L. Seizures and epilepsy: an overview for neuroscientists. *Cold Spring Harb Perspect Med.* 2015;5(6):a022426.
 24. Morita H, Abe C, Tanaka K. Long-term exposure to microgravity impairs vestibulo-cardiovascular reflex. *Sci Rep.* 2016;6(1):1–10.
 25. Gotoh TM, Fujiki N, Matsuda T, Gao S, Morita H. Roles of baroreflex and vestibulosympathetic reflex in controlling arterial blood pressure during gravitational stress in conscious rats. *Am J Physiol-Regul Integr Comp Physiol.* 2004;286(1):R25–R30.
 26. Katz E, de Jong J, Buettner-Ennever J, Cohen B. Effects of midline medullary lesions on velocity storage and the vestibulo-ocular reflex. *Exp Brain Res.* 1991;87(3):505–520.
 27. Wearne S, Raphan T, Cohen B. Contribution of vestibular commissural pathways to spatial orientation of the angular vestibuloocular reflex. *J Neurophysiol.* 1997;78(2):1193–1197.
 28. Wearne S, Raphan T, Cohen B. Control of spatial orientation of the angular vestibuloocular reflex by the nodulus and uvula. *J Neurophysiol.* 1998;79(5):2690–2715.
 29. Laurens J, Angelaki DE. The functional significance of velocity storage and its dependence on gravity. *Exp Brain Res.* 2011;210(3):407–422.
 30. Angelaki DE, Cullen KE. Vestibular system: the many facets of a multimodal sense. *Annu Rev Neurosci.* 2008;31:125–150.
 31. Choi J-Y, Park Y-M, Lee SH, et al. Linear vertigo in benign paroxysmal positional vertigo: prevalence and mechanism. *Cerebellum.* 2021;20(2):160–168.
 32. Lee S-U, Kim H-J, Choi J-Y, Kim J-S. Ictal downbeat nystagmus in Ménière disease: a cross-sectional study. *Neurology.* 2020;95(17):e2409–e2417.
 33. Kim J-S, Kim HJ. Inferior vestibular neuritis. *J Neurol.* 2012;259(8):1553–1560.
 34. Lee H, Kim H-A. Reversible orthostatic hypotension in PICA territory cerebellar infarction. *J Neurol Sci.* 2014;341(1–2):187–188.
 35. Ruchoux M-M, Gray F, Gherardi R, Schaeffer A, Comoy J, Poirier J. Orthostatic hypotension from a cerebellar gangliocytoma (Lhermitte-Duclos disease): case report. *J Neurosurg.* 1986;65(2):245–248.
 36. Senard J-M, Brefel-Courbon C, Rascol O, Montastruc J-L. Orthostatic hypotension in patients with Parkinson's disease. *Drugs Aging.* 2001;18(7):495–505.
 37. Wenning GK, Colosimo C, Geser F, Poewe W. Multiple system atrophy. *Lancet Neurol.* 2004;3(2):93–103.