

# Open Bristow Versus Open Latarjet for Anterior Shoulder Instability in Rugby Players

## Radiological and Clinical Outcomes

Makoto Tanaka,<sup>\*†</sup> MD, PhD, Hiroto Hanai,<sup>‡</sup> MD, Yuki Kotani,<sup>‡</sup> MD, Kosuke Kuratani,<sup>§</sup> MD, Hidekazu Nakai,<sup>||</sup> MD, Shuma Kinoshita,<sup>||</sup> MD, Takehito Hirose,<sup>‡</sup> MD, and Kenji Hayashida,<sup>||</sup> MD, PhD

*Investigation performed at Daini Osaka Police Hospital, Osaka, Japan*

**Background:** Coracoid transfer is a reliable method for managing anterior shoulder instability in athletes who play contact sports; however, differences between the Bristow and Latarjet procedures are unclear.

**Purpose:** To compare clinical outcomes and rates of bone union and bone resorption of the coracoid process between the open Bristow and open Latarjet procedures in rugby players.

**Study Design:** Cohort study; Level of evidence, 3.

**Methods:** Rugby players who underwent an open Bristow or an open Latarjet procedure were retrospectively reviewed for anterior shoulder instability, and 66 shoulders in the Bristow group and 35 in the Latarjet group were included. Graft union and resorption were evaluated using computed tomography at 3 months to 1 year postoperatively. Patient-reported outcome measures (American Shoulder and Elbow Surgeons score, Rowe score, and satisfaction rate) were obtained at a mean follow-up of 74 months (range, 45-160 months) for Bristow and 64 months (range, 50-76 months) for Latarjet procedures. Recurrence and the rate of return to play (RTP), frequency of pain after RTP, and retirement rate after RTP were also assessed.

**Results:** In 97.1% of the Latarjet procedure cases, bone union of the coracoid was achieved at 3 months postoperatively; however, bone union was achieved in only 72.7% of the Bristow procedure cases at 6 months postoperatively. Bone resorption of the coracoid process occurred in 6.1% of shoulders after the Bristow procedure, whereas 100% of shoulders showed bone resorption after the Latarjet procedure. No statistical differences were found in outcome scores between the 2 procedures. Subluxation and persistent pain after returning to sports were identified at a significantly higher rate in the Latarjet group (5 shoulders [14%] and 9 shoulders [26%], respectively) than in the Bristow group (2 shoulders [3%] and 2 shoulders [3%]) ( $P = .0471$  and  $P = .001$ , respectively).

**Conclusion:** The Latarjet procedure had an advantage in the early and high rate of bone union but was at a disadvantage in bone resorption compared with the Bristow procedure. Subluxation and pain after returning to sports were more frequent in patients who underwent the open Latarjet procedure than in those who underwent the open Bristow procedure.

**Keywords:** shoulder; instability; Bristow; Latarjet; bone resorption; clinical outcomes; rugby

Many surgeons prefer to use coracoid transfer to treat contact sports athletes who have anterior shoulder instability because arthroscopic Bankart repair has been reported to have a high postoperative recurrence rate,<sup>21,22,27</sup> given that large bone defects are common in these athletes. Participation in contact sports,<sup>21</sup> especially rugby, and younger age<sup>20</sup> are considered risk factors for recurrence. Nakagawa et al<sup>23</sup>

reported that the recurrence rate after arthroscopic Bankart repair in contact sports athletes was higher in rugby players (33.3%) than in American football players (17.2%) and players of other contact sports (11.1%). Torrance et al<sup>33</sup> reported that rugby players aged <16 years had a 2.2 times higher risk of recurrence (with a recurrence rate of 93%) than athletes aged >16 years.

At our institute, the Bristow-Latarjet procedure is the first-line treatment for anterior shoulder instability in young rugby players. There are mainly 2 procedures for coracoid transfer: the modified Bristow procedure and the

The Orthopaedic Journal of Sports Medicine, 10(5), 23259671221095094

DOI: 10.1177/23259671221095094

© The Author(s) 2022

This open-access article is published and distributed under the Creative Commons Attribution - NonCommercial - No Derivatives License (<https://creativecommons.org/licenses/by-nc-nd/4.0/>), which permits the noncommercial use, distribution, and reproduction of the article in any medium, provided the original author and source are credited. You may not alter, transform, or build upon this article without the permission of the Author(s). For article reuse guidelines, please visit SAGE's website at <http://www.sagepub.com/journals-permissions>.

Latarjet procedure.<sup>6</sup> In the Bristow procedure, the coracoid process is placed in a standing position, and the cut surface comes into contact with the glenoid, where it is fixed using a single screw. In the Latarjet procedure, where the osteotomy is performed more toward the base of the coracoid, the coracoid process is placed in a lying position and fixed using 2 screws. The concept of both procedures is almost the same, producing a sling effect of the conjoint tendon and bony augmentation in front of the glenoid by the coracoid.<sup>11,24,34</sup>

Both procedures have been reported to have a low reinjury rate and a high rate of return to sports at the preinjury level.<sup>3,14,15,18,25,26,35</sup> However, a biomechanical study<sup>12</sup> revealed that the Latarjet procedure was superior to the Bristow procedure in its ability to restore joint stability. In contrast, a systematic review concluded that the recurrence of dislocation had a statistically significant difference favorable to the Bristow procedure.<sup>8</sup> The Bristow and Latarjet procedures are slightly different, but no reports have directly compared the 2 procedures in clinical settings. Therefore, the advantages and disadvantages of each procedure have not been clarified.

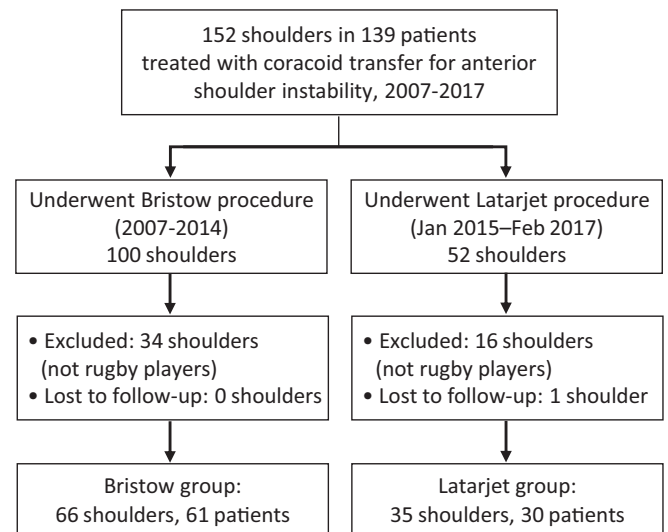
In this study, we aimed to compare the bone union and bone resorption of the transferred coracoid process and to address the clinical outcomes that occur after the Bristow and Latarjet procedures in rugby players. We hypothesized that the Latarjet procedure would have a higher bone union rate and better clinical outcomes because of biomechanical superiority.

## METHODS

This retrospective, single-center, comparative study consisted of a continuous series of patients. The study protocol was approved by an institutional review board. Patients were not required to give informed consent because we applied an opt-out method to use clinical and radiological data anonymously, which was agreed upon at the patient's initial visit.

### Patient Selection

All patients who underwent coracoid transfer for the treatment of anterior shoulder instability between 2007 and 2017 were retrospectively reviewed. Of those, patients involved in rugby were included in this study. Between 2007 and 2014, we performed the Bristow procedure, but in January 2015, we changed to the Latarjet procedure.



**Figure 1.** Flowchart of patient selection.

Between 2007 and 2017, a total of 152 shoulders in 139 patients (100 shoulders with Bristow procedure and 52 shoulders with Latarjet procedure) underwent the coracoid transfer procedure for the treatment of anterior shoulder instability. Of those, 50 shoulders (34 shoulders in the Bristow group and 16 shoulders in the Latarjet group) in patients involved in sports activity other than rugby were excluded. One shoulder in the Latarjet group was lost to follow-up (the patient moved 6 weeks after surgery). Consequently, this study included 66 shoulders in 61 patients treated with the Bristow procedure and 35 shoulders in 30 patients treated with the Latarjet procedure (Figure 1). Our first choice for treating anterior shoulder instability for rugby players is the coracoid transfer, regardless of glenoid bone loss. All patients included in the study were competitive rugby players who wanted to return to play (RTP).

### Surgical Procedures

The surgical approach for both procedures was identical, following the approach described by Bouju et al.<sup>4</sup> A 4- to 8-cm vertical skin incision from the coracoid tip was made, the length depending on the patient's physique. The standard deltopectoral approach was used to expose the coracoid process by disinserting the coracoacromial ligament and pectoralis minor tendon. The coracoid process was

\*Address correspondence to Makoto Tanaka MD, PhD, Center for Sports Medicine, Daini Osaka Police Hospital, 2-4-60 Karasugatsuji, Tennouji-ku, Osaka, 543-8922, Japan (e-mail: makoto.tanaka@mac.com).

<sup>†</sup>Center for Sports Medicine, Daini Osaka Police Hospital, Osaka, Japan.

<sup>‡</sup>Department of Orthopaedic Surgery, Osaka University Graduate School of Medicine, Suita, Japan.

<sup>§</sup>Department of Orthopaedic Surgery, Japan Community Healthcare Organization Osaka Hospital, Osaka, Japan.

<sup>||</sup>Department of Orthopaedic Surgery, Daini Osaka Police Hospital, Osaka, Japan.

Final revision submitted February 5, 2022; accepted February 23, 2022.

The authors have declared that there are no conflicts of interest in the authorship and publication of this contribution. AOSSM checks author disclosures against the Open Payments Database (OPD). AOSSM has not conducted an independent investigation on the OPD and disclaims any liability or responsibility relating thereto.

Ethical approval for this study was obtained from Daini Osaka Police Hospital (ref No. 1041).

sectioned using an L-shaped bone saw (Zimmer) that was 12 to 18 mm long in the Bristow procedure and 18 to 25 mm long in the Latarjet procedure. The lower one-third of the subscapularis muscle was separated up to the junction, and then the entire capsular planes were released from the deep side of the subscapularis. Horizontal capsulotomy was extended to the edge of the glenoid labrum, and then the capsule was dissected off of the glenoid rim, creating an inferior capsular flap. The anterior part of the glenoid neck was exposed and refreshed using an osteotome.

In the Bristow procedure, a guide pin was inserted from the center of the cutting plane to the tip of the coracoid process and then drilled using a 3.0-mm drill, and the length of the coracoid tip was measured using a depth gauge. A screw hole was drilled at the 4-o'clock position of the glenoid neck and 5 to 8 mm medial from the joint surface. The coracoid was fixed to the glenoid neck using a 4.0-mm cannulated cancellous screw (Meira) with a washer.

In the Latarjet procedure, the bone cortex of the inferior part of the coracoid was removed using a bone saw, and the cancellous bone was exposed. A screw hole was made in the upper part of the coracoid. A screw hole was drilled between the 3- and 4-o'clock positions of the glenoid neck and at 5 to 8 mm medial from the joint surface. The coracoid bone block was positioned using a 4.0-mm superior screw so that it lay flush across the glenoid face. An inferior screw hole was drilled parallel to the guide pin inserted into the superior screw. A 3.5-mm cannulated cancellous screw was then inserted into the inferior screw hole and secured.

After the coracoid was fixed in both the procedures, the capsule was repaired using anatomic Bankart repair with 3 single-loaded anchors with a mattress suture while appropriately retensioning the inferior capsular flap from south to north.

### Postoperative Protocols

The shoulder was immobilized postoperatively for 4 weeks in internal rotation using a Shoulder Brace IR (ALCARE). Passive forward elevation in the supine position was started 2 weeks after surgery. Active forward elevation and external rotation were started 6 weeks after surgery, and usual daily activities were allowed thereafter. Strengthening exercises were started 3 months after surgery, followed by rugby practice 4 months after surgery. Full RTP in rugby was allowed depending on a patient's condition.

### Data Collection

Preoperatively, a detailed history was obtained for all patients, who were then assessed using the American Shoulder and Elbow Surgeons (ASES) shoulder score<sup>28</sup> and the Rowe score.<sup>30</sup> The usual postsurgical follow-up was conducted until RTP after surgery, and annual follow-up was recommended but depended on a patient's consent. We asked eligible patients to answer a questionnaire to evaluate the latest conditions of the affected shoulders. The

questionnaire was accessible via an online survey tool, which was facilitated by team staff or by telephone (English version available as supplemental material).

The survey was conducted between April and May 2021 and was answered by all patients. The questionnaire included questions regarding the history of recurrences, concerns regarding RTP, and current sports activity. In terms of recurrences, *dislocation* was defined as shoulder dislocation that required manual reduction, and *subluxation* was defined as the subjective feeling of shoulder subluxation that relocated spontaneously.<sup>10</sup> The questionnaire also included the functional measurements of the ASES score, the Rowe score, and satisfaction rates. To assess the degree of pain and satisfaction using the online survey tool, we adopted linear scales instead of a numeric rating scale. In addition, postoperative pain requiring intraglenohumeral injections was determined from medical records. The indications for intraglenohumeral injections were pain continuing for >7 days and pain resulting in difficulty in playing rugby.

RTP in rugby, the postoperative period before RTP, and the continuity of the rugby activity were assessed. In terms of the postoperative period, preceding operations were excluded in patients who underwent surgeries for both of their shoulders.

### CT Examination

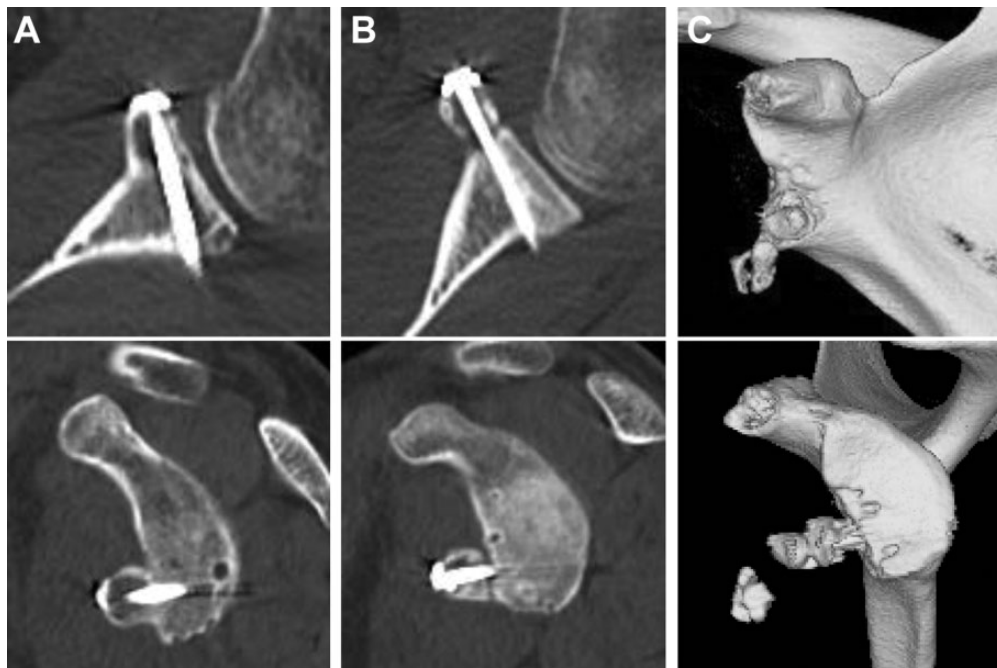
Computed tomography (CT) was performed using an Aquilion scanner (Canon Medical Systems) at a slice thickness of 0.50 mm. During the usual postsurgical follow-up period, all patients underwent CT on the day after surgery to evaluate the contact and position of the transferred coracoid process. CT examination was performed at 3 months, 6 months, and  $\geq 1$  year postoperatively to evaluate coracoid bone union and resorption, depending on patient consent.

Bone union and resorption of the coracoid process were examined on sagittal and axial views of CT images with multiplanar reconstruction. We defined *bone union* as continuity of the trabecular bone between the coracoid process and glenoid, *insufficient union* when the coracoid process did not move but there was a radiolucent zone between the coracoid process and glenoid, and *translocation* when the coracoid process was fractured and translocated from the screw or when screw back-out was recognized (Figure 2).

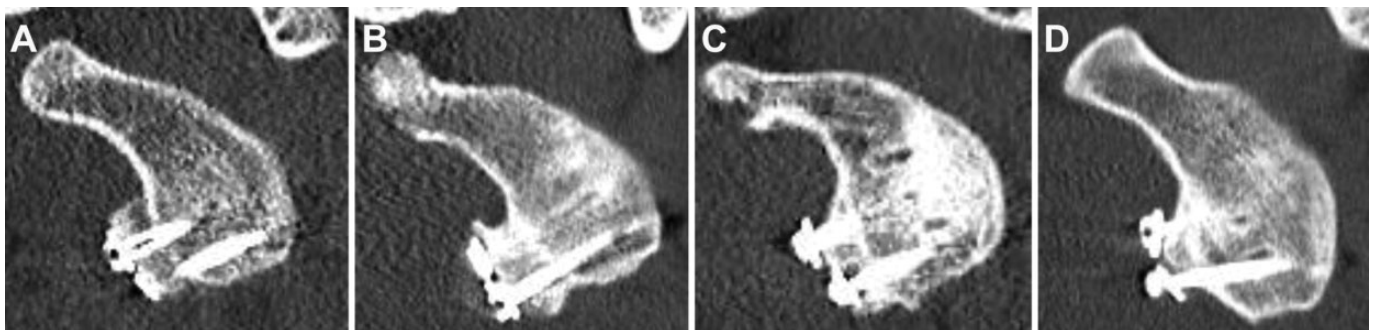
Bone resorption was evaluated by comparing postoperative coracoid process morphology with baseline morphology on the day after surgery using CT images. The conditions of bone resorption were classified into 4 groups: none (no bone resorption) (Figure 3A), mild (slight bone resorption, but it did not reach the screw head) (Figure 3B), moderate (bone resorption reached the screw head) (Figure 3C), and severe (severe bone resorption with exposure of the screw shaft and loosening of the washer) (Figure 3D). Bone resorption was evaluated for both the superior and inferior screws in the Latarjet group.

### Statistical Analysis

The Fisher exact test was used to analyze differences in preoperative sports activities, bone union rate, recurrences,



**Figure 2.** Definitions of postoperative bone integrity of the coracoid on computed tomography (CT) images with multiplanar reconstruction. Top row: axial view, bottom row: sagittal view. (A) Bone union: Continuity of the trabecular bone between the coracoid process and glenoid. (B) Insufficient union: The coracoid process did not move, but a radiolucent zone was seen between the coracoid process and the glenoid. (C) Translocation: The coracoid process was fractured and translocated from the screw, or screw back-out was recognized (3-dimensional CT).



**Figure 3.** Classification of postoperative bone resorption of the coracoid on computed tomography images with multiplanar reconstruction. (A) None: No bone resorption. (B) Mild: Slight bone resorption, but it did not reach the screw head. (C) Moderate: Bone resorption reached the screw head. (D) Severe: Severe bone resorption with exposure of the screw shaft and loosening of the washer.

reoperation, severe pain that required injections, concerns after RTP, levels of RTP, and the current rugby activity between groups. The *t* test was used to analyze differences in age between groups. The Mann-Whitney *U* test was used to determine the differences in clinical follow-up, duration before RTP, and continued period of play before retirement between groups and satisfaction rates in each group. The Wilcoxon signed rank test was used to analyze preoperative and postoperative differences in the ASES and Rowe scores for each group. All statistical analyses were performed using JMP pro software (Version 14.0.0, SAS

Institute Japan, Tokyo, Japan), and  $P < .05$  was considered statistically significant.

## RESULTS

### Patient Characteristics

The patient characteristics are shown in Table 1. No significant differences were found in age or clinical follow-up periods between the Bristow and Latarjet groups. The mean

TABLE 1  
Descriptive Data of Rugby Players (N = 101 shoulders, 91 patients)<sup>a</sup>

	Bristow Group (n = 66 Shoulders, 61 Patients)	Latarjet Group (n = 35 Shoulders, 30 Patients)	P
Age at surgery, y, mean (range)	18.4 (15-26)	17.7 (13-21)	.1964
Sex	All males	All males	—
Dislocations:subluxations, n	31:35	15:20	.8340
Clinical follow-up, mo, mean (range)	73.5 (45-160)	63.5 (50-76)	.3459

<sup>a</sup>Dashes indicate not calculated.

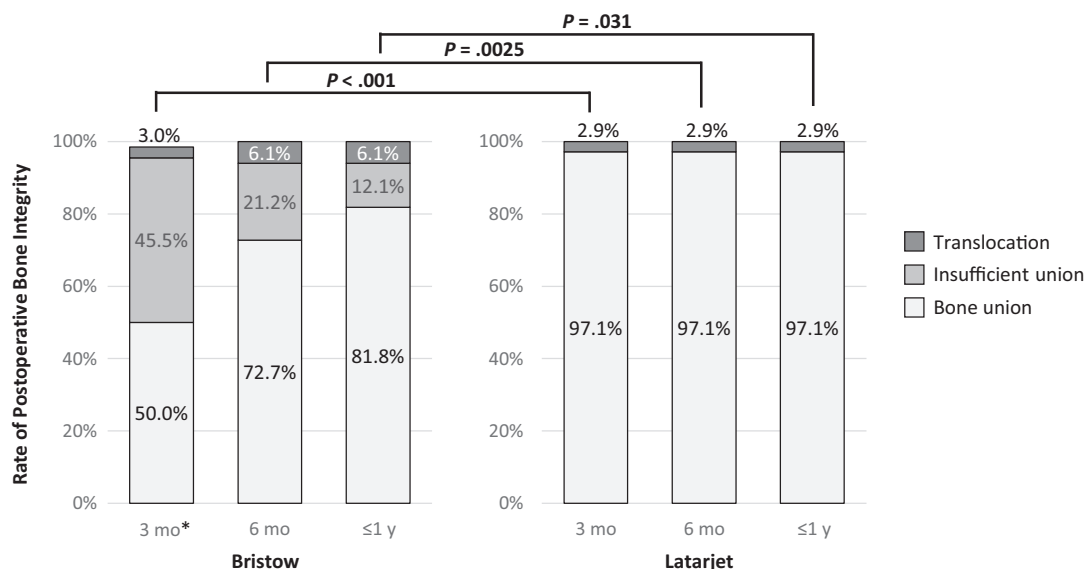


Figure 4. Rate of postoperative bone integrity of the coracoid process. \*One shoulder did not undergo computed tomography examination because insufficient bone union was obvious on radiograph.

face-to-face follow-up was 23.3 months for the Bristow group and 23.1 months for the Latarjet group.

CT was performed 3 months postoperatively for all shoulders, except 1 Bristow-treated shoulder in which insufficient bone union was obvious on radiographs. A total of 55 Bristow-treated shoulders and 25 Latarjet-treated shoulders underwent CT at 6 months, and 36 Bristow-treated shoulders and 30 Latarjet-treated shoulders underwent CT at ≥1 year after surgery. The mean radiographic follow-up was 10.4 months (range, 2.5-47 months) in the Bristow group and 12.1 months (range, 3-26 months) in the Latarjet group ( $P = .144$ ).

### Bone Union Rate

Figure 4 shows the cumulative bone union rate of the coracoid. Bone union was delayed in the Bristow group, and the rate of bone union was significantly lower in the Bristow group than in the Latarjet group at every period (50.0% vs 97.1% at 3 months [ $P < .001$ ], 72.7% vs 97.1% at 6 months [ $P = .0025$ ], and 81.8% vs 97.1% at ≥1 year after

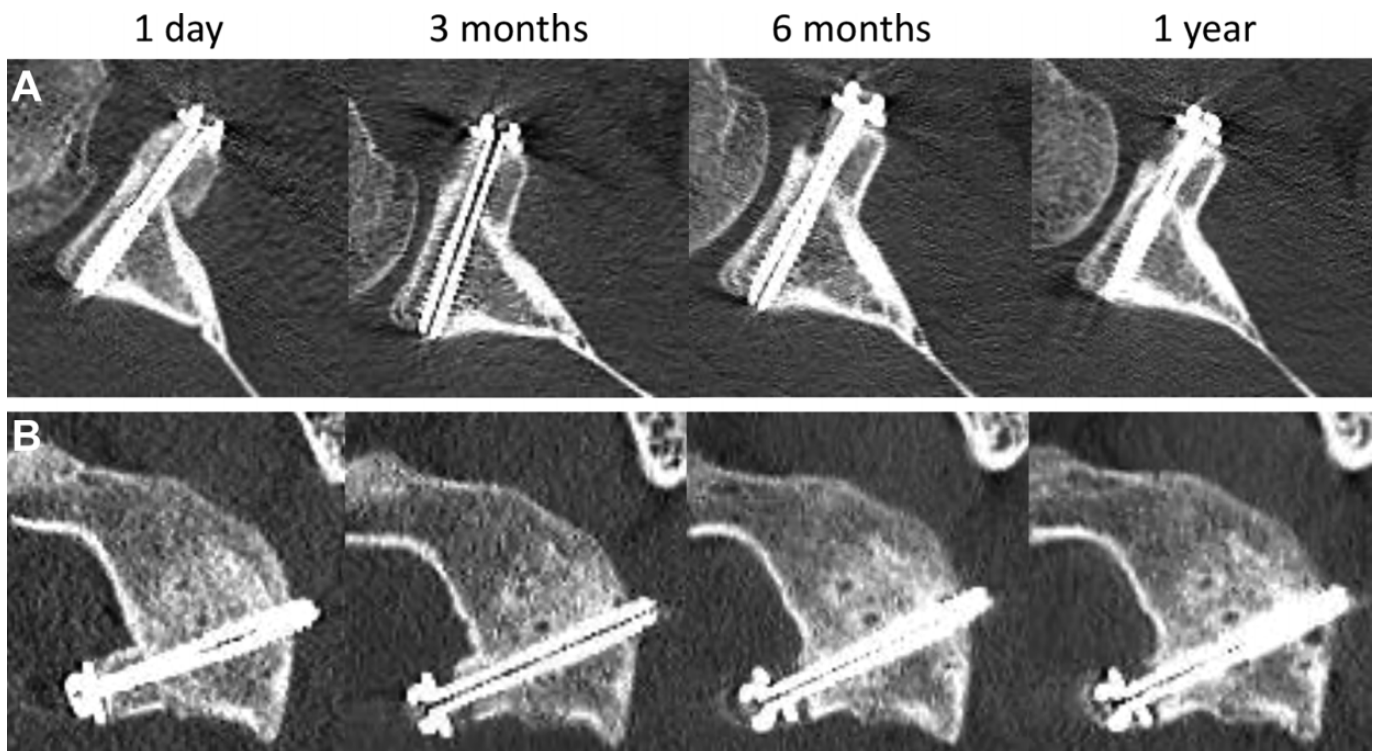
surgery [ $P = .031$ ]). A fracture of the coracoid process caused all cases of translocations, and there were no cases of screw back-out. No new translocations occurred after 6 months postoperatively.

### Bone Resorption

In the Bristow group, bone resorption was observed in 4 shoulders (6%) at 6 months after surgery. Of those, 3 shoulders showed mild bone resorption at the articular side of the coracoid, and 1 shoulder demonstrated moderate bone resorption at the coracoid tip. Representative cases are shown in Figure 5.

Bone resorption was recognized in all cases of the Latarjet group, and progression occurred over time. The progression of bone resorption is summarized in Table 2.

Bone resorption at the superior screw was observed in all shoulders 1 year after surgery, and half of the cases showed a severe degree of bone resorption. Bone resorption at the inferior screw was observed in 20% of cases. The representative cases of the Latarjet group are presented in Figure 6.



**Figure 5.** Representative cases of bone resorption after the Bristow procedure. (A) Axial computed tomography (CT) views of the right shoulder of a 16-year-old boy showing mild bone resorption of the articular side of the coracoid. (B) Sagittal CT views of the left shoulder of a 17-year-old boy showing moderate bone resorption of the coracoid tip.

**TABLE 2**  
Rate of Postoperative Bone Resorption of the Coracoid After the Latarjet Procedure<sup>a</sup>

Bone Resorption	3 mo (n = 35 Shoulders)		6 mo (n = 25 Shoulders)		≥1 y (n = 30 Shoulders)		Cumulative (n = 35 Shoulders)	
	Superior	Inferior	Superior	Inferior	Superior	Inferior	Superior	Inferior
None	5 (14)	34 (97)	0 (0)	22 (88)	0 (0)	23 (77)	0 (0)	28 (80)
Mild	24 (69)	0 (0)	9 (36)	2 (8)	3 (10)	0 (0)	8 (23)	0 (0)
Moderate	4 (11)	0 (0)	9 (36)	0 (0)	9 (30)	2 (7)	9 (26)	2 (6)
Severe	2 (6)	1 (3)	7 (28)	1 (4)	18 (60)	5 (17)	18 (51)	5 (14)

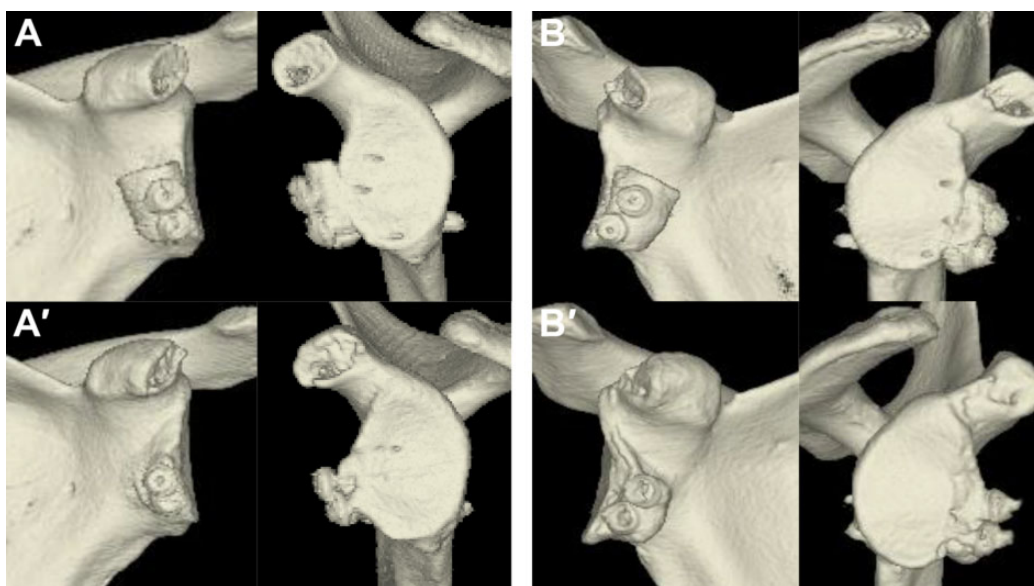
<sup>a</sup>Data are reported as No. (%) of shoulders.

### Recurrence Rate and Return to Sports

Table 3 summarizes recurrences, postoperative pain, and the patients' concerns after RTP. No patients experienced a recurrent dislocation that required manual reduction. Subluxation was significantly more common in the Latarjet group (5 shoulders; 14%) compared with the Bristow group (2 shoulders; 3%) ( $P = .0471$ ). Among those with subluxation, 1 shoulder (2%) with translocation of the coracoid due to fracture in the Bristow group and 1 shoulder (3%) with bone union of the coracoid in the Latarjet group required revision surgeries because of repetitive subluxation. The remaining cases, all of which were bone union cases, did not require revision surgery, and patients could RTP after

only 1 week of rest and could continue to play rugby. A total of 2 shoulders (3%) in the Bristow group and 9 shoulders (26%) in the Latarjet group required intraglenohumeral joint injections due to severe pain during rugby play. Injections were required significantly more often in the Latarjet group than in the Bristow group ( $P = .001$ ).

Postoperative sports activity is summarized in Table 4. All patients in the Bristow group were able to RTP in rugby at the same level as before injury. A total of 34 shoulders (96%) in 29 patients in the Latarjet group could RTP at the same level as before injury, but 1 patient of a revision case returned at a lower level than before injury. The mean postoperative periods before RTP in rugby were 5.8 months (range, 3-12 months) in the Bristow group and 4.8 months



**Figure 6.** Representative cases of bone resorption after the Latarjet procedure on 3-dimensional computed tomography images (axial view on the left and sagittal view on the right of each image pair). (A) Left shoulder of a 17-year-old boy at (A) 1 day after surgery and (A') 1 year after surgery showing bone resorption at both superior and inferior sides of the coracoid process. (B) Right shoulder of a 16-year-old boy at (B) 1 day after surgery and (B') 1 year after surgery showing bone resorption at superior and articular sides of the coracoid process.

**TABLE 3**  
Postoperative Shoulder Stability and Shoulder Conditions<sup>a</sup>

	Bristow Group (n = 66 Shoulders)	Latarjet Group (n = 35 Shoulders)	<i>P</i>
Recurrences			
No recurrence	64 (97)	30 (86)	
Dislocation	0 (0)	0 (0)	
Subluxation	2 (3) (1 bone union, 1 translocation case)	5 (14) (5 bone union cases)	<b>.047</b>
Reoperation	1 (2) (translocation case)	1 (3) (bone union case)	<b>≥.99</b>
Severe pain requiring injections	2 (3)	9 (26)	<b>.001</b>
Concerns when returning to play <sup>b</sup>			
None	19 (29)	8 (23)	.638
Range of motion restrictions	23 (35)	16 (46)	.293
Pain	11 (17)	4 (11)	.567
Fear when colliding	21 (32)	13 (37)	.660
Muscle weakness	16 (24)	14 (40)	.104

<sup>a</sup>Data are reported as No. (%) of shoulders. Bolded *P* values indicate statistically significant difference between groups ( $P < .05$ ).

<sup>b</sup>Players could report >1 concern.

(range, 3-7 months) in the Latarjet group, which represented a statistically significant difference ( $P = .001$ ). The reason for retiring was graduation from school or age. No patients retired from playing rugby because of shoulder problems. No statistically significant differences were found in the levels of RTP and rugby activities between groups.

#### Clinical Scores

Clinical scores are summarized in Table 5. Both the ASES and Rowe scores at the final follow-up significantly

improved in the Bristow and Latarjet groups compared with preoperative scores ( $P < .001$  for all). The average satisfaction rate was 92.0% in the Bristow group and 94.3% in the Latarjet group, with no significant difference between the 2 groups ( $P = .2758$ ).

#### DISCUSSION

The main findings of this study are that Bristow and Latarjet procedures had high rates of RTP and good outcome scores. We also found that the open Latarjet procedure

decreased the nonunion rate of the coracoid process but resulted in greater coracoid bone resorption compared with the open Bristow procedure and that subluxation and pain after returning to sports were recognized more frequently in patients who underwent the open Latarjet procedure than in those who underwent the open Bristow procedure. We hypothesized that the Latarjet procedure would have a higher rate of bone union and better clinical outcomes, but higher bone union rates did not lead to better clinical outcomes.

Excellent clinical outcomes have been reported for both Bristow<sup>18,31</sup> and Latarjet procedures,<sup>25,26</sup> including a low rate of recurrence, high rate of return to sports, and good clinical scores. In this study, the clinical scores and RTP in rugby were similar for both Bristow and Latarjet procedures, with high satisfaction rates. However, about 71% of patients in Bristow procedure and 77% of patients in Latarjet procedure had concerns after RTP. This suggests that although both procedures are good at restoring stability, they do not return the shoulder to normal. In both procedures, the coracohumeral ligaments and pectoralis minor tendon must be dissected to some extent. The coracoacromial<sup>29</sup> and coracohumeral<sup>17,32</sup> ligaments play key roles in shoulder stability, and the pectoralis minor muscle is

related to scapular kinematics.<sup>5</sup> Minor stability and/or scapular dyskinesis caused by dissection of these ligaments and tendon could be the reasons for muscle weakness, fear when colliding, and pain after RTP.

The Latarjet procedure entailed higher rates of subluxation and required more frequent injections for pain compared with the Bristow procedure; this finding was consistent with that of a previous systematic review.<sup>8</sup> We suspect that these findings could be caused by minor instability after the Latarjet procedure. One reason for this suspicion is that fewer tissues support the anterosuperior to middle side of the glenohumeral joint. The conjoint tendon was positioned lower and closer to the glenoid in the Latarjet procedure compared with the Bristow procedure. In addition, the superior side of the coracoid process was absorbed after the Latarjet procedure, and bony augmentation at the middle part of the glenoid was less reliable than that after the Bristow procedure. Biomechanically, both procedures showed excellent stabilizing effects against the major instability to the anteroinferior side, but we are skeptical about the minor instability to the anterosuperior to middle side. A second reason for the above-mentioned suspicion is that a larger portion of the coracoid process was resected during the Latarjet procedure compared with the Bristow procedure, and eventually the amount of dissection of the coracoacromial ligament, the coracohumeral ligaments, and the pectoralis minor tendon must be larger with the Latarjet procedure compared with the Bristow procedure. This is our hypothesis, but these less supportive tissues at the anterosuperior site of the glenoid and the dissection of anterosuperior stabilizers might cause minor anterosuperior instability and lead to postoperative pain after the Latarjet procedure. One proof regarding our hypothesis is that anterosuperior subluxation over the united coracoid process with failed Bankart repair was recognized in the revision case after the Latarjet procedure, which means that concomitant restoration of the glenohumeral ligament and labrum is important.

After completing the coracoid transfer, we performed Bankart repair using 3 anchors. A systematic review showed that RTP at the same level, especially in contact sports, was relatively low with the Latarjet procedure without Bankart repair.<sup>16</sup> We believe that the Bankart repair concomitant with the coracoid transfer is essential to treat anterior shoulder

TABLE 4  
Return to Play and Continuity of Rugby Activity<sup>a</sup>

	Bristow Group	Latarjet Group	<i>P</i>
Return to play			.346
Same level	66 (100)	34 (96)	
Lower level	0 (0)	1 (4)	
Period before return to play, mo	5.8	4.8	<b>.001</b>
Current rugby activity			.675
Same level	26 (39)	17 (49)	
Lower level	6 (9)	3 (9)	
Retired	34 (52)	15 (43)	
Period before retiring, mo (range)	41.4 (12-121)	43.6 (13-62)	.387

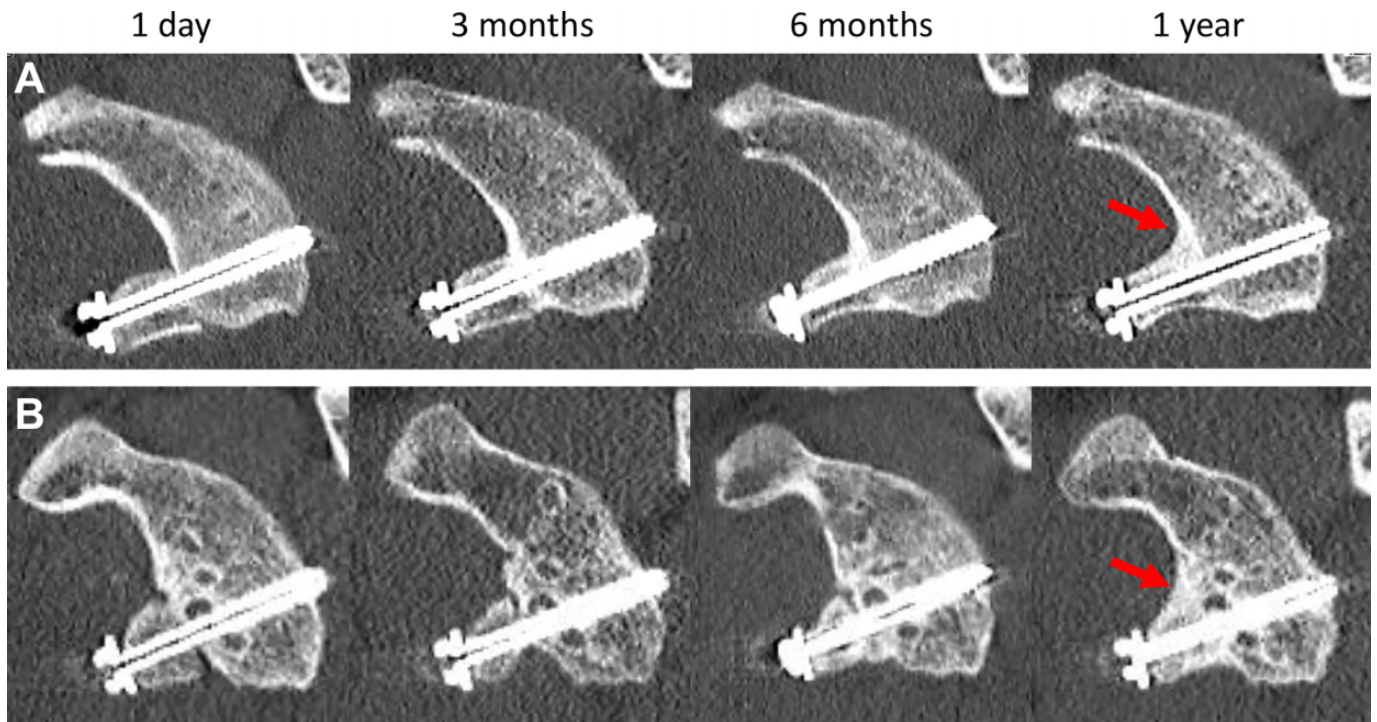
<sup>a</sup>Data are reported as No. (%) of shoulders unless otherwise noted. Bolded *P* value indicates statistically significant difference between groups (*P* < .05).

TABLE 5  
Preoperative and Postoperative Shoulder Scores<sup>a</sup>

	Bristow Group			Latarjet Group		
	Preoperative	Postoperative	<i>P</i>	Preoperative	Postoperative	<i>P</i>
ASES	48.0 (44.2-51.6)	91.0 (88.4-93.5)	<b>&lt;.001</b>	60.8 (57.7-85.5)	90.2 (85.6-94.8)	<b>&lt;.001</b>
Rowe	30.6 (27.0-34.2)	88.5 (85.1-91.9)	<b>&lt;.001</b>	38.7 (36.6-40.9)	86.4 (81.2-91.6)	<b>&lt;.001</b>
Satisfaction rate, %	NA	92.0 (88.9-95.1)	—	NA	94.3 (90.6-97.9)	—

<sup>a</sup>Data are reported as mean (95% CI). Bolded *P* values indicate statistically significant difference between groups (*P* < .05). ASES, American Shoulder and Elbow Surgeons; NA, not available. Dashes indicate not calculated.





**Figure 7.** Representative cases of the enlargement of the glenoid area (red arrows) after the Bristow procedure, as shown on sagittal computed tomography view. (A) Right shoulder of a 15-year-old boy. (B) Left shoulder of a 16-year-old boy.

instability in contact sports athletes. In contrast, patients who underwent the Latarjet procedure returned to playing rugby on average 4.8 months postoperatively, which was 1 month earlier than RTP with the Bristow procedure (5.8 months). RTP was earlier with the Latarjet procedure because of the early and consistent bone union, but restoration of soft tissues and muscle strength might not be enough at 5 months postoperatively, and early return to rugby might be related to the higher subluxation rates and more frequent injections required with the Latarjet procedure.

Several reports have mentioned that a high rate of bone union has been achieved with the Latarjet procedure,<sup>9,19</sup> whereas a comparatively low rate of bone union has been achieved with the Bristow procedure.<sup>2,9</sup> In this study, a high rate of early bone union (97% at 3 months postoperatively) was achieved with the Latarjet procedure, whereas delayed bone union was achieved with the Bristow procedure. Fixation using 2 screws was more reliable in securing the separated bones. A single lag screw fixation can exert a compression force between the coracoid and glenoid neck with the Bristow procedure. However, this fixation might be too weak to control the rotation of the coracoid, which could delay bone union. Early and secure bone union could allow patients to RTP earlier, which is very important for competitive athletes, and we noted a significant difference between the procedures (Latarjet, 4.8 months; Bristow, 5.8 months;  $P = .001$ ).

As 3-dimensional CT examinations are becoming common, several reports regarding bone resorption after the Latarjet procedure have been published.<sup>1,7,13,36</sup> However,

few reports are available regarding bone resorption after the Bristow procedure.<sup>3</sup> In this study, bone resorption was observed in 6.1% of cases, and the degree of bone resorption was not severe. Boileau et al<sup>3</sup> reported bone resorption in 7% of cases after the Bristow procedure. In contrast, the reported frequency of bone resorption after the Latarjet procedure has ranged from 66.7% to 100%.<sup>1,7,13,36</sup>

In the current study, bone resorption was observed in 100% of cases after the Latarjet procedure. The progress of bone resorption was particularly remarkable between 3 and 6 months after the operation, which was after bone union was completed, and seemed to be caused by adapting and remodeling of the glenoid (Figure 6). Bone resorption after the Latarjet procedure was recognized mainly at the superior screws and was uncommon around the inferior screws, where the conjoint tendon is attached. This outcome may be caused by low contact of the humeral head or by disruption of the blood supply and/or stress shielding at the resection site of the coracoid process. Return to sports was usually allowed at 4 to 6 months after surgery. This finding means that bone resorption occurred before RTP in rugby, and bony augmentation became smaller when necessary. Even though detailed analysis was not conducted in this study, we found several cases in which the surface area of the glenoid increased after the Bristow procedure (Figure 7). This increase might have been caused by remodeling of the glenoid surface or callus formation around the border between the coracoid process and glenoid surface. After bone union is achieved after the Bristow procedure, the effect of bone block of the coracoid can be more reliable than that after the Latarjet procedure.

The merits of the Bristow procedure are a lower rate of subluxation and pain after RTP. The shortcomings of the open Bristow procedure are delayed and lower bone union rates and later return to sports. Reoperation after the Bristow procedure was performed in 1 shoulder with postoperative fracture of the coracoid process. The important point to improve results after the open Bristow procedure is to ameliorate the bone union rates. Confirming the fixation arthroscopically and/or preparing better contact of the coracoid process against the glenoid might help overcome the disadvantages of the open Bristow procedure. In contrast, the merits of the Latarjet procedure include early bone union, high rates of bone union, and early return to sports; the shortcomings of the Latarjet procedure are bone resorption of the coracoid process, a higher rate of requiring injections for pain after RTP, and higher rate of subluxation compared with the Bristow procedure. A possible way to reduce failure after the Latarjet procedure is to make sure the coracoid process is long enough to insert 2 screws but otherwise is as short as possible and fix the coracoid process superiorly on the glenoid: for example, placing the coracoid tips at the 4-o'clock position on the right shoulder.

### Limitations

This study had several limitations. First, this was not a randomized study, and it described the different procedures at sequential time periods. Second, the unequal sample number could have caused statistical bias. However, there were enough patients in each group to perform appropriate statistical analysis, so we believe that the number of patients does not affect the conclusions. Third, not all patients underwent CT examinations at >6 months. CT examination is invasive in terms of radiation exposure; therefore, CT examination must be performed with a patient's agreement. After bone union was confirmed, some patients were reluctant to undergo CT examination. Fourth, we did not address preoperative conditions, such as number of preoperative instability events and glenoid bone loss, which could affect the clinical results. Fifth, the final follow-up and clinical scoring were completed using questionnaires accessible via an online survey tool. Patients did not undergo direct physical examinations at the final follow-up, including range of motion, apprehension sign, and muscle strength. We did not address range of motion restrictions, which was the most prevalent concern after RTP. However, using an online survey tool, we could achieve a high rate of data collection (100%) with the help of the team. After patients have returned to sports and experience no problems, it is difficult to ask athletes to keep visiting the hospital, so the middle- to long-term follow-up after treatment of athletes is usually low. Online survey tools could be the option to overcome this problem.

### CONCLUSION

Both Bristow and Latarjet procedures had high rates of RTP and good clinical results. However, 75% of patients had continued concerns regarding the shoulder after RTP.

The Latarjet procedure had an advantage in early and high bone union but a disadvantage in bone resorption compared with the Bristow procedure. Subluxation and injections for pain after returning to sports were recognized more frequently in patients who underwent the open Latarjet procedure than those who underwent the open Bristow procedure.

### ACKNOWLEDGMENT

The authors thank Prof Luc Favard and Dr Yves Bouju for their instruction in the surgical procedure. This study could not have been accomplished without the help of the rugby teams' staff to collect data of the questionnaires using Google form. Special thanks to Dr Masayasu Takahashi of Konan Medical Center (Kobe, Japan), who is one of the team doctors for Kobelco Steelers Kobe; Dr Shinnosuke Hada of Tokyo Rosai Hospital (Tokyo, Japan), who is one of the team doctors for Yokohama Canon Eagles; and Dr Mutsuo Yamada of Ryutsu Keizai University (Ibaraki, Japan), who is a team doctor of the rugby football club of RKU. The authors also acknowledge the coaches and trainers of the rugby teams Hanazono Kintetsu Liners, NTT Docomo RedHurricanes Osaka, Shizuoka BlueRevs, Tenri University, Doshisha University, Ritsumeikan University, Kindai University, Kansai University, Osaka University of Health and Sport Science, Kyoto Seisho High School, Tokai University Osaka Gyosei High School, Osaka Toin High School, Osaka Korean High School, Kansai University Hokuyo Senior High School, Josho Keiko Gakuen Senior High School, and Gose Industrial High School. Finally, thanks go to Enago ([www.enago.jp](http://www.enago.jp)) for the English-language review.

Supplemental material for this article is available at <http://journals.sagepub.com/doi/suppl/10.1177/23259671221095094>.

### REFERENCES

- Balestro JC, Young A, Maccioni C, Walch G. Graft osteolysis and recurrent instability after the Latarjet procedure performed with bioabsorbable screw fixation. *J Shoulder Elbow Surg.* 2015;24(5):711-718.
- Banas MP, Daldorf PG, Sebastianeli WJ, DeHaven KE. Long-term followup the modified Bristow procedure. *Am J Sports Med.* 1993;21(5):666-671.
- Boileau P, Th  lu C  , Mercier N, et al. Arthroscopic Bristow-Latarjet combined with Bankart repair restores shoulder stability in patients with glenoid bone loss. *Clin Orthop Relat Res.* 2014;472(8):2413-2424.
- Bouju Y, Gad  a F, Stanovici J, Moubarak H, Favard L. Shoulder stabilization by modified Latarjet-Patte procedure: results at a minimum 10 years' follow-up, and role in the prevention of osteoarthritis. *Orthop Traumatol Surg Res.* 2014;100(4S):S213-S218.
- Carbone S, Moroder P, Runer A, Resch H, Gumina S, Hertel R. Scapular dyskinesia after Latarjet procedure. *J Shoulder Elbow Surg.* 2016;25(3):422-427.

6. Cowling PD, Akhtar MA, Liow RYL. What is a Bristow-Latarjet procedure? A review of the described operative techniques and outcomes. *Bone Joint J*. 2016;98-B(9):1208-1214.
7. Di Giacomo G, de Gasperis N, Costantini A, De Vita A, Beccaglia MAR, Pouliart N. Does the presence of glenoid bone loss influence coracoid bone graft osteolysis after the Latarjet procedure? A computed tomography scan study in 2 groups of patients with and without glenoid bone loss. *J Shoulder Elbow Surg*. 2014;23(4):514-518.
8. Garcia JC, do Amaral FM, Belchior RJ, de Carvalho LQ, Markarian GG, Montero EF de S. Comparative systematic review of fixation methods of the coracoid and conjoined tendon in the anterior glenoid to treat anterior shoulder instability. *Orthop J Sports Med*. 2019;7(1):2325967118820539.
9. Gendreau P, Thélu CE, d'Ollonne T, Trojani C, Gonzalez JF, Boileau P. Coracoid bone block fixation with cortical buttons: an alternative to screw fixation? *Orthop Traumatol Surg Res*. 2016;102(8):983-987.
10. Gil JA, DeFroda S, Owens BD. Current concepts in the diagnosis and management of traumatic, anterior glenohumeral subluxations. *Orthop J Sports Med*. 2017;5(3):2325967117694338.
11. Giles JW, Boons HW, Elkinson I, et al. Does the dynamic sling effect of the Latarjet procedure improve shoulder stability? A biomechanical evaluation. *J Shoulder Elbow Surg*. 2013;22(6):821-827.
12. Giles JW, Degen RM, Johnson JA, Athwal GS. The Bristow and Latarjet procedures: why these techniques should not be considered synonymous. *J Bone Joint Surg Am*. 2014;96(16):1340-1348.
13. Haeni DL, Opsomer G, Sood A, et al. Three-dimensional volume measurement of coracoid graft osteolysis after arthroscopic Latarjet procedure. *J Shoulder Elbow Surg*. 2017;26(3):484-489.
14. Hardy A, Sabatier V, Laboudie P, et al. Outcomes after Latarjet procedure: patients with first-time versus recurrent dislocations. *Am J Sports Med*. 2020;48(1):21-26.
15. Hovelius L, Vikersfors O, Olofsson A, Svensson O, Rahme H. Bristow-Latarjet and Bankart: a comparative study of shoulder stabilization in 185 shoulders during a seventeen-year follow-up. *J Shoulder Elbow Surg*. 2011;20(7):1095-1101.
16. Hurley ET, Montgomery C, Jamal MS, et al. Return to play after the Latarjet procedure for anterior shoulder instability: a systematic review. *Am J Sports Med*. 2019;47(12):3002-3008. doi:10.1177/0363546519831005
17. Jost B, Koch PP, Gerber C. Anatomy and functional aspects of the rotator interval. *J Shoulder Elbow Surg*. 2000;9(4):336-341.
18. Kawasaki T, Hasegawa Y, Kaketa T, et al. Midterm clinical results in rugby players treated with the Bristow procedure. *Am J Sports Med*. 2018;46(3):656-662.
19. Kordasiewicz B, Kicinski M, Małachowski K, Wieczorek J, Chaberek S, Pomianowski S. Comparative study of open and arthroscopic coracoid transfer for shoulder anterior instability (Latarjet)—computed tomography evaluation at a short term follow-up, part II. *Int Orthop*. 2018;42(5):1119-1128.
20. Lee SH, Lim KH, Kim JW. Risk factors for recurrence of anterior-inferior instability of the shoulder after arthroscopic Bankart repair in patients younger than 30 years. *Arthroscopy*. 2018;34(9):2530-2536.
21. Mazzocca AD, Brown FM, Carreira DS, Hayden J, Romeo AA. Arthroscopic anterior shoulder stabilization of collision and contact athletes. *Am J Sports Med*. 2005;33(1):52-60.
22. Nakagawa S, Hirose T, Uchida R, Tanaka M, Mae T. Postoperative recurrence of instability after arthroscopic Bankart repair for shoulders with primary instability compared with recurrent instability: influence of bipolar bone defect size. *Am J Sports Med*. 2020;48(1):48-55.
23. Nakagawa S, Mae T, Sato S, Okimura S, Kuroda M. Risk factors for the postoperative recurrence of instability after arthroscopic Bankart repair in athletes. *Orthop J Sports Med*. 2017;5(9):2325967117726494.
24. Nourissat G, Delarochette C, Bouillet B, Doursounian L, Aim F. Optimization of bone-block positioning in the Bristow-Latarjet procedure: a biomechanical study. *Orthop Traumatol Surg Res*. 2014;100(5):509-513.
25. Privitera DM, Sinz NJ, Miller LR, et al. Clinical outcomes following the Latarjet procedure in contact and collision athletes. *J Bone Joint Surg Am*. 2018;100(6):459-465.
26. Ranalletta M, Rossi LA, Bertona A, et al. Modified Latarjet without capsulolabral repair in rugby players with recurrent anterior glenohumeral instability and significant glenoid bone loss. *Am J Sports Med*. 2018;46(4):795-800.
27. Rhee YG, Ha JH, Cho NS. Anterior shoulder stabilization in collision athletes. *Am J Sports Med*. 2006;34(6):979-985.
28. Richards RR, An KN, Bigliani LU, et al. A standardized method for the assessment of shoulder function. *J Shoulder Elbow Surg*. 1994;3(6):347-352.
29. Rothenberg A, Gasbarro G, Chlebeck J, Lin A. The coracoacromial ligament: anatomy, function, and clinical significance. *Orthop J Sports Med*. 2017;5(4):2325967117703398.
30. Rowe CR, Patel D, Southmayd WW. The Bankart procedure: a long-term end-result study. *J Bone Joint Surg Am*. 1978;60(1):1-16.
31. Tasaki A, Morita W, Yamakawa A, et al. Combined arthroscopic Bankart repair and coracoid process transfer to anterior glenoid for shoulder dislocation in rugby players: evaluation based on ability to perform sport-specific movements effectively. *Arthroscopy*. 2015;31(9):1693-1701.
32. Terra BB, de Figueiredo EA, Marczyk CSF, et al. Osteotomies of the coracoid process: an anatomical study. *Rev Bras Ortop*. 2015;47(3):337-343.
33. Torrance E, Clarke CJ, Monga P, Funk L, Walton MJ. Recurrence after arthroscopic labral repair for traumatic anterior instability in adolescent rugby and contact athletes. *Am J Sports Med*. 2018;46(12):2969-2974.
34. Yamamoto N, Muraki T, An KN, et al. The stabilizing mechanism of the Latarjet procedure: a cadaveric study. *J Bone Joint Surg Am*. 2013;95(15):1390-1397.
35. Yoneda M, Hayashida K, Wakitani S, Nakagawa S, Fukushima S. Bankart procedure augmented by coracoid transfer for contact athletes with traumatic anterior shoulder instability. *Am J Sports Med*. 1999;27(1):21-26.
36. Zhu YM, Jiang CY, Lu Y, Li FL, Wu G. Coracoid bone graft resorption after Latarjet procedure is underestimated: a new classification system and a clinical review with computed tomography evaluation. *J Shoulder Elbow Surg*. 2015;24(11):1782-1788.