


## CLINICAL ARTICLE

# Analysis of Factors Affecting Early Functional Recovery of Bernese Periacetabular Osteotomy

Yan-ge Gu<sup>1,2</sup> , Zhi-wei Shi<sup>1,2</sup>, Yao-hui Yue<sup>1,2</sup>, Zhao-long Yan<sup>2</sup>, Lu-xu Yin<sup>2</sup>, Ye-yong Zhang<sup>2</sup>, Hua-qiang Sun<sup>2</sup>, Shu-feng Li<sup>2</sup>, Xin-feng Yan<sup>2</sup>

<sup>1</sup>School of Medicine, Shandong University and <sup>2</sup>Department of Orthopaedic Surgery, The First Affiliated Hospital of Shandong First Medical University & Shandong Provincial Qianfoshan Hospital, Shandong Key Laboratory of Rheumatic Disease and Translational Medicine, Jinan, China

**Objectives:** To explore factors affecting the efficacy of Bernese periacetabular osteotomy for the treatment of hip dysplasia.

**Methods:** A retrospective study was conducted on 44 patients with hip dysplasia who underwent Bernese periacetabular osteotomy with a modified Smith-Peterson approach between January 2017 and November 2019. Among them, 40 were women and four were men. The average age was  $31.2 \pm 9.4$ . Preoperative and postoperative imaging parameters were measured. The acetabular top tilt angle, lateral central edge angle, acetabular abduction angle, femoral head extrusion index, sphericity index of femoral head, Shenton line, Tonnis grade of osteoarthritis, joint congruency, p/a ratio, acetabular anteversion angle, Western Ontario and McMaster Universities Osteoarthritis Index (WOMAC) scale scores, and modified Harris hip score (MHHS) were observed. MHHS were divided into three clinically relevant categories: poor (<70 points), good (70–85 points), and excellent (86–91 points). Patient demographic data, as well as preoperative and postoperative radiographic parameters, were subjected to univariate logistic regression analysis. Multiple regression analysis was used to determine factors influencing postoperative MHHS.

**Results:** The follow-up time was 1.0–3.9 years after surgery, with an average of 1.6 years. By the last follow-up, MHHS increased from 70 points before surgery to 91 points after surgery ( $P < 0.001$ ), WOMAC pain score decreased from 4 points before surgery to 0 points after surgery ( $P < 0.001$ ). WOMAC functional score decreased (Preoperative: 18.0 [4.0]; Postoperative: 4.0 [0],  $P = 0.004$ ). Six patients had sensory disturbance of the lateral femoral cutaneous nerve, four of which recovered completely during follow-up. No other complications related to surgical approach, osteotomy, acetabular displacement, acetabular fixation, and postoperative stage were found. There was no significant vascular, nerve, or visceral injuries in any of the patients. On multiple regression analysis, the probability of the postoperative modified Harris hip score of a hip joint with a preoperative lateral center edge angle  $\geq 4.5^\circ$  being classified as excellent was six times that of angles  $< 4.5^\circ$  (Exp[ $\beta$ ]: 6.249, 95% CI: 1.03–37.85,  $P = 0.046$ ). Regression analysis of other factors found no significant correlation with postoperative functional scores.

**Conclusion:** Overall functional scores post-PAO significantly improved, and pain symptoms were significantly reduced. Patients with a preoperative lateral center edge angle  $\geq 4.5^\circ$  had better joint function after surgery.

**Key words:** Acetabular dysplasia; Bernese periacetabular osteotomy; Developmental dysplasia of the hip; Outcome assessment

**Address for correspondence** Xin-feng Yan and Shu-feng Li, Department of Orthopaedic Surgery, The First Affiliated Hospital of Shandong First Medical University and Shandong Provincial Qianfoshan Hospital, Shandong Key Laboratory of Rheumatic Disease and Translational Medicine, 16766 Jing Shi Road, Jinan, Shandong, China 250014 Tel: 13869112527; Email: yanxinfeng@sdhospital.com.cn (Yan); Tel: 15168889967; Email: 15168889967@126.com (Li)

All authors listed meet the authorship criteria and all authors are in agreement with the manuscript.

Received 26 February 2021; accepted 26 May 2021

## Introduction

Developmental dysplasia of the hip (DDH) is characterized by insufficient coverage of the femoral head and an upper lateral tilt of the acetabular joint surface, resulting in a reduction in the contact area between the femoral head and the acetabulum, thereby making the joint unstable and overloading the acetabular edge. The labrum and cartilage are damaged as a result, and this eventually progresses to secondary osteoarthritis<sup>1-3</sup>. Ganz *et al.* reported in 1988 that a new type of periacetabular osteotomy using the iliac-inguinal approach was applied to treat DDH, specifically Bernese periacetabular osteotomy (PAO). This technique overcomes some of the shortcomings of traditional hip-preserving surgery and has since become widely used worldwide and has become one of the main methods of hip-preserving treatment for DDH. For young patients with normal hip cartilage, PAO is the best surgical option to treat hip joint pain and improve the mechanical load conditions related to dysplasia. It can resolve both biomechanical and structural abnormalities of the hip joint in patients with DDH, correct the pathological mechanism of the hip joint, relieve symptoms, maintain or improve the patient's mobility, and delay and prevent the occurrence of secondary osteoarthritis. There is increasing evidence that Bernese periacetabular osteotomy can improve the protection of hip joints in patients with DDH.

A study on the recovery of activity of patients during the mid-term follow-up after PAO showed that 67% of the patients had a good overall clinical effect and maintained a high level of activity. In the middle stage after PAO, most patients can return to a high level of activity, maintain an active lifestyle, effectively relieve pain, and improve their quality of life<sup>4</sup>. Although there is evidence that PAO can achieve reliable deformity correction and improve functional prognosis<sup>5</sup>, it is not clear which patients will benefit the most from this surgery. The study by Petrie *et al.*<sup>6</sup> showed that patients with lower preoperative activity levels had higher postoperative University of California Los Angeles (UCLA) activity scores, and that history of ipsilateral surgery was a predictor of changes in UCLA scores. PAO performed after prior pelvic surgery is associated with improvements in pain symptoms, function, radiographic correction, and early complication rates, but the improvements observed at short-term follow-up were smaller and more variable than those seen in patients who had not undergone prior pelvic surgery<sup>7</sup>. In addition, increased postoperative pain is a predictor of longer postoperative recovery time<sup>8</sup>. If the postoperative acetabular top tilt angle was less than 15° and the lateral central edge angle (LCEA) was between 20° and 40°, a higher Western Ontario and McMaster Universities Osteoarthritis Index (WOMAC) scale score would be obtained<sup>9</sup>. Despite the growing use of PAO to treat symptomatic dysplasia of the hip, the optimal selection criteria for surgery and factors for functional recovery are still evolving. The main factors affecting the effect and survival of PAO surgery are as follows: preoperative imaging results, postoperative imaging

results, demographic factors, and surgical complications. Recent studies focus on assessing the medium- and long-term outcomes of PAO. Some of them have identified several predictors of surgical failure, including age older than 25 years, poor congruency, Tonnis grade of hip osteoarthritis  $\geq$  grade 2, etc<sup>10</sup>.

Accurate acetabular correction is an important means to improve hip joint function and relieve pain. In repositioning the osteotomy fractures and increasing the coverage of the femoral head while improving the load distribution of the entire joint, this correction process is a key part of PAO surgery. However, a large number of studies do not attempt to correlate deformity correction or imaging parameters with clinical results as neither the level of patient function nor the factors that influence clinical and functional outcome are well-described. Based on the level of evidence provided by existing studies, many factors affecting the effectiveness of PAO surgery are not fully understood. We speculate that there are other demographic or imaging factors that may affect hip joint function after PAO. Therefore, we collected the demographic data of patients, observed changes in imaging parameters before and after the operation, confirmed the functional recovery of the patients after the operation, and used regression analysis to identify factors that affect the functional score after PAO. The purpose of this study: (i) to evaluate the improvement of hip joint function after PAO; (ii) to analyze the changes in the radiographic parameters of patients after PAO; and (iii) to explore the factors that affect early functional recovery after PAO.

## Materials and Methods

### Inclusion and Exclusion Criteria

This was a single-center retrospective study. The inclusion criteria: (i) patients with DDH aged 12–50 years whose Tonnis grade of hip osteoarthritis were  $\leq 2$  and crown grade of grade 1 and lateral center edge angle were  $< 15^\circ$ ; (ii) underwent PAO between January 2017 and November 2019; (iii) changes in the imaging parameters and functional scores of patients after PAO; (iv) factors that affect the functional scores after PAO; and (v) a retrospective study. The exclusion criteria were: (i) a history of hip joint trauma; (ii) an existing nerve, muscle, or connective tissue disease; (iii) a history of hip surgery; (iv) severe joint deformity; (v) hip flexion and extension range of motion  $< 90^\circ$ ; and (vi) acetabular retroversion (positive cross sign).

### Patient Data

The research objects were patients who underwent modified Smith-Peterson (MSP) approach PAO to treat DDH in our hospital between January 2017 and November 2019. During this period, a total of 75 patients underwent Bernese PAO. However, 16 cases wherein the iliac-inguinal approach was used were excluded, five cases were lost to follow-up, eight cases had incomplete imaging data, and there were two cases of acetabular retroversion. The sample size estimation was

based on the principle of 10 outcome events per variable. Using an estimated incidence of excellent results of 77% in the study patients<sup>5</sup> and three influencing factors, we aimed to enroll 40 patients and eventually enrolled 44, including 40 women and four men with a mean age of  $31.2 \pm 9.4$  (range, 12–49) years.

## Surgical Procedure

### Anesthesia and Position

The patient was positioned supine on a radiolucent table. We typically used general anesthesia. The involved extremity was prepared and draped free to the costal margin, medially to the umbilicus, and posteriorly to the posterior third of the ilium<sup>11</sup>.

### Approach and Exposure

All the PAOs were performed by the same surgeon using an MSP approach and a surgical technique that preserves the abductor muscle. The procedure has been described in detail previously<sup>12</sup>. An incision was made forward and downward from the front of the iliac crest with a length of 15–18 cm. The skin, subcutaneous tissue, and the deep fascia were cut successively. The anterior superior iliac spine was chiseled. The ligamentum inguinale and the starting point of sartorius were pulled together toward the inside. The surgeon entered through the lower segment from the fascia lata separation between the tensor and sartorius while protecting the lateral femoral cutaneous nerve. The upper segment was stripped within the periosteum of the ilium. The origin of the rectus femoris was incised and reflected and the iliac wall, as well as the four sides of the body, the upper ramus of the pubic bone, and the hip capsule were revealed. The interspace between medial side of the hip capsule and the iliolumbar tendon and neck of femur, and ischial ramus were revealed.

### Osteotomy Steps of PAO

The specific osteotomy steps of PAO have been reported in detail in previous literature<sup>5,11,13</sup>. The first step is an incomplete osteotomy of the ischium, starting from the inferior acetabular groove (the posterior lower edge of the acetabulum), using a 30° forked, angled bone chisel, and the osteotomy depth is 2.0–2.5 cm. The second step is an osteotomy of the pubic bone inside the iliac pubic eminence. In the third step, osteotomy is performed above and behind the acetabulum. The fourth step is the meeting, namely from the inner side of the pelvis, wherein the first step ischial insufficiency osteotomy line and the third step acetabular osteotomy line are connected with an arc osteotome. The osteotomy process is evaluated and corrected by intraoperative X-ray fluoroscopy.

### Acetabular Displacement and Fixation

After completion of osteotomy, the osteotomy block was clamped by the acetabular reset forceps and rotated to a satisfactory position with the acetabulum apex angle close to 0°

under perspective<sup>14</sup>. The acetabulum was mildly anteverted, and the acetabular rotation center was unchanged or slightly displaced and fixed with 4.5 mm pelvic screws. The site was then flushed and sutured.

### Postoperative Rehabilitation

Within 6 weeks after the operation, the affected limb was allowed partial weight bearing. This weight bearing capacity was gradually increased after 6 weeks. Furthermore, 3 months after surgery, the bone had healed, and complete weight loading was permitted.

### Radiographic Assessment

An independent observer used standard anterior and posterior X-rays of both hips obtained before the operation and during the clinical follow-up period at least 1 year after the operation for radiographic measurements. Radiographic parameters included: the acetabular top tilt angle (Tonnis angle), lateral center edge angle (LCEA), acetabular abduction angle (ABA), femoral head extrusion index (EI), sphericity index of femoral head, Shenton line, distance from the innermost surface of the femoral head to the ilioischial line, osteoarthritis Tonnis grade<sup>15</sup>, joint congruency<sup>16</sup>, p/a ratio<sup>17</sup> and corresponding acetabular anteversion angle (AAA). All the above imaging parameters were measured on the standard anterior and posterior X-rays of both hips. The measurement methods<sup>11,15</sup> of imaging parameters are shown in Fig. 1.

### Acetabular Top Tilt Angle

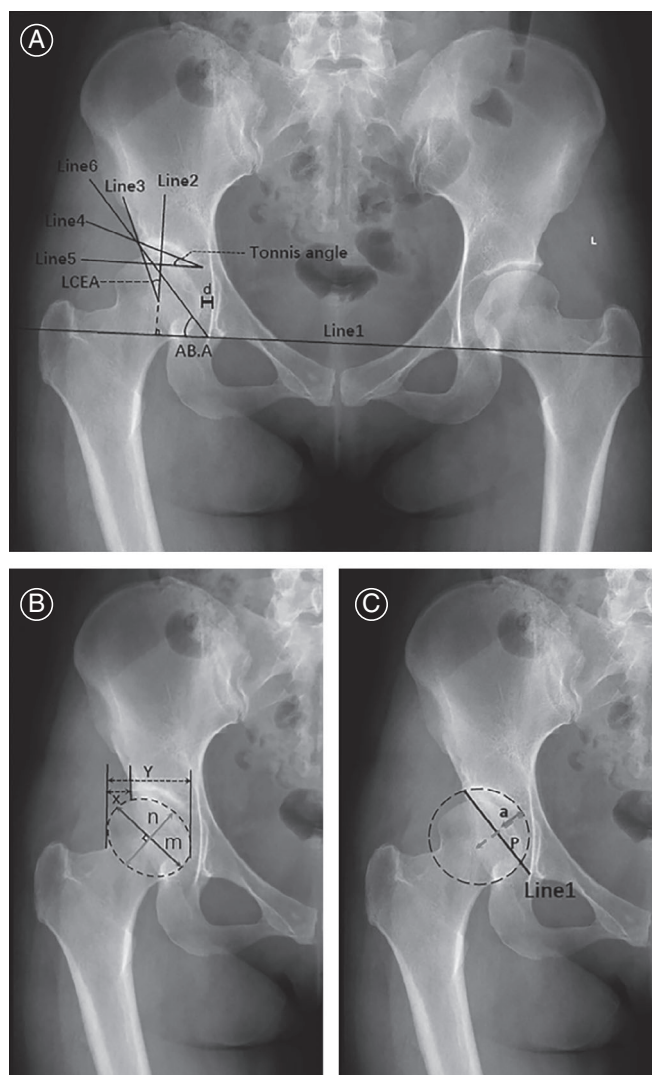
Acetabular top tilt angle is the angle formed between a line parallel to the weight-bearing surface of the acetabulum and a horizontal line. Acetabula having an acetabular top tilt angle of 0° to 10° were considered normal, whereas those having an angle of >10° or <0° were considered to have increased and decreased inclination, respectively. Acetabula with increased acetabular top tilt angle were subject to structural instability, whereas those with decreased acetabular top tilt angle were considered to be at risk for pincer-type femoroacetabular impingement<sup>11</sup>.

### Lateral Center Edge Angle (LCEA)

LCEA is formed by the line joining the center of the femoral head to the lateral edge of the acetabulum and a vertical line through the center of the head. LCEA was designed to assess lateral coverage of the femoral head. Wiberg reported values 25° and above as normal, values between 20° and 25° to be borderline, and values less than 20° are diagnostic of acetabular dysplasia<sup>14</sup>.

### Acetabular Abduction Angle (ABA)

ABA was measured by obtaining the angle between a line drawn from the acetabular teardrop to the lateral acetabular margin and a horizontal line between the teardrops. ABA is an imaging parameter that reflects the coverage of acetabulum to femoral head. Its normal range is 27° to 51°<sup>14,18</sup>. A



**Fig. 1** Measurement method. (A) Line 1 is the teardrop connection, Line 2 passes through the center of the femoral head and is perpendicular to Line 1, Line 3 is the connection between the center of the femoral head and the outermost point of the weight-bearing area of acetabular sclerosis, and the angle formed by Line 2 and Line 3 is the LCEA. Line 4 is the parallel line of the acetabular weight-bearing surface, Line 5 is parallel to Line 1, and the angle formed by Line 4 and Line 5 is the Tonnis angle. Line 6 is the line connecting the outer and lower edges of the acetabulum, the angle formed by Line 6 and Line 1 is the acetabular abduction angle, and d is the distance between the inner surface of the femoral head and the ilioischial line, which is used to assess the position of the hip joint center. (B) X is the length of the femoral head that is not covered by the acetabulum, Y is the transverse diameter of the femoral head, and  $EI = X/Y$  ratio. Femoral head sphericity index<sup>29</sup>: The ratio of the short axis (n) to the long axis (m) of the femoral head. (C) Line 1 is the connection line between the outer edge of the acetabulum and the anterior lower edge. The p/a ratio is calculated by dividing p (the distance from the acetabular joint surface to the edge of the posterior wall of the acetabulum) by a (the distance

normal ABA is very important to maintain the stability of hip joint. In patients with DDH, the ABA is too large and the acetabular cover to the femoral head is insufficient, so the joint is unstable. Thus, subluxation or dislocation occurs easily and osteoarthritis occurs prematurely.

#### **Extrusion Index (EI)**

The EI is the percentage of the femoral head that is not covered by the acetabulum. In normal hips, less than 25% of the femoral head is uncovered but values greater than 25% are often found in patients with acetabular dysplasia and can be much higher in patients with femoral head subluxation or dislocation<sup>19</sup>.

#### **Sphericity Index of Femoral Head**

The sphericity index of the femoral head is defined as the ratio of the short axis to the major axis of the femoral head, which reflects the spherical degree of the femoral head.

#### **Shenton Line**

Shenton line is a continuous line between the inner edge of the femoral neck and the upper edge of the obturator. The discontinuity of Shenton line indicates the existence of dislocation of the femoral head.

#### **Distance from the Innermost Surface of the Femoral Head to the Ilioischial Line**

The hip center can be classified as lateralized or not lateralized on the basis of the position of the medial aspect of the femoral head relative to the ilioischial line. The hip center was considered to be lateralized if the medial aspect of the femoral head was >10 mm from the ilioischial line, and not lateralized if the medial aspect of the femoral head was 10 mm or less from the ilioischial line. The hip center of a normal person should be not lateralized. The lateralized hip center will lead to poor joint congruency and abnormal stress distribution of hip joint.

#### **Osteoarthritis Tonnis Grade**

The degree of osteoarthritis present in each hip can be determined with use of the Tonnis classification system<sup>11</sup>. As defined by Tonnis, grades of osteoarthritis range from 0 to 3, with Grade 0 indicating no signs of osteoarthritis; Grade 1, increased sclerosis of the head and acetabulum, slight joint-space narrowing, and slight lipping at the joint margins; Grade 2, small cysts in the head or acetabulum,

from the acetabular joint surface to the edge of the anterior wall of the acetabulum), and both are measured on the vertical bisector of Line 1. When the vertical bisector of Line 1 is located in the acetabular fossa, the acetabular fossa is ignored. The acetabular articular surface is used as a part of the circle to make the best-fit circle, and the intersection of the trajectory of the circle and the vertical bisector of Line 1 is taken as the point of p and a near-point.



moderate joint space narrowing, and moderate loss of sphericity of the head; and Grade 3, large cysts in the head or acetabulum, joint space obliteration or severe joint space narrowing, severe deformity of the femoral head, or evidence of necrosis.

### **Joint Congruency**

Joint congruency was graded according to Yasunaga<sup>10</sup> as excellent if the radii of curvature of the acetabulum and the femoral head were identical and joint space was maintained, good if with curvature of femoral head and acetabulum not identical but with preserved joint space, fair if the joint space was partially narrowed, and poor if there was loss of joint space. Poor joint congruency is one of the important causes of early hip osteoarthritis<sup>10</sup>.

### **p/a Ratio and Corresponding Acetabular Anteversion Angle (AAA)**

AAA is a radiographic parameter that reflects the position of the acetabulum along the sagittal plane, the normal range is  $20^\circ \pm 5^\circ$ . Excessive AAA is an important cause of abnormal biomechanics of hip joint in patients with DDH. Using the method described by Koyama<sup>17</sup>, p/a ratio and corresponding acetabular anteversion angle can be measured on the anteroposterior pelvic radiograph.

### **Follow-Up and Assessment**

#### **Modified Harris Hip Score**

Patients' modified Harris hip scores (MHHS) were collected before surgery and at least 1 year after surgery. MHHS is a principal outcome measure used in the assessment of hip joint function<sup>5</sup>. The MHHS system mainly includes three aspects: pain, function, and functional activities. The score distribution is as follows: 44 points for the pain part, 33 points for the function part, 14 points for the functional activities part, and the total score of the MHHS is 91 points. The lighter the pain and the better the functional recovery, the higher the score. The surgery outcome of every patient was divided into three clinically relevant categories based on the results of MHHS: poor (<70 points), good (70–85 points), and excellent (86–91 points). The categories of MHHS were used as the outcome measure to explore factors affecting the efficacy of PAO<sup>12</sup>.

#### **WOMAC Scale Scores**

The WOMAC scale scores were collected prior to surgery and at the last follow-up after surgery. It was used to assess patients with hip osteoarthritis and the course of disease using 24 parameters<sup>12</sup>. For each parameter the full score is 4. The WOMAC scale included three subscales for pain, stiffness, and function. The three subscales included five, two, and 17 parameters respectively, with a total score of 20 points, 10 points, and 68 points. The more severe the pain and joint stiffness, the higher the score on the pain and stiffness subscales. The number of function subscale parameters

that the patient cannot complete is proportional to the score on the function subscale. The WOMAC scale was used as a supplement for the MHHS to assess surgery outcome of patients.

### **Statistical Methods**

A Kolmogorov–Smirnov test was used to test the normal distribution of quantitative variables, including patients' demographic data (age at surgery, follow-up time, body mass index [BMI]), radiographic parameters (the acetabular top tilt angle, LCEA, ABA, EI, sphericity index of femoral head, p/a ratio, AAA), and scores (MHHS, WOMAC scale scores) before and after surgery. Normally distributed measurement data were expressed as mean  $\pm$  standard deviation ( $\bar{X} \pm S$ ). The skew distribution measurement data were represented as median (interquartile range) [M(IQR)]. A paired t-test was performed to compare preoperative and postoperative radiographic quantity variables that followed a normal distribution. Skewed distribution radiographic quantitative variables used the Wilcoxon test. Categorical variables (Shenton line, Tonnis grade of osteoarthritis, joint congruency) were expressed as a percentage (%) and Fisher's exact test was used for preoperative and postoperative comparison. Patient demographic data (age at surgery, follow-up time, BMI, gender, side), as well as preoperative and postoperative radiographic parameters (the acetabular top tilt angle, LCEA, ABA, EI, sphericity index of femoral head, p/a ratio, AAA), were subjected to univariate logistic regression analysis. MHHS category was set as the dependent variable. If an independent variable had a *P* value <0.1 in single-factor logistic regression analysis, that variable was included in the multiple logistic regression analysis. If an independent variable with a *P* value <0.1 was a continuous variable, that independent variable was used as the test variable. MHHS category was also set as the state variable. The sensitivity was the ordinate, 1-specificity was the abscissa, the Receiver Operating Characteristic (ROC) curve was drawn, and the Yoden index was used to find the best cut-off value and set the sub-variable according to the best cut-off value of the continuous variable and then incorporate it into the multiple logistic regression analysis. Multivariate logistic regression analysis was used to determine which variables were the influencing factors of the functional score results, and *P* <0.05 was considered statistically significant. All the statistical analyses were performed with SPSS software for Windows (version 25.0; SPSS, New York, NY, USA).

## **Results**

### **Follow-Up**

Patients' MHHS and WOMAC scale scores were collected through on-site communication before surgery and at least 1 year after surgery. Due to the short postoperative time, only five cases were lost to follow-up and we excluded them. A final cohort of 44 patients was included in this study. The

average age was  $31.2 \pm 9.4$ . No cases of failed surgery were found. The average follow-up time was 18 months (ranging from 12 to 27 months). The general information of the patients is shown in Table 1.

### Radiographic Improvement

After operation, the radiographic parameters were significantly improved (Table 2, Fig. 2). LCEA increased (Preoperative:  $10.7 \pm 7.2$ ; Postoperative:  $34.8 \pm 7.1$ ,

$P < 0.001$ ), ABA (Preoperative:  $48.0 [6.8]$ ; Postoperative:  $38.0 [6.8]$ ,  $P < 0.001$ ), Tonnis angle (Preoperative:  $23 [5.8]$ ; Postoperative:  $9.5 [6.0]$ ,  $P < 0.001$ ), EI (Preoperative:  $28.4\% \pm 9.5\%$ ; Postoperative:  $10.5\% \pm 5.4\%$ ,  $P < 0.001$ ), p/a ratio decreased (Preoperative:  $2.3 [1.5]$ ; Postoperative:  $1.6 [0.6]$ ,  $P < 0.001$ ) and corresponding AAA (Preoperative:  $21.9 [14.6]$ ; Postoperative:  $15.3 [5.6]$ ,  $P < 0.001$ ) were all decreased, hip joint center shifted 2.3 mm medial ( $P < 0.001$ ). The Tonnis classification of postoperative hip osteoarthritis was improved (0 or 1 grade, Preoperative: 95.5%; Postoperative: 97.7%,  $P < 0.001$ ), and the joint congruency after operation was better than that before operation (excellent or good, Preoperative: 81.9%; Postoperative: 95.5%,  $P = 0.017$ ). All the differences were statistically significant.

### Functional Evaluation

#### Modified Harris Hip Score (MHHS)

The MHHS was significantly improved (Preoperative: 70.0 [29.0]; Postoperative: 91.0 [3.8],  $P < 0.001$ ) (Fig. 3, Table 3). Hip joint function improved, and excellent results rate reached 81.8%. A patient who underwent simultaneous intertrochanteric osteotomy achieving excellent results was defined according to the MHHS.

#### WOMAC Scale Scores

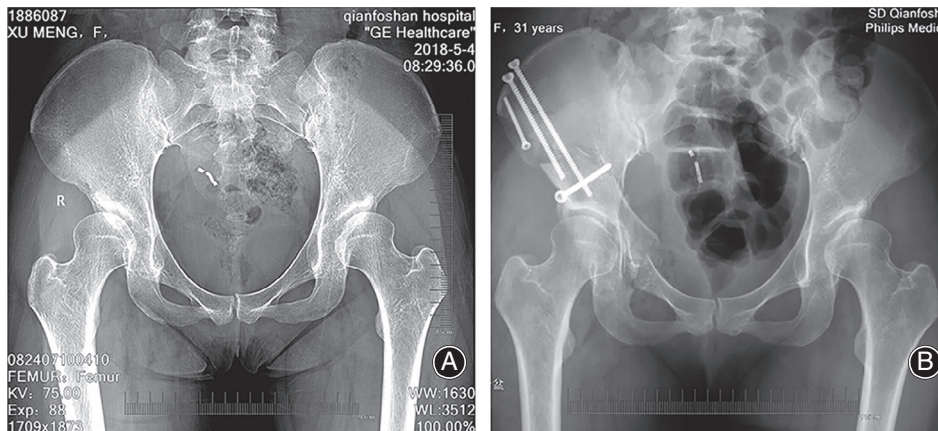
The WOMAC pain subscale score decreased (Preoperative: 4.0 [7.0]; Postoperative: 0 [0],  $P < 0.001$ ), and pain symptoms were alleviated. The WOMAC function subscale score decreased (Preoperative: 18.0 [4.0]; Postoperative: 4.0 [0],  $P$

**TABLE 1** General data parameters of patients

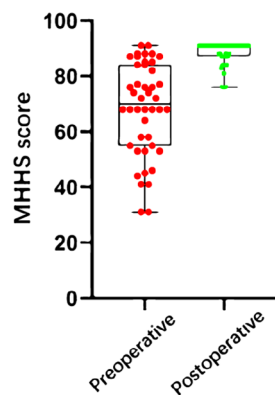
Demographic parameters	Value
Number of patients (hips)	44 (44)
Age at surgery ( $\bar{X} \pm S$ , years)	$31.2 \pm 9.4$ (12–49)
Follow-up time (M[IQR], years)	1.6 (1.4)
Gender (case [%])	
Male	4 (9.1)
Female	40 (90.9)
Side (case [%])	
Left	17 (38.6)
Right	27 (61.4)
BMI (M[IQR], Kg/m <sup>2</sup> )	22.8 (3.7)
Smoke (case [%])	3 (6.8)
Drink (case [%])	1 (2.3)
Femoral head sphericity index ( $\bar{X} \pm S$ )	$83.9\% \pm 7.2\%$ (7.06%–97.2%)
Prior hip trauma or surgery (case [%])	0 (0)
Combined intertrochanteric osteotomy (case [%])	1 (2.3)
BMI, body mass index.	

**TABLE 2** X-ray findings of patients before and after surgery

Radiographic parameters	Preoperative value	Postoperative value	P value
LCEA ( $\bar{X} \pm S$ , °)	$10.7 \pm 7.2$	$34.8 \pm 7.1$	<0.001
ABA (M[IQR], °)	48.0 (6.8)	38.0 (6.8)	<0.001
EI ( $\bar{X} \pm S$ )	$28.4\% \pm 9.5\%$	$10.5\% \pm 5.4\%$	<0.001
Tonnis grade			<0.001
Grade 0	22.8%	20.4%	
Grade 1	72.7%	77.3%	
Grade 2	4.5%	2.3%	
Grade 3	—	—	
Tonnis angle [M[IQR], °)	23 (5.8)	9.5 (6.0)	<0.001
p/a ratio (M[IQR])	2.3 (1.5)	1.6 (0.6)	<0.001
AAA (M[IQR], °)	21.9 (14.6)	15.3 (5.6)	<0.001
Shenton line			0.496
Continuous	68.2%	75%	
Discontinuous	31.8%	25%	
Joint congruency			0.017
Excellent	29.5%	81.9%	
Good	52.4%	13.6%	
General	13.6%	4.5%	
Poor	4.5%	0%	
Hip joint center position (M[IQR], mm)	10.8 (4.4)	8.5 (3.4)	<0.001
AAA, acetabular anteversion angle; ABA, acetabular abduction angle; EI, extrusion index; LCEA, lateral central edge angle.			



**Fig. 2** Preoperative and postoperative X-ray comparison. After operation, the radiographic parameters were significantly improved. ABA, Tonnis angle; EI, p/a ratio and corresponding AAA were all decreased. LCEA increased and hip joint center shifted medially. The Tonnis classification of postoperative hip osteoarthritis and the joint congruency were improved.



**Fig. 3** Comparison of preoperative and postoperative MHHS.

= 0.004) (Table 3), and the quality of daily life of the patients improved.

### Factors Influencing Postoperative MHHS

The general information of patients and the radiographic parameters before and after operation were screened by univariate logistic regression analysis. With the screening  $P$ -value set to 0.1, it was found that only preoperative LCEA ( $P = 0.073$ ) and postoperative Shenton line ( $P = 0.084$ ) had a significant correlation with the outcome variables. The ROC curve analysis was performed on the preoperative LCEA (Fig. 4), and an optimal cut-off value of  $4.5^\circ$  was found by the Youden index method. According to that cut-off value, patients were divided into two subgroups: the preoperative LCEA  $<4.5^\circ$  group and the preoperative LCEA  $\geq 4.5^\circ$  group. The postoperative Shenton line was included in the multiple logistic regression analysis. The results showed that only preoperative LCEA and higher MHHS were significantly statistically significant. According to the multiple logistic regression analysis, the probability of the postoperative MHHS of a hip joint with a preoperative lateral center edge angle  $\geq 4.5^\circ$  being classified as excellent is six times that of a hip joint with a preoperative lateral center edge angle  $<4.5^\circ$  (Exp[ $\beta$ ]: 6.249,

95% CI: 1.03–37.85,  $P = 0.046$ , Table 4). No statistical correlation was found between other imaging factors or demographic factors and a higher MHHS.

### Subgroup Analysis of Postoperative MHHS Influencing Factors

#### Age

According to age, the patients were divided into two groups:  $\leq 30$  years old group and  $>30$  years old group. The independent variables of the group  $\leq 30$  years old were screened by univariate analysis. The screening  $P$  value was set to 0.1, the only independent variable selected was preoperative EI ( $P = 0.057$ ), and preoperative EI had no significant effect on postoperative MHHS grade. The independent variables of the group  $>30$  years old were analyzed by the same method, and no statistically significant independent variables were selected.

#### Gender

The patients were divided into male and female groups. In the female group, the independent variables selected were preoperative LCEA ( $P = 0.077$ ) and postoperative Shenton line ( $P = 0.081$ ). The preoperative LCEA and postoperative Shenton line were included in multiple logistic regression analysis, and no significant statistical significance was found.

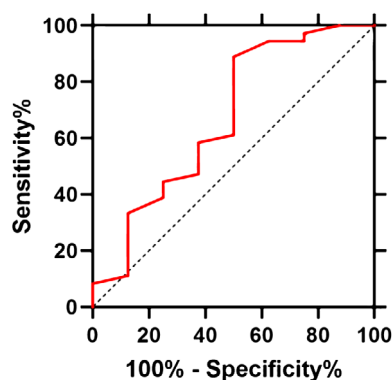
#### Follow-Up Time

According to follow-up time, the patients were divided into two groups: follow-up time  $\leq 2$  years group and follow-up time  $>2$  years group. In the group with follow-up time  $\leq 2$  years, the independent variables selected were as follows: preoperative Tonnis angle ( $P = 0.061$ ), postoperative Tonnis angle ( $P = 0.089$ ), preoperative EI ( $P = 0.056$ ). The above variables were included in multiple logistic regression analysis, there was no significant difference between the above variables and MHHS grade. In the group of follow-up time  $>2$  years, the only independent variable selected was the sphericity index of femoral head ( $P = 0.090$ ), that is, the

**TABLE 3** Comparison of clinical results of hip joint before and after surgery

Score	Preoperative value	Postoperative value	P value
MHHS (M[IQR], score)	70.0 (29.0)	91.0 (3.8)	<0.001
WOMAC (M[IQR], score)			
Pain	4.0 (7.0)	0 (0)	<0.001
Stiffness	0 (0)	0 (0)	<0.001
Physical function	18.0 (4.0)	4.0 (0)	0.004

MHHS, modified Harris hip score; WOMAC, Western Ontario and McMaster Universities Osteoarthritis Index.

**Fig. 4** ROC curve of preoperative LCEA.**TABLE 4** Results of multiple logistic regression analysis

Variables	P value	Exp(B)	95% CI
LCEA <4.5°/LCEA ≥4.5°	0.046	6.249	1.032–37.854
Postoperative Shenton line	0.300	0.444	0.061–2.037

LCEA, lateral central edge angle.

sphericity index of femoral head had no significant effect on the MHHS grade.

### Osteoarthritis Tonnis Grade

The independent variables selected from the group with Tonnis grade 1 were preoperative LCEA ( $P = 0.008$ ) and preoperative AAA ( $P = 0.026$ ). When the variables were included in multiple logistic regression analysis, it was found that only preoperative LCEA and MHHS grade had significant statistical significance. According to the multiple logistic regression analysis, for every additional unit of preoperative LCEA, the probability of the postoperative MHHS being classified as excellent was 1.2 times higher than that of the original ( $\text{Exp}[\beta]: 1.201$ , 95% CI: 1.050–1.374,  $P = 0.008$ ). No statistically significant independent variables were selected in the group with Tonnis grade 0.

### Joint Congruency

The independent variables selected from the good joint congruency group were preoperative Tonnis angle ( $P = 0.052$ ), preoperative AAA ( $P = 0.089$ ), and preoperative hip joint center position ( $P = 0.085$ ). When the above variables were included in multiple logistic regression analysis, no significant statistical significance was found between the variables and MHHS grade. No statistically significant independent variables were screened out in the excellent joint congruency group.

### Shenton Line

Shenton line divided the patients into two groups: continuous Shenton line group and discontinuous Shenton line group. No statistically significant independent variables were screened out in the continuous Shenton line group. The only independent variable of the discontinuous Shenton line group screened out was preoperative AAA ( $P = 0.070$ ), that is, preoperative AAA had no significant effect on MHHS grade.

### Complications

Six patients had sensory disturbance of the lateral femoral cutaneous nerve, manifesting as numbness in the anterolateral area of the thigh, four of which recovered completely during follow-up. A lateral femoral cutaneous nerve injury is very common in PAO, but this is a purely sensory nerve. This kind of nerve injury has no significant effect on the function of hip joint and the effect of PAO operation, so it does not need special treatment<sup>20</sup>. No other complications related to the surgical approach, osteotomy, acetabular displacement, acetabular fixation, and postoperative stage were found. There were also no significant vascular and nerve injuries nor visceral injuries found in any of the patients.

### Discussion

#### Radiographic and Functional Improvement After PAO

Compared with other hip-preserving surgeries for patients with DDH, PAO can achieve the ideal positioning of the hip joint rotation center and maintain the inherent stability of the combination of acetabular fragments and residual pelvis,



allowing early postoperative weight bearing<sup>21,22</sup>. PAO can effectively resolve both biomechanical and structural abnormalities of the hip joint in patients with DDH, maintain or improve the patient's mobility and quality of life, and delay or prevent the occurrence of secondary osteoarthritis<sup>13,14,23</sup>. This study demonstrated that the overall functional scores of patients after PAO were significantly improved, pain symptoms were significantly reduced, and postoperative radiographic parameters were significantly improved compared with those performed before the operation, which is consistent with the conclusions of other studies<sup>5,12,18</sup>. Since PAO through an iliac-inguinal approach requires a wealth of experience as there are more pelvic vascular nerve plexuses, a higher risk for severe intraoperative bleeding, and high incidence of nerve damage, the MSP approach, which has a clear anatomical structure and less damage to blood vessels and nerves, less intraoperative bleeding, and the ability to treat intra-articular lesions at the same time, is preferable<sup>24,25</sup>. Therefore, we switched to the MSP approach. Considering that different surgical approaches may have an impact on postoperative function, to facilitate comparison, only patients who underwent the MSP approach were included in the study.

#### **Influencing Factors of Function After PAO**

This study found that the functional score and pain levels of patients after PAO were significantly improved. There was a direct correlation between a larger preoperative LCEA and better hip function after surgery. Especially in DDH patients with osteoarthritis Tonnis grade 1, the effect of preoperative LCEA on postoperative MHHS grade is more obvious. No other demographic or imaging factors were found to be associated with improved postoperative function scores. Although the number of reports regarding postoperative function in PAO is gradually increasing, the results regarding factors that affect postoperative function are still inconclusive. Albers<sup>26</sup> followed up patients after PAO for more than 10 years and proved that LCEA  $<22^\circ$  after PAO was an independent risk factor for PAO surgery failure. Based on this conclusion, Novais *et al.*<sup>12</sup> studied factors influencing a postoperative LCEA of  $<22^\circ$  after PAO. The results showed that among demographic factors and various preoperative imaging parameters, including age, gender, BMI, and severity of acetabular dysplasia, preoperative LCEA was the only independent factor related to postoperative LCEA  $<22^\circ$ . This indicates that developmental hip dysplasia with small preoperative LCEA is more likely to be under-corrected, which leads to failure of the operation. However, there is a lack of relevant reports on the relationship between preoperative LCEA and a patient's postoperative clinical function. To a certain extent, this study explains the correlation between preoperative LCEA and the patient's PAO postoperative function, showing that patients with preoperative LCEA  $\geq 4.5^\circ$  have better postoperative function. This phenomenon may be related to the

size and position of the contact stress area of the hip joint. A study conducted by Kralj<sup>27</sup> *et al.* proved that the peak contact stress of the hip joint was related to prognosis post-PAO. The contact stress area of the hip joint in DDH patients increases sharply toward the lateral edge, and an increase in LCEA can improve the lateral coverage of the femoral head, reduce the size of the hip joint contact stress, and change the location of the peak contact stress. This better biomechanical status of a hip joint with LCEA  $\geq 4.5^\circ$  before surgery may be the main reason for better postoperative function.

Through univariate analysis, we found that after surgery the Shenton line may be one of the factors that affect function; however, there was no statistical significance in the regression analysis, which may be due to our small sample size. The study conducted by Fujii *et al.*<sup>28</sup> showed that the Shenton line was not a factor influencing the degree of intra-articular lesions in patients with severe DDH. Therefore, further research is needed to clarify the relationship between the Shenton line and postoperative function.

Previous studies have shown that the Tonnis classification of osteoarthritis is one of the imaging indicators that affects postoperative function<sup>29</sup>. Patients with no arthritis or only mild arthritis before surgery have better postoperative function<sup>30</sup>. Beaulé *et al.*<sup>30</sup> found that a larger  $\alpha$  angle ( $>50.5^\circ$ ) before surgery indicates a lower postoperative WOMAC function score. In addition, Petrie<sup>6</sup> found that a previous history of surgery involving the ipsilateral hip was a predictor of postoperative UCLA score changes. Since there were only two patients whose osteoarthritis Tonnis grade was Grade 2 before the operation in our study and our follow-up time was short, the degree of osteoarthritis did not progress significantly, and therefore we could not observe if the functional score was correlated with the Tonnis grade of osteoarthritis. All the patients had no previous history of surgery of the hip joint on the operative side and, therefore, we could not verify this factor. Further, most patients lacked the Dunn position X-ray required to measure the  $\alpha$  angle, so we did not consider the  $\alpha$  angle as a variable.

#### **Limitations of the Study**

This study had certain limitations. First, our sample size was small. Second, our study was a retrospective case study. This type of study inherently has various sources of bias, including selection bias, measurement and evaluation bias<sup>31</sup>, as well as loss to follow-up. Finally, this was a short-term follow-up study, and it did not provide medium- to long-term follow-up results. Based on the level of evidence provided by existing studies, many factors that affect the effectiveness of PAO were not fully understood. Finding out the factors through a large sample of prospective randomized studies will provide reference for the development and improvement of this surgical technique.

**Conclusion**

Overall functional scores post-PAO significantly improved and pain symptoms were significantly reduced. In addition,

patients with preoperative LCEA  $\geq 4.5^\circ$  had better clinical function after surgery.

**References**

1. Chen M, Shang XF. Surgical treatment for young adult hip dysplasia: joint-preserving options. *Int Orthop*, 2016, 40: 891–900.
2. Hernandez PA, Wells J, Usheva E, et al. Early-onset osteoarthritis originates at the chondrocyte level in hip dysplasia. *Sci Rep*, 2020, 10: 627.
3. Schmitz MR, Murtha AS, Clohisy JC, Group AS. Developmental dysplasia of the hip in adolescents and young adults. *J Am Acad Orthop Surg*, 2020, 28: 91–101.
4. Okoroafor UC, Pascual-Garrido C, Schwabe MT, Nepple JJ, Schoenecker PL, Clohisy JC. Activity level maintenance at midterm follow-up among active patients undergoing periacetabular osteotomy. *Am J Sports Med*, 2019, 47: 3455–3459.
5. Larsen JB, Mechlenburg I, Jakobsen SS, Thilleman TM, Søballe K. 14-year hip survivorship after periacetabular osteotomy: a follow-up study on 1,385 hips. *Acta Orthop*, 2020, 91: 299–305.
6. Petrie JR, Novais EN, An TW, Clohisy J. What is the impact of Periacetabular osteotomy surgery on patient function and activity levels?. *J Arthroplasty*, 2020, 35: S113–S118.
7. Stambough JB, Clohisy JC, Baca GR, et al. Does previous pelvic osteotomy compromise the results of periacetabular osteotomy surgery? *Clin Orthop Relat Res*, 2015, 473: 1417–1424.
8. Heyworth BE, Novais EN, Murray K, et al. Return to play after periacetabular osteotomy for treatment of acetabular dysplasia in adolescent and young adult athletes. *Am J Sports Med*, 2016, 44: 1573–1581.
9. Grammatopoulos G, Wales J, Kothari A, Gill HS, Wainwright A, Theologis T. What is the early/mid-term survivorship and functional outcome after Bernese Periacetabular osteotomy in a pediatric surgeon practice?. *Clin Orthop Relat Res*, 2016, 474: 1216–1223.
10. Wells J, Millis M, Kim YJ, Bulat E, Miller P, Matheny T. Survivorship of the Bernese Periacetabular osteotomy: what factors are associated with long-term failure?. *Clin Orthop Relat Res*, 2017, 475: 396–405.
11. Matheny T, Kim YJ, Zurakowski D, Matero C, Millis M. Intermediate to long-term results following the bernese periacetabular osteotomy and predictors of clinical outcome: surgical technique. *J Bone Joint Surg Am*, 2010, 92: 115–129.
12. Novais EN, Duncan S, Nepple J, Pashos G, Schoenecker PL, Clohisy JC. Do radiographic parameters of dysplasia improve to normal ranges after Bernese Periacetabular osteotomy?. *Clin Orthop Relat Res*, 2017, 475: 1120–1127.
13. Thomas-Aitken HD, Goetz JE, Dibbern KN, Westermann RW, Willey MC, Brown TS. Patient age and hip morphology alter joint mechanics in computational models of patients with hip dysplasia. *Clin Orthop Relat Res*, 2019, 477: 1235–1245.
14. Gaffney BMM, Clohisy JC, van Dillen LR, Harris MD. The association between periacetabular osteotomy reorientation and hip joint reaction forces in two subgroups of acetabular dysplasia. *J Biomech*, 2020, 98: 109464.
15. Clohisy JC, Carlisle JC, Beaulé PE, et al. A systematic approach to the plain radiographic evaluation of the young adult hip. *J Bone Joint Surg Am*, 2008, 90: 47–66.
16. Wells J, Schoenecker P, Duncan S, Goss CW, Thomason K, Clohisy JC. Intermediate-term hip survivorship and patient-reported outcomes of Periacetabular osteotomy: the Washington university experience. *J Bone Joint Surg Am*, 2018, 100: 218–225.
17. Koyama H, Hoshino H, Suzuki D, Nishikino S, Matsuyama Y. New radiographic index for evaluating acetabular version. *Clin Orthop Relat Res*, 2013, 471: 1632–1638.
18. Stem ES, O'Connor MI, Kransdorf MJ, Crook J. Computed tomography analysis of acetabular anteversion and abduction. *Skeletal Radiol*, 2006, 35: 385–389.
19. Li PL, Ganz R. Morphologic features of congenital acetabular dysplasia: one in six is retroverted. *Clin Orthop Relat Res*, 2003, 416: 245–253.
20. Yang J, Zhang Z, Cheng H, Xiao K, Luo D, Zhang H. Sciatic and femoral nerve injury among patients who received Bernese peri-acetabular osteotomy. *Int Orthop*, 2019, 43: 573–577.
21. Abraham CL, Knight SJ, Peters CL, Weiss JA, Anderson AE. Patient-specific chondrolabral contact mechanics in patients with acetabular dysplasia following treatment with peri-acetabular osteotomy. *Osteoarthritis Cartil*, 2017, 25: 676–684.
22. Luo DZ, Zhang H, Xiao K, Cheng H, Zhang H. Efficiency and accuracy of Bernese Periacetabular osteotomy for adult hip dysplasia. *Orthop Surg*, 2015, 7: 375–377.
23. Wyles CC, Stutz JM, Hevesi M, Chalmers BP, Sierra RJ, Trousdale RT. Incidence and risk factors for hardware removal following periacetabular osteotomy and its association with clinical outcomes. *Hip Int*, 2021, 31: 410–416.
24. Luo D, Zhang H, Zhang W. Comparison of three approaches of Bernese periacetabular osteotomy. *Ther Clin Risk Manag*, 2016, 12: 67–72.
25. Shang JJ, Zhang ZD, Luo DZ, Cheng H, Zhang H. Effectiveness of multi-modal blood management in Bernese periacetabular osteotomy and periacetabular osteotomy with proximal femoral osteotomy. *Orthop Surg*, 2020, 12: 1748–1752.
26. Albers CE, Steppacher SD, Ganz R, Tannast M, Siebenrock KA. Impingement adversely affects 10-year survivorship after periacetabular osteotomy for DDH. *Clin Orthop Relat Res*, 2013, 471: 1602–1614.
27. Kraji M, Mavcic B, Antolic V, Igljic A, Kraji-Igljic V. The Bernese periacetabular osteotomy: clinical, radiographic and mechanical 7-15-year follow-up of 26 hips. *Acta Orthop*, 2005, 76: 833–840.
28. Fujii M, Nakashima Y, Noguchi Y, et al. Factors associated with severity of intra-articular lesions in patients with severe hip dysplasia. *Art Ther*, 2016, 32: 1581–1589.
29. Yu D, Zhai Z, Zhang J, et al. Optimal level of femoral neck for predicting postoperative stem anteversion in total hip arthroplasty for Crowe type I dysplastic hip. *Orthop Surg*, 2020, 12: 480–487.
30. Beaulé PE, Dowding C, Parker G, Ryu JJ. What factors predict improvements in outcomes scores and reoperations after the Bernese periacetabular osteotomy?. *Clin Orthop Relat Res*, 2015, 473: 615–622.
31. Yang GY, Li YY, Luo DZ, Hui C, Xiao K, Zhang H. Differences of anteroposterior pelvic radiographs between supine position and standing position in patients with developmental dysplasia of the hip. *Orthop Surg*, 2019, 11: 1142–1148.