

Open-Wedge Valgus High Tibial Osteotomy Technique With Inverted L-Shaped Configuration



Juan C. Monllau, M.D., Ph.D., Juan I. Erquicia, M.D., Federico Ibañez, M.D., Maximiliano Ibañez, M.D., Pablo E. Gelber, M.D., Ph.D., Angel Masferrer-Pino, M.D., and Xavier Pelfort, M.D., Ph.D.

Abstract: High tibial osteotomy (HTO) is a useful alternative in the treatment of symptomatic varus malalignment. However, among its drawbacks is the tendency to decrease patellar height and increase the posterior tibial slope. The increased tibial slope increases anterior cruciate ligament tension and may compromise its function. On the other hand, patella baja often causes anterior knee pain and, over time, may favor degeneration of the patellofemoral joint. The aim of this study is to describe a technical modification of the standard open-wedge HTO. It consists of a double inverted L-shaped cut, which includes the anterior tibial tuberosity in the proximal fragment, to avoid any alteration of patellar height and control the eventual increase of the posterior tibial slope.

High tibial osteotomy (HTO) is usually performed as an effective surgical intervention for patients with medial knee osteoarthritis and varus malalignment. The procedure aims to realign the lower limb to redistribute

the weight-bearing load from the damaged medial compartment to the relatively unaffected lateral compartment of the knee.^{1,2} This technique has several advantages over the lateral closing-wedge HTO. One of them is to avoid carrying out a fibular osteotomy and, likewise, the associated risk of peroneal nerve complications.^{3,4} Several authors have reported superior clinical outcomes of the traditional supratubercular open-wedge HTO (OWHTO) over the infratubercular OWHTO because of the lower non-union rates.^{5,6} However, a supratubercular OWHTO leads to a decrease in patellar height and tends to increase the sagittal tibial slope.⁷ Some authors have recently advocated for the use of a standard infratubercular HTO in cases of patella infera with the aim to widen the indications for OWHTO.⁸

The aim of this work is to describe a technical modification of the standard OWHTO, consisting of a double inverted L-shaped cut (L-OWHTO). It includes the anterior tibial tuberosity in the proximal fragment and is designed for cases with a patella with a height that may lead to a low postoperative patella. Additionally, the described order of osteotomy fixation contributes to better control of the postoperative tibial slope.

Preoperative Study

- Full-weight-bearing long-leg standing anteroposterior radiographs were done to determine the angle of the extremity and the desired degree of correction (Fig 1). A postoperative anatomic

From the Department of Orthopaedic Surgery, Hospital del Mar (J.C.M.), ICATME, Hospital Universitari Dexeus (J.C.M., J.I.E., F.I., M.I., P.E.G., A.M-P., X.P.), and Department of Orthopaedic Surgery, Hospital de la Sta Creu i Sant Pau (P.E.G.), Universitat Autònoma de Barcelona, Barcelona; and Department of Orthopaedic Surgery, Consorci Sanitari de l'Anoia (X.P.), Igualada, Spain.

The authors report the following potential conflicts of interest or sources of funding: J.C.M. receives board membership fees from European Society of Sports Traumatology, Knee Surgery, and Arthroscopy (ESSKA); is a paid consultant for ConMed Linvatec, Smith & Nephew, and Surgival; has provided expert testimony for Bioiberica; has grants/grants pending from Spanish Arthroscopy Association, Spanish Ministry of Health, Social Service and Equality; receives payment for lectures including service on speakers bureaus from ConMed Linvatec, Smith & Nephew, and Surgival; and receives payment for development of educational presentations ConMed Linvatec, Smith & Nephew, and Surgival. P.E.G. receives institutional support from the Spanish Arthroscopic Association, is a paid consultant for Conmed, and is an employee of Hospital Sant Pau, Barcelona, Spain. Full ICMJE author disclosure forms are available for this article online, as [supplementary material](#).

Received March 30, 2017; accepted August 7, 2017.

Address correspondence to Juan C. Monllau, M.D., Ph.D., Department of Orthopedic Surgery and Traumatology, Hospital del Mar, Universitat Autònoma de Barcelona, Passeig Marítim, 25, 08003 Barcelona, Spain. E-mail: jmonllau@parcdesalutmar.cat

© 2017 by the Arthroscopy Association of North America. Published by Elsevier. This is an open access article under the CC BY-NC-ND license (<http://creativecommons.org/licenses/by-nc-nd/4.0/>).

2212-6287/17445

<http://dx.doi.org/10.1016/j.eats.2017.08.009>

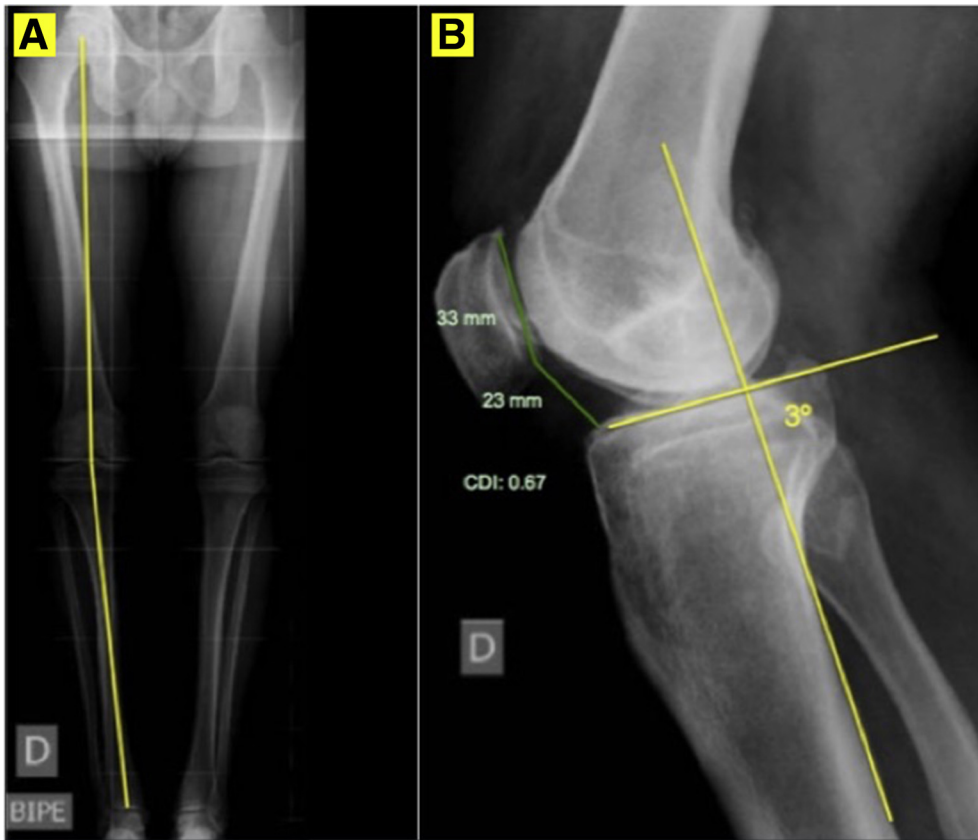


Fig 1. (A) Full-weight-bearing long-leg standing anteroposterior radiographs. (B) Measurement of the Caton-Deschamps index (CDI) and the posterior tibial slope (TS).

femoral-tibial axis of 5° to 8° valgus and a mechanical axis around the Fujisawa point was the goal.⁹

- The Schuss or Rosenberg radiographic view¹⁰ was used to evaluate the joint line space.
- A lateral non-weight-bearing radiography of the knee at 30° of flexion was used to measure the posterior tibial slope as well as the patellar height. The

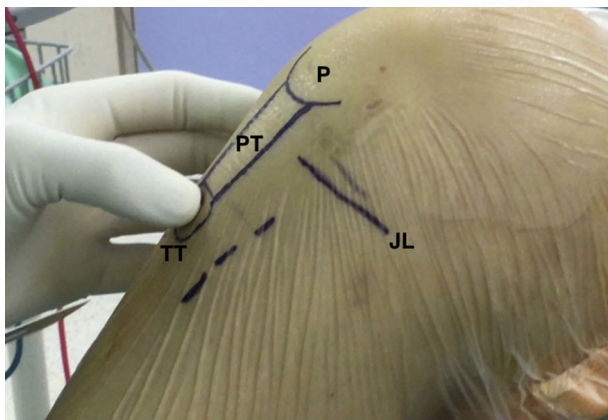


Fig 2. Right knee, medial view image showing patient positioning on the operating table. Longitudinal approach midway between the anterior tibial tuberosity and the posteromedial border of the tibia. (JL, joint line; P, patella; PT, patellar tendon.)

posterior tibial slope was determined by the angle between a line passing through the posterior cortex of the tibia and tangent to the tibial plateau (parallel to the joint slope).¹¹ The patellar height was calculated with the Caton-Deschamps index (CDI) (Fig 1).

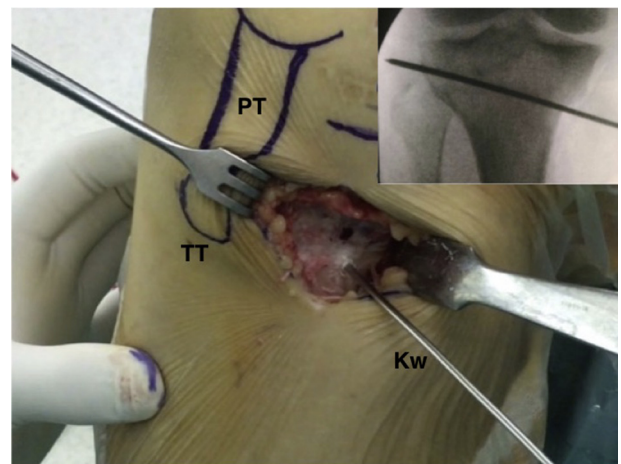


Fig 3. Fluoroscopic control imaging. Right knee, medial view. A 2.4-mm Kirschner guidewire is placed in the medial cortex of the tibia, aimed toward the tip of the fibular head in a proximal and posterolateral direction. To avoid peroneal nerve injury during this step, the tip of the K-guidewire should end 1 cm of the lateral tibial cortex.

Fig 4. (A) Right knee, medial view. The proposed biplane HTO. The horizontal cut (H) is similar to the standard cut. The vertical cut (V) of the osteotomy runs posterior to the anterior tibial tuberosity. (B) View of the 3 cuts taken from the medial side of the joint. (HTO, high tibial osteotomy.)

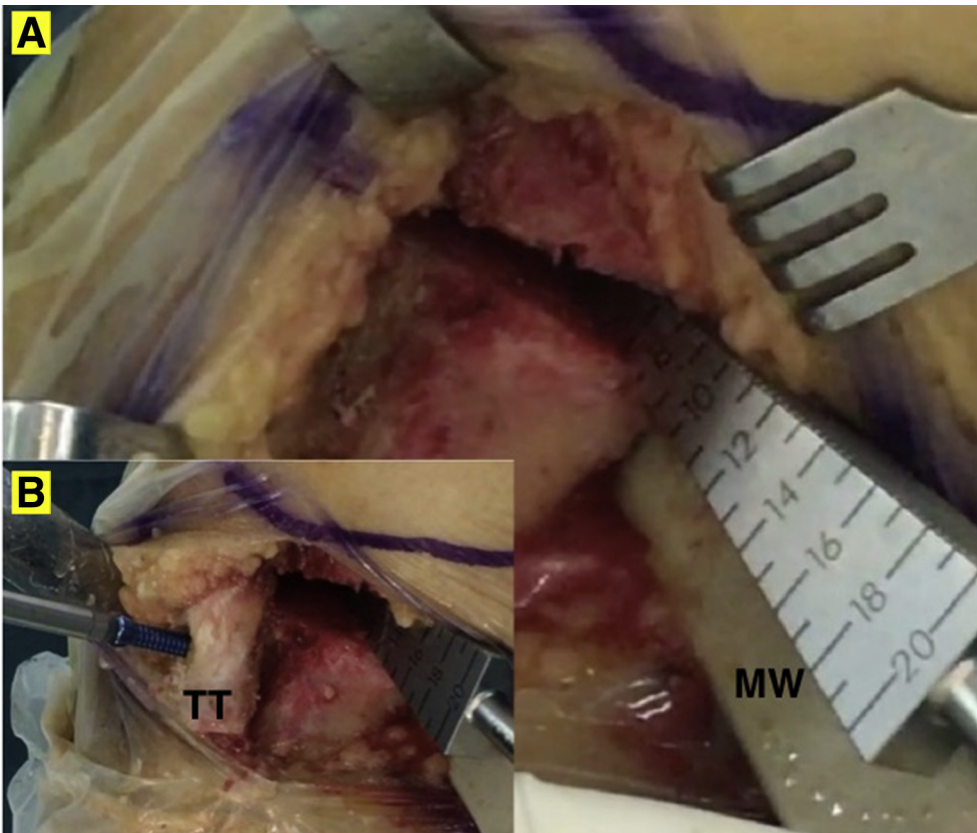
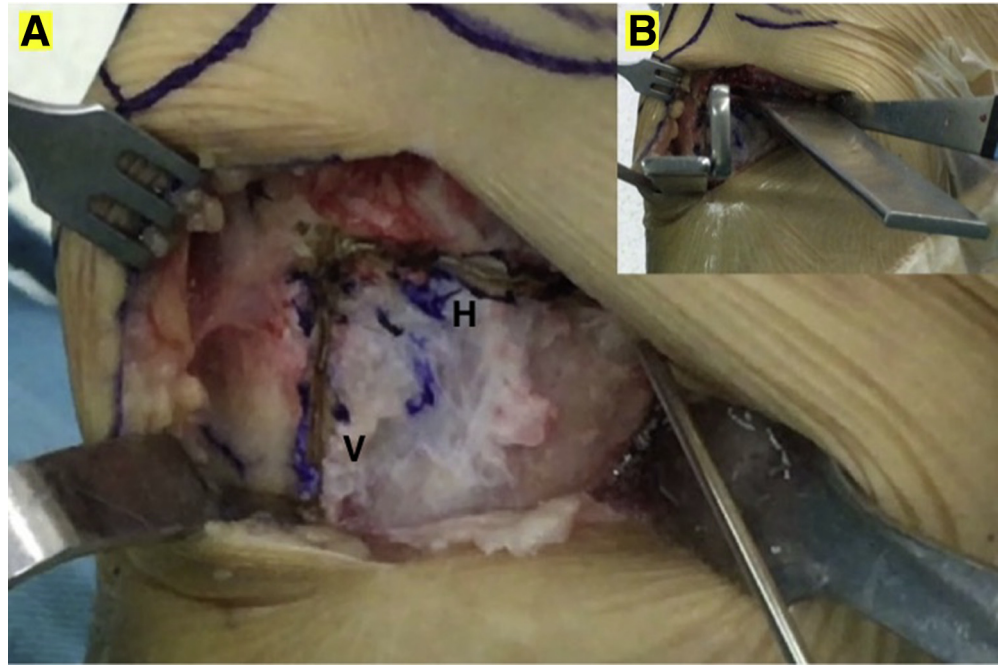


Fig 5. (A) Right knee, medial view. Correction is achieved using a metallic wedge that is introduced in the most posterior part of the osteotomy site. That creates a trapezoidal gap minimizing the risk of any tibial slope increment. (B) Anteroposterior cortical screw fixing the TT. This screw fixation prevents anterior tilting of the TT, which might lead to an increase of the posterior tibial slope. (TT, tibial tuberosity.)

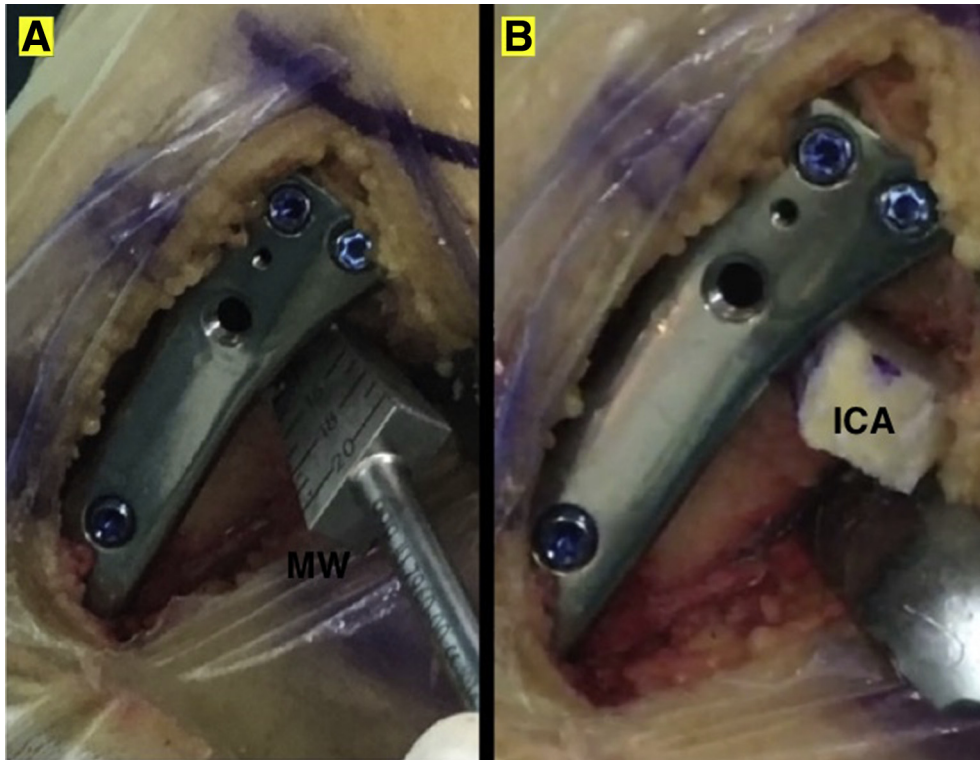


Fig 6. (A) Right knee, medial view. Locking LOQTEQ HTO plate. (B) Osteotomy gap filled with tricortical iliac bone crest allograft (ICA).

Based on this parameter, the indication for L-OWHTO was seen when the CDI was less than 1. In cases in which the CDI was between 1 and 1.2 but with a planned correction greater than 10° , the authors also chose the same technique.

Surgical Technique

The patient was positioned supine on the operating table with the knee at 90° of flexion, using a distal foot support and a lateral support for the thigh. Once an arthroscopic evaluation of the knee was done, a 6- to 7-cm longitudinal approach midway between the tibial tuberosity (TT) and the posteromedial border of the tibia was performed (Fig 2). The semitendinosus and gracilis tendons were released as was the distal insertion of the superficial medial collateral ligament. A Hohmann retractor was placed between the superficial medial collateral ligament and the posterior cortex of the tibia. The patellar tendon was identified and protected with a retractor.

Osteotomy

The L-OWHTO has 2 osteotomy planes. Whereas the horizontal cut is similar to the standard OWHTO, the vertical part of the osteotomy runs posterior to the anterior tibial tubercle. Under fluoroscopic control, a 2.4-mm Kirschner guidewire was placed in the medial cortex of the tibia at the metaphyseal-diaphyseal

transition zone aimed toward the tip of the fibular head in a proximal and posterolateral direction (Fig 3). To avoid peroneal nerve injury during this step, the tip of the K-guidewire should end at 1 cm of the lateral tibial cortex. The desired vertical section of the inverted L-osteotomy was marked with electrocautery and subsequently performed. The K-wire guided the sagittal cut performed in the posterior two-thirds of the tibia. Maintaining perfect perpendicularity to the main axis of the bone on the sagittal plane is crucial to preventing tibial slope modifications. This section of the osteotomy should end 1 to 2 cm medial to the lateral tibial cortex. The use of a calibrated saw and osteotome allows for reducing the use of an image intensifier and thus the dose of radiation.

The second section of the osteotomy was vertical on the coronal plane and it extended 3 to 4 cm distally, thereby keeping the TT together with the proximal segment of the osteotomized tibia. The TT fragment should maintain a thickness of about 10 mm in the most proximal part to minimize the risk of fracture (Fig 4). The desired correction was achieved using a metallic wedge introduced into the most posterior part of the osteotomy site. That created a trapezoidal gap that minimized the risk of any tibial slope increment (Fig 5). The one or two 3.5-mm anteroposterior cortical screws fixing the TT were secured before the osteotomy plate was put in place. This screw fixation prevents the

Table 1. Step-by Step Open-Wedge Valgus High Tibial Osteotomy With Inverted L-Shaped Configuration Technique

Step	Description
1	The patient is positioned supine at the operative table, with 90° knee flexion, using a distal foot support and a lateral support for the thigh.
2	A 6- to 7-cm longitudinal approach midway between the tibial tuberosity (TT) and the posteromedial border of the tibia was performed.
3	The semitendinosus and gracilis tendons are released as well as the distal insertion of the superficial medial collateral ligament is performed. The patellar tendon is identified and protected with a retractor.
4	Under fluoroscopic control, a 2.4-mm guiding Kirschner wire (K-wire) is placed in the medial cortex of the tibia at the metaphyseal-diaphyseal transition zone, aiming to the tip of the fibular head in a proximal and posterolateral direction.
5	The K-wire guided the sagittal cut performed in the posterior two-thirds of the tibia. This section of the osteotomy ended 1-2 cm medial to the lateral tibial cortex.
6	The second section of the osteotomy is vertical in the coronal plane, and it extends 3-4 cm distally, thereby maintaining the TT together with the proximal segment of the osteotomized tibia.
7	The desired correction is achieved using a metallic wedge introduced in the most posterior part of the osteotomy site, thereby creating a trapezoidal gap.
8	One or 2 anteroposterior 3.5-mm cortical screws fixing the TT is/are secured before the osteotomy plate is placed.
9	Then, the locking LOQTEQ HTO plate is accordingly fixed. This plate allows a fixation of the proximal segment of the osteotomy with 4 angular stability screws of 4.5 mm and 3 more in the distal fragment.
10	The osteotomy gap was filled with tricortical iliac crest allograft.

HTO, high tibial osteotomy.

anterior tilting of the TT that leads to an increase of the posterior tibial slope. Then, the locking LOQTEQ HTO plate (Aap Implantate AG, Berlin, Germany) was accordingly fixed. This plate allows for fixation of the proximal segment of the osteotomy with four 4.5-mm angular stability screws and 3 more in the distal fragment. To achieve correct adaptation of the plate to bone, the use of a 4.5-mm cortical screw in the first of the 3 distal holes is recommended. Once adapted to the tibia, the rest of the distal fixation can also be carried out with angular stability screws.

Once the fixation was finished, the opening wedge was removed. The osteotomy gap was then filled with tricortical iliac crest allograft (Fig 6). A step-by-step summary of this technique is provided in Table 1.

After the posterior Hohmann retractor was removed, the medial collateral ligament covered the osteotomy plate. Then, the semitendinosus and gracilis tendons were repaired. Suction drainage was used on the plane

of the osteotomy to minimize the risk of hematoma. Pearls and pitfalls to performing this surgical procedure are listed in Table 2.

Rehabilitation Protocol

Patients should start continuous passive motion of the knee as well as isometric quadriceps-strengthening exercises immediately after surgery. During the first 3 weeks, toe-touch partial weight bearing is allowed. Progress to full weight bearing can be achieved over 3 to 6 weeks as tolerated (Video 1).

Discussion

Traditional OWHTO techniques cause distalization and lateralization of the TT, resulting in a decrease of patellar height as suggested by Goutallier et al.¹² using a mathematical model. In a recent study, Amzallag et al.¹³ showed that patellar height decreased more than 20% in one-third of patients after an OWHTO. With the L-OWHTO technique, the tibial tuberosity remains attached to the proximal fragment of the osteotomy. Subsequently, the patellar height remained unchanged. Gaasbeek et al.,¹⁴ in a study with 17 patients, showed the results of an OWHTO preserving the TT attached to the proximal tibia and fixing the TT with an anteroposterior screw. However, those authors did so after the osteotomy plate was fixed. Thus, this anteroposterior screw could not have prevented any eventual anterior tilting of the proximal fragment. It is likely that the different sequencing of the osteotomy's fixation provides better contact between the tibial tuberosity and the distal tibial fragment.

Standard OWHTO is contraindicated in patients with patella baja or infera. The CDI defines patella baja as those between 0.6 and 0.8. Those below 0.6 are considered patella infera. In a retrospective Level IV study of patients who had undergone an OWHTO, El-Amrani et al.¹⁵ observed that the worse functional results were associated with postoperative patella infera. They observed that patellar height decreased by 10% to 15% after an OWHTO, but without correlation to the degree of axial correction. Gaasbeek et al.¹⁴ also found a significant reduction in the CDI after an OWHTO.

Several studies have shown that HTO might result in tibial slope changes. In general, the posterior tibial slope increases after open-wedge high tibial osteotomies and decreases after the closed-wedge type.¹⁶ The increase in tibial slope may result in a correction loss on the frontal plane¹⁷ and could alter in situ cruciate ligament forces and influence knee stability and kinematics.^{16,18-20} Changes to the tibial slope might also accelerate the process of joint degeneration

Table 2. Pearls, Pitfalls, and Risks

Pearls

- Double inverted L-shaped open-wedge HTO has 2 osteotomy planes. Whereas the horizontal cut is similar to the standard open-wedge HTO, the vertical part of the osteotomy runs posterior to the anterior tibial tubercle.
- The desired vertical section of the inverted L-osteotomy is marked with electrocautery and subsequently performed.
- It is crucial to maintain a perfect perpendicularity to the main axis of the bone in the sagittal plane so as to avoid tibial slope modifications.
- The use of a calibrated saw and osteotome allows reducing the use of image intensifier and thus the dose of radiation.
- The tibial tuberosity (TT) fragment should maintain a thickness of about 10 mm in the most proximal part to minimize the risk of fracture.
- The metallic wedge is placed in the most posterior part of the osteotomy site, creating a trapezoidal gap that minimizes the risk of tibial slope increment.
- One or 2 anteroposterior 3.5-mm cortical screws fixing the TT is/are secured before the osteotomy plate is placed, to prevent anterior tilting of the TT leading to an increase of the posterior tibial slope.
- To achieve a correct adaptation of the plate to bone, it is recommended to use a 4.5-mm cortical screw in the first of the 3 distal holes.
- A suction drainage is used to minimize the risk of hematoma.
- Patients started continuous passive motion of the knee as well as isometric quadriceps strengthening exercises immediately after surgery. During the first 3 weeks, toe-touch partial weight bearing is allowed. Progress to full weight bearing is accomplished over 3-6 weeks as tolerated.

Pitfalls and Risks

- Increased tibial slope increases anterior cruciate ligament tension and may compromise its function. Patella baja often causes anterior knee pain and may favor degeneration of the patellofemoral joint.
- There is a risk of fracture on the second vertical plane of the osteotomy and the lateral tibial cortex
- Stiffness can occur if the patient is not able to follow the established rehabilitation protocol.

HTO, high tibial osteotomy.

because of alterations in knee kinematics and its biomechanics.²¹

To maintain the posterior slope, there is the suggestion that the anterior opening of the osteotomy site should be half of the posterior opening of the wedge.²² The current technique avoids any increment in the tibial slope by creating a trapezoidal gap and first fixing the TT with an anteroposterior screw. A list of advantages and limitations of our procedure can be found in Table 3.

In conclusion, the OWHTO with a dihedral L-cut distal and posterior to the tibial tubercle accurately corrects axial malalignment without changing patellar height or the posterior tibial slope (Fig 7). The radiographic as well as the clinical results support the use of this technique in the treatment of medial compartment

knee osteoarthritis and varus malalignment in young and middle-aged patients with a normal to low patellar height.

Table 3. Advantages and Limitations

Advantages

- Simple and reproducible
- Unlike the lateral closing-wedge high tibial osteotomy, this technique avoids fibular osteotomy and the associated risk of peroneal nerve complications
- Achieves a correction of the axial malalignment without changing patellar height or posterior tibial slope
- Effective surgical intervention to treat medial compartment knee osteoarthritis and varus malalignment in young and middle-aged patients with a normal to low patellar height

Limitations

- Risk of fracture on the second vertical plane of the osteotomy if the thickness is less than 10 mm
- Risk of fracture on the lateral tibial cortex
- Soft tissue pain related to the osteotomy plate

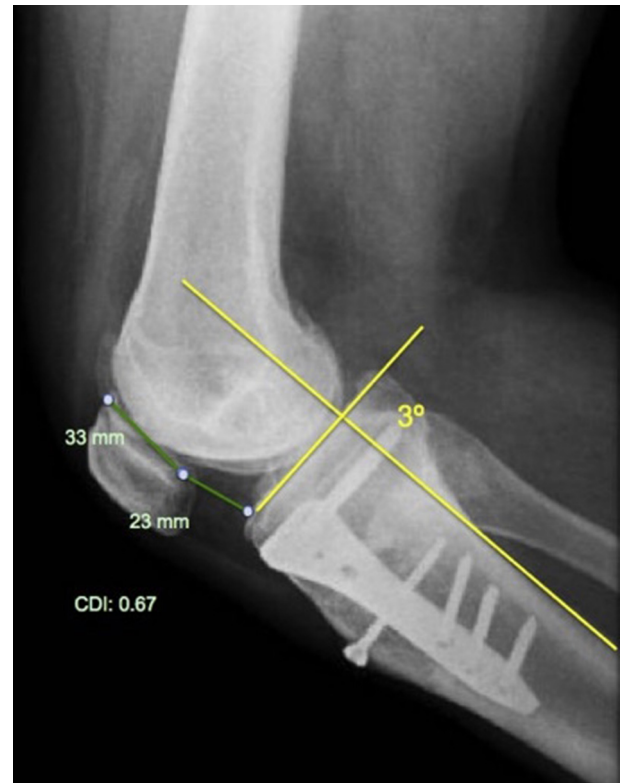


Fig 7. Postoperative radiographic sagittal imaging. Note that neither modification in patellar height nor posterior tibial slope has been made.

References

- Hernigou P, Medevielle D. Proximal tibial osteotomy for osteoarthritis with varus deformity: a ten to thirteen year follow up study. *J Bone Joint Surg Am* 1987;69:332-354.
- Poignard A, Flouzat Lachaniette CH, Amzallag J, Hernigou P. Revisiting high tibial osteotomy: Fifty years of experience with the opening-wedge technique. *J Bone Joint Surg Am* 2010;92:187-195.
- Aglietti P, Buzzi R, Vena LM, Baldini A, Mondaini A. High tibial valgus osteotomy for medial gonarthrosis: a 12-21 year study. *J Knee Surg* 2003;16:21-26.
- Gaasbeek RD, Nicolaas L, Rijnberg WJ, van Loon CJ, van Kampen A. Correction accuracy and collateral laxity in open versus closed wedge high tibial osteotomy. A one-year randomized controlled study. *Int Orthop* 2010;34:201-207.
- Noyes FR, Mayfield W, Barber Westin SD, Albright JC, Heckmann TP. Opening wedge high tibial osteotomy: An operative technique and rehabilitation program to decrease complications and promote early union and function. *Am J Sports Med* 2006;34:1262-1273.
- Sprenger TR, Doerzbacher JF. Tibial osteotomy for the treatment of varus gonarthrosis. Survival and failure analysis to twenty-two years. *J Bone Joint Surg Am* 2003;85:469-474.
- Akizuki S, Shibakawa A, Horiuchi H, Yamazaki I, Horiuchi H. The long-term outcome of high tibial osteotomy: A ten- to 20-year follow-up. *J Bone Joint Surg Br* 2008;90:592-596.
- Shim JS, Lee SH, Jung HJ, Lee HI. High tibial open wedge osteotomy below the tibial tubercle: Clinical and radiographic results. *Knee Surg Sports Traumatol Arthrosc* 2013;21:57-63.
- Habata T, Uematsu K, Hattori K, Kasanami R, Takakura Y, Fujisawa Y. High tibial osteotomy that does not cause recurrence of varus deformity for medial gonarthrosis. *Knee Surg Sports Traumatol Arthrosc* 2006;14:962-967.
- Rosenberg TD, Paulos LE, Parker RD, Coward DB, Scott SM. The forty-five-degree posteroanterior flexion weight-bearing radiograph of the knee. *J Bone Joint Surg Am* 1988;70:1479-1483.
- Brazier J, Migaud H, Gougeon F, Cotton A, Fontaine C, Duquenois A. Evaluation of methods for radiographic measurement of the tibial slope: A study of 83 healthy knees. *Rev Chir Orthop Reparatrice Appar Mot* 1996;82:195-200.
- Goutallier D, Delepine G, Debeyre J. The patella-femoral joint in osteoarthritis of the knee with genu varum. *Revue de Chirurgie Orthopedique* 1979;65:25-31.
- Amzallag J, Pujol N, Maqdes A, Beaufile P, Judet T, Catonne Y. Patellar height modification after high tibial osteotomy by either medial opening-wedge or lateral closing-wedge osteotomies. *Knee Surg Sports Traumatol Arthrosc* 2013;21:255-259.
- Gaasbeek RD, Sonneveld H, van Heerwaarden RJ, Jacobs WCH, Wymenga AB. Distal tuberosity osteotomy in open wedge high tibial osteotomy can prevent patella infera: A new technique. *Knee* 2004;11:457-461.
- El-Amrani MH, Lévy B, Scharycki S, Asselineau A. Patellar height relevance in opening-wedge high tibial osteotomy. *Orthop Traumatol Surg Res* 2010;96:37-43.
- Ozalay M, Ozkoc G, Circi E, et al. The correlation of correction magnitude and tibial slope changes following open wedge high tibial osteotomy. *Knee Surg Sports Traumatol Arthrosc* 2008;16:948-951.
- Asada S, Akagi M, Mori S, Matsushita T, Hasimoto K, Hamanishi C. Increase in posterior tibial slope would result in correction loss in frontal plane after medial open wedge high tibial osteotomy. *Knee Surg Sports Traumatol Arthrosc* 2012;20:571-578.
- El-Azab H, Halawa A, Anetzberger H, Imhoff AB, Hinterwimmer S. The effect of closed- and open-wedge high tibial osteotomy on tibial slope: A retrospective radiological review of 120 cases. *J Bone Joint Surg* 2008;90:1193-1197.
- Ozel O, Yucel B, Mutlu S, Orman O, Mutlu H. Changes in posterior tibial slope angle in patients undergoing open-wedge high tibial osteotomy for varus gonarthrosis. *Knee Surg Sports Traumatol Arthrosc* 2015;25:314-318.
- Lustig S, Scholes CJ, Costa AJ, Coolican AJ, Parker DA. Different changes in slope between the medial and lateral tibial plateau after open-wedge high tibial osteotomy. *Knee Surg Sports Traumatol Arthrosc* 2013;21:32-38.
- Brinkman JM, Lobenhoffer P, Agneskirchner JD, Staubli AE, Wymenga AB, van Heerwaarden RJ. Osteotomies around the knee: Patient selection, stability of fixation and bone healing in high tibial osteotomies. *J Bone Joint Surg Br* 2008;90:1548-1557.
- Noyes FR, Goebel SX, Wfest J. Opening wedge tibial osteotomy: The 3-triangle method to correct axial alignment and tibial slope. *Am J Sports Med* 2005;33:378-387.