

# Clinical Outcomes and Techniques for Radiofrequency Ablation of Lung Tumors Smaller than 1 cm

1) Department of Diagnostic and Interventional Radiology, Aichi Cancer Center, Japan

2) Department of Thoracic Surgery, Aichi Cancer Center, Japan

Takaaki Hasegawa<sup>1)</sup>, Yozo Sato<sup>1)</sup>, Hiroaki Kuroda<sup>2)</sup>, Shohei Chatani<sup>1)</sup>, Shinichi Murata<sup>1)</sup>,  
Hidekazu Yamaura<sup>1)</sup>, Mina Kato<sup>1)</sup>, Hiroaki Onaya<sup>1)</sup>, Yoshitaka Inaba<sup>1)</sup>

## Abstract

**Purpose:** To evaluate the outcomes of radiofrequency ablation (RFA) on lung tumors < 1 cm in maximum diameter.

**Materials and Methods:** Twenty-eight patients (12 male, 16 female; median age, 59 years; mean age, 58 ± 16 years; range, 16-78 years) who underwent RFA for lung tumors < 1 cm in diameter between November 2009 and September 2018 were included in this study. Thirty-five tumors (median size, 8.4 mm; mean size, 7.7 ± 1.9 mm; range, 3.6-9.9 mm) were treated with 33 sessions of RFA. Technique efficacy and safety were subsequently evaluated. Initial and secondary technique efficacy were defined as complete ablation without residual tumor or local tumor progression after initial and repeat RFA, respectively. Safety was evaluated according to the Common Terminology Criteria for Adverse Events, version 5.0.

**Results:** Residual tumor remained for 1 tumor (3%, 1/35) and local tumor progression was found in 2 tumors (6%, 2/35). Initial technique efficacy rate was therefore 91% (32/35). The remaining 3 tumors were treated by repeat RFA (secondary technique efficacy rate: 100%, 35/35). Initial technique efficacy rate was significantly lower for tumors treated with starting energy ≥ 20 W (P = 0.02) and showing a quick increase in tissue impedance (P = 0.01). There were 4 grade 2 adverse events (12%, 4/33) comprising pneumothorax requiring chest tube placement, and 14 grade 1 adverse events comprising self-limiting pneumothorax (36%, 12/33) and pulmonary parenchymal hemorrhage (6%, 2/33).

**Conclusion:** To achieve good outcomes for lung tumors < 1 cm, radiofrequency energy should be started at < 20 W. Application of manual mode ablation might be considered when delivery of power cannot be continued due to a quick increase in tissue impedance.

**Key words:** Interventional oncology, Small lung nodule, Radiofrequency ablation

(Interventional Radiology 2020; 5: 94-102)

## INTRODUCTION

The application of radiofrequency ablation (RFA) for the treatment of malignant lung tumors is increasing [1-5]. Several studies have detected risk factors for local tumor progression after lung RFA, including tumor size, histology, and contact with major vessels [2-4], with large tumor size

as the factor mentioned most frequently. A small lung tumor is thus considered a good indication for lung RFA.

Nevertheless, local tumor progression sometimes develops after RFA even for small lung tumors. As electrical impedance is high in lung parenchyma [6], delivery of electrical current may be insufficient, especially in RFA of small lung tumors. However, factors associated with local progression after RFA for small lung tumors have not been well investi-

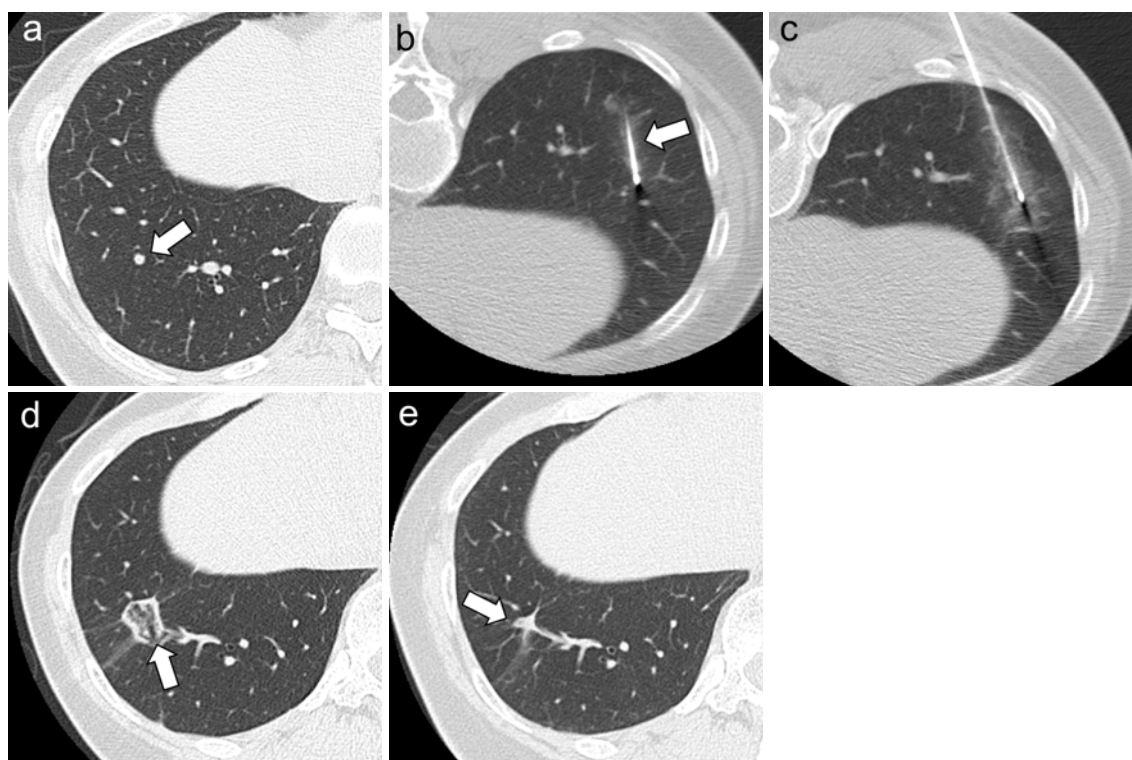
**Table 1. Background and tumor characteristics of patients**

Variables	Number	
Patient characteristics		
Sex	Male	12 (43)
	Female	16 (57)
Age (years)	Median	59
	Range	16–78
Number of lung tumors < 10 mm	1	24 (86)
	2	2 (7)
	3	1 (4)
	4	1 (4)
Previous history of malignancy	CRC	12 (43)
	NSCLC	8 (29)
	HCC	2 (7)
	Sarcoma	2 (7)
	Uterine cancer	2 (7)
	Breast cancer	1 (4)
	ACC	1 (4)
Total	28	
Tumor characteristics		
Maximum tumor diameter (mm)	Median	8.4
	Range	3.6–9.9
Radiologic findings	Solid	31 (89)
	GGO	4 (11)
Location	Right upper lobe	4 (11)
	Right middle lobe	6 (17)
	Right lower lobe	4 (11)
	Left upper lobe	12 (34)
	Left lower lobe	9 (26)
Total	35	

Numbers in parentheses represent percentages.

CRC, colorectal cancer; NSCLC, non-small cell lung cancer; HCC, hepatocellular carcinoma; ACC, adenoid cystic carcinoma; GGO, ground-glass opacity.

gated. Thus, this article retrospectively evaluated the clinical outcomes of RFA for lung tumors with a maximum diameter of 1 cm.



**Figure 1.** Axial CT images of a 52-year-old woman who underwent RFA for pulmonary metastasis from uterine cancer

(a) A 4.1-mm lung tumor in the lower right lung. (b) RFA is performed with a cooled electrode (arrow). Radiofrequency energy was applied starting from 5 W and was elevated at +5 W/min. However, delivery of power was not able to be continued due to a quick increase in tissue impedance at 15 W. (c) Manual mode ablation was applied at 20 W for 7 min until an ablation zone seemed to surround the tumor. (d) CT at 1 month after RFA shows that the tumor is covered by an ablation zone (arrow). (e) The treated tumor became smaller and showed a cordlike shape (arrow) and no progression of the local tumor was evident on CT 4 years after RFA.

## MATERIAL AND METHODS

### Study design

This retrospective study included patients who underwent RFA for malignant lung tumors with a diameter < 1 cm at our institution between November 2009 and September 2018. This study was approved by the institutional review board at Aichi Cancer Center. The need to obtain informed consent for inclusion in this study was waived, but informed consent to perform lung RFA was obtained from all patients prior to each procedure.

### Patients

Treatment outcomes of RFA were evaluated for 35 lung tumors with diameter < 1 cm (median size, 8.4 mm; mean size,  $7.7 \pm 1.9$  mm; range, 3.6-9.9 mm) in 28 patients (12 male, 16 female; median age, 59 years; mean age,  $58 \pm 16$  years; range, 16-78 years). Eight patients (29%, 8/28) had been included in a previous publication [1]. Patient and tumor characteristics are presented in **Table 1**. All patients had a history of malignancy, comprising of primary lung tu-

mors in 8 patients and metastatic lung tumors in 20 patients. Ten tumors were in contact with major vessels, with luminal diameters > 2 mm. Treatment indications were determined based on discussion among interventional radiologists, thoracic surgeons, and radiation oncologists. RFA was considered more useful than surgery or radiotherapy for these patients, based on a consideration of general and specific tumor conditions.

All patients underwent routine physical examination, laboratory tests, pulmonary function tests, and imaging studies, including chest radiography and computed tomography (CT), within the 4 weeks preceding treatment. Malignancy was diagnosed based on imaging findings from serial follow-up CT of the chest. Lung nodules that emerged and increased in size were regarded as malignant lung tumors [7]. No tumors were pathologically diagnosed before RFA.

### Lung RFA

Lung RFA was performed under moderate sedation and local anesthesia on an inpatient basis. Fentanyl citrate (Fentanyl; Daiichi Sankyo Co., Tokyo, Japan) was used for analgesia and lidocaine (Xylocaine; Astellas Pharma, Tokyo, Japan) was used for local anesthesia. Cefazolin (Cefazolin;

**Table 2. Details of procedure for each target tumor**

Variables		Number	
Ablation tip length	15 mm	1	(3)
	20 mm	29	(83)
	25 mm	1	(3)
	30 mm	4	(11)
Starting energy	5 W	27	(77)
	10 W	3	(9)
	15 W	2	(6)
	20 W	3	(9)
Maximum energy	≤15 W	3	(9)
	20 W	6	(17)
	25 W	1	(3)
	30 W	11	(31)
	40 W	11	(31)
	50 W	3	(9)
Quick increase in tissue impedance	Yes	9	(26)
	No	26	(74)
Application of manual ablation	Yes	8	(23)
	No	27	(77)
Ablation time (min)	Median	12	
	Range	4–28	
Total		35	

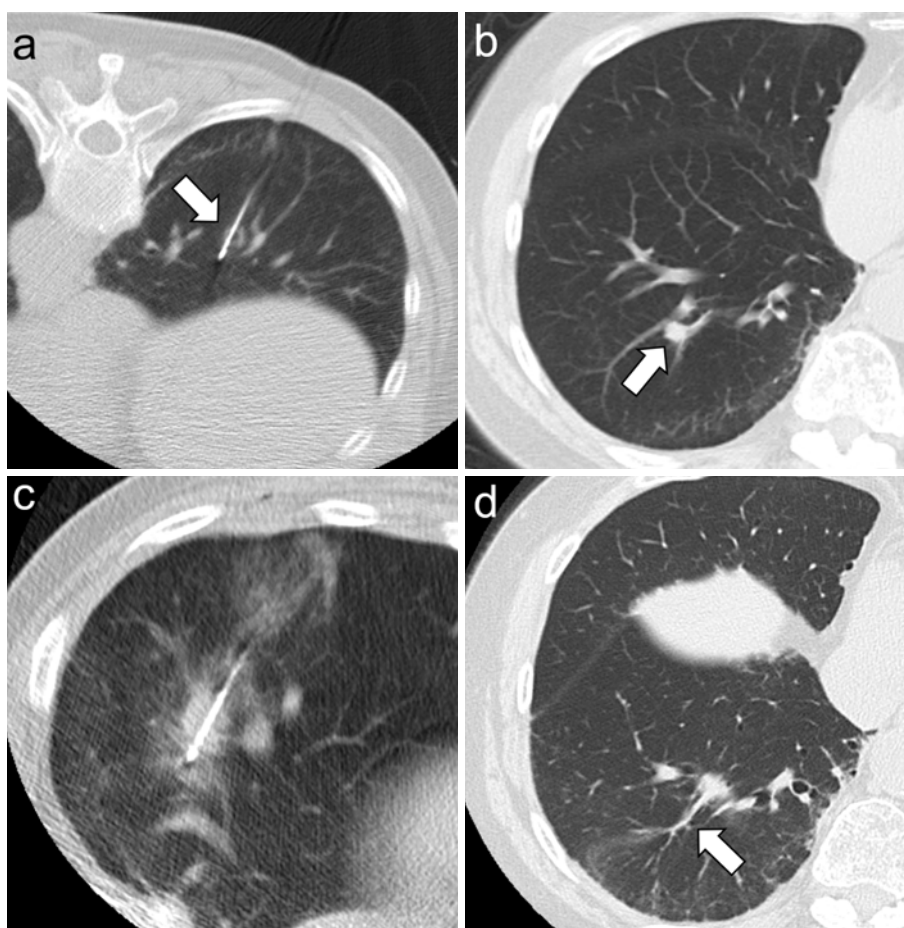
Numbers in parentheses represent percentages.

Astellas Pharma) was administered before and for 2 days after RFA as prophylaxis, in accordance with our institutional standards and policies. Real-time CT fluoroscopy (Aquillion LB; Canon Medical Systems Corp., Otawara, Japan) was used for image guidance. All procedures were performed using an internally cooled electrode (Cool-Tip RF Ablation System; Covidien, Boulder, CO until November 2015 and VIVA RF System; STARmed Co., Seoul, Korea since December 2015). Radiofrequency energy was applied using an impedance-control algorithm. When a quick increase in tissue impedance occurred, i.e., the impedance rose markedly and energy was unable to be applied any longer within 5 min or before the ablation zone covered the entire tumor on CT, manual mode ablation (in which radiofrequency energy is applied without an impedance control algorithm) was applied according to the judgment of the operator (**Figure 1a-e**). Ablation was performed until at least 6 min of ablation

time, more than 5 break-downs, and full coverage of the target tumor by the ablation zone on CT fluoroscopy was achieved. CT fluoroscopy was scanned every 3 min before first break-down and at each break-down after that. In total, 33 sessions of RFA were performed for the 35 tumors as an initial treatment. Procedure details for each tumor are summarized in **Table 2**.

#### **Follow-up**

After RFA, routine physical examinations, laboratory tests and CT with or without contrast enhancement were performed at 1 month, then every 3-4 months for 2 years, and every 6 months thereafter. Local tumor progression was defined as the appearance of new tumor foci at the edge of the ablated zone (**Figure 2a-d**) after confirming adequate ablation of the target tumor on follow-up CT [8]. Data were followed-up until death or December 31, 2019 in surviving



**Figure 2.** Axial CT images in a 78-year-old woman with pulmonary metastasis from rectal cancer (a) RFA was performed with a cooled electrode for a 9.0-mm lung tumor (arrow). Radiofrequency energy was applied from 5 W and elevated by +5 W/min up to 30 W. (b) The treated tumor was well covered by an ablative zone and appears smaller on CT after RFA. However, a 7.2-mm nodule (arrow) was seen adjacent to the edge of the ablation zone on CT 11 months after RFA. This nodule enlarged to 11.0 mm on follow-up CT 3 months later, and was diagnosed as local tumor progression. (c) The tumor was treated by repeat RFA. (d) The treated tumor became smaller and showed a cordlike shape (arrow) on CT 4 years after initial RFA.

patients. If residual tumor remained or local tumor progression emerged on follow-up CT, repeat ablation was performed.

### Assessment and statistical analyses

Technique efficacy and safety were both evaluated in this study. Technique efficacy was evaluated based on tumors. Initial technique efficacy was defined as achievement of complete ablation without residual tumor or local tumor progression on CT after the initial RFA procedure [8]. Secondary technique efficacy was defined as achievement of complete ablation after all RFA sessions, including repeat RFA for residual or recurrent tumors [8]. Factors potentially associated with technique efficacy were compared using Fisher's exact test. Safety was evaluated according to the Common Terminology Criteria for Adverse Events (CTCAE) version 5.0 based on sessions [9]. Any patient death occurring within 30 days of lung RFA was designated as Grade 5.

Data are expressed as mean  $\pm$  standard deviation. Values

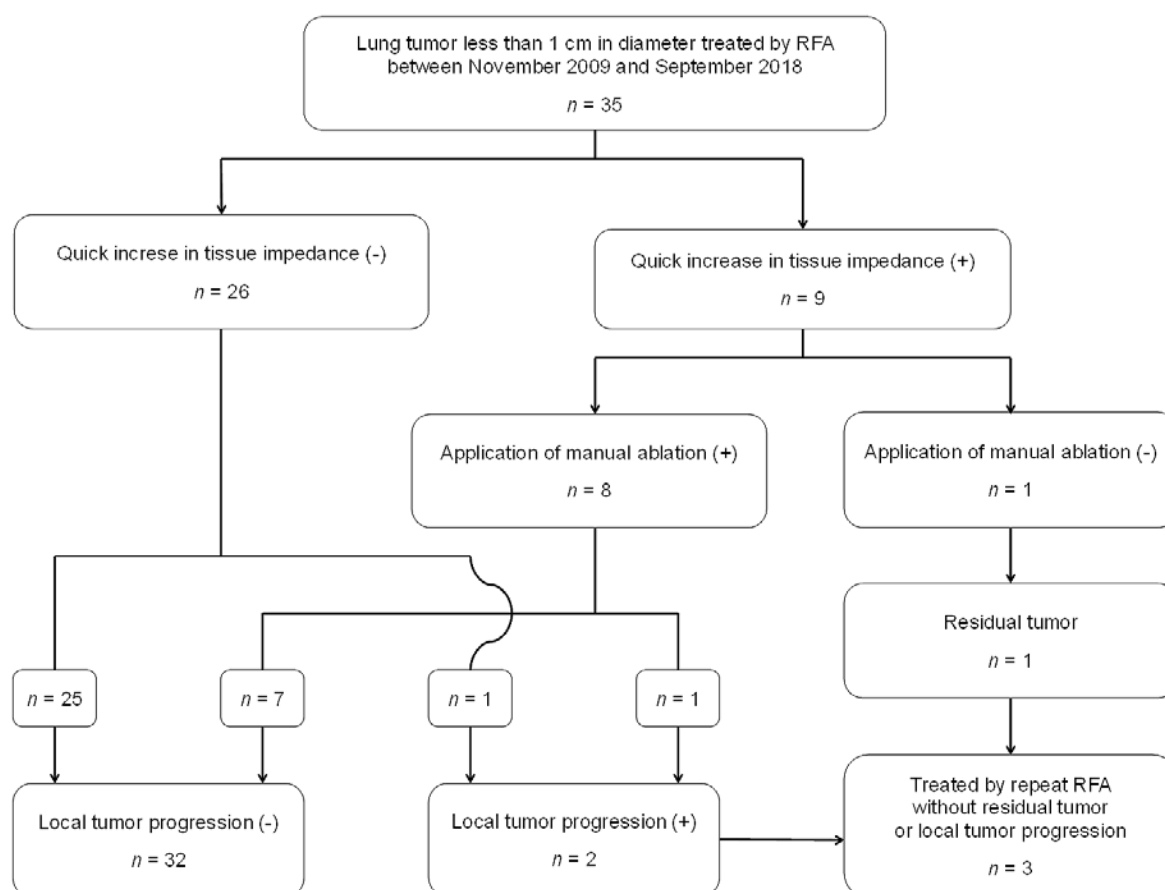
with  $p < 0.05$  were taken as statistically significant. Statistical analyses were performed using SPSS for Windows, version 24 software (IBM, Armonk, NY).

## RESULTS

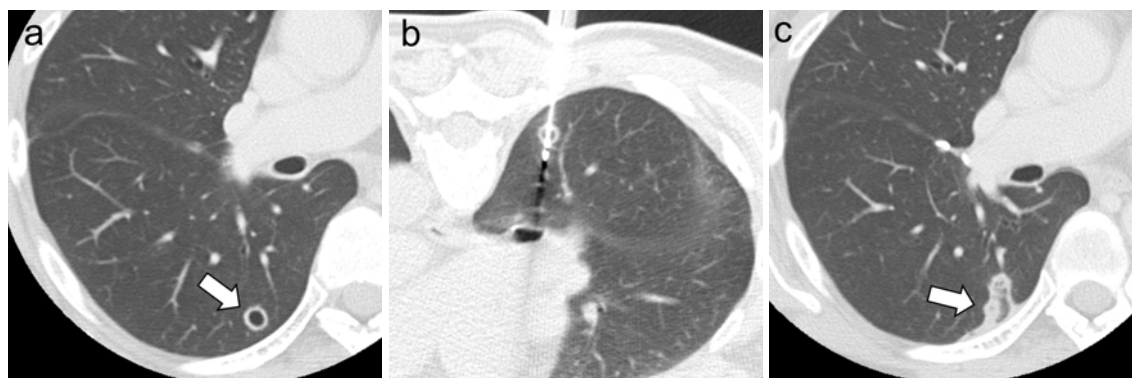
### Technique efficacy

The treatment protocol was accomplished in all treatments of target tumors (100%, 35/35). Continued delivery of power was interrupted due to a quick increase in tissue impedance in the treatment of 9 tumors, with manual mode ablation applied for 8 of those 9 tumors (Figure 3). All tumors seemed to have been covered by the ablation zone on CT immediately after RFA.

Residual tumor remained in 1 tumor (3%, 1/35), according to CT obtained 1 month after RFA (Figure 4a-c). During follow-up (median, 28 months; range, 12-79 months), local tumor progression was observed in 2 tumors (6%, 2/



**Figure 3.** Flow chart of outcomes for tumors included in this study



**Figure 4.** Axial CT images for a 58-year-old woman who underwent RFA for pulmonary metastasis from colon cancer

(a) An 8.7-mm lung tumor is evident in the lower right lung. (b) RFA was performed using a cooled electrode. Radiofrequency energy was applied from 20 W and elevated at +10 W/min. Delivery of power was interrupted due to a quick rise in tissue impedance at 50 W, but manual mode ablation was not applied. (c) The tumor was not covered by an ablative zone (arrow) on CT obtained 1 month after repeat RFA. Residual tumor was diagnosed and treated by repeat RFA.

35) at 11 and 12 months after RFA. Initial technique efficacy was thus achieved in 91% of tumors (32/35). The 1 residual tumor and 2 local tumor progressions were treated by repeat RFA, with no subsequent local tumor progression identified (secondary technique efficacy rate: 100%, 35/35).

Factors potentially affecting technique efficacy that were evaluated are summarized in **Table 3**. The initial technique

efficacy rate was significantly lower for tumors treated with a starting procedure with energy  $\geq 20$  W ( $P = 0.02$ ) and showing a quick increase in tissue impedance ( $P = 0.01$ ).

### Safety

No adverse events (AEs) of grade 3, 4, or 5 were encountered. Grade 2 pneumothorax requiring temporary chest tube

**Table 3. Risk factors for achievement of technique efficacy for each target tumor**

	Technique efficacy		<i>p</i>
	Yes (n = 32)	No (n = 3)	
Ablation tip length ( $\leq 20$ mm / $\geq 25$ mm)	28 / 4	2 / 1	0.38
Starting energy ( $\leq 15$ W / $\geq 20$ W)	31 / 1	1 / 2	0.015
Maximum energy ( $\leq 25$ W / $\geq 30$ W)	9 / 23	1 / 2	> 0.99
Quick increase in tissue impedance (Yes / No)	6 / 26	3 / 0	0.013
Application of manual ablation (Yes / No)	7 / 25	1 / 2	0.55
Radiologic findings (Solid / GGO)	28 / 4	3 / 0	> 0.99
Contact with major vessels (Yes / No)	9 / 23	1 / 2	> 0.99
Tumor size ( $\leq 8$ mm / $> 8$ mm)	15 / 17	0 / 3	0.24
Tumor type (Primary tumor / Metastatic tumor)	8 / 24	0 / 3	> 0.99
Ablation time ( $\leq 12$ min / $> 12$ min)	22 / 10	2 / 1	> 0.99

GGO, ground-glass opacity.

insertion without pleurodesis was observed in 4 patients (12%, 4/33). Grade 1 self-limiting pneumothorax occurred in 12 sessions (36%, 12/33) and pulmonary parenchymal hemorrhage occurred in 2 sessions (6%, 2/33).

## DISCUSSION

This study showed the clinical outcomes of RFA for small lung tumor and revealed some factors that apparently affect technique efficacy. To achieve effective ablation for small lung tumors, ablation needs to be started at a low energy of  $< 20$  W, and manual mode ablation should be applied when delivery of power cannot be continued due to a quick increase in tissue impedance.

Starting energy  $\geq 20$  W and occurrence of a quick in-

crease in tissue impedance represented factors associated with a lack of initial technique efficacy. In a previous expert consensus report on RFA, lung RFA was recommended to be started at 20 W [10]. In this study; however, a starting energy of 20 W might be too high to achieve complete ablation. The high volume of surrounding lung parenchyma and resulting inadequate provision of electricity is one explanation for incomplete ablation in RFA starting at a higher power. To overcome this point, Lee et al. reported an experimental study injecting saline into the lung parenchyma at the time of lung RFA [6, 11]. However, this technique carries the risk of troublesome complications related to multiple needle punctures or excessive necrosis [6, 11], and thus is not currently in clinical use. As another technique, we started RFA at lower energy. Under this technique, effusion

emerges in the lung parenchyma around the electrode, and this may help reduce electrical impedance and may thus facilitate achievement of complete ablation for the tumor. Occurrence of a quick increase in tissue impedance was another significant factor. Cauterization of surrounding tissue may be one reason for a quick elevation in impedance and subsequent insufficient ablation. Under such conditions, application of manual mode ablation may be one solution. In this study, residual tumor remained in which manual-mode ablation was not applied despite encountering a quick increase in tissue impedance during ablation. We cannot definitively confirm the utility of manual-mode ablation from this result alone, but our results do suggest that this technique may well help to improve the complete ablation rate when a quick increase in tissue impedance is encountered.

No complications of Grade 3 or higher were encountered. Incidences of Grade 1 and 2 complications were on par with findings in previous studies [2, 12]. As a needle-puncturing procedure, lung RFA procedures always carry risks of pneumothorax or pulmonary alveolar hemorrhage. However, the requirement of a smaller number of punctures might contribute to reduced occurrence of severe complications in the treatment of small lung tumors.

Our institution uses an internally cooled electrode, but the multi-tined needle can also be used for lung RFA [3, 13]. In a previous study examining treatment outcomes for small lung tumors using a multi-tined needle, Sakurai et al. reported an efficacy rate of 95% for tumors < 1 cm [13]. Evaluation of ablation zones might be easier with a multi-tined needle, as visual recognition of the needle wrapping around the tumor can be achieved. However, the shape of the multi-tined needle is more complicated than that of the internally cooled electrode and intensive training is needed to ensure safe placement of the needle at the target position. Operators must select the needle according to their experience and skill. Microwave ablation (MWA) has also been used recently as an ablation modality, reportedly allowing the creation of a larger, more uniform ablation zone compared to RFA [14]. Kurilova et al. reported that the local tumor progression rate after MWA was significantly lower for lung tumors < 1 cm than for those  $\geq$  1 cm [14], so MWA might be a good choice for small lung tumors. Nevertheless, less evidence has been accumulated for MWA than for RFA, and further investigation is required to confirm the effectiveness of MWA for lung tumors.

This study showed several limitations that warrant consideration when interpreting the results. First, this was a retrospective study at a single center, so selection bias could not be avoided. The relatively small sample size was another limitation. Initial technique efficacy could not be achieved in the treatment of only 3 tumors, so the results might have been statistically underpowered. The necessity of manual mode ablation at the time of encountering a quick increase in tissue impedance was not statistically confirmed. Further investigation with a larger sample size is needed to clarify the utility of these techniques.

In conclusion, RFA offers favorable outcomes for lung tumors < 1 cm but starting at a lower energy of < 20 W appears to be warranted. Delivery of power can sometimes not be continued due to a quick increase in tissue impedance, but application of manual mode ablation in such cases may contribute to the achievement of complete ablation.

**Acknowledgement:** We would like to thank Dr. Keitaro Matsuo, MD, PhD, MSc, who helped with the statistical analysis.

**Conflict of interest:** The authors declare that they have no conflict of interest.

**Disclaimer:** Takaaki Hasegawa and Yoshitaka Inaba are the Editorial Board members of Interventional Radiology. They were not involved in the peer-review or decision-making process for this paper.

## References

- Hasegawa T, Sato Y, Inaba Y, Kuroda H, Tomita N, Sakao Y. The Clinical Utility and Safety of Radiofrequency Ablation for Malignant Lung Tumors: Preliminary Results. *Interventional Radiology* 2017; 2 :25-32
- Yamakado K, Hase S, Matsuoka T, Tanigawa N, Nakatsuka A, Takaki H, et al. Radiofrequency ablation for the treatment of unresectable lung metastases in patients with colorectal cancer: a multicenter study in Japan. *J Vasc Interv Radiol* 2007; 18: 393-398.
- Hiraki T, Gobara H, Mimura H, Sano Y, Tsuda T, Iguchi T, et al. Does tumor type affect local control by radiofrequency ablation in the lungs? *Eur J Radiol* 2010; 74: 136-141.
- Yang Q, Qi H, Zhang R, Wan C, Song Z, Zhang L, et al. Risk Factors for Local Progression after Percutaneous Radiofrequency Ablation of Lung Tumors: Evaluation Based on a Review of 147 Tumors. *J Vasc Interv Radiol* 2017; 28: 481-489.
- Hasegawa T, Takaki H, Kodama H, Yamanaka T, Nakatsuka A, Sato Y, et al. Three-year survival rate after Radiofrequency ablation for surgically-resectable colorectal lung metastases: a prospective multicenter study. *Radiology* 2020; 294: 686-695.
- Lee JM, Youk JH, Kim YK, Han YM, Chung GH, Lee SY, et al. Radio-frequency thermal ablation with hypertonic saline solution injection of the lung: ex vivo and in vivo feasibility studies. *Eur Radiol* 2003; 13: 2540-2547.
- Lazzaron AR, Vieira MV, Damin DC. Should preoperative chest computed tomography be performed in all patients with colorectal cancer? *Colorectal Dis* 2015; 17: 184-190.
- Ahmed M, Solbiati L, Brace CL, Breen DJ, Callstrom MR, Charboneau JW, et al. Image-guided tumor ablation: standardization of terminology and reporting criteria--a 10-year update. *Radiology* 2014; 273: 241-260.
- Common Terminology Criteria for Adverse Events v5.0 (CTCAE) 2017. [https://ctep.cancer.gov/protocoldevelopment/electronic\\_applications/docs/CTCAE\\_v5\\_Quick\\_Reference\\_5x7.pdf](https://ctep.cancer.gov/protocoldevelopment/electronic_applications/docs/CTCAE_v5_Quick_Reference_5x7.pdf) Published November 27, 2017, Accessed December 25, 2019.
- Miyazaki M, Iguchi T, Takaki H, Yamanaka T, Tamura Y, Tokue H, et al. Ablation protocols and ancillary procedures in tumor ablation therapy: consensus from Japanese experts. *Jpn J Radiol*. 2016;34(9):647-656.
- Kim TS, Lim HK, Kim H. Excessive hyperthermic necrosis of a pulmonary lobe after hypertonic saline-enhanced monopolar radiofrequency ablation. *Cardiovasc Intervent Radiol* 2006; 29: 160-163.
- Kashima M, Yamakado K, Takaki H, Kodama H, Yamada T, Uraki



- J, et al. Complications after 1000 lung radiofrequency ablation sessions in 420 patients: a single center's experiences. *Am J Roentgenol* 2011; 197: W576-580.
13. Sakurai J, Hiraki T, Mimura H, Gobara H, Fujiwara H, Tajiri N, et al. Radiofrequency ablation of small lung metastases by a single application of a 2-cm expandable electrode: determination of favorable responders. *J Vasc Interv Radiol* 2010; 21: 231-236.
14. Kurilova I, Gonzalez-Aguirre A, Beets-Tan RG, Erinjeri J, Petre EN, Gonen M, et al. Microwave Ablation in the Management of Colorectal Cancer Pulmonary Metastases. *Cardiovasc Intervent Radiol* 2018; 41: 1530-1544.

Interventional Radiology is an Open Access journal distributed under the Creative Commons Attribution-NonCommercial 4.0 International License. To view the details of this license, please visit (<https://creativecommons.org/licenses/by-nc/4.0/>).