



Review Article

Emphysematous pyelonephritis: classification, management, and prognosis

Shu-Yu Wu^a, Stephen Shei-Dei Yang^{a,b}, Shang-Jen Chang^{a,b}, Chun-Kai Hsu^{a*}

^aDivision of Urology, Taipei Tzu Chi Hospital, Buddhist Tzu Chi Medical Foundation, New Taipei, Taiwan; ^bSchool of Medicine, Tzu Chi University, Hualien, Taiwan

ABSTRACT

Urinary tract infections are commonly encountered and managed worldwide, and emphysematous pyelonephritis (EPN) is among the most serious types of urinary tract infections. EPN is an acute necrotizing infection of the kidney, often associated with high rates of renal loss and mortality. The symptoms of EPN infection can be nonspecific, but the clinical triad of fever, flank pain, and nausea represent the most common presentations. The diagnosis and classification are performed with the assistance of computed tomography (CT). The imaging-based classification system created by Huang and Tseng is widely used in clinical assessments. They defined EPN into four different class (1–4), with the higher number the more severe disease. Optimal EPN treatment is controversial, with emergent nephrectomy suggested during early studies, whereas more recent evidence favors more conservative approaches. *Escherichia coli*, *Klebsiella pneumoniae* and *Proteus mirabilis* are most common pathogens. The initial use of broad-spectrum antibiotics such as Third- or fourth-generation cephalosporins and carbapenems are recommended. Diabetes, obstructive uropathy and hypertension are the most common risk factors and often need treatment together. Emergent drainage is indicated with a larger-sized drainage tube to achieve better drainage function. CT guidance has a better success rate than insertion under the guidance of ultrasonography. Nephrectomy should be reserved as the last resort for those who fail to respond to conservative therapy. This review aims to provide comprehensive, evidence-based recommendations for the diagnosis and management of this life-threatening urological infection.

KEYWORDS: *Emphysematous pyelonephritis, Gas-forming infection, Necrotizing pyelonephritis, Prognostic factors, Urinary tract infections*

Submission : 14-Sep-2021
Revision : 28-Sep-2021
Acceptance : 02-Nov-2021
Web Publication : 13-Apr-2022

INTRODUCTION

Emphysematous pyelonephritis (EPN) is a serious kidney infection associated with very high rates of renal loss and mortality. EPN is an acute necrotizing infection of the renal parenchyma and surrounding tissues. Gas may present in the renal parenchyma or collecting system or in the perinephric fat [1,2]. Diabetes mellitus is the most relevant risk factor, presenting in >90% of EPN patients [3,4]. EPN was first reported in 1898 by Kelly and MacCallum [5] and was named by Schultz and Klorfein [6] more than 60 years later due to gas accumulation characteristics. EPN is a life threatening disease, with reported mortality rates ranging from 40% to 90% [7,8]. EPN treatment options have evolved over time, ranging from aggressive operations to more conservative therapy approaches consisting primarily of drainage and medication [9]. We provide an evidence-based review of the clinical presentation, diagnosis, treatment modalities, risk factors, and prognostic factors associated

with EPN for use as a reliable resource when determining the course of care.

PRESENTATION AND DIAGNOSIS

The symptoms of EPN infection can be nonspecific, but the clinical triad of fever, flank pain, and nausea represent the most common presentations. Patients may also present with renal colic or hematuria. In cases of severe sepsis, patients may present with conscious disturbance. A history of urolithiasis or urinary tract malignancy may also be associated with the occurrence of EPN [10,11]. Costovertebral angle tenderness is often present in cases of severe infection, and if the gas reaches the subcutaneous layer, subcutaneous crepitus may be noticeable during the physical examinations. Blood

*Address for correspondence: Dr. Chun-Kai Hsu, Division of Urology, Taipei Tzu Chi Hospital, Buddhist Tzu Chi Medical Foundation, 289, Jianguo Road, Xindian District, New Taipei, Taiwan.
E-mail: svevi0614@gmail.com

This is an open access journal, and articles are distributed under the terms of the Creative Commons Attribution-NonCommercial-ShareAlike 4.0 License, which allows others to remix, tweak, and build upon the work non-commercially, as long as appropriate credit is given and the new creations are licensed under the identical terms.

For reprints contact: WKHLRPMedknow_reprints@wolterskluwer.com

How to cite this article: Wu SY, Yang SS, Chang SJ, Hsu CK. Emphysematous pyelonephritis: classification, management, and prognosis. Tzu Chi Med J 2022;34(3):297-302.

Access this article online	
Quick Response Code: 	Website: www.tcmjmed.com
	DOI: 10.4103/tcmj.tcmj_257_21

test abnormalities include leukocytosis, thrombocytopenia, elevated creatinine levels, high C-reactive protein levels, high procalcitonin levels or hypoalbuminemia. Pyuria and hematuria can also be detected by urinalysis. The clinical presentations were summarized in Table 1. The collection of the urine and blood cultures should always be performed prior to antibiotic administration [1,3]. Patients may present variable symptoms and depends on the extent of renal involvement. And the disease may have an insidious onset and may rapidly progress to severe sepsis or septic shock.

Imaging studies are necessary when diagnosing EPN. Conventional abdominal X-ray plan film can only be used to detect abnormal gas shadows (crescentic configuration) in approximately 30% of cases. Ultrasonography is a better choice than abdominal films and can usually be used to detect the presence of an enlarged kidney with hyperechoic gas accumulations in the renal parenchyma or collecting system [12,13]. On gray-scale ultrasound, a highly echogenic area with an associated ring down artifact, commonly referred to as dirty shadowing, indicates the presence of gas bubbles. The abscess presents as a hypoechoic well-circumscribed mass with poor through transmission. There will be no internal vascular flow on Doppler. Low-level internal echoes means hemorrhage or infection debris different from gas formation [14].

Urologic computed tomography (CT) is the most valuable examination for EPN, which can be used to identify the infected kidney and gas accumulation, and provide an accurate assessment of the extent of infection. The characteristic findings include intraparenchymal, intracalyceal, or intrapelvic gas, often extending into the subcapsular space or across Gerota's fascia. Furthermore, CT can be used to detect possible ureteral obstructions and urolithiasis, which are often associated with EPN occurrence. On CT, infected kidneys appear heterogeneous and embedded with hypodense abscesses containing fluid and gas [12].

An imaging-based classification system was first described in 1996 by Wan *et al.* [15], who distinguished EPN into two groups based on the detection of fluid and gas patterns in the CT findings. Class I refer to those cases that present with parenchymal destruction, with either the absence of fluid collection or the presence of streaky or mottled gas. Class II refers to those cases with either the renal or perinephric collection of bubbly or localized gas or gas in the renal collecting system. Class I is typically associated with poor

prognosis and a higher mortality rate than Class II [8]. In 2000, Huang and Tseng [10] reported another classification system bases on CT findings, which is currently widely used in clinical assessments. Because most current research studies use the Huang and Tseng definition, all further discussions in this review will also reference this classification system. Huang and Tseng focused primarily on the gas distribution: In Class 1, the gas is present only in the renal collecting system; in Class 2, the gas is present in the renal parenchyma, without extension to the extrarenal area; in Class 3A, gas or abscess are present in the perinephric space; in Class 3B, gas or abscess are present in the pararenal space; and in Class 4 bilateral involvement can be observed. The clinical pictures were showed in Figures 1 and 2. An increase in the gas distribution reflects an increase in the infection area, which is associated with an increase in the mortality rate, with Class 4 having the worst outcomes.

The diagnosis of EPN is difficult on magnetic resonance imaging (MRI). The typical characteristic is still the presence of gas in the renal parenchyma or peri-renal tissues. The free gas presents as signal voids on both T1-and T2-weighted images (WI). The use of contrast injection could be useful to assess the degree of renal destruction [16,17]. The most valuable finding for MRI in such patients refer to the evaluation of abscess and the structure of kidney. The abscess could appear initially as small wedge-shaped or round nonenhancing area. The margin is often poorly defined. It typically show low and inhomogeneous signal intensity on T1-WI and high signal intensity on T2-WI. The abscesses usually show high signal on diffusion-weighted image and apparent diffusion coefficient value. The extend of abscess and degree of kidney destruction could be well evaluated by multiplanar MRI [18,19].

PATHOPHYSIOLOGY

The most common pathogens associated with EPN occurrence are facultative anaerobes. Among these bacteria, *Escherichia coli* is the mostly commonly isolated pathogen (49%–67%), followed by *Klebsiella* (20%–24%), *Proteus* (5%–18%), *Enterococcus* (14%), and *Pseudomonas* (5%) [9]. In relatively rare cases, *Candida* species have been detected, including *Candida albicans*, *Candida parapsilosis*, and *Candida tropicalis* [20-22]. Interestingly, polymicrobial infections are seldom observed in EPN cases, with only 4%–24% of patients reported as harboring multiple pathogens. In current studies, high tissue glucose levels and poor tissue oxygenation due to microvascular disease are thought to underlie bacterial propagation and disease progression, resulting in EPN being commonly associated with diabetes [23]. The typical findings of gas accumulation in EPN are attributable to the production of gases, including hydrogen, carbon di-oxide, and nitrogen, during the fermentation of glucose and lactate by microbial organisms [10].

MANAGEMENT STRATEGIES

Antibiotics

The treatment of serious infections should always begin with aggressive resuscitation, including the provision of adequate intravenous hydration, oxygen supply,

Table 1: Summarize of the clinical symptoms of emphysematous pyelonephritis

Clinical symptoms	Abnormal laboratory data
Fever (most common)	Pyuria (common)
Flank pain (most common)	Hematuria (common)
Nausea (most common)	Leukocytosis (common)
Renal colic	Thrombocytopenia
Hematuria	Elevated creatinine levels
CV angle tenderness	High C-reactive protein levels
Conscious change (in severe cases)	High procalcitonin levels
Subcutaneous crepitus (in severe cases)	Hypoalbuminemia

CV: Costovertebral, EPN: Emphysematous pyelonephritis

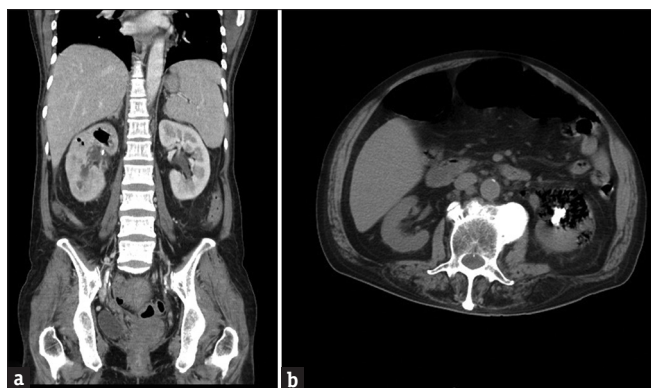

Figure 1: (a) Computed tomography scans of a 55-year-old female with right side class 2 emphysematous pyelonephritis; (b) Computed tomography scan of a 68-year-old male with left side class 2 emphysematous pyelonephritis and renal stones

insulin-mediated blood sugar control, and broad-spectrum antibiotics. Empiric antibiotics can reduce mortality in cases of gram-negative systemic infections. The choice of antibiotics must be effective against common bacteria such as *Escherichia coli*, *Klebsiella pneumoniae* and *Proteus mirabilis*. Other causative organisms include *Pseudomonas aeruginosa* and *Enterococcus* species. The preferred single-agent treatment for EPN should be effective against these most common pathogens. Third- or fourth-generation cephalosporins and carbapenems are recommended. Combination therapy, such as the use of amikacin and third-generation cephalosporin, is an alternative strategy due to low resistance rates among *E. coli*, *K. pneumoniae* and *P. mirabilis*. The additional use of gentamycin is inappropriate and not recommended [24].

The increasing global use of antibiotics has resulted in the increased incidence of drug resistance, which represents another issue for consideration. Bacteria that produce extended-spectrum beta-lactamase (ESBL) reduce the effectiveness of third-generation cephalosporin. In cases of severe bacteremia caused by ESBL-producing species, the initial use of third-generation cephalosporin is often insufficient and ineffective [25]. Fluoroquinolones have previously been recommended as a good treatment option for urinary tract infections; however, the excessive use of this agent has resulted in high levels of resistance. The reported resistance rate was >20% among common uropathogens in current research [26]. Therefore, fluoroquinolones should be avoided as first-line empiric treatments for EPN. Due to a lack of general consensus, the use of antibiotics should be guided by the patients' clinical status and the common bacteria endemic to the geographic region.

The duration of antimicrobial therapy is another important issue. Unfortunately, there is currently no report on the duration of antibiotics specifically for EPN. But we can still find the answer in the literatures about urinary tract infections. According to the treatment guidelines of the European Association of Urology on urological infections [27], EPN can be classified as complicated urinary tract infection or urosepsis. In these two groups, treatment for 7–14 days is generally recommended. But the duration should be closely

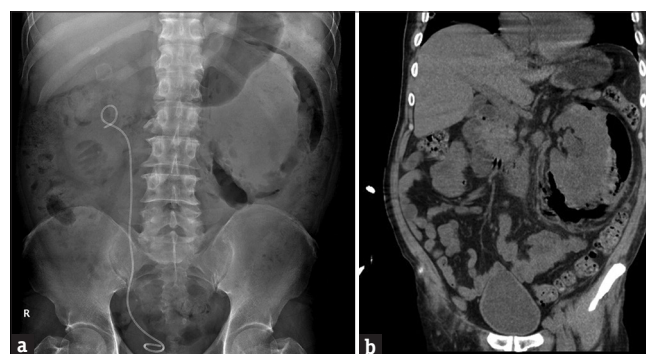

Figure 2: (a) KUB and (b) computed tomography scan of a 49-year-old male with left side severe emphysematous pyelonephritis (class 3B), large amount retroperitoneal gas accumulation and kidney destruction

related to the treatment of the underlying disease. Therefore we recommend continuous use of antibiotics for 2 weeks in treating these patients. In mild disease, antibiotics therapy for at least 1 week is still necessary.

Drainage

Antibiotics alone are not sufficient to treat EPN, and the mortality risk remained high in patients treated with antibiotics alone (19%) compared with patients provided with adequate drainage through the placement of a ureteral stent or percutaneous nephrostomy tube (PCN) (9%) in early reports [28]. In the initial report by Huang and Tseng [10], all patients with Class 1 and 2 EPN required PCN or ureteral stents. More recently, evidences has suggested that patients with less severe symptoms (such as Class 1 and 2 EPN) and no urinary obstructions can achieve excellent outcomes without drainage [29-31]. However, even among patients without obvious obstruction, the insertion of a ureteral stent or PCN was still associated with better outcomes compared with antibiotic treatment alone. In addition, improved drainage can provide a better understanding of the underlying pathogens associated with each case. Furthermore, PCN was shown to preserve renal function in the affected kidney in 70% of cases [32].

To achieve better drainage, a larger-sized drainage tube has been advised, ideally inserted under CT guidance, which has a better success rate than insertion under the guidance of ultrasonography [33]. Multiple catheters should be used in loculated abscesses or in cases of multiple abscesses. The drainage tube should remain in place until a follow-up CT shows the resolution of EPN features. A follow-up CT scan is recommended 4–7 weeks after the initial treatment to evaluate the outcome and determine the need for further invasive procedures [34]. Unfortunately, despite evidence that medical management combined with adequate drainage provides better therapeutic outcomes, which type of drainage is optimal remains unknown due to a lack of comparative studies. As most published evidence is based on the use of PCN, medical management combined with PCN can be regarded as the standard therapy for patients with mild illness.

Nephrectomy

The treatment preferences for EPN have changed a great deal over the past 20 years. In early studies, nephrectomy

was considered to be the optimal treatment strategy for EPN management, and some reports demonstrated increased mortality with medical therapy compared with surgery therapy [3,35]. However, surgery is often poorly tolerated during the acute phase due to poor hemodynamic status. Ahlering *et al.* [36] reported a high mortality rate of 42% after emergent nephrectomy. Kapoor *et al.* [37] also reported that early nephrectomy was associated with a higher mortality rate compared with the initial conservative treatment [36]. Figure 3 showed our recommendation for the management algorithm of EPN. Currently, the preferred treatment of EPN has evolved from invasive operations toward more conservative approaches, which is likely due to improvements in imaging modalities and antibiotic use and advancements in drainage technology, which have combined to reduce the mortality rate associated with EPN to 21% [8,31]. Aboumarzouk *et al.* [38] conducted a meta-analysis that compared emergent nephrectomy, percutaneous drainage and medical management alone. Their overall mortality rate was approximately 18% and both percutaneous drainage and medical management alone were associated with significantly lower mortality rates than emergent nephrectomy. Although nephrectomy has become a less popular first-line treatment option, it remains an important treatment strategy for patients who fail conservative therapy. In patients with poor EPN control (especially Class 3 and 4 patients) who fail to respond to medical management and percutaneous drainage, a subsequent nephrectomy remains necessary. The use of routine subsequent nephrectomy after infection control in severe EPN was not support by current evidence. Nephrectomy can be simple, radical or laparoscopic depending on patients' health status and the extent of disease [32]. Among patients who undergo nephrectomy after failing conservative therapy, the overall mortality was <10%. In consider about removing the

deconstructed kidney after infection control to avoid recurrent EPN. There's only rare case reports mentioned about recurrent EPN and recurrent urinary tract infection after complete infection control [39,40]. The interval of different episodes is about 1–4 years. The maximum number of relapses is three. In current evidence, there's no risk of lifelong serious infection. Therefore, the current treatment recommendations emphasize the initial use of conservative treatment strategies, including endoscopic or percutaneous drainage, to attempt renal preservation, and nephrectomy should be reserved for those who fail to respond to this approach [22,33].

RISK FACTORS AND PROGNOSTIC FACTORS

The most common risk factors for EPN include diabetes (75%–96%), obstructive uropathy (29%–49%), and hypertension (39%) [22,23]. A high average hemoglobin A1c level (9.2%) was also reported among EPN patients. Glucosuria nourishes the growth of glucose-fermenting microbes, ultimately leading to the development of a necrotizing infection with gas formation [10]. Urinary tract obstructions decrease the renal blood flow and tissue perfusion, which can worsen the infection. Immunocompromising diseases, such as alcohol abuse, acquired immunodeficiency syndrome, or tuberculosis, are often diagnosed among nondiabetic EPN patients [31]. Previous urologic procedures, hospitalization and a history of antibiotic use during the prior year do not appear to be relevant risk factors for EPN development. Female sex is another risk factor for EPN because women typically have higher rates of urinary tract infections than men. The left kidney is more frequently involved than the right, with reported infection rates of 52% on the left-side, 37.7% on the right-side and 10.2% bilateral [37]. The risk factors were summarized in Table 2.

Geographical distribution is also reported as possible risk factors due to the highest numbers reported from Asia [41]. Although rare, it is still reported in the western country [19]. Arsene *et al.* [42] and Sanford *et al.* [43] reported the high association with EPN and urinary tract obstruction caused by urolithiasis. In the United States, urinary tract obstructions caused by renal calculi were the other important risk factors same as diabetes. The urinary tract stone obstruction often results in acute infection of the kidney and associated with upper urinary tract damage. EPN could happen after persistent obstruction without adequate drainage [9]. Noncontrasted CT

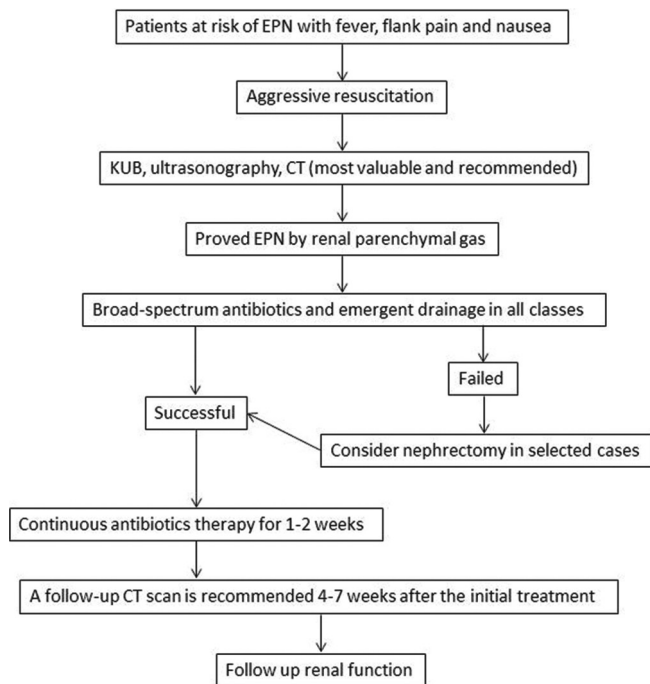


Figure 3: Management algorithm of emphysematous pyelonephritis

Table 2: Summarize of the risk factors of emphysematous pyelonephritis

Risk factors of EPN	Risk factors of poor outcomes
Diabetes	Advanced age
Obstructive uropathy	Altered mental status
Urolithiasis	Thrombocytopenia
Hypertension	Severe proteinuria
Female sex	Acute renal failure
	Hypoalbuminemia
	High grade EPN
	Polymicrobial infections
	Shock

EPN: Emphysematous pyelonephritis

Table 3: Treatment recommendations

Recommendations	Grade of recommendation	Level of evidence
CT is the most valuable examination for EPN. In cases of obstructive uropathy, delayed nephrogram or excretory phase was associated with high risk of bacteremia	B	3
<i>Escherichia coli</i> , <i>Klebsiella</i> , <i>Proteus</i> , <i>Enterococcus</i> , and <i>Pseudomonas</i> are the mostly commonly isolated pathogen	B	3
Third- or fourth-generation cephalosporins and carbapenems are recommended for initial therapy		
Drainage of the infected kidney is necessary with large size tube, ideally inserted under CT guidance	B	3
Nephrectomy should be reserved for those who fail to respond to conservative therapy	B	3

CT: Computed tomography, EPN: Emphysematous pyelonephritis

is the gold standard for the diagnosis of urolithiasis. Yagihashi *et al.* [44] had reported that a delayed nephrogram or excretory phase was associated with a 6.7-fold high risk of bacteremia such patients with stone obstruction. However, contrasted CT scan was still used widely in the emergent department to get more differential diagnosis. In addition to detecting the stones, CT scan provides the degree of hydronephrosis and retroperitoneal fat stranding. Emergent decompression for infection control was usually needed prior to the stone managements.

Factors associated with poor outcomes and higher mortality rates include advanced age, altered mental status, thrombocytopenia, severe proteinuria, acute renal failure, shock (systolic blood pressure <90 mmHg), hypoalbuminemia (serum albumin <3 g/dL), polymicrobial infections and severe hyponatremia [Table 2] [2,3,22,36,45]. Other common parameters related to infection, such as glycaemia, hemodynamic instability, leukocytosis, and coagulopathy, do not appear to be associated with EPN prognosis. The presence of hydronephrosis, urolithiasis, and bacteremia do not appear to affect the outcome. CT-based classifications can also be used to indicate the degree of the infection. Among patients with more severe diseases, higher rates of both nephrectomy and mortality were noted. The destruction of >50% of the renal parenchyma (typical of Class 3), based on CT findings, was reported to be a significant predictor of nephrectomy and death [36]. In addition, to predicting overall mortality, some laboratory data can be used to predict the response to medical management. Low hemoglobin levels, low platelet counts, and severe proteinuria were reported as independent risk factors for the failure of conservative treatments [46].

CONCLUSIONS

EPN is a serious infection characterized by gas-forming renal destruction. *E. coli* is the most commonly isolated pathogen. Diabetes is the most common risk factor. CT evaluation is the current preferred diagnostic methods, and the results can be used to classify the severity of EPN. The recommended treatment strategy has shifted from emergent nephrectomy toward first-line conservative therapy, which often combines medical management with the use of percutaneous drainage. Most patients with EPN can be successfully treated using a minimally invasive approach. The presence of advanced age, altered mental status, thrombocytopenia, severe proteinuria, acute renal failure, shock, hypoalbuminemia, polymicrobial infections

and severe hyponatremia are predictors of poor outcomes. Emergent nephrectomy is not recommended; however, delayed nephrectomy may be necessary if conservative treatment fails. The treatment recommendations based on current evidence were listed in Table 3.

Financial support and sponsorship

Nil.

Conflicts of interest

There are no conflicts of interest.

REFERENCES

- Shokeir AA, El-Azab M, Mohsen T, El-Diasty T. Emphysematous pyelonephritis: A 15-year experience with 20 cases. *Urology* 1997;49:343-6.
- Tang HJ, Li CM, Yen MY, Chen YS, Wann SR, Lin HH, et al. Clinical characteristics of emphysematous pyelonephritis. *J Microbiol Immunol Infect* 2001;34:125-30.
- Misgar RA, Mubarik I, Wani AI, Bashir MI, Ramzan M, Laway BA. Emphysematous pyelonephritis: A 10-year experience with 26 cases. *Indian J Endocrinol Metab* 2016;20:475-80.
- Smitherman KO, Peacock JE Jr. Infectious emergencies in patients with diabetes mellitus. *Med Clin North Am* 1995;79:53-77.
- Kelly HA, MacCallum WG. Pneumaturia. *JAMA* 1898;31:375-81.
- Schultz EH Jr., Klorfein EH. Emphysematous pyelonephritis. *J Urol* 1962;87:762-6.
- Falagas ME, Alexiou VG, Giannopoulou KP, Siempos II. Risk factors for mortality in patients with emphysematous pyelonephritis: A meta-analysis. *J Urol* 2007;178:880-5.
- Ciccarese F, Brandi N, Corcioni B, Golfieri R, Gaudiano C. Complicated pyelonephritis associated with chronic renal stone disease. *Radiol Med* 2021;126:505-16.
- Koch GE, Johnsen NV. The diagnosis and management of life-threatening urologic infections. *Urology* 2021;156:6-15.
- Huang JJ, Tseng CC. Emphysematous pyelonephritis: Clinicoradiological classification, management, prognosis, and pathogenesis. *Arch Intern Med* 2000;160:797-805.
- Aswathaman K, Gopalakrishnan G, Gnanaraj L, Chacko NK, Kekre NS, Devasia A. Emphysematous pyelonephritis: Outcome of conservative management. *Urology* 2008;71:1007-9.
- Mongha R, Punit B, Ranjit DK, Anup KK. Emphysematous pyelonephritis – Case report and evaluation of radiological features. *Saudi J Kidney Dis Transpl* 2009;20:838-41.
- Abdul-Halim H, Kehinde EO, Abdeen S, Lashin I, Al-Hunayan AA, Al-Awadi KA. Severe emphysematous pyelonephritis in diabetic patients: Diagnosis and aspects of surgical management. *Urol Int* 2005;75:123-8.
- Zulfiqar M, Ubilla CV, Nicola R, Menias CO. Imaging of renal infections and inflammatory disease. *Radiol Clin North Am* 2020;58:909-23.
- Wan YL, Lee TY, Bullard MJ, Tsai CC. Acute gas-producing bacterial

- renal infection: Correlation between imaging findings and clinical outcome. *Radiology* 1996;198:433-8.
16. Brown JA, Maharaj P, Khan O, Sinanan A. A rare case of emphysematous pyelonephritis within a horseshoe kidney. *West Indian Med J* 2011;60:229-31.
 17. Kua CH, Abdul Aziz Y. Air in the kidney: Between emphysematous pyelitis and pyelonephritis. *Biomed Imaging Interv J* 2008;4:e24.
 18. Haddad MC, Hawary MM, Khoury NJ, Abi-Fakher FS, Ammouri NF, Al-Kutoubi AO. Radiology of perinephric fluid collections. *Clin Radiol* 2002;57:339-46.
 19. Cruz J, Figueiredo F, Matos AP, Duarte S, Guerra A, Ramalho M. Infectious and inflammatory diseases of the urinary tract: Role of MR imaging. *Magn Reson Imaging Clin N Am* 2019;27:59-75.
 20. Ideguchi S, Yamamoto K, Ikeda A, Hashimoto K, Takazono T, Saijo T, et al. A case of bilateral emphysematous pyelonephritis caused by *Candida albicans*. *J Infect Chemother* 2019;25:302-6.
 21. Bhat RA, Bashir G, Wani M, Lone S. Emphysematous pyelonephritis caused by *Candida parapsilosis*: An unknown etiological agent. *N Am J Med Sci* 2012;4:364-6.
 22. Batirel A, Regmi SK, Singh P, Mert A, Konety BR, Kumar R. Urological infections in the developing world: An increasing problem in developed countries. *World J Urol* 2020;38:2681-91.
 23. Somani BK, Nabi G, Thorpe P, Hussey J, Cook J, N'Dow J, et al. Is percutaneous drainage the new gold standard in the management of emphysematous pyelonephritis? Evidence from a systematic review. *J Urol* 2008;179:1844-9.
 24. Lu YC, Hong JH, Chiang BJ, Pong YH, Hsueh PR, Huang CY, et al. Recommended initial antimicrobial therapy for emphysematous pyelonephritis: 51 cases and 14-year-experience of a tertiary referral center. *Medicine (Baltimore)* 2016;95:e3573.
 25. Vardakas KZ, Tansarli GS, Rafailidis PI, Falagas ME. Carbapenems versus alternative antibiotics for the treatment of bacteraemia due to *Enterobacteriaceae* producing extended-spectrum β -lactamases: A systematic review and meta-analysis. *J Antimicrob Chemother* 2012;67:2793-803.
 26. Hsueh PR, Lau YJ, Ko WC, Liu CY, Huang CT, Yen MY, et al. Consensus statement on the role of fluoroquinolones in the management of urinary tract infections. *J Microbiol Immunol Infect* 2011;44:79-82.
 27. Bonkat G, Bartoletti R, Bruyère F, Cai T, Geerlings SE, Köves B, et al. EAU Urological Infections Guidelines. Edn. Presented at the EAU Annual Congress Milan Italy 2021. ISBN 978-94-92671-13-4.
 28. Borofsky MS, Walter D, Shah O, Goldfarb DS, Mues AC, Makarov DV. Surgical decompression is associated with decreased mortality in patients with sepsis and ureteral calculi. *J Urol* 2013;189:946-51.
 29. Eswarappa M, Suryadevara S, John MM, Kumar M, Reddy SB, Suhail M. Emphysematous pyelonephritis case series from South India. *Kidney Int Rep* 2018;3:950-5.
 30. Sharma PK, Sharma R, Vijay MK, Tiwari P, Goel A, Kundu AK. Emphysematous pyelonephritis: Our experience with conservative management in 14 cases. *Urol Ann* 2013;5:157-62.
 31. Pontin AR, Barnes RD. Current management of emphysematous pyelonephritis. *Nat Rev Urol* 2009;6:272-9.
 32. Khaira A, Gupta A, Rana DS, Gupta A, Bhalla A, Khullar D. Retrospective analysis of clinical profile prognostic factors and outcomes of 19 patients of emphysematous pyelonephritis. *Int Urol Nephrol* 2009;41:959-66.
 33. Ubee SS, McGlynn L, Fordham M. Emphysematous pyelonephritis. *BJU Int* 2011;107:1474-8.
 34. Chen MT, Huang CN, Chou YH, Huang CH, Chiang CP, Liu GC. Percutaneous drainage in the treatment of emphysematous pyelonephritis: 10-year experience. *J Urol* 1997;157:1569-73.
 35. Cook DJ, Achong MR, Dobranowski J. Emphysematous pyelonephritis. Complicated urinary tract infection in diabetes. *Diabetes Care* 1989;12:229-32.
 36. Ahlering TE, Boyd SD, Hamilton CL, Bragin SD, Chandrasoma PT, Lieskovsky G, et al. Emphysematous pyelonephritis: A 5-year experience with 13 patients. *J Urol* 1985;134:1086-8.
 37. Kapoor R, Muruganandham K, Gulia AK, Singla M, Agrawal S, Mandhani A, et al. Predictive factors for mortality and need for nephrectomy in patients with emphysematous pyelonephritis. *BJU Int* 2010;105:986-9.
 38. Aboumarzouk OM, Hughes O, Narahari K, Coulthard R, Kynaston H, Chlosta P, et al. Emphysematous pyelonephritis: Time for a management plan with an evidence-based approach. *Arab J Urol* 2014;12:106-15.
 39. Huang JJ, Chen KW, Ruaan MK, Tsai HM. Recurrent emphysematous pyelonephritis. A case report. *Int Urol Nephrol* 1994;26:389-93.
 40. Sravani M, Subha A, Manuel MB, Alekhya B, Ram R, Kumar VS. Recurrent emphysematous pyelonephritis: Report of a patient with three episodes. *Saudi J Kidney Dis Transpl* 2021;32:286-8.
 41. Karthikeyan VS, Manohar CM, Mallya A, Keshavamurthy R, Kamath AJ. Clinical profile and successful outcomes of conservative and minimally invasive treatment of emphysematous pyelonephritis. *Cent European J Urol* 2018;71:228-33.
 42. Arsene C, Saste A, Arul S, Mestrovich J, Kammo R, Elbashir M, et al. A case series of emphysematous pyelonephritis. *Case Rep Med* 2014;2014:587926.
 43. Sanford TH, Myers F, Chi T, Bagga HS, Taylor AG, Stoller ML. Emphysematous pyelonephritis: The impact of urolithiasis on disease severity. *Transl Androl Urol* 2016;5:774-9.
 44. Yagihashi Y, Shimabukuro S, Toyosato T, Arakaki Y. Can excretory phase computed tomography predict bacteremia in obstructive calculous pyelonephritis? *Int Urol Nephrol* 2018;50:2123-9.
 45. Lu YC, Chiang BJ, Pong YH, Huang KH, Hsueh PR, Huang CY, et al. Predictors of failure of conservative treatment among patients with emphysematous pyelonephritis. *BMC Infect Dis* 2014;14:418.
 46. Sokhal AK, Kumar M, Purkait B, Jhanwar A, Singh K, Bansal A, et al. Emphysematous pyelonephritis: Changing trend of clinical spectrum, pathogenesis, management and outcome. *Turk J Urol* 2017;43:202-9.