



Treatment of Primary Shoulder Stiffness: Results of a Survey on Surgeon Practice Patterns in Italy

Davide Cucchi¹ Silvana De Giorgi² Maristella F. Saccomanno³ Francesco Uboldi⁴
Alessandra Menon^{5,6} Max J. Friedrich¹ Sebastian G. Walter¹ Laura de Girolamo⁷

¹ Department of Orthopaedics and Trauma Surgery, Universitätsklinikum Bonn, Bonn, Germany

² Department of Basic Medical Sciences, Neurosciences and Sensory Organs, University of Bari, Bari, Italy

³ Department of Bone and Joint Surgery, Spedali Civili, Brescia, Italy

⁴ UOC Ortopedia e Traumatologia Pediatrica, ASST Centro Specialistico Ortopedico Traumatologico Gaetano Pini-CTO, Milan, Italy

⁵ Department of Biomedical Sciences for Health, Laboratory of Applied Biomechanics, Università degli Studi di Milano, Milan, Italy

⁶ 1° Clinica Ortopedica, ASST Centro Specialistico Ortopedico Traumatologico Gaetano Pini-CTO, Milan, Italy

⁷ Laboratorio di Biotecnologie applicate all'Ortopedia, IRCCS Istituto Ortopedico Galeazzi, Milan, Italy

Address for correspondence Davide Cucchi, MD, Department of Orthopaedics and Trauma Surgery, University of Bonn, Sigmund-Freud-Straße 25, Bonn, D-53127, Germany (e-mail: d.cucchi@gmail.com).

Joints 2019;7:165–173.

Abstract

Objectives Shoulder stiffness is a condition of restricted glenohumeral range of motion (ROM), which can arise spontaneously or as consequence of a known cause. Several treatment options are available and currently no consensus has been obtained on which treatment algorithm represents the best choice for the patient. The aim of this study was to investigate surgeon practice patterns in Italy regarding treatment of primary shoulder stiffness.

Methods A literature review was performed to identify randomized controlled trials reporting results of shoulder stiffness treatment. The following controversial or critical points in the treatment of primary shoulder stiffness were identified: modalities of physical therapy; indication for oral corticosteroid; indication and frequency for injective corticosteroid; technique and site of injection; and indication, timing, and technique for surgery. A survey composed by 14 questions was created and administered to the members of a national association specialized in orthopaedics and sports traumatology (SIGASCOT at the time of survey completion, recently renamed SIA-GASCOT after the fusion of the societies SIGASCOT and SIA).

Results A total of 204 completed questionnaires were collected. Physical therapy was recommended by 98% of the interviewed. The use of oral corticosteroids was considered by 51%, and injections of corticosteroids by 72%. The posterior injection approach was the one preferred and a number of three was considered the upper limit

Keywords

- ▶ shoulder stiffness
- ▶ adhesive capsulitis
- ▶ frozen shoulder
- ▶ treatment
- ▶ steroid
- ▶ results
- ▶ review
- ▶ survey

received
December 22, 2019
accepted after revision
April 19, 2021
published online
June 18, 2021

DOI <https://doi.org/10.1055/s-0041-1730983>.
ISSN 2282-4324.

© 2021. The Author(s).

This is an open access article published by Thieme under the terms of the Creative Commons Attribution-NonDerivative-NonCommercial-License, permitting copying and reproduction so long as the original work is given appropriate credit. Contents may not be used for commercial purposes, or adapted, remixed, transformed or built upon. (<https://creativecommons.org/licenses/by-nc-nd/4.0/>)

Georg Thieme Verlag KG, Rüdigerstraße 14, 70469 Stuttgart, Germany

for repeated injections. Injective therapy with local anesthetics and hyaluronic acid was considered by more than 20% of the interviewed. Thirty percent of the interviewed did not treat shoulder stiffness surgically.

Conclusion Several approaches to shoulder stiffness have been proposed and high-level evidence is available to analyze and discuss their results. Several controversial points emerged both from a literature review and from this national survey. Treatment of shoulder stiffness should be tailored to the patient's clinical situation and the stage of its pathology and should aim at pain reduction, ROM restoration, functional regain, and shortening of symptoms duration, with conservative therapy remaining the mainstay of treatment.

Introduction

Shoulder stiffness (SS) is defined as a condition of restricted active and passive glenohumeral range of motion (ROM). It can be classified into primary (or idiopathic forms, also known as "frozen shoulder") and secondary forms (which arise as a consequence of a known cause).¹

Several risk factors have been described, nevertheless the exact etiology and pathology of primary SS have not been clarified yet: an unspecific underlying proinflammatory condition has recently been postulated to be a possible predisposing risk factor for the development of SS, which could explain also the known associations with hormonal and metabolic diseases, such as diabetes, hyper-, and hypothyroidism.^{2,3} Several treatment options have been proposed to address primary SS, ranging from conservative therapies to surgical approaches. As a general rule, treatment of SS should begin addressing known risk factors, to avoid relapses; the treatment is completed by strategies for pain reduction, ROM restoration, functional regain, and shortening of symptoms duration. The choice between treatments needs to be tailored to the stage of shoulder pathology and to the patient's clinical situation. Although several studies have tried to outline the most appropriate treatment options, no consensus has been obtained on which treatment algorithm represents the best choice for the patient.

Between 2006 and 2014, the Cochrane Company summarized the evidence derived from the randomized controlled trials (RCTs) available at that time on different approaches to SS treatment.⁴⁻⁹ More recently, a review of the literature was performed to identify RCTs reporting results of SS treatment from December 2005 onwards, updating the evidence-based indications provided by the Cochrane Company.¹⁰ Analyzing the available evidences, several still controversial points have emerged. For this reason, a survey was proposed to the members of SIGASCOT (Società Italiana Ginocchio Artrosopia Sport Cartilagine Tecnologie Ortopediche), a national scientific society focusing on arthroscopy and sports traumatology (recently renamed SIAGASCOT - Società Italiana di Artrosopia, Ginocchio, Arto Superiore, Sport, Cartilagine, Tecnologie Ortopediche - after the fusion of the societies SIGASCOT and SIA), regarding the conservative and operative treatment of SS, with the aim to investigate their attitudes toward this frequent condition.

This article reports and discusses the results of the survey, comparing the gathered data with the results of the available studies with a high level of evidence, which should be considered a guide for clinical practice.

Methods

Study Design

The following controversial or critical points in the treatment of primary SS were identified through a literature review including the RCTs encompassed in the Cochrane systematic reviews (published between 2006 and 2014⁴⁻⁹) and all newer RCTs published from 2005 onwards¹⁰:

- Different modalities of physical therapy.
- Indication for oral corticosteroids.
- Indication, frequency, and timing for injective corticosteroids.
- Technique and site of injection for injective corticosteroids.
- Conservative treatments alternative to painkillers, physical therapy, and corticosteroids.
- Indication, timing, and technique for surgical treatment.

A cross-sectional survey draft was prepared by two orthopaedic surgeons and then optimized by the members of the SIGASCOT Basic Science Committee (currently renamed Comitato Scienza di Base SIAGASCOT), composed of basic and clinical researchers and orthopaedic surgeons. The drafting process included several iterations between the Basic Science Committee and external opinion leaders in shoulder surgery, resulting in a final version composed of 14 questions which was approved by the whole research team and by the SIGASCOT Board (and later on by the SIAGASCOT Board).

The survey was generated using an online format (<https://docs.google.com/forms>) and first distributed at the Society's national congress in October 2018 to all the participants. To further increase the response rate the survey was then sent to the active members using the Society's official e-mailing list together with a short message explaining the purpose and contents of the questionnaire. Members who agreed to respond gave an implicit informed consent to the treatment of their data in an anonymous way. Three reminders were then sent 6 weeks, 3 months, and 6 months after the initial

mailing. Possibly duplicated answers were sorted based on demographic and professional data and eliminated. The results of the survey were reported following specific guidelines.¹¹

Sample Size

At the time of Survey completion and before the new SIAGASCOT society was created with the fusion of SIGASCOT and SIA, the SIGASCOT e-mail contacts were approximately 800, of which 90% working in Italy as orthopaedic surgeons. Based on a maximum total of 800 responses, at least 202 participants would be needed to achieve a statistical precision at 90% confidence intervals with a type I error rate of 5%.

Data Collection and Procedure

Completion of the questionnaire was voluntary, and no incentives were offered. Ethical approval for the study was not required. A pilot test, involving four health professional experts, was conducted to test the reliability of our survey by assessing the clarity and the accuracy of the items. The survey was comprised of two main sections: (1) general information—demographic data, region of origin, place(s) of work, education, and professional role; (2) personal attitudes toward the treatment of SS with references to both conservative and surgical approaches.

Data Analysis

Data obtained from the completed questionnaires were entered into a spreadsheet for analysis (Microsoft Excel Package Office 2007 for Windows). Statistical analysis and plotting of the data was then performed using GraphPad Prism v 6.0 software (GraphPad Software Inc.). The Kolmogorov–Smirnov normality test was used to evaluate the normal distribution of the sample. Continuous variables were expressed as the mean \pm standard deviation or medians and first and third quartiles [Q1–Q3] as appropriate. Response rates were summarized in terms of proportions of respondents.

Results

A total of 204 completed questionnaires were collected. The median age of the responders was 43 years (35–54). Thirty-seven percent of them practiced in northeast Italy, 22% in northwest, 20% in central Italy, and 22% in southern Italy, Sicily or Sardinia. Thirty-eight percent of the interviewed subjects were practicing as orthopaedic surgeons since 5 years or less, and 15% since 30 years or more. The majority of the interviewed subjects reported counseling between 4 and 6 patients affected by SS each month (**Fig. 1**). Physical therapy was recommended by 98% of the responders, with a similar distribution between physician suggesting a single type of physiotherapy and those recommending a combination of different types of physical therapy (**Fig. 2A**). The vast majority of the interviewed (88%) indicated passive rehabilitation as the preferred type of treatment (**Fig. 2B**). The use of oral corticosteroids was considered by 51% of the interviewed, 19% of whom indicated them as their first choice of

1. How many patients with shoulder stiffness do you see, on average, in a month?

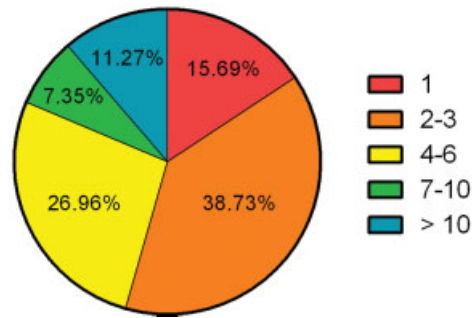
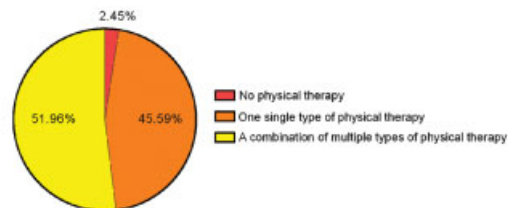


Fig. 1 Distribution of answers to question number 1.

2A. What kind of physical therapy do you recommend to your patients with shoulder stiffness?



2B. What kind of physical therapy do you recommend to your patients with shoulder stiffness?

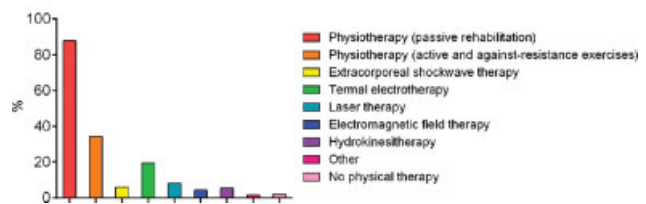


Fig. 2 (A, B) Distribution of answers to question number 2.

treatment (**Fig. 3**). Injections of corticosteroids were considered by 72% of the interviewed (**Fig. 4A**). Among those using injective steroids, 53% considered their use suitable both in stages I and II (**Fig. 4B**) and one-third of them encouraged their administration as soon as the diagnosis of SS is made (**Fig. 4C**). **Fig. 4D** summarizes the timing choices according both to disease stage and response to physical therapy. The number of three injections was considered as an upper limit by over three-quarters of the surgeons using repeated corticosteroid injections, with only 8% considering acceptable to use more than three

3. Do you use oral corticosteroids?

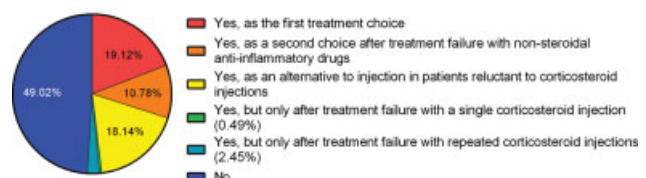
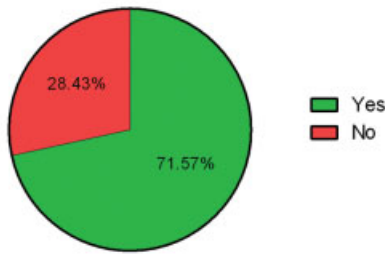
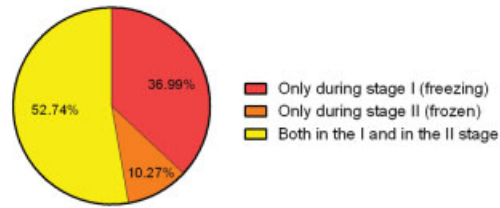


Fig. 3 Distribution of answers to question number 3.

4A. Do you use corticosteroid injections?



4B. In which stage of the disease do you take corticosteroid infiltrations into consideration?



4C. How much time after the diagnosis do you take corticosteroid infiltrations into consideration?

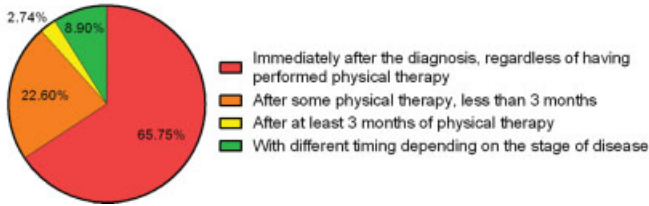

Fig. 4 (A–C) Distribution of answers to question number 4.

5. How many corticosteroid injections do you consider useful/necessary?

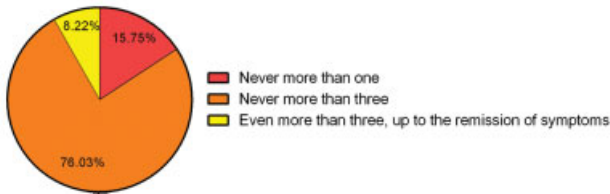

Fig. 5 Distribution of answers to question number 5.

injections (→Fig. 5). A quite variable attitude toward the distance between repeated injections was encountered (→Fig. 6). Ultrasound (US) guidance was regarded as unnecessary to assist injections by the half of those surgeons considering steroid injective therapy (→Fig. 7). The posterior approach was the preferred one to inject steroids in the shoulder and a double injection was considered by 20% of the surgeons (→Fig. 8). Among alternative treatments for SS, injections of local anesthetics and of hyaluronic acid were the only options considered by at least 20% of the interviewed surgeons (→Fig. 9). Hydrodilatation and manipulation under anesthesia were considered, respectively, by 13

6. If you use repeated injections, what is the distance between injections?

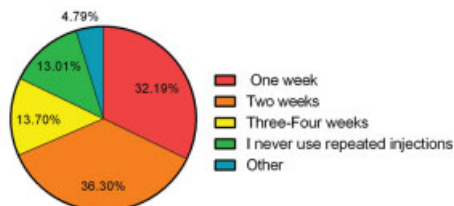


Fig. 6 Distribution of answers to question number 6.

7. Do you use ultrasound to guide corticosteroid injection?

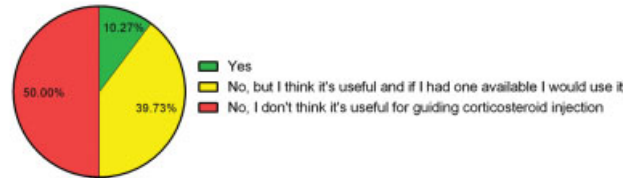


Fig. 7 Distribution of answers to question number 7.

8. How do you perform corticosteroid injections?

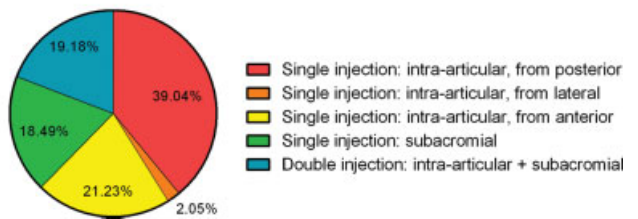


Fig. 8 Distribution of answers to question number 8.

9. Have you ever used some of these conservative treatment methods?

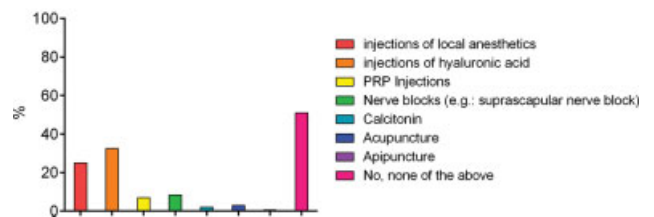


Fig. 9 Distribution of answers to question number 9.

10. Do you consider hydrodilatation?

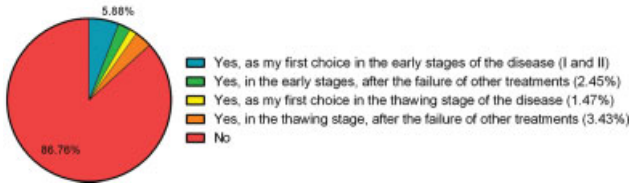


Fig. 10 Distribution of answers to question number 10.

11. Do you consider manipulation under anesthesia?

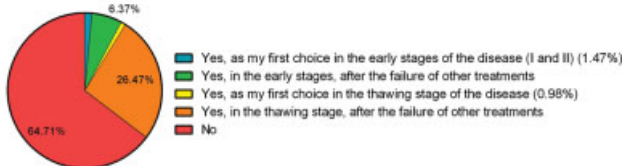


Fig.11. Distribution of answers to question number 11.

and 35% of the surgeons, across different stages of the disease (►Figs. 10 and 11). About 30% of the interviewed subjects declared not to treat SS surgically; of the remaining 70%, the majority allocated to surgery not more than 10% of the patients, with only 10% of the responders declaring to treat more than 10% of their patients surgically (►Fig. 12). Timing for surgical treatment was controversial (►Fig. 13); almost 40% of the interviewed declared to wait at least 6 months of noneffective conservative treatment before indicating surgery. Arthroscopic pancapsular release and arthroscopic capsular release associated to rotator interval release were the preferred approaches, equally distributed among the survey's participants, and clearly outnumbering open approaches (►Fig. 14).

12. In how many cases do you indicate surgery?

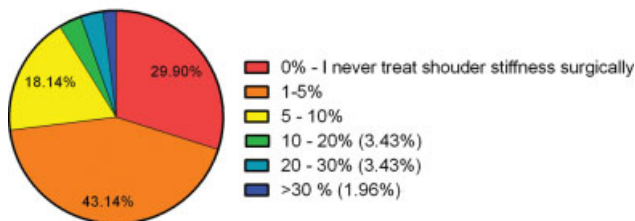


Fig. 12 Distribution of answers to question number 12.

13. After how many months of conservative treatment do you indicate surgery?

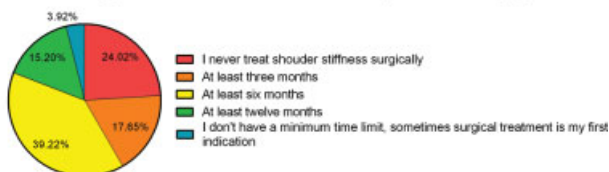

Fig. 13 Distribution of answers to question number 13.

14. What surgical technique do you use?

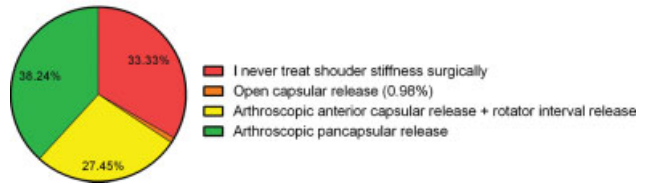


Fig.14. Distribution of answers to question number 14.

Discussion

The results of this survey among the members of largest subspecific orthopaedic Italian society confirmed that a consensus among Italian orthopaedic surgeons regarding the treatment of SS does not exist yet. In particular, several different approaches are considered across the country and numerous points remain controversial, well reflecting the panorama of other European countries.¹² A good agreement among respondents on the treatment of this disease was only obtained regarding the indication to physical therapy and to injective corticosteroid.

Medical Therapy

Oral steroids can reduce pain and disability and can improve ROM in the short term. Therefore, they may be indicated for short periods in patients without internistic contraindications to the administration of this medication.⁴ Oral steroids were considered only by the half of the interviewed surgeons and only less than 20% of them considered oral steroids as a first-choice medication (►Fig. 3).

As opposed to these data, over 70% of the interviewed surgeons considered injective corticosteroids relevant for the treatment of primary SS (►Fig. 4A); within this subgroup, 53% considered their use suitable both in the I and in the II stages (►Fig. 4B) and one-third of them stated that the administration of injective corticosteroids is indicated as soon as the diagnosis of SS is made (►Fig. 4C).

Twelve trials investigating the role of injective corticosteroids in the treatment of primary SS were identified by the Cochrane Company, two of which suggested a possible early benefit and concluded that an intra-articular (IA) injection may be beneficial.⁷ More recent literature confirmed that the use of corticosteroid injections in the treatment of idiopathic SS leads to fast pain relief and improves ROM, with superior results to nonsteroidal anti-inflammatory drugs.^{13,14} Two meta-analyses recently summarized the available evidence on injective corticosteroid treatment for SS: both Wang et al (5 studies, 225 patients) and Sun et al (8 studies, 416 patients) confirmed that IA steroid injections are effective and safe and provide pain reduction, functional performance improvement, and ROM increase.^{15,16} As compared with physiotherapy, no superiority was noted in favor of either treatment, but a single steroid injection was demonstrated to improve symptoms faster and provide greater external rotation.¹⁷ A low dose of steroid should be preferred, since higher doses did not show a significant superiority.^{18,19} No high-

level evidence indicates which is the ideal number of injections to choose, with most surgeons preferring not to inject steroids more than three times (►Fig. 5).

The widespread of US imaging permits to add it to the traditional localization of the injection site, guided by anatomical landmarks alone. In a recent publication, US-guided injections appeared to be more accurate and to yield to superior results as compared with blind injections,²⁰ updating the results of a previously published Cochrane Company review, which was unable to establish any advantage for US-guided injections.⁸ The increased time required to perform the US-guided injections and the additional costs are issues to consider.²⁰ As a result, only 10% of the interviewed surgeons reported to use US imaging to guide injections and 50% of them reported that they do not see any additional benefit in this technique (►Fig. 7).

The injection site has also been postulated to possibly influence the clinical outcome: initial investigations indicated that the efficacy of a single corticosteroid injection was not related to the site of injection,²¹ even though IA (glenohumeral) injections led to earlier pain relief compared with subacromial (SA) injections.²² These results are currently a topic of open discussion: in 2015, Prestgaard et al reported superiority of steroid treatment to placebo but no significant differences between the IA and the combined IA + SA corticosteroid injections in a three-arm, double-blind, sham-controlled RCT.²³ On the contrary, in 2016 Cho et al presented the results of a RCT on 126 patients, which indicated that the efficacy of SA injections was inferior to IA injections up to 12 weeks. Furthermore, the authors suggested that a combination of both injections could have an additive effect on increasing the internal rotation, indicating that the SA space may be a contributing site, although the glenohumeral joint remains a major site in the pathogenesis of primary SS.²⁴ For this reason, multiple injections can be considered: for example, a three-site injection (posterior capsule, SA, and subcoracoid) was proposed as an alternative to the single-site injection: Pushpasekaran et al randomized 85 patients to receive the same dose of steroid with these different approaches and concluded that a three-site injection is a safe method and provides early recovery and better improvement in shoulder function with less relapses.²⁵ A single RCT evaluated patient positioning for IA corticosteroid injections: similar satisfactory outcomes and accuracy were recorded using either the anterior or posterior US-guided approach, but positioning time was shorter for the anterior approach.²⁶

Physical Therapy

Physical therapy should aim at pain reduction, ROM restoration, and functional regain, preventing or reducing capsular contracture in the early phases and improving ROM in the latter stages of the disease. The available literature suggests a conservative treatment as the first approach to SS treatment, with physical therapy appearing the most prescribed treatment. Consistently with these data, the survey revealed that only less than 3% of the interviewed surgeons prefer not to prescribe any physical treatment (►Fig. 2A).

Several physical therapy approaches are available, with passive rehabilitation appearing to be the preferred one among the responders to this survey. A multimodal therapy, which was considered by more than the half of the interviewed surgeons, is recommended, since it can lead to superior results than a single treatment.^{27,28}

Electrotherapy modalities, like laser therapy, thermal electrotherapy, and pulsed electromagnetic field therapy, have been described as possible, effective adjuncts to active and passive rehabilitation.⁵ These treatments aim to reduce pain and improve function through an increase in transfer of different forms of energy (thermal, electrical, light, sound) to the body. Almost 20% of the interviewed surgeons reported to prescribe thermal electrotherapy, although the evidence regarding this treatment is low (►Fig. 2B). High-intensity laser therapy is the only form of electrotherapy which was investigated in a prospective placebo-controlled RCT on patients affected by primary SS, showing pain relief at early follow-up time points.²⁹ Approximately 8% of the interviewed surgeons reported to prescribe laser therapy for primary SS.

Although extracorporeal shockwave therapy has been described as safe, efficient, tolerable, and with only transient side effects in a recent study, Italian surgeons appeared not to be attracted by this method, with only less than 6% of the interviewed physician prescribing it.³⁰

Other Conservative Treatment Options

Several adjunctive or alternative approaches have been described to treat primary SS, some of which belong also to the therapeutic portfolio of Italian surgeons (►Fig. 9). The IA injection of anesthetics can reduce pain and improve patients' compliance to physiotherapy, possibly improving its results.³¹ However, the negative effects of local anesthetics on cartilage should be kept in mind when performing this procedure.³² Injections of hyaluronic acid are not supported by current literature since they did not provide benefits as compared with a physiotherapy program³³ or IA corticosteroid injections.^{34,35} A single RCT evaluated the role of platelet-rich plasma in the treatment of SS; however, since the chosen control group did not reflect the currently accepted gold-standard treatment, the relevance of the presented conclusions is questionable.³⁶ Although the application of a suprascapular nerve block has been described as a well-tolerated, safe, and effective method to reduce physiotherapy-related pain, it is not clear if this benefit is sufficient to justify the increased technical effort and the added cost.³⁷

Acupuncture and bee venom acupuncture are a supporting pillar of traditional Oriental medicine and can be used to treat primary SS. Although RCTs exist, which demonstrate safety and efficacy of such approaches, their diffusion in Italy is minimal.^{38,39}

The possible beneficial effect of calcitonin administration was initially suggested by Waldburger et al. More recently, this hypothesis was supported by a placebo-controlled RCT on 64 patients, which indicated calcitonin to be effective in reducing the use of IA steroids as rescue medication.^{40,41}

Arthrographic distension of the glenohumeral joint (hydrodilatation) showed short-term benefits in terms of pain, ROM, and function in a Cochrane review published in 2008.⁹ Shortly after this publication, Tveitå et al questioned the role of hydrodilatation, since their RCT on 76 patients could not demonstrate any significant differences in ROM between hydrodilatation and corticosteroid injections.⁴² A recent meta-analysis on 12 studies concluded that hydrodilatation does not provide a clinically significant benefit in terms of pain reduction and ROM improvement.⁴³ Nowadays, hydrodilatation is mainly considered in cases resistant to other conservative approaches, in the later phases of the disease, since in the early inflammatory phase the patient may be unable to tolerate adequate dilatation.⁴⁴ The addition of an interscalene block and joint manipulation could improve patient satisfaction and ROM as compared with hydrodilatation alone.⁴⁵ The vast majority of the interviewed Italian surgeons did not consider hydrodilatation, whereas almost two-thirds considered manipulation under anesthesia, in different phases of the disease (► **Figs. 10 and 11**). Since manipulation under anesthesia did not show superiority as compared with IA steroid injections with distension⁴⁶ and hydrodilatation⁴⁷ and given the concerns about possible serious complications derived from forceful rotation maneuvers,¹ its use in the treatment of SS is not supported by current literature.

Surgical Treatment

The vast majority of SS cases can be effectively treated with a conservative approach, with surgery playing a minor role treating this pathology; subsequently, the number of RCTs that investigated invasive strategies to treat SS is markedly limited as compared with those investigating conservative approaches. Furthermore, the indications for surgical options remain highly subjective and need to be individualized to each patient. About 30% of the interviewed subjects did not treat SS surgically; of the remaining 70%, less than 10% allocated to surgical treatment to more than 10% of their patients (► **Fig. 12**). Timing for surgical treatment is controversial (► **Fig. 13**), as well as the preferred type of surgical approach (► **Fig. 14**). Arthroscopic arthrolysis and capsular release is preferred over open procedures as it is a less invasive intervention. The addition of a posterior capsular release permits to obtain a more rapid improve in ROM within the first 3 months postoperatively, however without improvement in patient function or ROM at 6 months.⁴⁸

Conclusion

This national survey revealed that a consensus among Italian orthopaedic surgeons regarding the treatment modalities for SS does not yet exist and indicated that several different approaches are considered across the country. Despite a good agreement regarding the indication to physical therapy and to the use injective corticosteroids, controversies exist regarding the different modalities of physical therapy available, as well as indications for oral

corticosteroids, frequency and timing for injective corticosteroids, technique and site of injection for IA administration of corticosteroids, and indication, timing, and technique for surgical treatment.

In this regard, active scientific societies can play an important role in providing adequate information for their members who want to deepen their knowledge of SS and to obtain practical suggestions for the daily clinical practice. Following the result of this survey, SIGASCOT first and later on SIAGASCOT have proposed further initiatives aimed at increasing awareness and discussion among society members, with the goal of trying to align the treatment choices for SS patients, basing them on the high-quality evidences available in literature.

Authors' Contributions

D.C.: study design, survey preparation, data collection, original draft preparation; S.D.G.: survey preparation, manuscript correction; M.F.S.: survey preparation, manuscript correction; F.U.: recruitment, management of Web platform for survey administration; A.M.: statistical analysis; M.F.: original draft preparation; S.W.: original draft preparation; L.D.G.: study design, manuscript correction.

Ethical Approval

The final version of the survey was approved by the SIGASCOT Board (and later on by the SIAGASCOT Board).

Funding

None.

Conflict of Interest

L.D.G. declares payment for development of personal fees from Geistlich and Lipogem; institutional grants from IGEA, outside the submitted work. The other authors declare no conflict of interest.

References

- Itoi E, Arce G, Bain GI, et al. Shoulder stiffness: current concepts and concerns. *Arthroscopy* 2016;32(07):1402–1414
- Cucchi D, Marmotti A, De Giorgi S, et al; SIGASCOT Research Committee. Risk factors for shoulder stiffness: current concepts. *Joints* 2017;5(04):217–223
- Yano T, Hagiwara Y, Ando A, et al. RAGE-dependent NF-κB inflammation processes in the capsule of frozen shoulders. *J Shoulder Elbow Surg* 2020;29(09):1884–1891
- Buchbinder R, Green S, Youd JM, Johnston RV. Oral steroids for adhesive capsulitis. *Cochrane Database Syst Rev* 2006;(04):CD006189
- Page MJ, Green S, Kramer S, Johnston RV, McBain B, Buchbinder R. Electrotherapy modalities for adhesive capsulitis (frozen shoulder). *Cochrane Database Syst Rev* 2014;(10):CD011324
- Page MJ, Green S, Kramer S, et al. Manual therapy and exercise for adhesive capsulitis (frozen shoulder). *Cochrane Database Syst Rev* 2014;(08):CD011275
- Buchbinder R, Green S, Youd JM. Corticosteroid injections for shoulder pain. *Cochrane Database Syst Rev* 2003;(01):CD004016
- Bloom JE, Rischin A, Johnston RV, Buchbinder R. Image-guided versus blind glucocorticoid injection for shoulder pain. *Cochrane Database Syst Rev* 2012;(08):CD009147

- 9 Buchbinder R, Green S, Youd JM, Johnston RV, Cumpston M. Arthrographic distension for adhesive capsulitis (frozen shoulder). *Cochrane Database Syst Rev* 2008;(01):CD007005
- 10 Cucchi D, Walter SG, Wirtz DC, Friedrich MJ. Shoulder stiffness - how to treat? *Z Orthop Unfall* 2019;157(06):668-675
- 11 Artino AR Jr, Durning SJ, Sklar DP. Guidelines for reporting survey-based research submitted to academic medicine. *Acad Med* 2018; 93(03):337-340
- 12 Cucchi D, Walter SG, Menon A, et al. A survey on surgeon practice shows lack of consensus on the management of primary shoulder stiffness. *J Biol Regul Homeost Agents* 2020;34(4 Suppl 3):59-67
- 13 Lorbach O, Anagnostakos K, Scherf C, Seil R, Kohn D, Pape D. Nonoperative management of adhesive capsulitis of the shoulder: oral cortisone application versus intra-articular cortisone injections. *J Shoulder Elbow Surg* 2010;19(02):172-179
- 14 Ranalletta M, Rossi LA, Bongiovanni SL, Tanoira I, Elizondo CM, Maignon GD. Corticosteroid injections accelerate pain relief and recovery of function compared with oral NSAIDs in patients with adhesive capsulitis: a randomized controlled trial. *Am J Sports Med* 2016;44(02):474-481
- 15 Sun Y, Zhang P, Liu S, et al. Intra-articular steroid injection for frozen shoulder: a systematic review and meta-analysis of randomized controlled trials with trial sequential analysis. *Am J Sports Med* 2017;45(09):2171-2179
- 16 Wang W, Shi M, Zhou C, et al. Effectiveness of corticosteroid injections in adhesive capsulitis of shoulder: a meta-analysis. *Medicine (Baltimore)* 2017;96(28):e7529
- 17 Sun Y, Lu S, Zhang P, Wang Z, Chen J. Steroid injection versus physiotherapy for patients with adhesive capsulitis of the shoulder: a PRIMSA systematic review and meta-analysis of randomized controlled trials. *Medicine (Baltimore)* 2016;95(20):e3469
- 18 Yoon S-H, Lee HY, Lee HJ, Kwack K-S. Optimal dose of intra-articular corticosteroids for adhesive capsulitis: a randomized, triple-blind, placebo-controlled trial. *Am J Sports Med* 2013;41(05):1133-1139
- 19 Kim Y-S, Lee H-J, Lee D-H, Choi K-Y. Comparison of high- and low-dose intra-articular triamcinolone acetonide injection for treatment of primary shoulder stiffness: a prospective randomized trial. *J Shoulder Elbow Surg* 2017;26(02):209-215
- 20 Raeissadat SA, Rayegani SM, Langroudi TF, Khoiniha M. Comparing the accuracy and efficacy of ultrasound-guided versus blind injections of steroid in the glenohumeral joint in patients with shoulder adhesive capsulitis. *Clin Rheumatol* 2017;36(04): 933-940
- 21 Shin S-J, Lee S-Y. Efficacies of corticosteroid injection at different sites of the shoulder for the treatment of adhesive capsulitis. *J Shoulder Elbow Surg* 2013;22(04):521-527
- 22 Oh JH, Oh CH, Choi J-A, Kim SH, Kim JH, Yoon JP. Comparison of glenohumeral and subacromial steroid injection in primary frozen shoulder: a prospective, randomized short-term comparison study. *J Shoulder Elbow Surg* 2011;20(07):1034-1040
- 23 Prestgaard T, Wormgoor MEA, Haugen S, Harstad H, Mowinckel P, Brox JI. Ultrasound-guided intra-articular and rotator interval corticosteroid injections in adhesive capsulitis of the shoulder: a double-blind, sham-controlled randomized study. *Pain* 2015;156(09):1683-1691
- 24 Cho C-H, Kim H, Bae K-C, Lee D, Kim K. Proper site of corticosteroid injection for the treatment of idiopathic frozen shoulder: results from a randomized trial. *Joint Bone Spine* 2016;83(03):324-329
- 25 Pushpasekaran N, Kumar N, Chopra RK, Borah D, Arora S. Thawing frozen shoulder by steroid injection. *J Orthop Surg (Hong Kong)* 2017;25(01):2309499016684470
- 26 Kim D-Y, Lee S-S, Nomkhondorj O, et al. Comparison between anterior and posterior approaches for ultrasound-guided glenohumeral steroid injection in primary adhesive capsulitis: a randomized controlled trial. *J Clin Rheumatol* 2017;23(01):51-57
- 27 Elhafez HM, Elhafez SM. Axillary ultrasound and laser combined with postisometric facilitation in treatment of shoulder adhesive capsulitis: a randomized clinical trial. *J Manipulative Physiol Ther* 2016;39(05):330-338
- 28 Çelik D, Kaya Mutlu E. Does adding mobilization to stretching improve outcomes for people with frozen shoulder? A randomized controlled clinical trial. *Clin Rehabil* 2016;30(08):786-794
- 29 Kim SH, Kim YH, Lee H-R, Choi YE. Short-term effects of high-intensity laser therapy on frozen shoulder: a prospective randomized control study. *Man Ther* 2015;20(06):751-757
- 30 Chen C-Y, Hu C-C, Weng P-W, et al. Extracorporeal shockwave therapy improves short-term functional outcomes of shoulder adhesive capsulitis. *J Shoulder Elbow Surg* 2014;23(12): 1843-1851
- 31 Hsu W-C, Wang T-L, Lin Y-J, Hsieh L-F, Tsai C-M, Huang K-H. Addition of lidocaine injection immediately before physiotherapy for frozen shoulder: a randomized controlled trial. *PLoS One* 2015;10(02):e0118217
- 32 Kreuz PC, Steinwachs M, Angele P. Single-dose local anesthetics exhibit a type-, dose-, and time-dependent chondrotoxic effect on chondrocytes and cartilage: a systematic review of the current literature. *Knee Surg Sports Traumatol Arthrosc* 2018;26(03): 819-830
- 33 Hsieh L-F, Hsu W-C, Lin Y-J, Chang H-L, Chen C-C, Huang V. Addition of intra-articular hyaluronate injection to physical therapy program produces no extra benefits in patients with adhesive capsulitis of the shoulder: a randomized controlled trial. *Arch Phys Med Rehabil* 2012;93(06):957-964
- 34 Lim TK, Koh KH, Shon MS, Lee SW, Park YE, Yoo JC. Intra-articular injection of hyaluronate versus corticosteroid in adhesive capsulitis. *Orthopedics* 2014;37(10):e860-e865
- 35 Park KD, Nam H-S, Lee JK, Kim YJ, Park Y. Treatment effects of ultrasound-guided capsular distension with hyaluronic acid in adhesive capsulitis of the shoulder. *Arch Phys Med Rehabil* 2013; 94(02):264-270
- 36 Lin J. Platelet-rich plasma injection in the treatment of frozen shoulder: a randomized controlled trial with 6-month follow-up. *Int J Clin Pharmacol Ther* 2018;56(08):366-371
- 37 Klç Z, Filiz MB, Çakır T, Toraman NF. Addition of suprascapular nerve block to a physical therapy program produces an extra benefit to adhesive capsulitis: a randomized controlled trial. *Am J Phys Med Rehabil* 2015;94(10, Suppl 1):912-920
- 38 Koh PS, Seo BK, Cho NS, Park HS, Park DS, Baek YH. Clinical effectiveness of bee venom acupuncture and physiotherapy in the treatment of adhesive capsulitis: a randomized controlled trial. *J Shoulder Elbow Surg* 2013;22(08):1053-1062
- 39 Park YC, Koh PS, Seo BK, et al. Long-term effectiveness of bee venom acupuncture and physiotherapy in the treatment of adhesive capsulitis: a one-year follow-up analysis of a previous randomized controlled trial. *J Altern Complement Med* 2014;20(12):919-924
- 40 Rouhani A, Mardani-Kivi M, Bazavar M, et al. Calcitonin effects on shoulder adhesive capsulitis. *Eur J Orthop Surg Traumatol* 2016; 26(06):575-580
- 41 Waldburger M, Meier JL, Gobelet C. The frozen shoulder: diagnosis and treatment. Prospective study of 50 cases of adhesive capsulitis. *Clin Rheumatol* 1992;11(03):364-368
- 42 Tveitå EK, Tariq R, Sesseng S, Juel NG, Bautz-Holter E. Hydrodilatation, corticosteroids and adhesive capsulitis: a randomized controlled trial. *BMC Musculoskelet Disord* 2008;9(01):53
- 43 Saltychev M, Laimi K, Virolainen P, Fredericson M. Effectiveness of hydrodilatation in adhesive capsulitis of shoulder: a systematic review and meta-analysis. *Scand J Surg* 2018;107(04): 285-293
- 44 Yoon JP, Chung SW, Kim J-E, et al. Intra-articular injection, subacromial injection, and hydrodilatation for primary frozen shoulder: a randomized clinical trial. *J Shoulder Elbow Surg* 2016; 25(03):376-383
- 45 Mun SW, Baek CH. Clinical efficacy of hydrodistention with joint manipulation under interscalene block compared with intra-

- articular corticosteroid injection for frozen shoulder: a prospective randomized controlled study. *J Shoulder Elbow Surg* 2016;25(12):1937–1943
- 46 Jacobs LG, Smith MG, Khan SA, Smith K, Joshi M. Manipulation or intra-articular steroids in the management of adhesive capsulitis of the shoulder? A prospective randomized trial. *J Shoulder Elbow Surg* 2009;18(03):348–353
- 47 Quraishi NA, Johnston P, Bayer J, Crowe M, Chakrabarti AJ. Thawing the frozen shoulder. A randomised trial comparing manipulation under anaesthesia with hydrodilatation. *J Bone Joint Surg Br* 2007;89(09):1197–1200
- 48 Chen J, Chen S, Li Y, Hua Y, Li H. Is the extended release of the inferior glenohumeral ligament necessary for frozen shoulder? *Arthroscopy* 2010;26(04):529–535