

# Femoral Condyles Tangential Views: An Effective Method to Detect the Screw Penetration of Femoral Condyles After Retrograde Nailing

Zhan-Le Zheng<sup>1</sup>, Xian Yu<sup>2</sup>, Wei Chen<sup>1</sup>, Yue-Ju Liu<sup>1</sup>, Kun-Lun Yu<sup>1</sup>, Tao Wu<sup>1</sup>, Ying-Ze Zhang<sup>1</sup>

<sup>1</sup>Department of Orthopedic, The Third Hospital of Hebei Medical University, Shijiazhuang, Hebei 050051, China

<sup>2</sup>Department of Endocrinology, The General Hospital of Hebei Province, Hebei Medical University, Shijiazhuang, Hebei 050051, China

## Abstract

**Background:** Postoperative knee soft tissue irritation is a common complication after retrograde nail fixation of femoral fractures. Distal locking screw prominence is one of the causes for soft tissue irritation. This study aimed to determine whether the use of the femoral condyles tangential views improve the diagnostic accuracy compared with anteroposterior (A-P) view in detecting distal locking screw penetrations during retrograde femoral nailing.

**Methods:** The angle between the sagittal plane and lateral aspect of the condyle and the angle between the sagittal plane and medial aspect of condyle were measured on computed tomography (CT) images. After the angles were measured and recorded, cadaveric femurs were used in a simulated surgical procedure. The retrograde femoral nail was inserted into the femur and placed distal locking screws, which were left 2, 4, and 6 mm proud of the medial and lateral condyles for each femur. A-P view, lateral condyle tangential view and medial condyle tangential view were obtained. All fluoroscopic images were recorded and sent to three observers blinded to the experimental procedure to determine whether screws penetrated the condyle cortex or not.

**Results:** According to the results of CT scan, the lateral condyle view was  $20.88 \pm 0.98^\circ$  and the medial condyle view was  $40.46 \pm 3.14^\circ$ . In the A-P view, we detected 0% at 2 mm penetration, 16.7% (lateral condyle screw) and 25.0% (medial condyle screw) at 4 mm, and 41.7% (lateral condyle screw) and 58.3% (medial condyle screw) at 6 mm. In the lateral tangential view, we detected 91.7% at 2 mm penetration of the lateral condyle and 100% at 4 mm and 6 mm. In the medial tangential view, we detected 66.7% at 2 mm penetration of the medial condyle and 100% at 4 mm and 6 mm. The femoral condyle tangential views provided significant improvement in detecting screw penetrations at all lengths (2, 4, and 6 mm) compared with the A-P view ( $P < 0.05$ ).

**Conclusions:** The femoral condyles tangential views increased the accuracy of detecting screw penetrations on the medial and lateral condyles. Routine clinical use of the femoral condyles tangential views has the potential to increase accuracy in detecting distal locking screw penetration during retrograde femoral nailing.

**Key words:** Femoral Condyle; Retrograde Nail; Screw Penetration; Tangential View

## INTRODUCTION

Antegrade intramedullary nailing remains the attractive method for femoral shaft fractures.<sup>[1]</sup> However, retrograde intramedullary nailing is an effective method for stabilization of femoral shaft fractures in case of polytrauma,<sup>[2]</sup> bilateral femoral fractures,<sup>[3]</sup> ipsilateral acetabular,<sup>[4,5]</sup> femoral neck,<sup>[4,5]</sup> and tibial fractures,<sup>[6,7]</sup> obesity<sup>[2,8]</sup> and periprosthetic fractures.<sup>[9]</sup> Postoperative knee pain caused by tendon and soft tissue irritation is a common complication.<sup>[10-12]</sup>

The incidence of persistent postoperative knee pain following retrograde nailing has been reported to be as high as 70%.<sup>[13,14]</sup>

A trans-patella tendon approach is the secondary to many factors, including distal locking screw tip penetration to the medial condyle cortex and protrusion of screw head in the lateral condyle cortex and impingement of the iliotibial

**Address for correspondence:** Prof. Ying-Ze Zhang, Department of Orthopedic, The Third Hospital of Hebei Medical University, Shijiazhuang, Hebei 050051, China  
E-Mail: lancelotzzl@163.com

This is an open access article distributed under the terms of the Creative Commons Attribution-NonCommercial-ShareAlike 3.0 License, which allows others to remix, tweak, and build upon the work non-commercially, as long as the author is credited and the new creations are licensed under the identical terms.

**For reprints contact:** reprints@medknow.com

© 2015 Chinese Medical Journal | Produced by Wolters Kluwer - Medknow

**Received:** 06-11-2014 **Edited by:** Xin Chen

**How to cite this article:** Zheng ZL, Yu X, Chen W, Liu YJ, Yu KL, Wu T, Zhang YZ. Femoral Condyles Tangential Views: An Effective Method to Detect the Screw Penetration of Femoral Condyles After Retrograde Nailing. Chin Med J 2015;128:3352-6.

### Access this article online

#### Quick Response Code:



**Website:**  
www.cmj.org

**DOI:**  
10.4103/0366-6999.171441

band.<sup>[15,16]</sup> In clinical practice, the anteroposterior (A-P) view is conventionally used to detect improper screw placement. Despite the use of A-P view, distal locking screw tip penetration and protrusion of screw head may still be overlooked intraoperatively, because the coronal view of the distal end of the femur demonstrates the trapezoidal shape and the screw tip and screw head is in the shadow of posterior condyle. In this study, we obtained medial condyle tangential view and lateral condyle tangential view along with standard A-P view to detect locking screw penetration to the medial and lateral aspect of the femoral condyle.

## METHODS

### Materials

Thirty-two adult cadaveric femurs were studied without evidence of fracture, tumor or deformity. Muscular and tendinous soft tissues were not left on the bone. Our study followed guidelines of The Third Hospital of Hebei Medical University regarding the use of cadavers.

### Computed tomography scan

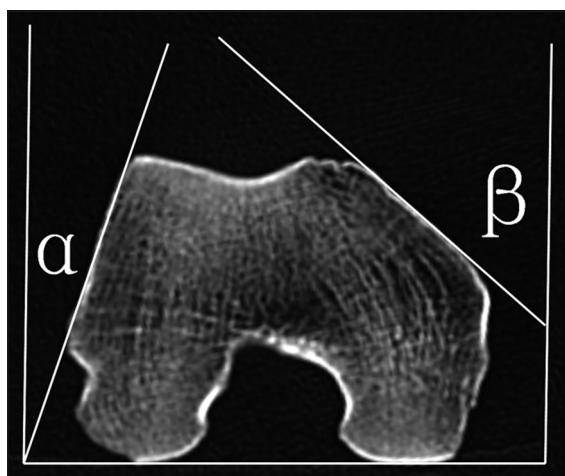
After putting the femurs in supine position on computed tomography (CT) scanner (Siemens, Germany), 1 mm fine-cut transverse CT scanning was performed in the femoral condyle.

### Angle measurement on computed tomography scan

The angle between sagittal plane and lateral aspect of condyle ( $\alpha$ ) and the angle between sagittal plane and medial aspect of condyle ( $\beta$ ) were measured on CT images by three experienced chief orthopedic surgeons [Figure 1].

### How to obtain the condyle tangential views

The lateral condyle tangential view was obtained by adjusting the direction of X-ray beam internal rotation  $\alpha$  angle from sagittal plane to the point that X-ray



**Figure 1:** After putting the femurs in a supine position on computed tomography (CT) scanner, 1 mm fine-cut transverse CT scanning was performed in the femoral condyle. The angle between the sagittal plane and lateral aspect of condyle ( $\alpha$ ) and the angle between the sagittal plane and medial aspect of condyle ( $\beta$ ) were measured on CT images.

beam was parallel to the lateral surface of the distal femur [Figure 2]. The medial condyle tangential view was obtained by adjusting the direction of X-ray beam external rotation  $\beta$  angle from sagittal plane to the point that X-ray beam was parallel to the medial surface of the distal femur [Figure 3].


### The comparison between the condyle tangential views and anteroposterior view for detecting the screw penetration

Thirty-two cadaveric femurs were used in a simulated surgical procedure. Each femur was held with clamps and then placed supine on a radiolucent table. There was no attempt to create a femoral shaft fracture; therefore this set-up resembled the condition of a femoral shaft fracture after closed anatomical reduction.

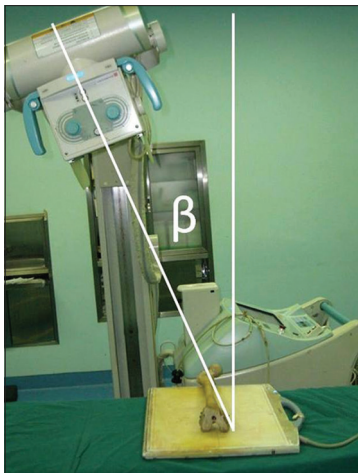
The retrograde femoral nail (Synthes Distal Femoral Nail, Switzerland) was inserted into the femur from intercondylar fossa into the medullary cavity of the femur. We then drilled the distal locking screw holes, measured and recorded the depths using the standard depth gauge, and placed screws, which were left 2, 4, and 6 mm proud of the medial and lateral condyles for each femur [Figure 4]. For each screw length, we obtained A-P view [Figure 5], lateral condyle tangential view [Figure 6], and medial condyle tangential view [Figure 7] using fluoroscopy (Siemens, Germany) and determined whether the tip or the head of the screw penetrated the cortex.

### Data collection

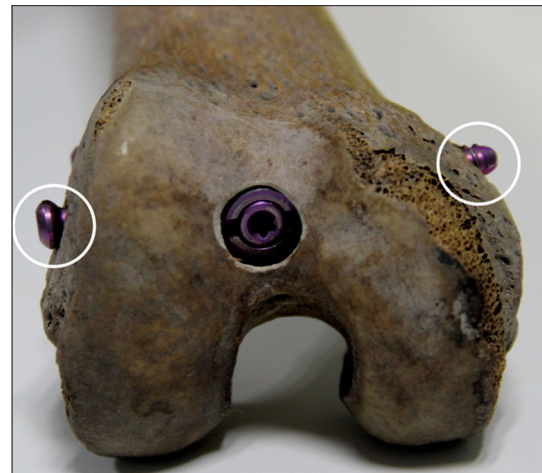All fluoroscopic images were recorded and sent to three observers who were experienced orthopedic surgeons blinded to the experimental procedure. The three observers assessed the images and came to a consensus whether the screw prominence on the medial cortex or lateral cortex. The rates of screw penetration in different lengths by different views were analyzed.



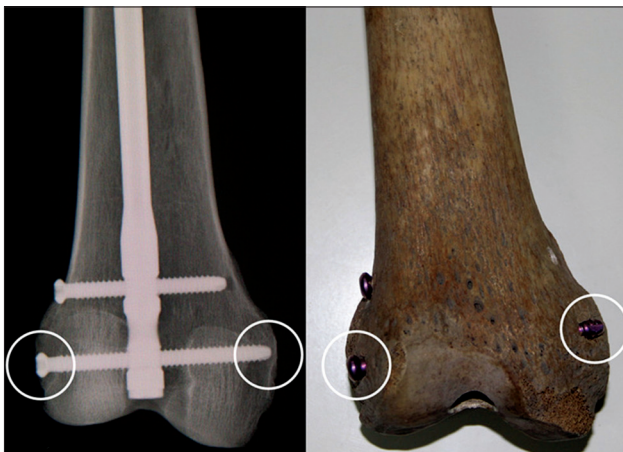**Figure 2:** The lateral condyle tangential view was obtained by adjusting the direction of X-ray beam internal rotation  $\alpha$  angle from sagittal plane to the point that X-ray beam was parallel to the lateral surface of the distal femur.



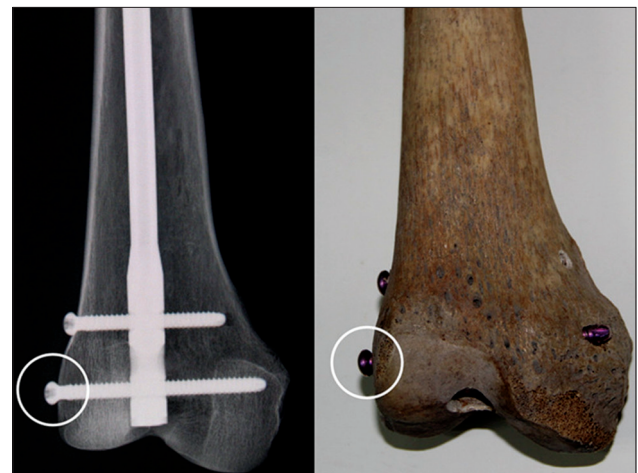**Figure 3:** The medial condyle tangential view was obtained by adjusting the direction of X-ray beam external rotation  $\beta$  angle from sagittal plane to the point that X-ray beam was parallel to the medial surface of the distal femur.



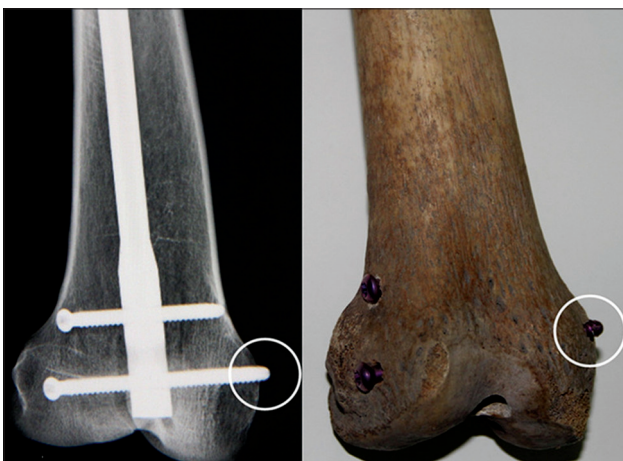**Figure 4:** The locking screw was left 4 mm proud (white circle) of the medial and lateral condyles.



**Figure 5:** The distal femoral condyle anteroposterior view cannot detect the screw 4 mm proud of the medial and lateral condyles (white circle).



**Figure 6:** The lateral condyle tangential view was obtained by changing the X-ray beam  $\alpha$  angle from sagittal plane to parallel to the lateral surface of the femoral condyle and can easily detect the proud of the screw head (white circle).



**Figure 7:** The medial condyle tangential view was obtained by changing the X-ray beam  $\alpha$  angle from sagittal plane to directed in the medial surface of the femoral condyle and can easily detect the proud of the screw tip (white circle).

### Statistical analysis

Statistical analyses were performed using Chi-square test by SPSS17.0 (SPSS Inc., Chicago, IL, USA). Categorical variables were presented as percentage or mean  $\pm$  standard error (SE). Statistical significance was defined as  $P < 0.05$ .

## RESULTS

### The angles of $\alpha$ and $\beta$

According to the CT scan results, the angle between sagittal plane and lateral aspect of condyle ( $\alpha$ ) was  $20.88 \pm 0.98^\circ$  and the angle between sagittal plane and medial aspect of condyle ( $\beta$ ) was  $40.46 \pm 3.14^\circ$ .

### Sensitivity in detecting cortical screw penetration

In the A-P view, we detected 0% at 2 mm penetration, 16.7% (lateral condyle screw) and 25.0% (medial condyle screw) at 4 mm, and 41.7% (lateral condyle screw) and

58.3% (medial condyle screw) at 6 mm. In the lateral tangential view, we detected 91.7% at 2 mm penetration of the lateral condyle and 100% at 4 mm and 6 mm. In the medial tangential view, we detected 66.7% at 2 mm penetration of the medial condyle and 100% at 4 mm and 6 mm.

At the lateral femoral condyle, the lateral condyle tangential view provided significant improvement in detecting screw heads proud at all lengths (2, 4, and 6 mm) compared with the A-P view (2 mm:  $\chi^2=46.703$ ,  $P = 0.000$ ; 4 mm:  $\chi^2=53.029$ ,  $P = 0.000$ ; and 6 mm:  $\chi^2=49.778$ ,  $P = 0.000$ ). At the medial femoral condyle, the medial condyle tangential view provided significant improvement in detecting screw penetrations at all lengths (2, 4, and 6 mm) compared with the A-P view (2 mm:  $\chi^2=35.902$ ,  $P = 0.000$ ; 4 mm:  $\chi^2=49.778$ ,  $P = 0.000$ ; 6 mm  $\chi^2=38.400$ ,  $P = 0.000$ ).

## DISCUSSION

Postoperative knee soft tissue irritation is a common complication after retrograde nail fixation of distal femoral fractures. Although the exact etiology of this complication is unknown, distal locking screw prominence is one of the causes for soft tissue irritation.<sup>[17,18]</sup> To avoid screw prominence, peroperative A-P view of the distal femur has traditionally been used. Intraoperatively, fluoroscopic evaluation of locking screw penetration is a challenge, because of the complex shape of the distal femur. Standard A-P view of the distal femur is inadequate to confirm proper screw position and length and do not always show cortical screw penetration, particularly at the medial femoral condyle. This is because of the width difference of the anterior aspect and posterior aspect of the femoral condyle, which in some cases can be more than 10 mm. Any screw penetrating the medial and lateral femoral cortex can potentially be hidden from fluoroscopic visualization using conventional A-P view because the direction of the X-ray beam is parallel to the sagittal plane. In order to improve the detecting rate of screw penetration, we first proposed the medial and lateral condyle tangential views. In the medial or lateral condyle tangential view, the beam is parallel to the medial or lateral surface of the distal femur, allowing improved visualization of the screw next to this bony prominence. In this study, we conducted an intraoperative fluoroscopic study to determine screw penetration and compared the standard radiographic views with medial and lateral condyle tangential views. At the medial oblique plane of the femoral condyle, the medial condyle tangential view provided significant improvement in detecting screw penetrations at all lengths compared with the A-P view ( $P < 0.05$ ). At the lateral oblique plane of the femoral condyle, the lateral condyle tangential view provided significant improvement in detecting screw heads proud at all lengths compared with the A-P view ( $P < 0.05$ ). From the results of this experiment, the detecting rate of lateral tangential view in 2 mm was slightly better than medial tangential view. The reason was the variation in medial condyle was larger than lateral condyle ( $20.88 \pm 0.98^\circ$  vs.  $40.46 \pm 3.14^\circ$ ).

The main limitation of this study is that this method cannot conclusively determine screw penetrations if the angles of oblique plane are not same when this method was carried out in the operating room. Because of the absence of CT scan, we do not claim that the medial and lateral condyle tangential views can be used as a gold standard to detect all screw penetrations on the femoral condyle cortex. Furthermore, if the condyle has a variation with larger angle of the condyle, the accuracy of this method will be decreased. An intraoperative continuous sequence of images around the condyle in the transverse plane will solve this problem.

To avoid femoral condyle screw penetration, one can always insert screws that are 5 mm shorter than the measured screw length and drill it carefully to feel the resistance of the lateral condyle bone cortex. We believe that the use of the medial and lateral condyle tangential views as assistance to the standard A-P view has the potential to increase the likelihood of detecting peroperative screw penetration, but it is not enough to detect all of the screw penetrations. In the clinical setting, the position of the leg usually external rotation, and hence that, in the A-P view, there may be not detected the penetration of screw tip in the medial condyle. In order to prevent this error, when we use this method, we should fix the leg in a neutral position.

In conclusion, the femoral condyles tangential views increase the accuracy of detecting screw penetrations on the medial and lateral condyles. Routine clinical use of the femoral condyles tangential views has the potential to increase accuracy in detecting distal locking screw penetration during retrograde femoral nailing.

## Financial support and sponsorship

This study was supported by grants from the Hebei Medical Science Key Research Plan (No. ZL20140208) and the National Natural Science Foundation of China (No. 81401789).

## Conflicts of interest

There are no conflicts of interest.

## REFERENCES

1. Zheng ZL, Yu X, Xu GQ, Chen W, Zhang YZ, Jiao ZQ. Four pins assisted reduction of complex segmental femoral fractures: A technique for closed reduction (in Chinese). *J Huazhong Univ Sci Technol Med Sci* 2014;34:912-6.
2. Moed BR, Watson JT. Retrograde intramedullary nailing, without reaming, of fractures of the femoral shaft in multiply injured patients. *J Bone Joint Surg Am* 1995;77:1520-7.
3. Ricci WM, Bellabarba C, Evanoff B, Herscovici D, DiPasquale T, Sanders R. Retrograde versus antegrade nailing of femoral shaft fractures. *J Orthop Trauma* 2001;15:161-9.
4. Moed BR, Watson JT, Cramer KE, Karges DE, Teefey JS. Unreamed retrograde intramedullary nailing of fractures of the femoral shaft. *J Orthop Trauma* 1998;12:334-42.
5. Sanders R, Koval KJ, DiPasquale T, Helfe DL, Frankle M. Retrograde reamed femoral nailing. *J Orthop Trauma* 2014;28 Suppl 8:S15-24.
6. Gregory P, DiCicco J, Karpik K, DiPasquale T, Herscovici D, Sanders R. Ipsilateral fractures of the femur and tibia: Treatment

- with retrograde femoral nailing and unreamed tibial nailing. *J Orthop Trauma* 1996;10:309-16.
7. Ostrum RF. Treatment of floating knee injuries through a single percutaneous approach. *Clin Orthop Relat Res* 2000;375:43-50.
  8. Koerner JD, Patel NM, Yoon RS, Gage MJ, Donegan DJ, Liporace FA. Femoral malrotation after intramedullary nailing in obese versus non-obese patients. *Injury* 2014;45:1095-8.
  9. Biber R, Bail HJ. Retrograde intramedullary nailing for periprosthetic fractures of the distal femur. *Oper Orthop Traumatol* 2014;26:438-54.
  10. El Moumni M, Schraven P, ten Duis HJ, Wendt K. Persistent knee complaints after retrograde unreamed nailing of femoral shaft fractures. *Acta Orthop Belg* 2010;76:219-25.
  11. Andrzejewski K, Panasiuk M, Grzegorzewski A, Synder M. Comparison of knee function in patients with a healed fracture of the femoral shaft fixed with retrograde and antegrade intramedullary nailing. *Ortop Traumatol Rehabil* 2013;15:395-405.
  12. Reina R, Vilella FE, Ramirez N, Valenzuela R, Nieves G, Foy CA. Knee pain and leg-length discrepancy after retrograde femoral nailing. *Am J Orthop (Belle Mead NJ)* 2007;36:325-8.
  13. Acharya KN, Rao MR. Retrograde nailing for distal third femoral shaft fractures: A prospective study. *J Orthop Surg (Hong Kong)* 2006;14:253-8.
  14. Papadokostakis G, Papakostidis C, Dimitriou R, Giannoudis PV. The role and efficacy of retrograding nailing for the treatment of diaphyseal and distal femoral fractures: A systematic review of the literature. *Injury* 2005;36:813-22.
  15. Handolin L, Pajarinen J, Lindahl J, Hirvensalo E. Retrograde intramedullary nailing in distal femoral fractures – Results in a series of 46 consecutive operations. *Injury* 2004;35:517-22.
  16. Seifert J, Stengel D, Matthes G, Hinz P, Ekkernkamp A, Ostermann PA. Retrograde fixation of distal femoral fractures: Results using a new nail system. *J Orthop Trauma* 2003;17:488-95.
  17. Tornetta P 3<sup>rd</sup>, Tiburzi D. Antegrade or retrograde reamed femoral nailing. A prospective, randomised trial. *J Bone Joint Surg Br* 2000;82:652-4.
  18. Ingman AM. Retrograde intramedullary nailing of supracondylar femoral fractures: Design and development of a new implant. *Injury* 2002;33:707-12.