

## New Observations Letters

## Globus Pallidum DBS for Task-Specific Dystonia in a Professional Golfer

Aparna Wagle Shukla<sup>1\*</sup>, Wei Hu<sup>1</sup>, Zakia Jabarkheel<sup>1</sup>, Syed Shah<sup>2</sup>, Joseph Legacy<sup>1</sup>, Kamilia Nozile Firth<sup>1</sup>, Pam Zeilman<sup>1</sup>, Kelly Foote<sup>3</sup> & Michael S. Okun<sup>1</sup>

<sup>1</sup>Department of Neurology, University of Florida, Center for Movement Disorders and Neurorestoration, Gainesville, FL, USA, <sup>2</sup>Department of Neurology, University of Missouri, Columbia, MO, USA, <sup>3</sup>Department of Neurosurgery, University of Florida, Gainesville, FL, USA

**Keywords:** Task-specific cervical dystonia, yips, globus pallidum, deep brain stimulation, golf

**Citation:** Wagle Shukla A, Hu W, Jabarkheel Z, Shah S, Legacy J, Firth KN, et al. Globus pallidum DBS for task-specific dystonia in a professional golfer. Tremor Other Hyperkinet Mov. 2018; 8. doi: 10.7916/D83X9Q9D

\*To whom correspondence should be addressed. E-mail: Aparna.shukla@neurology.ufl.edu

**Editor:** Elan D. Louis, Yale University, USA

**Received:** May 30, 2018 **Accepted:** August 20, 2018 **Published:** October 9, 2018

**Copyright:** © 2018 Shukla et al. This is an open-access article distributed under the terms of the Creative Commons Attribution–Noncommercial–No Derivatives License, which permits the user to copy, distribute, and transmit the work provided that the original authors and source are credited; that no commercial use is made of the work; and that the work is not altered or transformed.

**Funding:** None.

**Financial Disclosures:** Aparna Wagle Shukla reports grants from the NIH and has received grant support from Benign Essential Blepharospasm Research foundation, Dystonia coalition, Dystonia Medical Research foundation, National Organization for Rare Disorders and grant support from NIH (KL2 and K23 NS092957-01A1). Dr. Kelly Foote – Received research support and fellowship support from Medtronic, and has received an honorarium from Medtronic for chairing an expert DBS practitioners' symposium. He has received research support from, and serves on the neurosurgery advisory board for Neuropace. He has also received research support from St. Jude, Boston Scientific, and Functional Neuromodulation. All listed research support has been granted to the University of Florida and Dr. Foote has derived no personal financial gain from these studies. Dr. Michael S. Okun serves as consultant for the National Parkinson's Foundation, and has received research grants from the National Institutes of Health, National Parkinson's Foundation, Michael J. Fox Foundation, Parkinson Alliance, Smallwood Foundation, Bachmann-Strauss Foundation, Tourette Syndrome Association, and UF Foundation. Dr. Okun has previously received honoraria, but in the past >60 months has received no support from industry. Dr. Okun has received royalties for publications with Demos, Manson, Amazon, Smashwords, Books4Patients, and Cambridge (movement disorders books). Dr. Okun is an associate editor for *New England Journal of Medicine Journal Watch Neurology*. Dr. Okun has participated in CME and educational activities on movement disorders (in the last 36 months) sponsored by PeerView, Prime, Quantia, Henry Stewart, and the Vanderbilt University. The institution and not Dr. Okun receives grants from Medtronic, Abbvie, and ANS/St. Jude, and the PI has no financial interest in these grants. Dr. Okun has participated as a site PI and/or co-I for several NIH, foundation, and industry sponsored trials over the years but has not received honoraria.

**Conflicts of Interest:** The authors report no conflict of interest.

**Ethics Statement:** This study was reviewed by the authors' institutional ethics committee and was considered exempted from further review.

Dear Editor

Task-specific dystonias are focal dystonias presenting in body parts engaged in highly skilled or overlearned tasks involving repetitive actions and overuse of muscles. These tasks commonly include playing musical instruments, writing, typing, and sports.<sup>1</sup> Although the neck is the most frequent body region involved in focal dystonia, task-specific cervical dystonia has only been rarely reported in literature.<sup>2</sup> These case reports were observed to be in relation to frequent cradling of a phone to the right ear (muscles engaged in tilting of neck involved),<sup>2</sup> chronic sledgehammer use (shoulder muscles),<sup>3</sup> chronic heavy lifting (shoulder muscles),<sup>3</sup> and in one report the patient had bilateral arm amputation and used the mouth for holding and the neck for stabilizing during many motor activities.<sup>4</sup> These patients were treated with botulinum toxin injections, with only two of them reporting mild to moderate improvement. We describe task-specific dystonia

symptoms (predominantly cervical) in a professional golfer who quit his career due to disabling symptoms but improved remarkably with deep brain stimulation (DBS) therapy.

A 56-year-old right-handed professional male golfer presented with a 10-year history of gradually progressive rightward and upward involuntary turning of the head noted during the swinging task along with intermittent left arm cramping during the putting task. He reported playing golf for over 35 years. He stated his neck symptoms were the most bothersome and the arm symptoms were very mild. He denied the presence of sensory trick for alleviation of his symptoms. He also complained of occasional tilting of the head to the left while playing golf. He reported he had no involuntary neck movement when the neck muscles were engaged in other tasks such as driving, watching television, or during routine conversation (non-golf activities). During the physical examination, a slight prominence of the left

sternocleidomastoid muscle was noted and abnormal right turning of head (torticollis) was elicited specific to the swinging task employed during golf (Video 1). There was no abnormal posturing noted in the head or any other body part during rest, posture, and action tasks such as voluntary neck flexion, neck extension, side-to-side movement, and the finger-to-nose task for the arms. He underwent multiple medication trials including baclofen, tizanidine, clonazepam, and trihexyphenidyl. He was then treated with several rounds of onabotulinum toxin injections administered into the left sternocleidomastoid, right splenius capitis, right semispinalis capitis, and bilateral trapezius muscles (maximum dose 300 units). However, none of these treatments



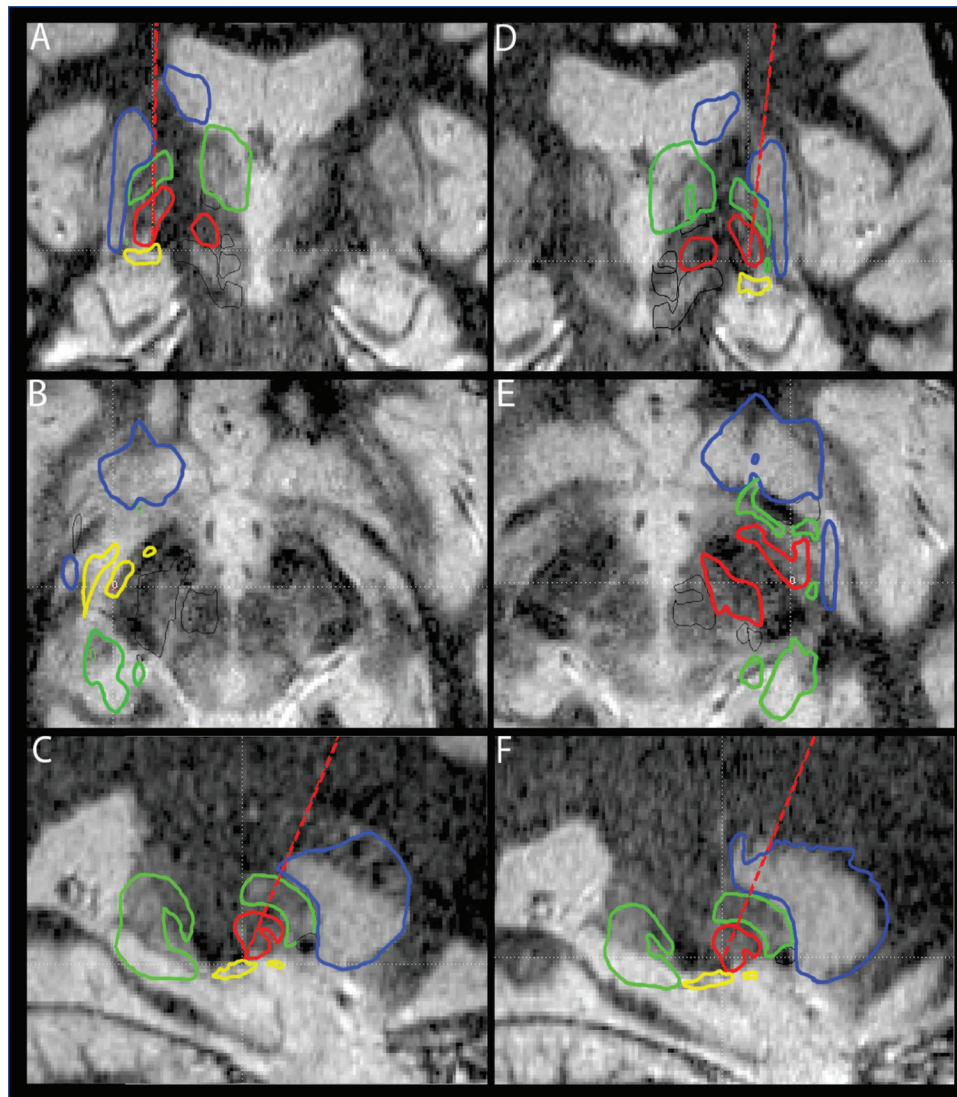
**Video 1. Pre and Post DBS Video Illustration. Segment 1.** This video illustrates the task-specific cervical dystonia manifested during swinging golf task. Dystonia manifests as sudden turning of head to the right with slight upward movement. **Segment 2.** This segment illustrates the remarkable improvement reported by the patient in about 6 months after surgery and programming. The patient is now able to resume competitive golf activities.

could alleviate his symptoms. Given the persistence of disabling symptoms manifesting only during golf, he eventually quit playing competitive tournaments (PGA tournaments). Subsequently, based on the recommendations of an interdisciplinary team evaluation, he underwent bilateral globus pallidus internus (GPi) DBS surgery. DBS leads were stereotactically implanted in the ventroposterolateral GPi and were localized with magnetic resonance imaging (MRI) and microelectrode mapping. A quadripolar electrode (Model 3387; Medtronic, MN) with four contacts numbered 0 (ventral) to 3 (dorsal) for the left side and four contacts numbered 8 (ventral) to 11 (dorsal) for the right side was implanted. The lead location was confirmed on a post-operative computed tomography scan fused with the preoperative MRI scan (Figure 1). Three months postoperatively, he reported significant improvement of approximately 50%, which further improved to 85% following 6 months of optimization in programming (Video 1, Segment 2). He has now been followed at our center for over 18 months and he endorses persistent clinical improvement. The current programming settings are for left GPi: C+2-; voltage 2.6; pulse width 60; frequency 180; and for right GPi: C+10-; voltage 2.6; pulse width 60; frequency 180. Using these settings he has resumed playing competitive golf.

The phenomenology and pathophysiology of task-specific dystonia as well as the phenomenon referred to as “yips” in golfers is not completely understood. Yips have been described to be dystonic in origin.<sup>5</sup> In a study by Adler et al.,<sup>6</sup> co-contraction of wrist flexors and extensors was demonstrated during golf tasks in a large cohort of golfers. Yips in golf traditionally affects only the arm muscles. Our patient had symptoms in the arm muscles and the neck region (predominantly neck). A similar report by Dhungana and Jankovic<sup>7</sup> described a golfer who initially had the arm symptoms described in yips who later developed neck turning during swinging. We believe, as golf requires hand–eye coordination with contemporaneous neck coordination especially during the swinging task, it is not surprising that golfers may sometimes develop symptoms in the neck in addition to the arm muscles.

The social and professional impact of task-specific dystonia on the quality-of-life (QOL) in golfers has not been described before. There are several studies that have reported QOL for dystonia in general; however, the impact in task-specific dystonia has not been well studied. In a large analysis of about 1,000 patients with musician’s dystonia, debilitating symptoms for most affected musicians manifested in the fourth decade of life coinciding with the peak of their career.<sup>8</sup> These musicians could not return to their prior level of performance despite medications and in some cases multiple trials with botulinum toxin injections.

Our report highlights the role of surgical intervention in task-specific dystonia, which has not been well studied. Few small studies on ventro-orals thalamotomy in musician’s dystonia and thalamic stimulation in writer’s cramp have demonstrated promising results.<sup>1</sup> However there is no study to date on DBS for task-specific cervical dystonia or DBS for yips. The remarkable clinical improvement experienced by our patient is encouraging. Further studies will be needed to confirm the therapeutic potential of DBS in medication-refractory task-specific



**Figure 1. MRI Targeting and Atlas Mapping for DBS Lead.** Deep brain stimulation (DBS) leads were stereotactically implanted in the ventroposterolateral globus pallidus (GPi) and were localized with magnetic resonance imaging (MRI) and microelectrode mapping. A quadripolar electrode (Model 3387; Medtronic, MN) with four contacts numbered 0 (ventral) to 3 (dorsal) for the left side and numbered 8 (ventral) to 11 (dorsal) for the right side was implanted. The GPi lead location on postoperative computed tomography was fused with the preoperative MRI scan and measured using Schaltenbrand–Bailey’s stereotactic atlas. We confirmed a well-placed location for the DBS leads on both sides. The coordinates for the tip of the right lead were X 21.06 mm; Y 0.06 mm; Z –5.09 mm; AC–PC angle 65; centerline angle 7. The coordinates for the tip of the left lead were X 21.25 mm; Y –0.64 mm; Z –3.17 mm; anterior commissure–posterior commissure (AC–PC) angle 65; centerline angle 1. Brain MRI T2 sequence coronal (A), axial (B), and sagittal (C) views of right GPi lead location. Brain MRI T2 sequence coronal (D), axial (E), and sagittal (F) views of left GPi lead location. The red line indicates the lead trajectory. Outlines of the atlas: blue, caudate nucleus; red, globus pallidus internus; lateral green, globus pallidus externus; internal green, thalamus; yellow, optic tract.

dystonia. Future tractography studies are also needed to identify the fiber tracts that respond to DBS and are unique to task-specific dystonia to better understand the pathophysiology. This improved understanding in turn will contribute to better therapies for task specific dystonia.

#### Acknowledgments

We would like to thank NIH K23 NS092957-01A1 (AWS) and Tyler’s Hope Foundation for Dystonia Cure.

#### References

1. Torres-Russotto D, Perlmutter JS. Task-specific dystonias: a review. *Ann NY Acad Sci* 2008;1142:179–199. doi: 10.1196/annals.1444.012
2. Hogg E, Tagliati M. Overuse cervical dystonia: a case report and literature review. *Tremor Other Hyperkinet Mov* 2016;6. doi: 10.7916/D8959HR1
3. Wright RA, Ahlskog JE. Focal shoulder-elevation dystonia. *Mov Disord* 2000;15:709–713. doi: 10.1002/1531-8257(200007)15:4<709::AID-MDS1017>3.0.CO;2-4

4. Schramm A, Naumann M, Reiners K, Classen J. Task-specific craniocervical dystonia. *Mov Disord* 2008;23:1041–1043. doi: 10.1002/mds.22006
5. McDaniel KD, Cummings JL, Shain S. The “yips”: a focal dystonia of golfers. *Neurology* 1989;39(Pt 1):192–195. doi: 10.1212/WNL.39.2.192
6. Adler CH, Crews D, Hentz JG, Smith AM, Caviness JN. Abnormal co-contraction in yips-affected but not unaffected golfers: evidence for focal dystonia. *Neurology* 2005;64:1813–1814. doi: 10.1212/01.WNL.0000162024.05514.03
7. Dhungana S, Jankovic J. Yips and other movement disorders in golfers. *Mov Disord* 2013;28:576–581. doi: 10.1002/mds.25442
8. Conti AM, Pullman S, Frucht SJ. The hand that has forgotten its cunning—lessons from musicians’ hand dystonia. *Mov Disord* 2008;23:1398–1406. doi: 10.1002/mds.21976