


Evaluation of Cannula Safety in Injection of Poly-L-Lactic Acid

Andreas Nikolis ^{1,2}
Luiz E Avelar^{3,4}
Kaitlyn M Enright²

¹Division of Plastic Surgery, McGill University Health Center, Montreal, QC, Canada; ²Erevna Innovations Clinical Research Unit, Montreal, QC, Canada; ³Department of Forensic Anthropology, Civil Police Department, Minas Gerais, Brazil; ⁴Private Practice, Belo Horizonte, Brazil

Background and Objective: Poly-L-lactic acid (PLLA) has been used in various medical applications for decades, including aesthetic ones. The use of a cannula technique in injecting PLLA has been proposed in order to lower the incidence rate of adverse events (AEs) following treatment. Such AEs include nodule formation, which may occur less frequently by fanning the product with a cannula, thus creating a more uniform product placement compared to that resulting from the use of a needle. Currently, however, there is a lack of comparative research regarding the safety of cannulas versus needles for PLLA injections, as the selection of either remains highly subjective. Therefore, the objective of our study was to investigate the safety of cannula use in the administration of PLLA, in order to report safety outcomes.

Materials and Methods: A single-center, retrospective chart review was conducted to examine the data of patients who had previously undergone treatment with PLLA in the form of Sculptra[®] Aesthetic[™] in the face and/or neck regions. Twenty-seven subject charts met eligibility. Descriptive data regarding treatment and follow-up visits were collected and analyzed.

Results: A total of seven AEs resulted from eighty-two treatment sessions (8.54%), with 6/27 patients having experienced at least one AE (22.22%). Mild bruising was the most commonly reported AE (57.14%). The majority of the AEs were mild and transient in nature, with one moderate AE being a nodule that was possibly related to a concomitant treatment. All AEs were resolved with follow-up care.

Conclusion: Mild AEs such as bruising, swelling and pain should be expected following the use of a cannula for PLLA injections. However, the incidence rates of AEs following treatment can remain low if proper product preparation and treatment techniques are utilized.

Keywords: poly-L-lactic acid, adverse events, cannula, injection techniques, antiaging

Introduction

Poly-L-lactic acid (PLLA) in the form of Sculptra[®] Aesthetic[™] (Galderma Laboratories, L.P.) is used to increase the volume of depressed areas in the face and various body regions (eg, neck, décolletage, breasts, arms, hands, abdomen, thighs, knees, glutes).¹⁻⁷ The United States Food and Drug Administration approved PLLA in 2004 for the treatment of facial lipoatrophy and in 2009, for the indication of volume loss,^{8,9} although it has been used in various medical applications for longer than three decades (eg, surgical stents and implants).^{8,10} The mechanism of action of PLLA operates mainly through generating a foreign-body reaction. Histological studies support that tissue response to PLLA begins with inflammatory cell infiltration, followed by degradation of the injected material

Correspondence: Andreas Nikolis
Erevna Innovations Clinical Research Unit,
Montreal, QC, Canada
Email anikolis@vicpark.com

and the formation of new collagen in its place.^{11,12} The resulting effect is a decrease in skin laxity and improvement in anatomical contours.^{1,13,14}

Early reports of PLLA use described high rates of nodule formation.^{15,16} Since these early adverse event (AE) reports, multiple authors have described varying techniques to lower the incidence of AEs.¹⁷ For example, increasing dilution during reconstitution and the duration of rehydration prior to injection, as well as performing post-treatment massages, have all been recommended to reduce the likelihood of nodule formation.^{12,18–21} Another method that has been proposed to reduce AEs is the use of a cannula to inject PLLA. In comparison to needles, cannulas are blunt and as such, reduce the likelihood of intravascular injection and cause less tissue damage. This may lead to the occurrence of less AEs, such as bruising and swelling.²² It is also possible that nodule formation may also occur less frequently when fanning the product upon injection, thus creating a more uniform product distribution compared to that resulting from the use of a needle. This opinion is founded on the rationale that when injecting with a cannula, the injector continuously moves the cannula while injecting the total fluid content over a large surface area, in a linear pattern. Conversely, when injecting with a needle, typically an injector will deposit small boluses of product, which may not reflect the same distribution pattern achieved with a cannula. To date however, the use of cannulas to inject PLLA often relies on physician preference and its safety compared to needle is only descriptive and subjective in nature. Therefore, a retrospective review investigating the safety of cannula use in the administration of PLLA would aid in supporting the use of this technique to ensuring a high rate of patient safety.

Objective

The objective of this study was to investigate the safety of PLLA use in the face and/or neck, injected using a cannula technique, for aesthetic indications. The primary endpoint was the incidence of AEs following treatment(s) and final follow-up.

Methods

This study was conducted in accordance with the ethical principles having their origin in the Declaration of Helsinki (2008), “Good Clinical Practice”, the International Council for Harmonization (ICH) Tripartite Guidelines (July 2002) and the applicable laws and

regulations of Canada.^{23–26} This protocol received unconditional approval from an independent research ethics board (Canadian SHIELD Ethics Review Board), which provided a waiver of the informed consent process. The waiver was granted on the basis that, as the population was small, requiring consent may have put the scientific integrity of the study at risk by introducing selection bias. Only non-identifiable information was pulled from the charts and only group data are displayed, to ensure individual subject data confidentiality.

This was a retrospective chart review performed at single Canadian center. All charts of subjects having been treated in the face and/or neck, using a cannula technique and which had at least completed one follow-up visit at the time of this review, were eligible. The charts of men and women who underwent this procedure were evaluated for all demographic and descriptive information, as well as all the below data points. Select data points were transcribed to data extraction forms in preparation for analysis. Data included, but were not limited to:

- Number of treatments conducted
- Length of time between treatment sessions
- Duration of follow-up
- AEs
- Device failures
- Management strategies for adverse events
- AE outcomes
- Subject demographics
- Treatment region(s)
- Treatment volume(s) per visit
- Cannula size and needle introducer size
- Number and location of cannula insertion site(s)

All descriptive data were reported. The program SPSS Statistics (version 20.0) was used for all data analysis.²⁷ Available data regarding all treatment and follow-up visits were collected and analyzed. Inclusion criteria included: 1) Having been treated with PLLA in the face and/or neck, using a cannula technique, for an aesthetic indication; and 2) Having had completed at least one follow-up from the last treatment. There were no implicit exclusion criteria.

The ICH definition of an AE, its severity and causality were used.²⁶ For safety evaluations, an AE was defined as any untoward medical occurrence in a patient administered a medical device, without regard to the possibility of a causal relationship with this treatment. Lack of medical

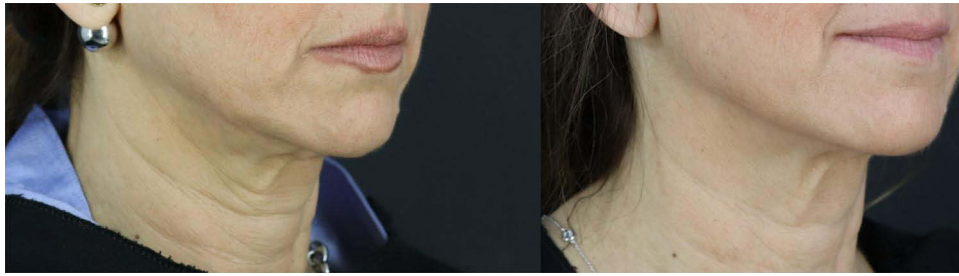


Figure 1 Female subject at baseline (left) and one month following three injections of poly-L-lactic acid in the neck.

device effect was not considered an AE. A physician (leading author) established the causality of the AE to treatment, as being either not related, unknown, possibly related, probably related or related. The intensity of any AE was also determined by the same physician, based on his clinical experience and familiarity with the literature. The severity of an AE was described as either mild, moderate or severe. Furthermore, a serious AE (SAE) was defined as any untoward medical occurrence that: resulted in death, was life-threatening, required inpatient hospitalization or prolongation of existing hospitalization, resulted in persistent or significant disability/incapacity, or resulted in a congenital anomaly/birth defect.

Results

Demographics

In total, the charts of twenty-seven patients met eligibility and were included in the present analyses (Figures 1–3). The large majority of patients treated with PLLA in the face and/or neck were female (24/27; 88.89%) and all were of Caucasian ethnicity. The average age of the population evaluated was 57.68 (SD: 5.36) years. The

demographic profile of the sample reflects the population from which it was selected.

Treatment Information

The twenty-seven patients included in this study underwent a combined total of eighty-two cannula-assisted PLLA treatment visits, between January 2018 and November 2020 (Mean = 3.04; SD: 0.94). There were thirty-five treatment sessions performed in the face only, thirty-one in the neck only, and sixteen in the face and neck (study total: 27 subjects; 82 visits; 98 treatments). Of the patients that received injections in the face, three had a supraperiosteal injection (using cannula), over 3 visits (9 treatment sessions), to enhance volume over the zygomatic bone. For the face, the PLLA powder was reconstituted to a total dilution of 9cc (8cc sterile water + 1cc xylocaine). For the neck, the PLLA powder was reconstituted to a total dilution of 18cc (16cc sterile water + 2cc xylocaine). The reconstituted PLLA was allowed to hydrate for 72 hours before injection and the xylocaine was added immediately prior to injection. The average volume used unilaterally in the facial regions was 3.05 mL per side (SD: 1.02). The average volume used unilaterally, in the neck

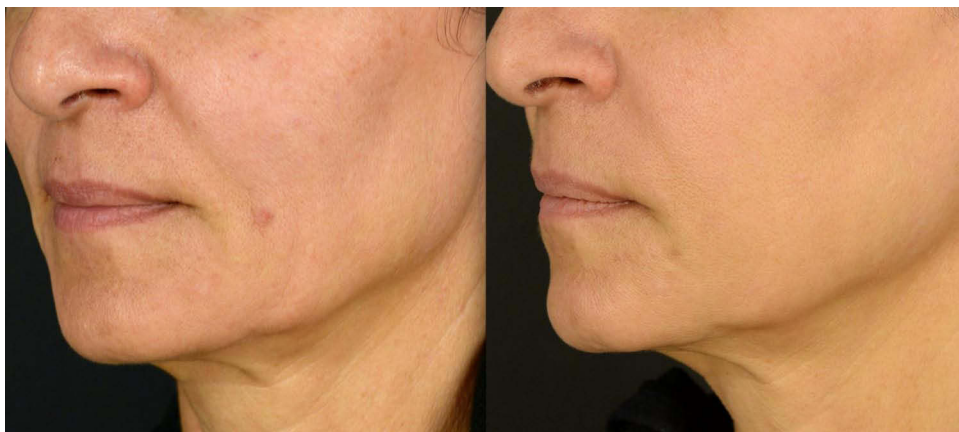

Figure 2 Female subject at baseline (left) and one month following two injections of poly-L-lactic acid in the mid-to-lower face.

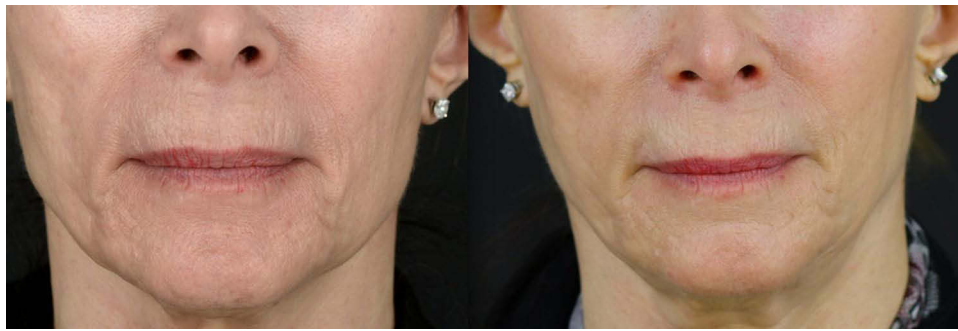

Figure 3 Female subject at baseline (left) and one month following three injections of poly-L-lactic acid in the mid-to-lower face.

regions was 1.67 mL per side (SD: 0.45). Patients underwent an average of 2.90 (SD: 0.83) sessions in the face and 3.10 (SD: 0.89) sessions in the neck. The average duration of time between treatment sessions was 32.33 days (SD: 5.25); the average duration of follow-up from first treatment was 437.76 (SD: 219.69) days; and the average duration of follow-up from last treatment was 365.50 (SD: 193.42) days.

The treatment techniques used for injection of PLLA into the face and neck are depicted in [Figure 4](#). For the face, only the mid-to-lower face was treated. Using a lateral entry point (per side), the face was inserted at the level of the mid-zygoma. For subjects requiring treatment near the chin, insertion was placed near the marionette lines. This provided for a total of 2 or 3 facial insertion sites. For PLLA treatment of the neck, entry points were again performed laterally, per side (total entry points for

the neck: 2). For the face, a 23-gauge needle was used as an introducer to create the entry point and a 25-gauge, 50mm cannula was used for the injections. For the neck, a 23-gauge needle was used as an introducer to create the entry point and either a 25- or 27-gauge, 50mm cannula was used for the injections. Injections were performed using a fanning technique.

AEs/SAEs, Management, Outcomes and Device Failures

In total, information relating to the occurrence of seven AEs were extracted from the patient charts ([Table 1](#)). There were six mild AEs and one moderate AE. Two AEs occurred within the same patient; one after Treatment 1 and one after Treatment 2. Therefore, 6/27 (22.22%) of the sample experienced at least one AE. The

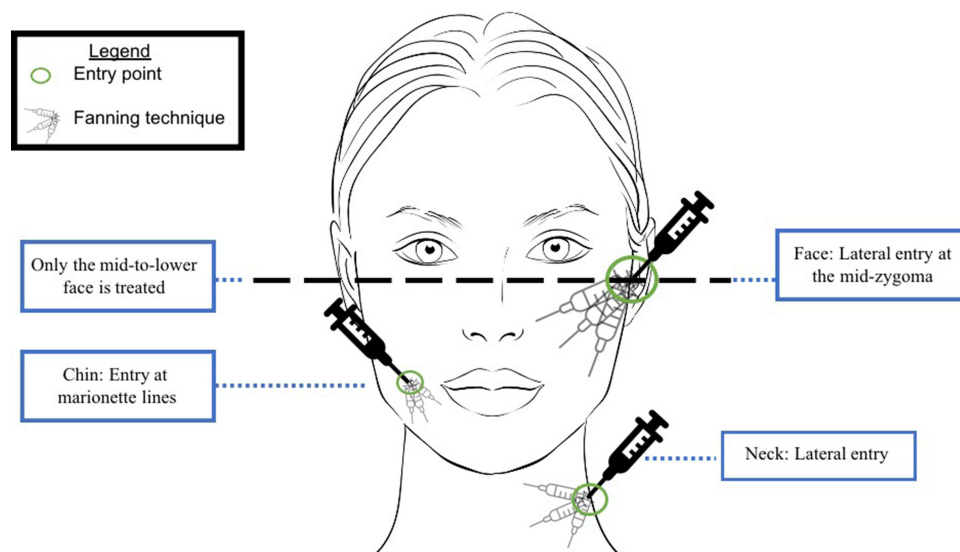


Figure 4 Treatment techniques used for injection of poly-L-lactic acid into the face and neck. Treatment locations can be performed bilaterally and are shown unilaterally for clarity, only.

Table 1 Summary Statistics of the Treatment Areas Assessed in the Present Review and the Corresponding Frequency of Adverse Events (AEs) Following Injection of Poly-L-Lactic Acid in These Regions

Treatment Area	n	Incidence of AEs
Face	51	Bruising = 2/51 (3.92%) Pain = 1/51 (1.96%) Nodule = 1/51 (1.96%)
Neck	47	Bruising = 2/47 (2.13%)
Total	98	7/98 = 7.14%

Notes: Study total = 27 subjects; 82 visits; 98 treatments. Sixteen subjects received treatment in both areas.

AE incidence rate per treatment visit was 7/82 (8.54%). There were no recordings of device failures or SAEs.

The most common AE (4/7 AEs, 57.14%; in 3/27 subjects, 11.11%) was mild bruising, which occurred in the face (n = 2) and neck (n = 2). In patients receiving multiple treatments of PLLA, bruising often occurred only after a single treatment, was equally as likely to occur in either treatment and was noted both uni- and bilaterally. Therefore, the likelihood of- and pattern of bruising appears

to be somewhat unpredictable. To reduce the duration of some bruises, two patients underwent one treatment session each of a pulsed-dye laser. These patients had complete resolution of their bruises within fourteen days.

Another subject presented to her first follow-up visit, following her first PLLA treatment to the neck region, with mild but persisting, uniform swelling. The physician gently but firmly massaged the area, which displayed immediate improvement. The physician instructed the patient to continue massaging the area using a similar technique, five times each day, for the next five days. The swelling was completely resolved by the time the patient came back to the physician's office the following week.

Another subject self-reported pain lasting for 4–6 days following her PLLA treatment. However, as this AE was only haphazardly reported to staff approximately five months after the event, no treatment or management strategy was deployed. The AE resolved spontaneously, and the subject continued to undergo further PLLA treatments following this event.

Lastly, the chart review revealed one moderate AE presenting in a subject. This AE consisted of a single

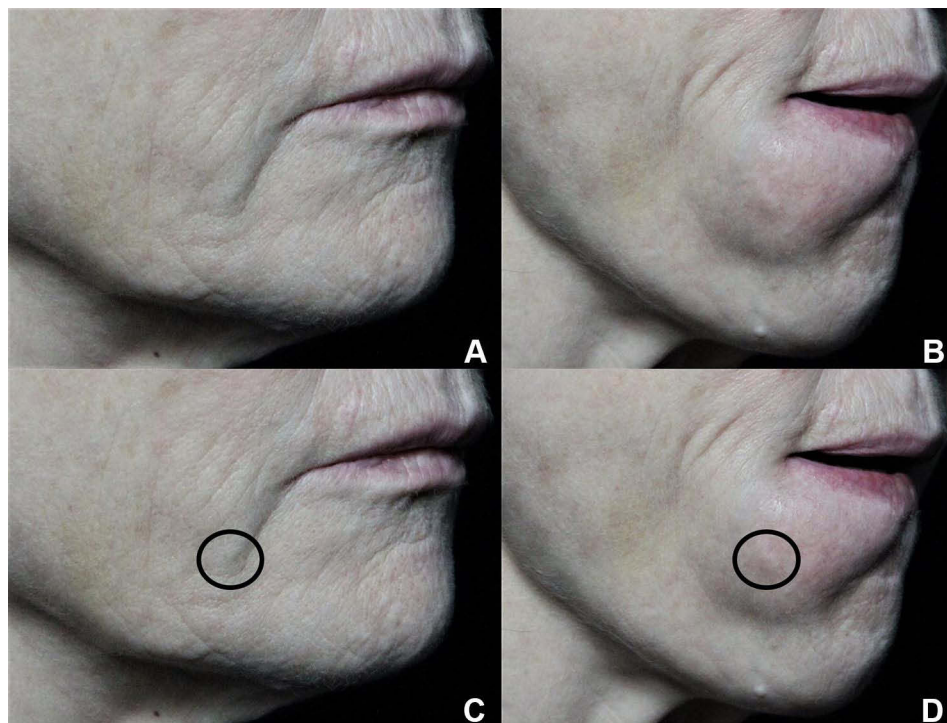


Figure 5 Female subject presenting with a nodule in her right marionette line. The nodule was identified following three rejuvenating treatments with poly-L-lactic acid injections. Each treatment was spaced one month apart and the nodule was identified sixteen weeks following the first treatment. The nodule was treated with 0.1 mL of intralesional glucocorticoid (Kenalog-10) and completely resolved.

Notes: (A and B) display raw images; (C and D) highlight the location of the nodule; (A and C) display subject at rest; (B and D) display subject emphasizing the nodule by pushing on her inner cheek with her tongue.

nodule which presented in the area of the patient's right marionette line (Figure 5). The appearance of this nodule followed the present course: Baseline (PLLA treatment 1); Week 4 (PLLA treatment 2); [Tissue biopsy between treatment 2 and 3]; Week 12 (PLLA treatment 3); Week 16 (PLLA follow-up 1): Nodule identified and treated intralesionally with 0.1mL glucocorticoid (Kenalog-10); Week 20 (PLLA follow-up 2): Nodule resolved. In this case, the nodule appeared sixteen weeks after the initial PLLA treatment. Of note, in between Treatments 2 and 3, this patient underwent a tissue biopsy in the gingiva-buccal space, at the discretion of her dentist for reasons unrelated to the aesthetic treatment. Following the biopsy, the patient developed a nodule 3mm away from the biopsy site. She also developed a 4mm by 2mm hypertrophic scar in the area of the biopsy. Due to the nodule formation in an area proximal to where the PLLA was injected and its temporal appearance in relation to the timing of the treatment sessions, it is probable that the nodule was a result of the biopsy and PLLA injections synergistically. The nodule completely resolved after treatment with a single intralesional steroid injection. Interestingly, the thickness of the biopsy scar also improved following injection of the nodule.

Discussion

In this study, AEs related to the injection procedure itself (ie, bruising, swelling and pain) were all mild and transient in nature. Although they would have likely resolved on their own, for patient ease and comfort, we treated some of the AEs still presenting at follow-up with various commonly used management strategies. For example, using pulsed-dye laser to quicken the resolution of a bruise or massaging the areas displaying persistent swelling. It is important to note that these mild AEs are expected, reported in the product monograph and well documented in the literature surrounding aesthetic injectable procedures. Furthermore, the likelihood of bruising is generally considered lower given the lack of multiple entry points that a needle technique would require. Therefore, there is nothing remarkable about their occurrence nor anything particularly unique about their management strategies, if required, as they have been well described previously.^{28,29}

As per the ICH definition, the one AE determined to be "probably" related to the PLLA treatment itself was a nodule.²⁶ The affected region and temporal relationship of the onset of this AE, relative to the treatment sessions, was reasonable and followed a known response pattern to

the treatment of PLLA.^{15,16} However, given this specific patient's medical history, the biopsy itself is likely a significant contributing factor.

Most recently, researchers have re-investigated the safety of immediate reconstitution and injection of PLLA for facial biostimulation. Despite previous literature declaring that longer hydration times were necessary to reduce the risk of AEs, especially nodule formation, these authors claimed to have demonstrated the safety of immediate injection with recently reconstituted PLLA.²¹ Their conclusion was founded on the following incidence rates of AEs, based on the number of patients (N = 26): Pain = 17/26 (65.38%); Bruising = 6/26 (23.08%); Nodule formation = 2/26 (7.70%); and by the following incidence rates based on the number of treatment sessions (N = 58): Pain = 17/58 (29.31%); Bruising = 6/58 (10.34%); Nodule = 2/58 (3.45%). Importantly, our sample demographics, interval between treatment sessions and average number of treatment sessions were similar to the Bravo & Carvalho (2020) study. These authors also used a cannula and fanning injection technique. However, the authors did not describe how information regarding AEs was collected (eg, subject diaries, questionnaire at follow-up visits) and it is unclear if a subject reported an AE, whether this AE indeed did occur after each-of-multiple treatment sessions or only a subset; as the authors appear to combine methods of calculating their incidence rates (ie, by number of patients versus number of treatment sessions). Therefore, this leads to some limitations with their conclusions. Nonetheless, whether calculating the incidence rate by number of patients or treatment sessions, the incidence rates of AEs reported herein [ie, by patients: Pain = 1/27 (3.70%); Bruising = 3/27 (11.11%); Nodule = 1/27 (3.70%); or by treatment session: Pain = 1/82 (1.22%); Bruising = 4/82 (4.88%); Nodule = 1/82 (1.22%)] remain even lower than these authors have recently reported. This finding, in combination with the strong overall literature supporting methods of avoiding AEs with the injection of PLLA (eg, a long duration of reconstitution, post-treatment massages, use of a high dilution), leads us to conclude that the product preparation and treatment methods described herein should continue to be employed.

An important practical matter for clinicians to consider is potential regulatory issues associated with the use of the medical device under consideration. As PLLA was first approved for medical purposes in immune-deficient patients with facial lipoatrophy, the subsequent FDA approval for aesthetic uses in healthy adult patients was

supported by clear evidence of its safety and efficacy.^{8,9} PLLA in the form of Sculptra[®] is currently marketed in more than 20 countries and in the US under the name of Sculptra[®] Aesthetic; and it has not been withdrawn from any marketplace, for any reason.⁹ There are different on-label uses for PLLA, which can vary by country. Despite the fact that clinicians regularly use medical devices in an off-label fashion, a potential future challenge for any off-label use of PLLA (ie, to improve skin quality) would be the lack of support for education and direction for use from the pharmaceutical company, which is often prohibited by federal regulations. For this reason, investigator-initiated investigations, such as the current study, are essential for promoting proper injector education, training and safe off-label use for ensuring optimal outcomes.

Limitations

As this study consisted of a retrospective chart review, there are inherent limitations to the study design. This includes the lack of patient-reported data (eg, satisfaction) and the possibility for missing data, among other factors that may have led to the under-reporting of AEs. Moreover, information regarding subjects' levels of pain during the procedure and satisfaction following treatment were not collected, which may have given reason to further investigate the possible occurrence of an AE. Lastly, a randomized controlled trial evaluating groups treated with needle versus cannula would allow for stronger comparisons.

Conclusion

With appropriate product preparation and treatment strategies, the incidence rates of AEs following the use of cannulas to inject PLLA in the face and/or neck can remain low (ie, 1–5%). The most common AEs following the injection of PLLA in the face and/or neck, using a cannula, include bruising, swelling and pain. Concomitant procedures near areas of PLLA injection should be performed with caution until well after the treatment cycle of PLLA is completed, when appropriate.

Disclosure

Dr Andreas Nikolis reports grants and personal fees from Galderma, Merz and Allergan, outside the submitted work. The authors report no other conflicts of interest in this work.

References

- Kollipara R, Hoss E, Boen M, Alhaddad M, Fabi SG, Randomized A. Split-body, placebo-controlled trial to evaluate the efficacy and safety of poly-L-lactic acid for the treatment of upper knee skin laxity. *Dermatol Surg.* 2020;46(12):1623–1627. doi:10.1097/DSS.0000000000002685
- Wilkerson EC, Goldberg DJ. Poly-L-lactic acid for the improvement of photodamage and rhytids of the décolletage. *J Cosmet Dermatol.* 2018;17(4):606–610. doi:10.1111/jocd.12447
- Durairaj KK, Devgan L, Lee A, et al. Poly-L-lactic acid for gluteal augmentation found to be safe and effective in retrospective clinical review of 60 patients. *Dermatol Surg.* 2020;46(Suppl 1):S46–S53. doi:10.1097/DSS.0000000000002598
- Rendon MI, Cardona LM, Pinzon-Plazas M. Treatment of the aged hand with injectable poly-L-lactic acid. *J Cosmet Laser Ther.* 2010;12(6):284–287. doi:10.3109/14764172.2010.538410
- Sadick NS, Arruda S. The use of poly-L-lactic acid in the abdominal area. *Dermatol Surg.* 2017;43(2):313–315. doi:10.1097/DSS.0000000000000881
- Redaelli A, Forte R. Cosmetic use of polylactic acid: report of 568 patients. *J Cosmet Dermatol.* 2009;8(4):239–248. doi:10.1111/j.1473-2165.2009.00459.x
- Coimbra DD, Amorim AGF. Poly-L-lactic acid in the rejuvenation of the medial and anterior arms. *Surg Cosmet Dermatol.* 2012;4(2):182–185.
- Galderma Laboratories. Sculptra aesthetic injectable poly-L-lactic acid. Instructions for use; 2016. Available from: <https://www.sculptraaesthetic.com/hcp>. Accessed January 14, 2021.
- Vleggaar D, Bauer U. Facial enhancement and the European experience with Sculptra (poly-L-lactic acid). *J Drugs Dermatol.* 2004;3(5):542–547.
- Blasi P. Poly(lactic acid)/poly(lactic-co-glycolic acid)-based micro-particles: an overview. *J Pharm Investig.* 2019;49(4):337–346.
- Lemperle G, Morhenn V, Charrier U. Human histology and persistence of various injectable filler substances for soft tissue augmentation. *Aesthetic Plast Surg.* 2003;27(5):354–366; discussion 367. doi:10.1007/s00266-003-3022-1
- Bartus C, William Hanke C, Daro-Kaftan E. A decade of experience with injectable poly-L-lactic acid: a focus on safety. *Dermatol Surg.* 2013;39(5):698–705. doi:10.1111/dsu.12128
- Mazzucco R, Dal'Forno T, Hexsel D. Poly-L-lactic acid for nonfacial skin laxity. *Dermatol Surg.* 2020;46(Suppl 1):S86–S88. doi:10.1097/DSS.0000000000002390
- Lin MJ, Dubin DP, Khorasani H. Poly-L-lactic acid for minimally invasive gluteal augmentation. *Dermatol Surg.* 2020;46(3):386–394. doi:10.1097/DSS.0000000000001967
- Hamilton DG, Gauthier N, Robertson BF. Late-onset, recurrent facial nodules associated with injection of poly-L-lactic acid. *Dermatol Surg.* 2008;34(1):123–126; discussion 126. doi:10.1097/00042728-200801000-00027
- Vleggaar D, Fitzgerald R, Lorenc ZP. Understanding, avoiding, and treating potential adverse events following the use of injectable poly-L-lactic acid for facial and nonfacial volumization. *J Drugs Dermatol.* 2014;13(4 Suppl):s35–s39.
- Lin MJ, Chu J. Poly-L-lactic acid preinjection aspiration as a safety checkpoint. *Dermatol Surg.* 2020. doi:10.1097/DSS.0000000000002450
- Lowe NJ. Optimizing poly-L-lactic acid use. *J Cosmet Laser Ther.* 2008;10(1):43–46. doi:10.1080/14764170701840074
- Narins RS. Minimizing adverse events associated with poly-L-lactic acid injection. *Dermatol Surg.* 2008;34(Suppl 1):S100–S104. doi:10.1111/j.1524-4725.2008.34250.x
- Schierle CF, Casas LA. Nonsurgical rejuvenation of the aging face with injectable poly-L-lactic acid for restoration of soft tissue volume. *Aesthet Surg J.* 2011;31(1):95–109. doi:10.1177/1090820X10391213

21. Bravo BSF, Carvalho RM. Safety in immediate reconstitution of poly-L-lactic acid for facial biostimulation treatment. *J Cosmet Dermatol*. 2020. doi:10.1111/jocd.13597
22. Kisyova R, Karkhi A, Lalemi C. Using a needle versus cannula: the advantages and disadvantages. *J Aesthet Nurs*. 2020;9:81–83. doi:10.12968/joan.2020.9.2.81
23. Government of Canada. Clinical trial regulations; 2007. Available from: <https://www.canada.ca/en/health-canada/services/science-research/science-advice-decision-making/research-ethics-board/policy-procedures/clinical-trial-regulations-policies-procedures.html>. Accessed January 14, 2021.
24. World Medical Association. World Medical Association declaration of Helsinki: ethical principles for medical research involving human subjects. *JAMA*. 2013;310(20):2191–2194. doi:10.1001/jama.2013.281053
25. Government of Canada. Good clinical practice; 2012. Available from: <https://www.canada.ca/en/health-canada/services/drugs-health-products/compliance-enforcement/good-clinical-practices.html>. Accessed January 14, 2021.
26. European Medicines Agency. ICH topic E6(R1) guidance for good clinical practice; 2002. Available from: https://www.ema.europa.eu/en/documents/scientific-guideline/ich-e6-r1-guideline-good-clinical-practice_en.pdf. Accessed January 14, 2021.
27. IBM Corp. IBM SPSS statistics for windows; 2017. Available from: <https://hadoop.apache.org>. Accessed January 14, 2021.
28. Jeong GJ, Kwon HJ, Park KY, Kim BJ. Pulsed-dye laser as a novel therapeutic approach for post-filler bruises. *Dermatol Ther*. 2018;31(6):e12721. doi:10.1111/dth.12721
29. Lam SM, Azizzadeh B, Graivier M. Injectable poly-L-lactic acid (Sculptra): technical considerations in soft-tissue contouring. *Plast Reconstr Surg*. 2006;118(3 Suppl):55S–63S. doi:10.1097/01.prs.0000234612.20611.5a

Clinical, Cosmetic and Investigational Dermatology

Dovepress

Publish your work in this journal

Clinical, Cosmetic and Investigational Dermatology is an international, peer-reviewed, open access, online journal that focuses on the latest clinical and experimental research in all aspects of skin disease and cosmetic interventions. This journal is indexed on CAS.

The manuscript management system is completely online and includes a very quick and fair peer-review system, which is all easy to use. Visit <http://www.dovepress.com/testimonials.php> to read real quotes from published authors.

Submit your manuscript here: <https://www.dovepress.com/clinical-cosmetic-and-investigational-dermatology-journal>