

Original article

Correlation between the position of the glenoid fossa and condylar translational movement in skeletal Class III mandibular asymmetry patients

Lin Tun Oo,[®] Jun J. Miyamoto[®], Jun-Ichi Takada[®] and Keiji Moriyama[®]

Department of Maxillofacial Orthognathics, Division of Maxillofacial and Neck Reconstruction, Graduate School of Medical and Dental Sciences, Tokyo Medical and Dental University (TMDU), Japan

Correspondence to: Jun J. Miyamoto, Department of Maxillofacial Orthognathics, Graduate School of Medical and Dental Sciences, Tokyo Medical and Dental University (TMDU), 1-5-45 Yushima, Bunkyo-ku, Tokyo 113-8549, Japan. E-mail: mjmort@tmd.ac.jp

Summary

Objectives: Understanding the mechanism of mandibular asymmetry (MA) is important to provide suggestions for occlusal treatment and to know the developmental process of masticatory dysfunction. To investigate the morphological and functional effects on MA, we evaluated the three-dimensional position of the glenoid fossa and its relationship to asymmetrical condylar translational movement.

Methods: In this retrospective study, 50 subjects who previously underwent computed tomography for surgical purposes were divided into MA and control groups according to a menton deviation of at least 4 mm from the mid-sagittal plane. The glenoid fossae positions were evaluated using a three-dimensional analysis program. Condylar translational movements were recorded and measured by computerized axiography on protrusion. Side-to-side asymmetry was measured for each parameter. Asymmetry index value was calculated to assess the correlation between glenoid fossa position and condylar movement. Wilcoxon's signed-ranked test, Mann-Whitney *U*-test, and Spearman's rank correlation were used for the statistical analysis.

Results: In the MA group, glenoid fossa position on the shifted side was significantly inferior and posterior as compared to that on the non-shifted side and of the control group. Condylar path length and sagittal condylar inclination were significantly greater on the shifted side versus non-shifted side, while no significant difference was found in transverse condylar inclination. The asymmetry index of the anterior–posterior glenoid fossa position was significantly correlated with that of condylar path length and bilateral transverse condylar inclination. In the control group, there were no significant correlations among the morphological and functional parameters.

Limitations: This study did not consider muscle activity and disc position, which may affect condylar movement.

Conclusions: Functional asymmetry of condylar translational movements is closely related to asymmetry of glenoid fossa position in MA patients.

Introduction

Facial asymmetry is a relatively common dentofacial characteristic, with a reported prevalence of clinically apparent asymmetry of up to 34 per cent in the orthodontic population (1). Although minor asymmetries are common in the normal human craniofacial complex (2), severe asymmetry of the mandibulofacial structures causes both aesthetic and functional masticatory problems (3). Studies of skeletal and dental asymmetry in patients with mandibular asymmetry (MA) using two-dimensional radiographs, tomography, and three-dimensional (3D) computed tomography (CT) have reported asymmetry of the dental arch (4), condyle and mandible (5), and temporomandibular joint (TMJ) (6, 7).

In MA patients, asymmetry is noted in both the mandible and the glenoid fossa. Glenoid fossa asymmetry be caused by defects in generation, proliferation, migration, and differentiation of cranial neural crest cells (8, 9) or asymmetric growth of the skull base structures (10, 11). These asymmetrical changes in the position of the glenoid fossa displace the mandible and influence the development of MA (9). Therefore, positional asymmetry of the glenoid fossa is an important aetiological factor in the development of MA. Although some studies have investigated the bilateral positional differences of the glenoid fossae in patients with MA (6, 12), the results are controversial.

Understanding the mechanism of MA is indispensable for delineation of a developmental process of masticatory dysfunction as well as for consideration of evidence-based occlusal treatment for MA patients. Masticatory dysfunction associated with MA has been reported; for example, mandibular lateral displacement resulted from using an appliance to produce a lateral functional shift of the mandible, which caused mandibular skeletal asymmetry and glenoid fossa positional changes in rats (13, 14). These studies showed that asymmetrical condylar movements may affect the glenoid fossa position and result in asymmetrical mandibular growth. In fact, in MA patients, tilting of the mandibular hinge axis, which indicates bilateral positional differences in the glenoid fossa, causes asymmetry of condylar rotational movement (15). Additionally, condylar translational movement, which constitutes condylar movement with rotational movement, also indicates asymmetry in MA patients and correlates with mandibular and condylar asymmetry (16, 17). However, there are no studies of the relationship between glenoid fossa position and condylar translational movement in patients with MA.

Studies of asymmetrical masticatory function in patients with MA have reported not only asymmetrical condylar movement but also asymmetrical masticatory muscle activity (18). This asymmetrical masticatory muscle activity improves symmetrically after surgery; however, it may remain even after surgery and may be associated with relapse (19) as an adverse effect of masticatory dysfunction. Meanwhile, asymmetrical condylar translational movements may also remain after surgery, and it has been speculated that asymmetrical glenoid fossa positions may affect residual asymmetrical condylar translational movement (20). Asymmetrical condylar translational movement may be related to the asymmetrical muscle adaptation mentioned above. However, it remains to be confirmed whether postoperative asymmetrical condylar translational movement results from a functional compensation in the anatomical asymmetry of the glenoid fossa, resulting in postoperative relapse of MA. Actually, condylar translational movement might reflect functional dynamic compensation in the anatomical pathology of TMJ (21).

To investigate the morphological and functional effects on MA, we evaluated the 3D position of the glenoid fossa and its relationship to asymmetrical condylar translational movement in patients with MA. This study constitutes fundamental research to clarify the

relationship between asymmetrical condylar movement and postoperative relapse of MA, and future research on this relationship should be planned.

Materials and methods

In this retrospective study, we recruited patients who underwent 3DCT examination for orthognathic surgery purposes. We excluded skeletal Class II patients because glenoid fossa position differs significantly from that of skeletal Class III patients (22). We then selected 50 adult subjects with maxillomandibular sagittal discrepancy (ANB) less than 2 degrees. All subjects had full permanent dentation except for the third molars. Patients with congenital malformation, namely cleft, fracture, rheumatoid arthritis, trismus, TMJ pain, and functional lateral mandibular shift and those taking medications that affect muscle activity or who had undergone orthognathic treatment were excluded. The participants provided fully informed consent as stipulated in the protocol approved by the institutional ethics committee of our university (approval number 731). Oral and functional examinations were performed by three certified orthodontists who were certified by the Japanese Orthodontic Society.

MA was defined as menton deviation of at least 4 mm from the mid-sagittal plane on 3D images (23). The description of the reference planes, including the mid-sagittal plane on 3D images, will be discussed later.

Subjects with a menton deviation at least 4 mm were defined as the MA group ($n = 25$; 14 women, 11 men; unilateral crossbite in 19 patients and 6 patients with no crossbite), while those with a menton deviation of less than 4 mm were defined as the control group ($n = 25$; 14 women, 11 men; unilateral crossbite: 3 patients, bilateral crossbite: 10 patients, and 12 patients with no crossbite).

We performed a power analysis, and the sample size was estimated to be at least 18 in each group (total: 36 patients), for a power calculation of 0.80 and an alpha of 0.05 (G*Power, version 3.1.9.6). The side towards which the menton deviated was defined as the shifted side, while the contralateral side was defined as the non-shifted side.

Although lateral and posteroanterior cephalometric radiographs are used routinely by orthodontists, oral surgeons use CT images of patients with facial deformity for surgical treatment planning. Therefore, we enrolled eligible patients with available CT images for this research. The CT scans were taken using a multi-slice CT unit (SOMATOM PLUS-S; Siemens Japan, Tokyo, Japan) with the following parameters: 3 mm slice thickness, 4 mm/second table speed, 120 kV, and 200 mA. The patients were positioned with the Frankfort horizontal plane (FH plane) perpendicular to the floor and the facial midline coinciding with the long axis of the CT machine. The gantry had 0 degree inclination. The digital imaging and communication in medicine (DICOM) files of the CT images were then reconstructed into 3D images using Sim-plant Pro (version 13; Materialise Dental NV, Leuven, Belgium). The anatomical landmarks were marked directly on the 3D images and were used to construct three reference planes (Table 1). The FH plane was defined as the plane passing through the right and left porions and the mid-point of bilateral orbitals. The sagittal reference plane was defined as the plane perpendicular to the FH plane passing through the mid-point of bilateral orbitals and the mid-point of bilateral foramen spinosa. The coronal reference plane was defined as the plane perpendicular to the FH plane and sagittal reference plane passing through the mid-point of bilateral foramen spinosa (Table 1 and Figure 1).

Table 1. Definitions of anatomical landmarks and reference planes.

Landmark	Definition
Or (infraorbitale)	Most inferior point of the bony orbitale
Mid-Or	Middle point of the bilateral orbitale
Po (porion)	Most superior point of the external auditory meatus
FoS	Centre of the foramen spinosum
Mid-FoS	Middle point of the bilateral foramen spinosa
Gf (glenoid fossa)	Most superior point of the glenoid fossa in relation to the FH plane
Me (menton)	Most inferior mid-point of the symphysis
Reference planes	
Horizontal reference plane (FH plane)	Plane passing through the right and left porion and the middle point of the bilateral orbitale
Sagittal reference plane	Perpendicular to the FH plane and passing through the middle point of the bilateral foramen spinosa and the middle point of the bilateral orbitale
Coronal reference plane	Perpendicular to the FH plane and sagittal reference plane and passing through the mid-point of the bilateral foramen spinosa

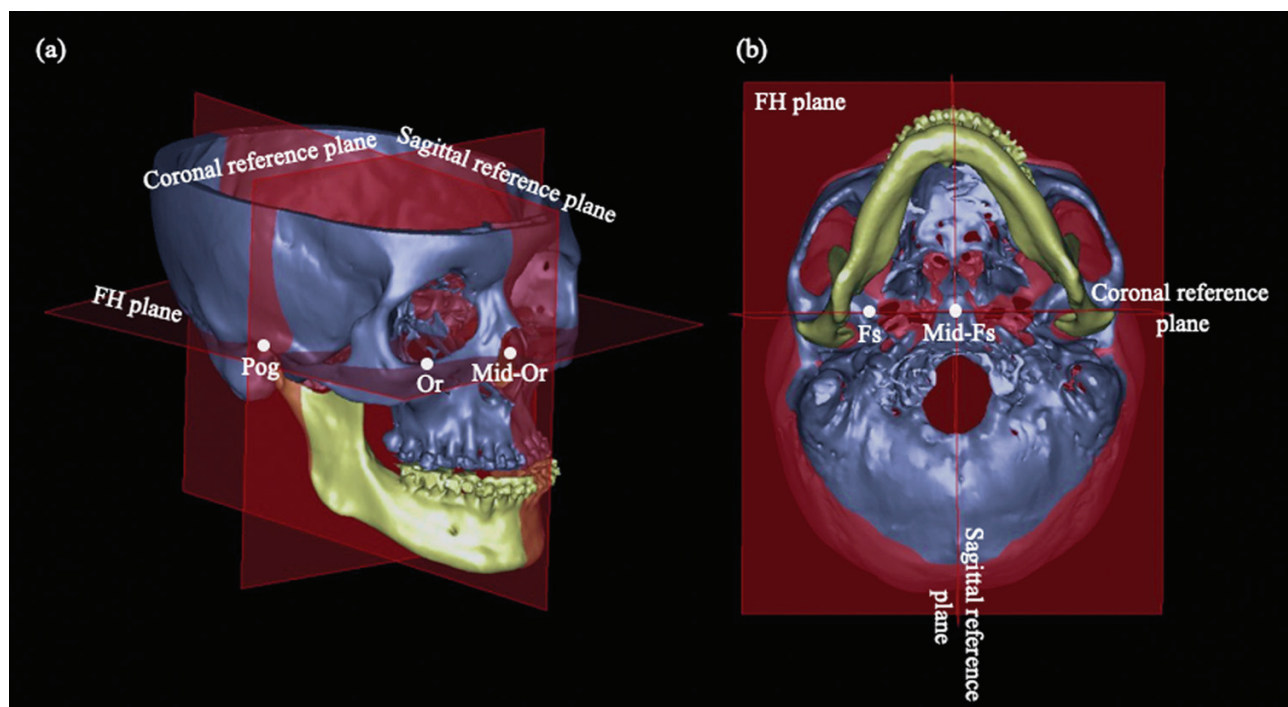


Figure 1. Reference planes and anatomical landmarks used in this study. (a) Frontolateral view and (b) inferior view. FH plane, Frankfort horizontal plane; Or, most inferior point of the bony orbitale; Mid-Or, mid-point of bilateral orbitale; Po, most superior point of the external auditory meatus; FoS, foramen spinosum; Mid-FoS, mid-point of bilateral foramen spinosa.

For the 3D positional assessment, the most superior point of the glenoid fossa in relation to the FH plane was defined as the position of the glenoid fossa (6) (Figure 2). The glenoid fossa superior–inferior position was measured as the distance of the glenoid fossa from the FH plane on each side. The glenoid fossa mediolateral position was measured as the distance from the sagittal reference plane, while the anteroposterior position was defined as the distance from the coronal reference plane on each side. The positions of the glenoid fossae located superior, posterior, and lateral to each respective reference plane were defined as positive values.

To assess functional asymmetry of condylar translational movement, we used a para-occlusal clutch, which was bonded to the labial surface of the lower teeth without interfering with occlusion. Each patient was then instructed to perform maximum voluntary protrusive movements with the teeth in contact, and condylar

translational movement was recorded by computed axiography (CADIAX®; Gamma Dental, Klosterneuburg, Austria). Condylar path length (CPL), sagittal condylar inclination (SCI) in the sagittal plane, and transverse condylar inclination (TCI) in the horizontal plane were measured during these movements (Figure 3). CPL was measured as the shortest linear distance between the reference point and the most translated condylar position in the sagittal plane. SCI and TCI were measured 5 mm from the reference point in the sagittal and horizontal planes, respectively (24). For the angular measurement in the horizontal plane (TCI), deviation towards the shifted side was defined as a negative value, while deviation towards the non-shifted side was defined as a positive value. Each condylar movement parameter was assessed manually using ImageJ software (version 1.45; National Institutes of Health, Bethesda, Maryland, USA).

The side-to-side asymmetry (shifted side versus non-shifted side) in the glenoid fossae 3D positions and the condylar movement were then assessed in both groups. A previous study showed that positional differences in the glenoid fossae do not significantly differ

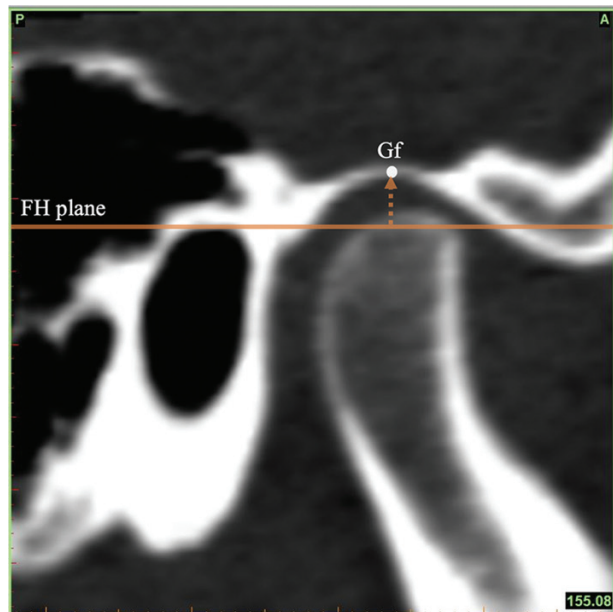


Figure 2. Determining the position of the glenoid fossa. The position of the glenoid fossa (Gf) was defined as the most superior point of the glenoid fossa in relation to the horizontal reference plane. FH plane, Frankfort horizontal plane.

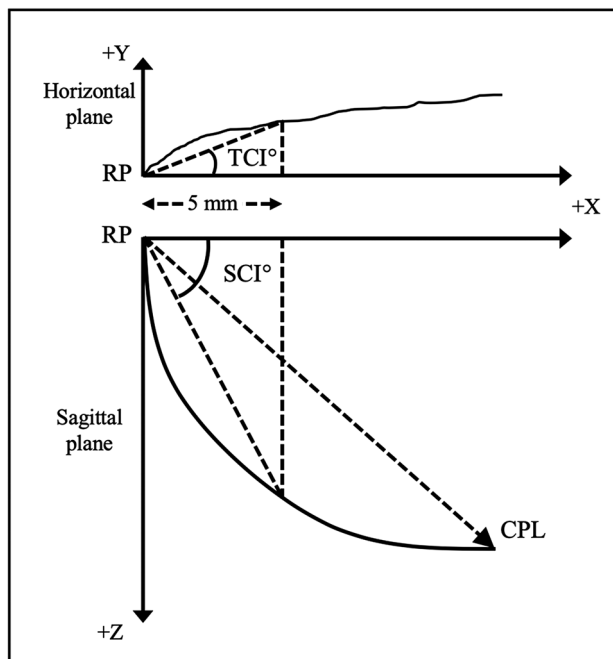


Figure 3. Schematic representation of the condylar path in mandibular protrusive movements and the measurement parameters for condylar path analysis. The condylar path length (CPL) was measured as the shortest linear distance between the reference point (RP) and the most translated position of the condyle in the sagittal plane. Sagittal condylar inclination (SCI) and transverse condylar inclination (TCI) were measured 5 mm from the reference point in the sagittal and horizontal planes, respectively.

bilaterally in patients without facial asymmetry (6). Therefore, we compared the mean value of the two sides in the control group with the values of both the shifted and non-shifted sides in the MA group. Moreover, to overcome the influence of the difference in the sizes of individual faces and to focus on the extent of intersubject asymmetry, the asymmetry index (shifted side – non-shifted side/shifted side + non-shifted side × 100) was used to assess the correlation between the glenoid fossae positions and condylar movements.

Anatomical landmark location and mandibular functional movement measurements were performed by the same investigator to exclude interexaminer errors. To assess the reliability of measurements on the 3D images, the same investigator reanalysed all variables after a 2 week interval. The intraclass correlation coefficients were calculated, and values greater than 0.8 were considered to indicate good reliability.

Statistical analysis

Wilcoxon’s signed-ranked test was used to compare measurements between the shifted and non-shifted sides within each group. The Mann–Whitney *U*-test was used to compare measurements between groups. Spearman’s rank correlation coefficient was used to analyse the correlation between the glenoid fossae 3D positions and condylar movement. All analyses were performed using SPSS version 10.0 (SPSS Inc., Chicago, Illinois, USA), with the level of significance set at *P* < 0.05.

Results

In this study, the intraclass correlation coefficients of the measurements ranged from 0.941 to 0.975, indicating excellent reliability. The patients’ characteristics are provided in Table 2.

The left and middle columns in Table 3 show the glenoid fossae 3D positions on the shifted and non-shifted sides within each group. The glenoid fossae positions in relation to all reference planes in the control group did not differ significantly between the shifted and non-shifted sides. Conversely, in the MA group, the superior–inferior glenoid fossa position was significantly more inferior on the shifted side versus the non-shifted side (*P* = 0.001, *Z* = –3.458), and the anteroposterior glenoid fossa position was significantly more posterior on the shifted side versus the non-shifted side (*P* = 0.001, *Z* = –3.431). The right column of Table 3 shows the mean values of

Table 2. Patient characteristics.

Variable	Mean	SD	Minimum	Maximum
Control group				
Age (years)	21.99	4.65	16.50	34.00
ANB (°)	–3.96	2.24	–8.50	0.00
MPA (°)	33.02	3.92	22.00	38.50
Overjet	–3.58	2.49	–8.50	1.00
Overbite	2.68	2.36	–2.00	7.00
MD (mm)	1.30	1.10	0.10	3.50
MA group				
Age (years)	25.87	6.61	17.58	41.92
ANB (°)	–2.82	2.76	–8.00	1.50
MPA (°)	32.38	3.71	27.00	40.00
Overjet	–2.44	2.72	–8.00	3.00
Overbite	1.67	1.85	–5.50	–2.00
MD (mm)	9.70	4.10	4.10	16.40

SD, standard deviation; MPA, mandibular plane angle; MD, degree of menton deviation.

Table 3. Comparison of the position of glenoid fossa on the shifted and non-shifted sides within each group and between the control and mandibular asymmetry (MA) groups.

Measurement	MA group				Control group				Comparison between MA and control groups				
	SS (1)		nSS (2)		SS (3)		nSS (4)		Mean value of SS and nSS in control group (5)		MA SS versus control (1 versus 5)	MA nSS versus control (2 versus 5)	P-value
	Mean	SD	Mean	SD	Mean	SD	Mean	SD	Mean	SD	P-value	P-value	
Superior-inferior position of the glenoid fossa (mm)	2.13	1.04	2.76	1.27	2.73	0.76	2.78	0.83	2.75	0.69	0.028*	0.634	
Mediolateral position of the glenoid fossa (mm)	49.90	2.80	50.24	2.86	50.21	3.20	49.93	3.19	50.07	3.05	0.786	0.600	
Anteroposterior position of the glenoid fossa (mm)	5.44	2.61	3.56	1.72	3.95	1.92	3.90	1.90	3.92	1.88	0.022*	0.509	

SS, shifted side; nSS, non-shifted side; SD, standard deviation.

* $P < 0.05$.** $P < 0.01$.

the glenoid fossae 3D positions on both sides in the control group and on the shifted and non-shifted sides in the MA group. Compared with the average values of the glenoid fossae 3D positions in the control group, the glenoid fossa on the shifted side in the MA group was significantly more inferior ($P = 0.028$, $U = 199.000$) and significantly more posterior ($P = 0.022$, $U = 194.500$). The glenoid fossa 3D positions on the non-shifted side in the MA group did not differ significantly versus the control group. The results of the comparison of the asymmetry index values of the glenoid fossa position between the control and MA group are provided in the [Supplementary Table 1](#).

[Table 4](#) shows the CPL, SCI, and TCI values. All linear and angular measurements of condylar movement in the control group did not differ significantly between the shifted and non-shifted sides. Conversely, in the MA group, the CPL of the shifted side was significantly longer versus the non-shifted side ($P = 0.003$, $Z = -3.014$), and the SCI was significantly greater on the shifted side versus the non-shifted side ($P = 0.001$, $Z = -3.027$). Although TCI did not differ significantly between the shifted and non-shifted sides in the MA group, TCI for both sides showed negative values, which indicates that both condyles had moved towards the shifted side. The results of the comparison of the asymmetry index values of condylar movement between the control and MA groups are provided in the [Supplementary Table 2](#).

There was a significant positive correlation between the asymmetry index of the glenoid fossa anteroposterior position and the CPL asymmetry index ($P = 0.002$, $r = 0.595$), which indicates that the asymmetry index of the glenoid fossa anteroposterior position increased in tandem with the CPL asymmetry index ([Figure 4](#) and [Table 5](#)).

The asymmetry index of the glenoid fossa anteroposterior position was negatively correlated with TCI on the shifted side ($P = 0.003$, $r = -0.570$) and non-shifted side ($P = 0.005$, $r = -0.543$) in the MA group. In other words, as the asymmetry index of the glenoid fossa anteroposterior position increased, both condyles in the MA group tended to slide towards the shifted side ([Figures 5](#) and [6](#) and [Table 5](#)).

Discussion

In patients with MA, craniofacial asymmetry is affected not only by the asymmetry of the condyle but also by that of the positional asymmetry of the glenoid fossa (6, 9). It is important to unravel the mechanism of MA for precise understanding of the process of asymmetric masticatory dysfunction as well as for consideration of evidence-based occlusal treatment for MA patients. In particular, proving that positional asymmetry of the glenoid fossa is closely related to condylar movement in MA patients could indicate the need for early treatment for asymmetrical condylar movements that result in a functional shift of the mandible.

In a study of the relationship between glenoid fossa morphology and mandibulofacial asymmetry in dry human Lapp skulls, the authors found a significant difference in glenoid fossa position between the 'right side' and 'left side' (12). In contrast, a previous retrospective study using 3DCT reported that patients without MA showed no difference in the glenoid fossae positions between shifted and non-shifted sides (6). The differences between these studies could be related to the comparisons between 'right versus left sides' and 'shifted versus non-shifted sides'. Moreover, evaluation using two-dimensional radiographs and 3DCT with different reference planes may have contributed to the different results between these studies. In the current study, the results for the glenoid

Table 4. Comparison of the condylar movement on the shifted and non-shifted sides in the control and mandibular asymmetry (MA) groups.

Measurement	MA group				P-value	Control group				P-value
	Shifted side		Non-shifted side			Shifted side		Non-shifted side		
	Mean	SD	Mean	SD		Mean	SD	Mean	SD	
CPL (mm)	7.52	3.14	5.52	2.24	0.003**	5.45	2.16	5.60	2.17	0.893
SCI (°)	44.72	8.18	39.03	7.12	0.001**	41.08	8.08	41.91	5.98	0.339
TCI (°)	-2.70	2.29	-2.43	3.82	0.840	-0.48	3.91	0.42	6.55	0.648

CPL, condylar path length; SCI, sagittal condylar inclination; TCI, transverse condylar inclination; SD, standard deviation.

** $P < 0.01$.

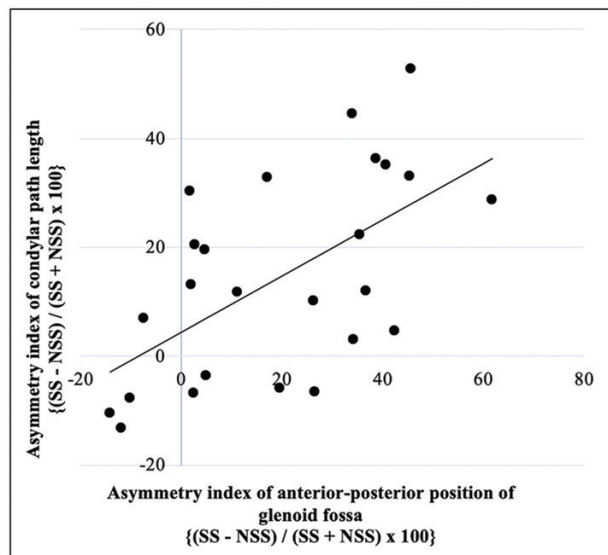


Figure 4. Simple regression analysis of the asymmetry index of the anteroposterior position of the glenoid fossa and the condylar path length in the mandibular asymmetry group. Asymmetry index was calculated as $[(\text{shifted side (SS)} - \text{non-shifted side (nSS)}) / (\text{SS} + \text{nSS})] \times 100$; X-axis, asymmetry index of the anteroposterior position of the glenoid fossa; Y-axis, asymmetry index of the condylar path length.

fossae positions in the control group were concordant with the previous 3DCT study comparing shifted versus non-shifted sides. Based on this result, we used the mean values of the two sides as the control group values when comparing the control group with the MA group.

In patients with MA, the glenoid fossa position on the shifted side deviated significantly posteriorly and inferiorly compared with the non-shifted side in the MA group and the mean value of the two sides in the control group. Similarly, Marianetti *et al.* (25) reported that the glenoid fossa of the non-shifted side is positioned forward and superior versus the shifted side in patients with facial asymmetry, and Kim *et al.* (6) noted that the glenoid fossa on the shifted side is located more inferiorly versus the non-shifted side. These and our findings suggest that the glenoid fossa is affected by MA. Only the glenoid fossa position on the shifted side in the MA group in our study differed significantly versus the control group, in contrast to results in previous studies (6, 25). The differences may relate to different reference systems, grouping methods, and patient selection, e.g. including or excluding skeletal Class II, in whom the position of the glenoid fossa differs to that of other skeletal classifications (22).

There are two possible reasons for glenoid fossa displacement in patients with MA. First, bilateral differences in growth of the cranial base may contribute to positional asymmetry of the glenoid fossae and lead to displacement and compensatory asymmetrical development of the mandible in patients with MA (9–11, 26). Marianetti *et al.* (25) also suggested that glenoid fossae positional asymmetry may represent a missing link between asymmetrical development of the temporal region of the cranial base and the mandible. Second, because the TMJ is a structure that undergoes remodelling throughout life by undergoing regression and progressive changes (27), untreated malocclusion with a posterior crossbite usually persists from childhood into adulthood (28) and leads to asymmetry of both dentation and the skeletal base (29). Thus, displacement of the glenoid fossae positions in patients with MA may also be affected by TMJ adaptive remodelling and functional responses.

Functional assessment of condylar movement was evaluated in patients with MA with no TMJ pain (16, 20) and in patients with no symptoms related to TMJ disorders (30). These studies found that CPL and SCI are longer and steeper on the shifted versus non-shifted side in patients with MA during protrusive (16, 20) and opening movements (17, 30, 31). Similarly, the present study, which excluded patients with TMJ pain, found that CPL was significantly longer, and SCI was significantly greater on the shifted side versus the non-shifted side in the MA group. Moreover, the present study also showed that TCI on both shifted and non-shifted sides showed negative values, which indicates that bilateral condyles tended to move towards the shifted side during protrusive movements. A previous study reported that the condyle on the shifted side tended to move outward during open–close and protrusion–retrusion movements (31). At the same time, condylar movement in the horizontal plane on one side affects the movement of the contralateral side during symmetrical condylar movement (32). Therefore, our TCI results are reasonable.

The anteroposterior position of the glenoid fossa was positively correlated with the CPL asymmetry index in our study, the greater the posterior location of the glenoid fossa on the shifted side, the greater the CPL on the shifted side, in MA patients. A study of the changes in condylar movement before and after orthognathic surgery showed that CPLs during protrusive and maximum mouth open–close movements remained asymmetrical postoperatively. The authors speculated that the condylar path during these movements may be affected by glenoid fossae asymmetry (20). Another study comparing magnetic resonance imaging and computed axiography also suggested that condylar path asymmetry could be due to functional compensation in the anatomical asymmetry of the TMJ (21). In our study, we also found a relationship between CPL asymmetry during protrusive movement and asymmetrical antero-posterior glenoid fossae positions. Therefore, CPL asymmetry may

Table 5. Correlation between the asymmetry index values of the positions of the glenoid fossae and condylar movement in the mandibular asymmetry (MA) group.

Measurement	MA group		Correlation with the CPL asymmetry index (P-value)	Correlation with the SCI asymmetry index (P-value)	Correlation with the TCI SS (P-value)	Correlation with the TCI nSS (P-value)
	Mean	SD				
Asymmetry index of the superior-inferior position of the glenoid fossa	-13.94	14.06	0.870	0.580	0.309	0.110
Asymmetry index of the mediolateral position of the glenoid fossa	-0.33	2.40	0.673	0.571	0.852	0.305
Asymmetry index of the anteroposterior position of the glenoid fossa	19.61	21.37	0.002**	0.751	0.003**	0.005**

Asymmetry index = (shifted side - non-shifted side)/(shifted side + non-shifted side) × 100. SD, standard deviation; CPL, condylar path length; SCI, sagittal condylar inclination; TCI SS, transverse condylar inclination on shifted side; TCI nSS, transverse condylar inclination on non-shifted side. **P < 0.01.

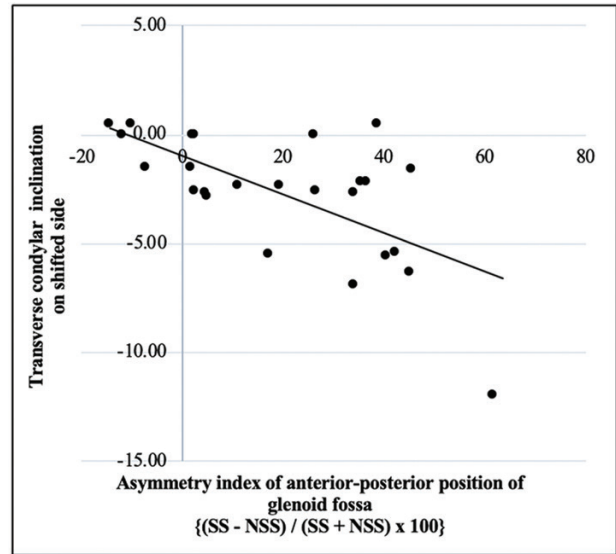


Figure 5. Simple regression analysis of the asymmetry index of the anteroposterior position of the glenoid fossa and the transverse condylar inclination on the shifted side in the mandibular asymmetry group. Asymmetry index was calculated as [shifted side (SS) - non-shifted side (nSS)]/(SS + nSS) × 100; X-axis, asymmetry index of the anteroposterior position of the glenoid fossa; Y-axis, transverse condylar inclination on the shifted side.

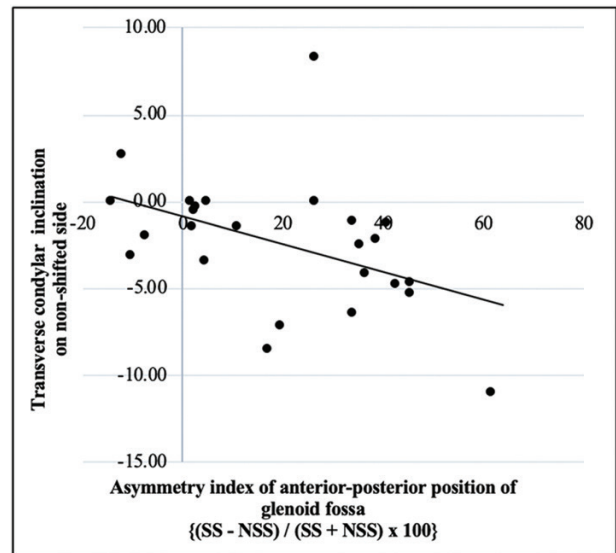


Figure 6. Simple regression analysis of the asymmetry index of the anteroposterior position of the glenoid fossa and the transverse condylar inclination on the non-shifted side in the mandibular asymmetry group. Asymmetry index was calculated as [shifted side (SS) - non-shifted side (nSS)]/(SS + nSS) × 100; X-axis, asymmetry index of the anteroposterior position of the glenoid fossa; Y-axis, transverse condylar inclination on the non-shifted side.

compensate for the glenoid fossae positional asymmetry in patients with MA. The current study also found that bilateral TCI decreased as the asymmetry index of the anteroposterior glenoid fossae positions increased. The condyles slid more towards the shifted side during protrusive movement with increased glenoid fossae positional asymmetry. In addition, increased condylar slide to the shifted side was associated with increased asymmetry of the mandibular volume, as reported previously (16). These results suggest that 3D glenoid

fossae positional asymmetry is closely related to functional asymmetry in patients with MA.

Oh *et al.* (33) suggested that the glenoid fossae contribute less to the amount of chin deviation because the right/left differences in the mandibular condyles have more impact. Simultaneously, the results of a previous study by Ikeda *et al.* (16) and the current study showed that the condyles, mandibles, and glenoid fossae are closely related to masticatory dysfunction of asymmetrical condylar translational movement in MA patients. Therefore, the asymmetrical changes in the glenoid fossa position closely interact with masticatory dysfunction in asymmetrical condylar movements and affect the development of MA. Considering that asymmetrical condylar movement is reported to remain after surgery (20), these asymmetries, with reciprocal relationships, might affect the stability of the treatment; further research is needed.

The current study has limitations. First, we did not evaluate masticatory muscle activity and articular disc position, which may affect condylar movements in MA patients. Second, although mandibular retrognathic patients were excluded in this study, skull base morphology in prognathic patients may differ congenitally from that of normal skeletal patients, which may affect the glenoid fossa position (34). Moreover, the TMJ undergoes lifelong remodelling, and there may be long-term changes in gnathological function, which is also affected by glenoid fossae asymmetry. Therefore, longitudinal observation of both condylar movement and glenoid fossae positions may be necessary.

Conclusion

We evaluated the relationship between the 3D glenoid fossae positions and condylar translational movement. In patients with MA, the glenoid fossae positions were asymmetrical, and this asymmetry was closely related to functional asymmetry of condylar translational movement.

Supplementary material

Supplementary material is available at *European Journal of Orthodontics* online.

Funding

Grants-in-Aid for Scientific Research Projects from the Japan Society for the Promotion of Science (#19H03857, 18K09830).

Acknowledgements

We thank all the members of our department, Tokyo Medical and Dental University, for the helpful comments.

Conflicts of interest

None to declare.

Data availability

The data underlying this article are available.

References

- Severt, T.R. and Proffit, W.R. (1997) The prevalence of facial asymmetry in the dentofacial deformities population at the University of North Carolina. *The International Journal of Adult Orthodontics and Orthognathic Surgery*, 12, 171–176.
- Sanders, D.A., Chandhoke, T.K., Uribe, F.A., Rigali, P.H. and Nanda, R. (2014) Quantification of skeletal asymmetries in normal adolescents: cone-beam computed tomography analysis. *Progress in Orthodontics*, 15, 26.
- Thiesen, G., Gribel, B.F. and Freitas, M.P. (2015) Facial asymmetry: a current review. *Dental Press Journal of Orthodontics*, 20, 110–125.
- Staudt, C.B. and Kiliaridis, S. (2010) Association between mandibular asymmetry and occlusal asymmetry in young adult males with class III malocclusion. *Acta Odontologica Scandinavica*, 68, 131–140.
- You, K.H., Lee, K.J., Lee, S.H. and Baik, H.S. (2010) Three-dimensional computed tomography analysis of mandibular morphology in patients with facial asymmetry and mandibular prognathism. *American Journal of Orthodontics and Dentofacial Orthopedics*, 138, 540.e1–e8; discussion 540.
- Kim, J.Y., Kim, B.J., Park, K.H. and Huh, J.K. (2016) Comparison of volume and position of the temporomandibular joint structures in patients with mandibular asymmetry. *Oral Surgery, Oral Medicine, Oral Pathology and Oral Radiology*, 122, 772–780.
- Kawakami, M., Yamamoto, K., Inoue, M., Kawakami, T., Fujimoto, M. and Kirita, T. (2006) Morphological differences in the temporomandibular joints in asymmetrical prognathism patients. *Orthodontics & Craniofacial Research*, 9, 71–76.
- Minoux, M. and Rijli, F.M. (2010) Molecular mechanisms of cranial neural crest cell migration and patterning in craniofacial development. *Development*, 137, 2605–2621.
- Buitrago, D.F. and Botero, J.R. (2017) Asymmetry of glenoid fossa as differential diagnosis for hemimandibular elongation. *Revista Mexicana de Ortodoncia*, 5, 221–230.
- Kim, S.J., Lee, K.J., Lee, S.H. and Baik, H.S. (2013) Morphologic relationship between the cranial base and the mandible in patients with facial asymmetry and mandibular prognathism. *American Journal of Orthodontics and Dentofacial Orthopedics*, 144, 330–340.
- St John, D., Mulliken, J.B., Kaban, L.B. and Padwa, B.L. (2002) Anthropometric analysis of mandibular asymmetry in infants with deformational posterior plagiocephaly. *Journal of Oral and Maxillofacial Surgery*, 60, 873–877.
- Pirttiniemi, P. and Kantomaa, T. (1992) Relation of glenoid fossa morphology to mandibulofacial asymmetry, studied in dry human Lapp skulls. *Acta Odontologica Scandinavica*, 50, 235–243.
- Liu, C., Kaneko, S. and Soma, K. (2007) Effects of a mandibular lateral shift on the condyle and mandibular bone in growing rats: a morphological and histological study. *The Angle Orthodontist*, 77:787–793.
- Liu, C., Kaneko, S. and Soma, K. (2007) Glenoid fossa responses to mandibular lateral shift in growing rats. *The Angle Orthodontist*, 77, 660–667.
- Takada, J., Miyamoto, J.J., Yokota, T., Ono, T. and Moriyama, K. (2015) Comparison of the mandibular hinge axis in adult patients with facial asymmetry with and without posterior unilateral crossbite. *European Journal of Orthodontics*, 37, 22–27.
- Ikeda, M., Miyamoto, J.J., Takada, J.I. and Moriyama, K. (2017) Association between 3-dimensional mandibular morphology and condylar movement in subjects with mandibular asymmetry. *American Journal of Orthodontics and Dentofacial Orthopedics*, 151, 324–334.
- Mimura, H. and Deguchi, T. (1994) Relationship between sagittal condylar path and the degree of mandibular asymmetry in unilateral crossbite patients. *Cranio*, 12, 161–166.
- Dong, Y., Wang, X.M., Wang, M.Q. and Widmalm, S.E. (2008) Asymmetric muscle function in patients with developmental mandibular asymmetry. *Journal of Oral Rehabilitation*, 35, 27–36.
- Sforza, C., Peretta, R., Grandi, G., Ferronato, G. and Ferrario, V.F. (2008) Soft tissue facial planes and masticatory muscle function in skeletal Class III patients before and after orthognathic surgery treatment. *Journal of Oral and Maxillofacial Surgery*, 66, 691–698.
- Hashimoto, T., Kuroda, S., Lihua, E., Tanimoto, Y., Miyawaki, S. and Takano-Yamamoto, T. (2008) Correlation between craniofacial and con-

- dylar path asymmetry. *Journal of Oral and Maxillofacial Surgery*, 66, 2020–2027.
21. Piancino, M.G., Cirillo, S., Frongia, G., Cena, F., Bracco, A.A., Dalmaso, P. and Bracco, P. (2012) Sensitivity of magnetic resonance imaging and computed axiography in the diagnosis of temporomandibular joint disorders in a selected patient population. *The International Journal of Prosthodontics*, 25, 120–126.
 22. Mengi, A., Sharma, V.P., Tandon, P., Agarwal, A. and Singh, A. (2016) A cephalometric evaluation of the effect of glenoid fossa location on craniofacial morphology. *Journal of Oral Biology and Craniofacial Research*, 6, 204–212.
 23. Baek, S.H., Cho, I.S., Chang, Y.I. and Kim, M.J. (2007) Skeletodental factors affecting chin point deviation in female patients with class III malocclusion and facial asymmetry: a three-dimensional analysis using computed tomography. *Oral Surgery, Oral Medicine, Oral Pathology, Oral Radiology, and Endodontics*, 104, 628–639.
 24. Kato, Y., Motohashi, N., Imamura, N., Nakagawa, F., Kawamoto, T., Ono, T. and Kuroda, T. (2000) Relation between frontal morphology of the facial skeleton and the condylar path in facial asymmetry patients. *The Japanese Journal of Jaw Deformities*, 10, 264–272.
 25. Marianetti, T.M., Marianetti, S., Gasparini, G. and Pelo, S. (2014) Correlation between cranial base morphology and the position of the glenoid fossa in patients with facial asymmetry. *The Journal of Craniofacial Surgery*, 25, 1190–1194.
 26. Sakurai, A., Hirabayashi, S., Sugawara, Y. and Harii, K. (1998) Skeletal analysis of craniofacial asymmetries in plagiocephaly (unilateral coronal synostosis). *Scandinavian Journal of Plastic and Reconstructive Surgery and Hand Surgery*, 32, 81–89.
 27. Hinton, R.J. (1981) Changes in articular eminence morphology with dental function. *American Journal of Physical Anthropology*, 54, 439–455.
 28. Egermark-Eriksson, I., Carlsson, G.E. and Magnusson, T. (1987) A long-term epidemiologic study of the relationship between occlusal factors and mandibular dysfunction in children and adolescents. *Journal of Dental Research*, 66, 67–71.
 29. O'Byrn, B.L., Sadowsky, C., Schneider, B. and BeGole, E.A. (1995) An evaluation of mandibular asymmetry in adults with unilateral posterior crossbite. *American Journal of Orthodontics and Dentofacial Orthopedics*, 107, 394–400.
 30. Oguri, Y., Yamada, K., Fukui, T., Hanada, K. and Kohno, S. (2003) Mandibular movement and frontal craniofacial morphology in orthognathic surgery patients with mandibular deviation and protrusion. *Journal of Oral Rehabilitation*, 30, 392–400.
 31. Ishizaki, K., Suzuki, K., Mito, T., Tanaka, E.M. and Sato, S. (2010) Morphologic, functional, and occlusal characterization of mandibular lateral displacement malocclusion. *American Journal of Orthodontics and Dentofacial Orthopedics*, 137, 454.e1–e9; discussion 454.
 32. Fushima, K., Sato, S., Suzuki, Y. and Kashima, I. (1994) Horizontal condylar path in patients with disk displacement with reduction. *Cranio*, 12, 78–86; discussion 87.
 33. Oh, M.H. and Cho, J.H. (2020) The three-dimensional morphology of mandible and glenoid fossa as contributing factors to menton deviation in facial asymmetry-retrospective study. *Progress in Orthodontics*, 21, 33.
 34. Sanggarnjanavanich, S., Sekiya, T., Nomura, Y., Nakayama, T., Hanada, N. and Nakamura, Y. (2014) Cranial-base morphology in adults with skeletal Class III malocclusion. *American Journal of Orthodontics and Dentofacial Orthopedics*, 146, 82–91.