

Comparison of ranibizumab alone versus ranibizumab with targeted retinal laser for branch retinal vein occlusion with macular edema

Siddhi Goel, Atul Kumar, Raghav D Ravani, Parijat Chandra, Mahesh Chandra, Vinod Kumar

Purpose: To determine the effect of ultra-widefield fluorescein angiography (UWFFA)-guided targeted retinal photocoagulation (TRP) in branch retinal vein occlusion (BRVO) with macular edema after intravitreal Ranibizumab (RBZ). **Methods:** 33 eyes of 32 treatment naïve patients diagnosed as BRVO with macular edema were prospectively randomized to 0.5 mg Ranibizumab only (RBZ group) ($n = 17$) or Ranibizumab with UWFFA-guided laser (RBZ + TRP group) ($n = 16$). Both groups received three injections at monthly intervals and PRN henceforth. RBZ + TRP group additionally underwent UWFFA-guided TRP of peripheral capillary nonperfusion areas 1 week post injection. Outcome measures included improvement in visual acuity, central subfoveal thickness (CST), and the number of injections required with a minimum follow-up of 9 months. **Results:** Both groups showed significant improvement in mean BCVA (25.7 ± 8.19 letters, $P < 0.001$ vs. 23.38 ± 7.56 letters, $P < 0.001$; in RBZ and RBZ + TRP group, respectively) and reduction in mean central subfoveal thickness ($379.12 \pm 242.7 \mu\text{m}$, $P < 0.001$ vs. $253.75 \pm 137.9 \mu\text{m}$, $P < 0.001$ in RBZ and RBZ + TRP group, respectively) at 9 months. The number of injections in the RBZ group (5.76 ± 1.3) was significantly greater than RBZ + TRP (4.06 ± 0.99) ($P < 0.001$). Both groups had significant improvement in contrast sensitivity and mean deviation on visual fields; however, the difference between the groups was not significant ($P = 0.62$ and $P = 0.79$, respectively). **Conclusion:** UWFFA-guided TRP reduced the number of injections of Ranibizumab in patients having BRVO with macular edema, while maintaining similar benefits in the improvement of BCVA, central subfoveal thickness without deleterious effect on the visual field, and contrast sensitivity.

Key words: Anti-vascular endothelial growth factor (anti-VEGF), branch retinal vein occlusion (BRVO), macular edema, targeted retinal photocoagulation (TRP), ultra-widefield fluorescein angiography (UWFFA)

Branch retinal vein occlusion (BRVO) is an obstruction of the major retinal vein that occurs most commonly at an arteriovenous crossing. It occurs due to thrombosis of a branch of the central retinal vein resulting in retinal hemorrhages, cotton wool spots, and varying amounts of retinal nonperfusion in the area drained by the occluded vessel. Macular edema (ME) is the most common cause of vision loss, others being macular ischemia and sequelae of neovascularization such as vitreous hemorrhage, neovascular glaucoma, and tractional retinal detachment.

Vascular endothelial growth factor (VEGF) is considered to play an important role in the pathogenesis of ME with BRVO.^[1] Noma *et al.* demonstrated that aqueous levels of VEGF and IL-6 were significantly elevated in patients of BRVO^[2] compared to controls. A high level of VEGF produced by the ischemic retina exacerbates retinal vascular leakage and neovascularization. Therefore, anti-VEGF drugs play a critical role in the treatment of ME with BRVO. Campochiaro *et al.* demonstrated that intraocular injections of 0.3 mg or 0.5 mg Ranibizumab provided rapid, effective treatment for macular edema following BRVO.^[3,4]

Currently, anti-VEGF is the gold standard treatment for the management of macular edema in vein occlusions, especially

BRVO. However, due to their limited half-life,^[5,6] single injection of anti-VEGF agents provide temporary relief with high chances of recurrence of macular edema and need for repeated injections. This adds on to the economic burden of treatment, increased number of hospital visits apart from the risk of repeated intravitreal injections such as endophthalmitis and retinal detachment. Thus, there is a need for a treatment option that may act as an adjuvant to the current gold standard and help in decreasing the number of injections required.

Ultra-widefield (UWF) imaging (Optos Tx200, Optos Inc.) is capable of capturing a 200° field allowing for a simultaneous view of the posterior pole, mid-periphery, and periphery.^[7] In a study, Wessel *et al.*^[8] demonstrated that UWF angiography detected 3.9 times more areas of capillary nonperfusion (CNP) than conventional angiography in patients with diabetic retinopathy. The peripheral CNP areas in the setting of BRVO can act as a continuous source of VEGF and maybe the potential area of interest as their selective ablation by laser

This is an open access journal, and articles are distributed under the terms of the Creative Commons Attribution-NonCommercial-ShareAlike 4.0 License, which allows others to remix, tweak, and build upon the work non-commercially, as long as appropriate credit is given and the new creations are licensed under the identical terms.

For reprints contact: reprints@medknow.com

Cite this article as: Goel S, Kumar A, Ravani RD, Chandra P, Chandra M, Kumar V. Comparison of ranibizumab alone versus ranibizumab with targeted retinal laser for branch retinal vein occlusion with macular edema. Indian J Ophthalmol 2019;67:1105-8.

Dr. Rajendra Prasad Centre for Ophthalmic Sciences, All India Institute of Medical Sciences (AIIMS), New Delhi, India

Correspondence to: Dr. Raghav D Ravani, Room No. 485, 4th Floor, Dr. Rajendra Prasad, Centre for Ophthalmic Sciences, AIIMS, New Delhi - 110 029, India. E-mail: raghavravani@yahoo.com

Manuscript received: 17.10.18; **Revision accepted:** 07.02.19

Access this article online

Website:

www.ijo.in

DOI:

10.4103/ijo.IJO_1364_18

Quick Response Code:



photocoagulation may reduce the continuous VEGF production and thus reduce the number of treatments with anti-VEGF agents. This concept of targeted retinal photocoagulation (TRP) has shown its utilization in proliferative diabetic retinopathy.^[9] We thus conducted this randomized clinical trial to determine whether targeted laser photocoagulation promotes resolution of macular edema, reduces the need for VEGF antagonists, and improves visual outcomes in patients with BRVO.

Methods

This is a prospective, randomized interventional study conducted at a tertiary eye care center in North India. 33 eyes of 32 patients with BRVO presenting to the retina clinic were enrolled from May 2015 to July 2016. The study was conducted in accordance with the Declarations of Helsinki and informed consent was obtained from all the enrolled participants. Ethical clearance was obtained from the Institute Ethics Committee. The trial was registered with CTRI (CTRI/2018/03/012383).

Patients with decreased visual acuity secondary to BRVO with macular edema were eligible for the study if they had a visual acuity between 20/400 and 20/63 and macular edema with a central subfoveal thickness (CST) greater than 300 μm presenting within 3 months of disease onset. Patients who were pregnant, had uncontrolled hypertension or diabetes, had macular ischemia, had sensitivity to sodium fluorescein, had received prior anti-VEGF injection or scatter laser photocoagulation, or had any other additional ocular diseases that could irreversibly compromise the visual acuity of the study eye were excluded from the study.

Patients underwent a comprehensive ophthalmologic examination that included visual acuity assessment using Early Treatment Diabetic Retinopathy Study (ETDRS) protocol (ETDRS Illuminated Cabinet, Netherlands), intraocular pressure using Goldmann applanation tonometer, slit-lamp biomicroscopy using 90 D, swept-source optical coherence tomography (SS-OCT, DRI Triton, Topcon, Tokyo, Japan), Pelli Robson contrast sensitivity (Pelli-Robson Contrast Sensitivity Chart, Haag-Streit, UK), Humphrey visual fields (30-2 Swedish Interactive Threshold Algorithm; Humphrey Field Analyser Model 750i, Carl Zeiss Meditec Inc., Dublin, California), and UWF fluorescein angiography (UWFFA) using Optos C200MA (Optos Plc, Dunfermline, Scotland). The visual acuity assessors and OCT graders were not masked.

The patients were randomized to 0.5 mg Ranibizumab only (RBZ group) or Ranibizumab with UWFFA (Optos, Optos Inc)-guided TRP (PASCAL laser, RBZ + TRP group). The patients were randomized using sealed envelopes containing allocation to either group. Patients in both groups received three loading injections at monthly intervals. All patients of the RBZ + TRP group additionally underwent UWFFA-guided PASCAL-targeted photocoagulation at 1 week after the first injection. After the first three injections, the patients in both the groups were treated with 0.5 mg Ranibizumab according to pro re nata regimen if visual acuity was $<20/40$ or central subfoveal thickness $>300 \mu\text{m}$. Patients in both the groups were followed-up for a minimum of 9 months.

UWFFA was done at baseline and 9 months for every patient [Fig. 1a]. A single trained optometrist performed it, and areas of CNP were delineated. CST was assessed by

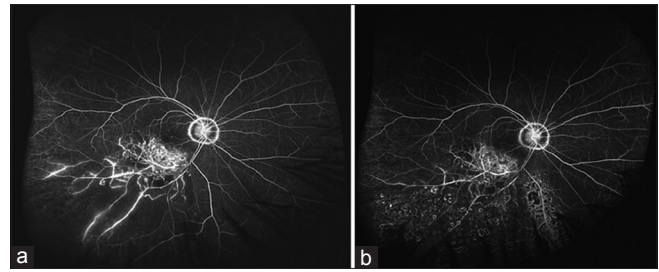


Figure 1: Patient having BRVO with macular edema in RBZ + TRP group. (a) Ultra-widefield angiogram of a patient with inferotemporal BRVO showing peripheral CNP areas. (b) Ultra-widefield angiogram of the same patient following targeted retinal photocoagulation

SS-OCT at each follow-up visit at monthly intervals. In the RBZ + TRP group, TRP of CNP areas was carried out by a single experienced retina specialist on day 7 of the first injection. TRP was carried out using Pattern Scan Laser (PASCAL, Topcon Medical Laser Systems, Santa Clara, CA, USA). Topical 0.5% Proparacaine was used to anesthetize the eyes before the procedure. Topical 0.5% Moxifloxacin was instilled at the end of the procedure. Capillary nonperfusion areas were selectively lasered using PASCAL 4*4 array with 20 ms pulse duration using QuadrAspheric lens (Volk Optical Inc., OH, USA) with a magnification factor of 0.51 and retinal spot size of 200 μm . Laser burns were applied to the CNP areas and at the junction of ischemic and nonischemic areas, extending anteriorly up to ora serrata [Fig. 1b]. The laser spots were placed 1 burn width apart, and the end point of the laser was taken to be moderate gray burns.

The primary outcome parameter was the mean change in best-corrected visual acuity (BCVA) from the baseline at 9 months. The secondary outcome parameters were the mean decrease in central subfoveal thickness as measured on serial SS-OCT scans, number of injections required, change in mean deviation (HVF 30-2 SITA standard), and Pelli Robson contrast sensitivity.

Statistical analysis was performed using Strata (Version 12.1). For pre- and postinjection analysis, paired *t*-test was used to evaluate the changes in CST. For nonparametric data, that is, visual acuity, contrast sensitivity, and mean deviation on visual fields, Wilcoxon signed-rank test was used. For intergroup analysis, two-sample *t*-test was used for parametric data and Mann-Whitney test was done for nonparametric data. *P* values less than 0.05 were considered statistically significant.

Results

A total of 33 eyes were enrolled: 17 were randomized to the RBZ group and 16 to the RBZ + TRP group. Both the groups were comparable in demography and baseline characteristics [Table 1]. In our study, 64% of cases had superotemporal BRVO and 36% had inferotemporal BRVO. Significant improvement in visual acuity was noted in both the groups ($P < 0.001$ in each group). The average gain in ETDRS letters in RBZ group was 25.7 ± 8.2 (95% CI: 21.5–29.9) vs. 23.38 ± 7.6 (95% CI: 19.3–27.4) in the RBZ + TRP group. Both the groups individually had significant improvement in BCVA. However, the intergroup analysis revealed that the difference in gain in BCVA was not significant. ($P = 0.93$) [Fig. 2]. No patients had a loss of more than five letters in our study. Among

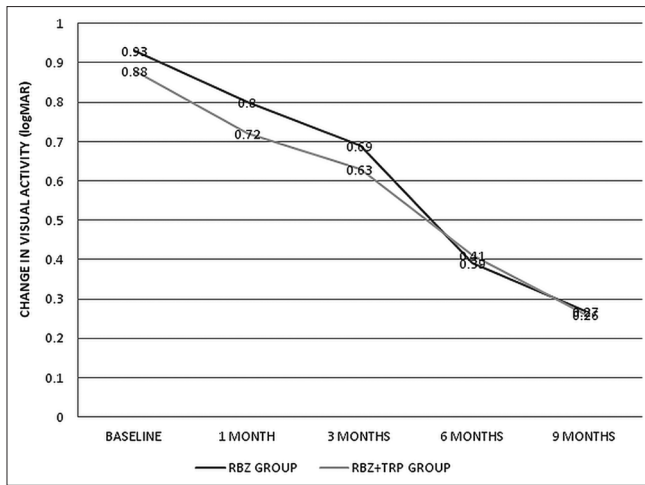


Figure 2: Change in logMAR visual acuity in RBZ group and RBZ + TRP group

Table 1: Demography and baseline characteristics of patients in both the groups (RBZ and RBZ + TRP)

Parameter	RBZ group	RBZ + TRP group	P
Age (years)	55.88±9.21	54.25±9.56	0.86
Males	47%	37%	0.57
Females	53%	63%	0.57
Phakic	88.24%	75%	0.32
Pseudophakic	11.76%	25%	0.32
Diabetes	23.53%	18.75%	0.73
Hypertension	58.82%	87.5%	0.06
Coronary artery disease	5.88%	18.75%	0.33
LogMAR VA (Snellen equivalent)	0.93 (20/170)	0.88 (20/150)	0.59
CST (µm)	631.88	496.69	0.69
IOP (mmHg)	15.41±2.52	15.63 3.28	0.83

the 33 study patients, 26 patients gained more than 15 letters. Similarly, a significant decrease in CST was noted in both the groups ($P < 0.001$ in each group). The mean change in CST in RBZ group was $379.12 \pm 242.7 \mu\text{m}$ (95% CI: 254.3–503.9) vs. $253.75 \mu\text{m} \pm 137.9$ (95% CI: 180.3–327.3) in the RBZ + TRP group; however, the difference between the two groups was not statistically significant. ($P = 0.06$) [Fig. 3]

The number of injections required ranged from 3 to 8 (mean = 5.76 ± 1.3) in RBZ group and from 3 to 6 (mean = 4.06 ± 0.99) in RBZ + TRP group. This difference was statistically significant ($P < 0.001$, Mann–Whitney test). The intraocular pressure (IOP) in both groups showed no significant change from baseline IOP ($P = 0.64$ and $P = 0.177$ respectively).

The baseline mean contrast sensitivity was 1.2 ± 0.25 in the RBZ group and 1.22 ± 0.27 in the RBZ + TRP group. The contrast sensitivity at 9 months was 1.36 ± 0.20 and 1.4 ± 0.22 in the RBZ and RBZ + TRP groups, respectively. Both the groups had significant improvement in contrast sensitivity ($P < 0.001$ in each group); however, the difference between the two groups was not statistically significant ($P = 0.62$). Patients in both groups demonstrated significant improvement in mean

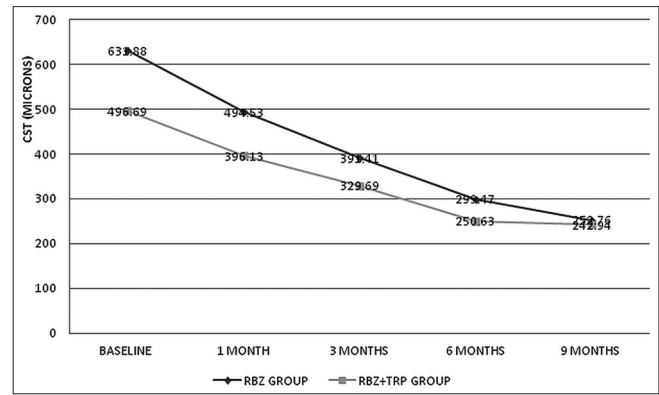


Figure 3: Change in central subfoveal thickness in RBZ group and RBZ + TRP group

deviation on visual fields from baseline ($P = 0.008$ and $P = 0.004$, respectively). None of the patients showed difficulty in fixation during visual field analysis despite macular edema. None of the patients showed disease progression or complications related to laser photocoagulation or intravitreal injection during the study period.

Discussion

VEGF is a potent angiogenic factor produced by Muller cells of the hypoxic retina^[10] due to vascular occlusion-related retinal ischemia leading to increased vascular permeability, leakage, and neovascularization. These factors contribute to macular edema, which is the main cause of visual morbidity in patients with venous occlusions. Anti-VEGF agents are thus, the mainstay for treatment of macular edema following BRVO. However, multiple injections are required to maintain the effect. The need for repeated injections can be explained by the short vitreous half-life of 7.19 days of intravitreal Ranibizumab (Krohne *et al.*).^[6] Studies done by Prasad *et al.* have demonstrated a positive correlation with untreated nonperfusion anterior to the equator with macular edema and neovascularization in cases of RVO.^[11] Thus, untreated areas of retinal nonperfusion may be the source of continuous production of VEGF leading to recurrence of macular edema after intravitreal anti-VEGF injection. Furthermore, the size of retinal nonperfusion is correlated with the severity of macular edema.^[12,13] Thus, we conceptualized this study with the hypothesis that treatment of these target areas of nonperfusion can reduce the production of VEGF and thereby decrease the number of anti-VEGF injections required.

In our study, both groups showed similar improvement in terms of visual acuity (VA) and CST. In addition, contrast sensitivity and visual field sensitivity improved significantly in both groups. We hypothesize that anti-VEGF injections by decreasing the macular edema improves the macular function and thereby increases the contrast sensitivity. As also suggested by Muqit *et al.*,^[9] the improved visual field sensitivity after TRP could be attributed to a reduction in retinal ischemia. The number of injections required was significantly reduced in the group where additional TRP was performed.

Similar results were demonstrated by Tomomatsu *et al.* suggesting that TRP of nonperfusion areas reduced the amount of ME recurrence following intravitreal Bevacizumab

compared to Bevacizumab alone.^[14] However, our study differed in the protocol of treatment, which involved monthly injections for the first 3 months along with laser after the first injection. We used UWFFA that helps to document a larger area of peripheral CNP^[8] that could be targeted with laser. The anti-VEGF used in our study was Ranibizumab, which is approved by the FDA for the treatment of macular edema in BRVO. The RELATE trial,^[15] on contrary, suggested that scatter photocoagulation does not reduce macular edema or treatment burden in patients with retinal vein occlusion. The study differed significantly from our study in the treatment protocol. The laser photocoagulation in the RELATE trial was performed after 6 months of anti-VEGF treatment, while it was performed in our study after the first injection itself. This could affect the number of injections as the greatest number of treatments for macular edema in BRVO are usually done in the first 6 months itself. The RELATE trial did not recruit treatment naïve eyes. Recently, the WAVE study with a sample size of 30 patients on 12 months follow-up demonstrated no added benefit of TRP on treatment burden or visual outcomes in ischemic RVO.^[16] However, a major difference from our study was the inclusion criteria that included patients with CRVO or BRVO demonstrating an incomplete response to previous anti-VEGF treatments. Patients with poor response to anti-VEGF for resolution of macular edema may be attributed to additional inflammatory factors such as IL-6. This may attribute to the difference in WAVE study from our study as we included only treatment-naïve patients with BRVO.

The limitations of our study were a small sample size and a relatively small follow-up period. The area of CNP was not quantified, and there may be a difference in the amount of CNP in the two groups at baseline. In addition, the use of other modalities that can assess the peripheral field to study the development of peripheral scotoma due to TRP will be beneficial. Longer follow-up studies with larger sample size are required to assess the long-term benefit of the added laser to Ranibizumab-treated patients of BRVO.

Conclusion

To conclude, targeted laser photocoagulation of peripheral CNP areas in BRVO with macular edema may decrease the need for repeated anti-VEGF injections and injection-related complications while maintaining similar benefits in visual acuity, contrast sensitivity, and visual fields, especially in treatment-naïve patients. This may bring down the healthcare cost related to management of venous occlusions.

Financial support and sponsorship

Nil.

Conflicts of interest

There are no conflicts of interest.

References

- Campochiaro PA, Hafiz G, Shah SM, Nguyen QD, Ying H, Do DV, *et al.* Ranibizumab for macular edema due to retinal vein occlusions: Implication of VEGF as a critical stimulator. *Mol Ther J Am Soc Gene Ther* 2008;16:791-9.
- Noma H, Minamoto A, Funatsu H, Tsukamoto H, Nakano K, Yamashita H, *et al.* Intravitreal levels of vascular endothelial growth factor and interleukin-6 are correlated with macular edema in branch retinal vein occlusion. *Graefes Arch Clin Exp Ophthalmol* 2006;244:309-15.
- Campochiaro PA, Heier JS, Feiner L, Gray S, Saroj N, Rundle AC, *et al.* Ranibizumab for macular edema following branch retinal vein occlusion: Six-month primary end point results of a phase III study. *Ophthalmology* 2010;117:1102-12.e1.
- Heier JS, Campochiaro PA, Yau L, Li Z, Saroj N, Rubio RG, *et al.* Ranibizumab for macular edema due to retinal vein occlusions: Long-term follow-up in the HORIZON trial. *Ophthalmology* 2012;119:802-9.
- Bakri SJ, Snyder MR, Reid JM, Pulido JS, Ezzat MK, Singh RJ. Pharmacokinetics of intravitreal ranibizumab (Lucentis). *Ophthalmology* 2007;114:2179-82.
- Krohne TU, Liu Z, Holz FG, Meyer CH. Intraocular pharmacokinetics of ranibizumab following a single intravitreal injection in humans. *Am J Ophthalmol* 2012;154:682-6.e2.
- Manivannan A, Plskova J, Farrow A, McKay S, Sharp PF, Forrester JV. Ultra-wide-field fluorescein angiography of the ocular fundus. *Am J Ophthalmol* 2005;140:525-7.
- Wessel MM, Aaker GD, Parlitsis G, Cho M, D'Amico DJ, Kiss S. Ultra-wide-field angiography improves the detection and classification of diabetic retinopathy. *Retina Phila Pa* 2012;32:785-91.
- Muqit MMK, Marcellino GR, Henson DB, Young LB, Patton N, Charles SJ, *et al.* Optos-guided pattern scan laser (Pascal)-targeted retinal photocoagulation in proliferative diabetic retinopathy. *Acta Ophthalmol (Copenh)* 2013;91:251-8.
- Campochiaro PA, Bhisitkul RB, Shapiro H, Rubio RG. Vascular endothelial growth factor promotes progressive retinal nonperfusion in patients with retinal vein occlusion. *Ophthalmology* 2013;120:795-802.
- Prasad PS, Oliver SCN, Coffee RE, Hubschman J-P, Schwartz SD. Ultra wide-field angiographic characteristics of branch retinal and hemispherical retinal vein occlusion. *Ophthalmology* 2010;117:780-4.
- Tan CSH, Chew MCY, Lim LWY, Sadda SR. Advances in retinal imaging for diabetic retinopathy and diabetic macular edema. *Indian J Ophthalmol* 2016;64:76-83.
- Tan CS, Chew MC, van Hemert J, Singer MA, Bell D, Sadda SR. Measuring the precise area of peripheral retinal non-perfusion using ultra-widefield imaging and its correlation with the ischaemic index. *Br J Ophthalmol* 2016;100:235-9.
- Tomomatsu Y, Tomomatsu T, Takamura Y, Gozawa M, Arimura S, Takihara Y, *et al.* Comparative study of combined bevacizumab/targeted photocoagulation vs. bevacizumab alone for macular oedema in ischaemic branch retinal vein occlusions. *Acta Ophthalmol (Copenh)* 2016;94:e225-30.
- Campochiaro PA, Hafiz G, Mir TA, Scott AW, Solomon S, Zimmer-Galler I, *et al.* Scatter Photocoagulation Does Not Reduce Macular Edema or Treatment Burden in Patients with Retinal Vein Occlusion: The RELATE Trial. *Ophthalmology* 2015;122:1426-37.
- Wykoff CC, Ou WC, Wang R, Brown DM, Cone C, Zamora D, *et al.* Peripheral laser for recalcitrant macular edema owing to retinal vein occlusion: The WAVE trial. *Ophthalmology* 2017;124:919-21.