

CASE REPORT

Long-term outcome after surgical repair of a rapid-grown ischemic ventricular aneurysm causing ventricular tachycardia

Daniel Gensler | Jonas Müntze | Peter Nordbeck 

Department of Internal Medicine I
and Comprehensive Heart Failure
Center, University Hospital Würzburg,
Würzburg, Germany

Correspondence

Peter Nordbeck, Department of Internal
Medicine I, University Hospital Würzburg,
Würzburg, Germany.
Email: nordbeck_p@ukw.de

Key Clinical Message

While improved treatment numerically decreased ventricular aneurysms after myocardial infarction, respective cases still represent a clinical challenge due to difficulties in diagnosis, complications like tachycardia, and controversies in state-of-the-art treatment. Our case illustrates good long-term outcome of surgical aneurysmectomy in cases where ventricular geometry can be restored to near-physiological dimensions.

KEYWORDS

aneurysm, cardiac MRI, myocardial infarction, surgical repair

1 | INTRODUCTION

Ventricular aneurysms are among the typical spectrum of complications after myocardial infarction. While improved treatment in general has led to decreasing numbers of ischemic ventricular aneurysms over the last years, respective cases still represent a clinical challenge due to accompanied complications such as ventricular tachycardia, difficulties in diagnosis, and controversies in state-of-the-art treatment. We here report a case illustrating the clinical short- and long-term course of a patient undergoing surgical repair of a rapid-grown left ventricular aneurysm after myocardial infarction.

2 | CASE REPORT

A 56-year-old male patient presented in our clinic with ongoing retrosternal pain for 12 hours. ECG raised suspicion of subacute posterior wall ST-segment elevation myocardial infarction. Coronary angiography revealed complete thrombotic occlusion of the right coronary artery, which was treated by percutaneous recanalization and stent implantation (Figure 1A). Echocardiography 4 days after the procedure demonstrated globally maintained left ventricular

systolic function (LVEF = 50%) with only mild posterior wall hypokinesia. The patient was discharged receiving best medical care. During rehabilitation stay, the patient developed progressive heart failure and repeated ventricular tachycardia. Echocardiography raised suspicion of a ventricular aneurysm. This was confirmed at clinical follow-up 3 months after myocardial infarction. Laevocardiography showed a giant akinetic left ventricular aneurysm resulting in highly reduced ejection fraction of 35% (Movie S1). Cardiac magnetic resonance imaging (CMR) revealed a pronounced ventricular aneurysm with dimensions of 7 × 7 × 8 cm located at the posterior wall of the left ventricle (Figure 1B, Movie S2). It was decided to perform surgical aneurysmectomy with myocardial Dacron patch reconstruction. Because of the ventricular tachycardia, an implantation of an ICD was considered, but was finally rejected.

Nine months after infarction, left ventricular systolic function had returned to values initially found directly after myocardial infarction (LVEF = 50%). CMR confirmed successful surgical removal of the aneurysm (Movie S2) and nearly physiological cardiac function (Figure 1C). Five-year follow-up showed stable general condition of the patient with constant ejection fraction around 50% (Figure 1D, Movie S3) and a NYHA functional class of I.

This is an open access article under the terms of the Creative Commons Attribution-NonCommercial License, which permits use, distribution and reproduction in any medium, provided the original work is properly cited and is not used for commercial purposes.

© 2018 The Authors. *Clinical Case Reports* published by John Wiley & Sons Ltd.

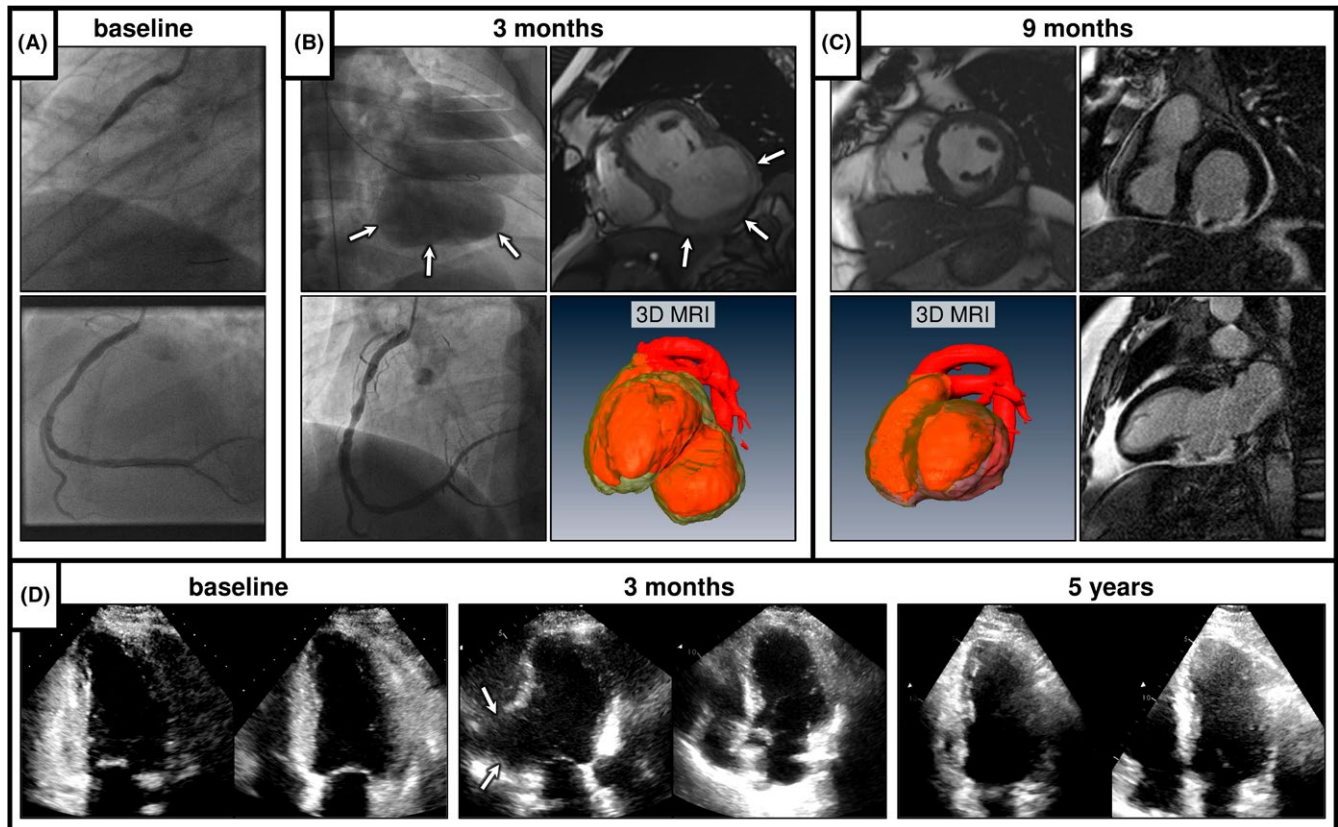


FIGURE 1 A, Coronary angiography showing the right coronary artery before and after intervention. B, Laevocardiography, angiography, and 2D short-axis as well as 3D CMR images showing the ventricular aneurysm. C, CMR after surgical reconstruction of the left ventricle. The 3D model shows successful ventricular repair. Late gadolinium enhancement images reveal the Dacron patch at the basal posterior wall. D, Long-term echocardiographic evaluation of cardiac function. White arrows highlight ventricular aneurysm

3 | DISCUSSION

While surgical repair represents the widely accepted cornerstone in treatment of pseudoaneurysms,¹ surgical reconstruction for treatment of true ventricular aneurysms is much more controversial.² A true aneurysm consists of all parts of the ventricular wall, while a pseudo aneurysm is built only by overlying pericardium.¹ Ventricular arrhythmias can be a consequence of ventricular aneurysms and can be treated via surgical reconstruction.³ The presented case demonstrates clinical survey of a patient initially presenting in our hospital more than 5 years ago, who developed a massive ventricular aneurysm only 3 months after myocardial infarction accompanied by heart failure and ventricular tachycardia. Considering the risk for aneurysm rupture, this underlines the need for a careful follow-up and extended diagnostics if needed in patients who develop heart failure following myocardial infarction. After detailed examinations including 3D imaging reconstruction, the decision for surgical reconstruction was made. Repeated follow-up examinations documented long-term surgical success, with 5-year follow-up examination recently demonstrating stable general condition of the patient

and near-normal ejection fraction. Importantly, despite prior occurrence of ventricular arrhythmia before surgery, it was decided not to implant an ICD due to near-normal morphology after repair. After repair, no further arrhythmia occurred. Of note, just recently several new options for minimally invasive reduction of the left ventricular volume have been introduced, such as the parachute or re-ventricular repair system.⁴ Here in particular, long-term outcomes and accompanying therapeutic options are still unclear, specifically regarding ventricular tachycardia which might be harder to tackle specifically by ablation therapy after interventional repair.

In conclusion, the case presented here is in line with the most recent clinical findings, suggesting generally good outcome of surgical ventricular repair in cases where ventricular geometry can be restored to near-normal physiological dimensions.⁵ Therefore, this therapeutic option should be considered in all respective cases dependent on the anticipated probability of technical success.

CONFLICT OF INTEREST

None declared.

AUTHOR CONTRIBUTION

DG, JM and PN: conceived and designed the study. DG and JM: acquired, analyzed, and interpreted the data. PN: drafted the manuscript and made critical revision.

ORCID

Peter Nordbeck  <https://orcid.org/0000-0002-2560-4068>

REFERENCES

1. Brown SL, Gropler RJ, Harris KM. Distinguishing left ventricular aneurysm from pseudoaneurysm. *Chest*. 1997;111:1403-1409.
2. Jones RH, Velazquez EJ, Michler RE, et al. Coronary bypass surgery with or without surgical ventricular reconstruction. *N Engl J Med*. 2009;360:1705-1717.
3. Ouyang F, Antz M, Deger FT, et al. An underrecognized subepicardial reentrant ventricular tachycardia attributable to left ventricular aneurysm in patients with normal coronary arteriograms. *Circulation*. 2003;107(21):2702-2709.
4. Costa MA, Pencina M, Nikolic S, Engels T, Templin B, Abraham WT. The PARACHUTE IV trial design and rationale: percutaneous

ventricular restoration using the parachute device in patients with ischemic heart failure and dilated left ventricles. *Am Heart J*. 2013;165(4):531-536.

5. Michler RE, Rouleau JL, Al-Khalidi HR, et al. Insights from the STICH trial: Change in left ventricular size after coronary artery bypass grafting with and without surgical ventricular reconstruction. *J Thorac Cardiovasc Surg*. 2013;146:1139-1145. e6.

SUPPORTING INFORMATION

Additional supporting information may be found online in the Supporting Information section at the end of the article.

How to cite this article: Gensler D, Müntze J, Nordbeck P. Long-term outcome after surgical repair of a rapid-grown ischemic ventricular aneurysm causing ventricular tachycardia. *Clin Case Rep*. 2019;7:413–415. <https://doi.org/10.1002/ccr3.1940>