

 **Case Report** 

Successful Surgery of Right Common Iliac Artery Injury during Lumbar Discectomy with Endovascular Balloon Occlusion of the Aorta Performed by Cardiologists

Noriyuki Takashima, MD, PhD,¹ Junghun Lee, MD,¹ Naoshi Minamidate, MD,¹ Takanari Fujita, MD,² Masayuki Yamaji, MD, PhD,² Tomoko Sakaguchi, MD, PhD,² Teruki Takeda, MD,² and Hiroshi Mabuchi, MD²

A 19-year-old woman developed hypotension and abdominal distension during lumbar discectomy. Computed tomography revealed a right common artery injury and a large retroperitoneal hematoma. She was transferred to our hospital and brought to an angiography room directly. Endovascular balloon occlusion of the aorta was performed by cardiologists while surgeons were preparing for surgery. With the hemodynamics stabilized, the injured artery was repaired. In such a case, closing the artery as soon as possible, whether by clamping or by balloon occlusion, is vital. The ability to respond with a “Heart Team” is essential for a small-manpower hospital to rescue a patient with a serious condition.

Keywords: lumbar discectomy, vascular injury, endovascular balloon occlusion

Introduction

A major vascular injury is a rare but life-threatening complication of lumbar discectomy. Types of vascular injury

include laceration, arteriovenous fistula, and pseudoaneurysm.¹⁾ Laceration of the common iliac artery is especially likely to cause hypotension and may even be fatal during or soon after surgery. We present a case of a right common iliac artery injury during lumbar discectomy that was rescued with intra-aortic balloon occlusion and emergency laparotomy thanks to our “Heart Team.”

Case Report


A 19-year-old woman who presented with numbness and pain from L4/5 lumbar herniation was admitted to her local hospital. The patient had undergone discectomy for L4/5 lumbar herniation at age 15. A repeat discectomy was performed. No significant bleeding was seen in the operative field, but the patient developed hypotension, tachycardia, and marked abdominal distension during the operation. Enhanced computed tomography (CT) showed a right common artery injury and a large retroperitoneal hematoma including extravasated contrast (**Fig. 1**). CT also showed a small abdominal aorta (8 mm), iliac arteries (5 mm), and femoral arteries (3 mm).

The patient was then transferred to our hospital and brought directly to an angiography room. Her initial vital sign readings were: blood pressure 60/40 mmHg; pulse rate 130/min; and SpO₂ 99% under general anesthesia with tracheal intubation. The patient had already been given six packs of red blood cells. An introducer sheath (7Fr.) (Glidesheath Slender, Terumo Corporation, Tokyo, Japan) was inserted into the left brachial artery, and a catheter (5Fr.) with a 30 mm occlusion balloon (Nipro Occlusion Catheter, Nipro, Osaka, Japan) was passed into the terminal aorta by cardiologists, about 18 min after the patient’s arrival. After balloon occlusion of the aorta was performed, the patient’s hemodynamics stabilized significantly. During the catheter procedure, surgeons were able to prepare to operate on the patient, check the CT images,

¹Department of Cardiovascular Surgery, Kotoh Memorial Hospital, Higashi-oumi, Shiga, Japan

²Department of Cardiology, Kotoh Memorial Hospital, Higashi-oumi, Shiga, Japan

Received: May 22, 2018; Accepted: October 25, 2018
Corresponding author: Noriyuki Takashima, MD, PhD. Department of Cardiovascular Surgery, Kotoh Memorial Hospital, Hiramatsu-cho, Higashi-oumi, Shiga 527-0134, Japan
Tel: +81-749-45-5000, Fax: +81-749-45-5001
E-mail: ntakashim@gmail.com

 ©2019 The Editorial Committee of Annals of Vascular Diseases. This article is distributed under the terms of the Creative Commons Attribution License, which permits use, distribution, and reproduction in any medium, provided the credit of the original work, a link to the license, and indication of any change are properly given, and the original work is not used for commercial purposes. Remixed or transformed contributions must be distributed under the same license as the original.

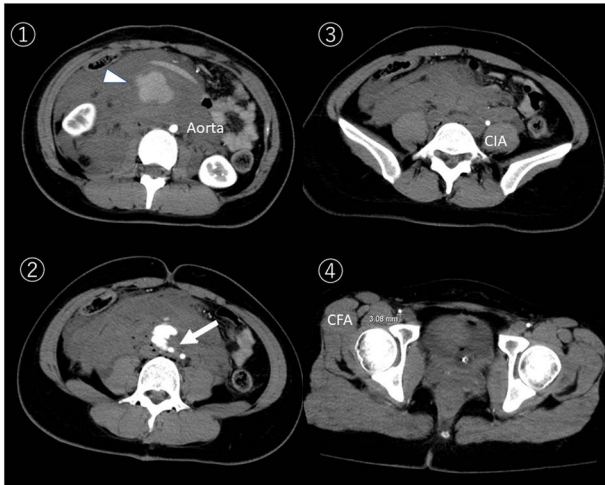


Fig. 1 Preoperative enhanced computed tomography showed a large retroperitoneal hematoma (arrowhead) and extravasated contrast from the right common artery injury (white arrow). The aorta, iliac artery and femoral artery were very small at 8mm, 5mm and 3mm respectively. Photos are numbered from the head side.
CIA: common iliac artery; CFA: common femoral artery

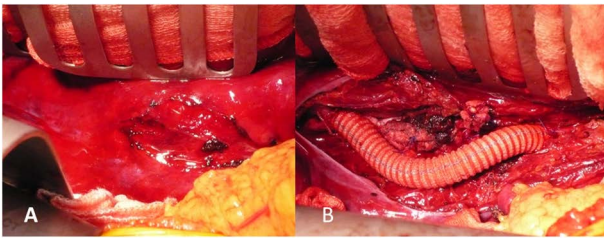


Fig. 2 Emergency laparotomy was performed. No active bleeding was detected because of effective intra-aortic balloon occlusion. (A) Massive retroperitoneal hematoma. (B) Graft interposition was made from the aorta to the right common iliac artery. The operation time was 371 min, the total blood-loss including the hematoma was 1,600ml, and 6 packs of red cell concentrate were transfused.

and obtain informed consent from the patient's family.

An emergency laparotomy was started 48 min after the patient's arrival. A right common iliac artery laceration was detected and repaired by excision. A 9 mm Dacron graft (J-graft, Japan Lifeline, Tokyo, Japan) was interposed between the aorta and the right common iliac artery (Fig. 2).

Although the postoperative course was uneventful, the patient's inflammatory response had been high, so prolonged hospitalization was recommended. The patient was discharged without complication on the 45th postoperative day (Fig. 3). The patient remains in good condition one year later.

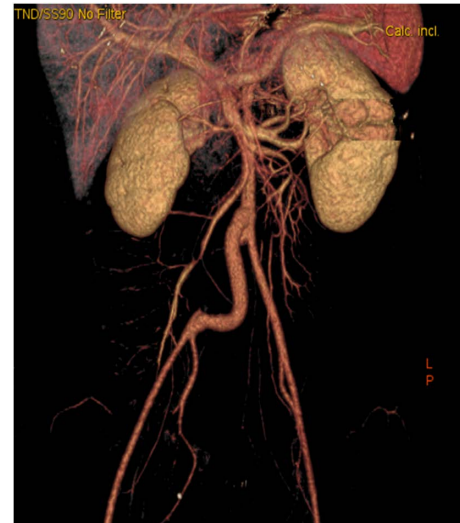

Fig. 3 Postoperative computed tomography with contrast.

Discussion

Vascular complications of lumbar surgery are rare (0.02–0.06%).^{1,2} According to a 1958 survey among spine surgeons in the United States, reported by DeSaussure,³ the incidence has remained the same for 50 years.⁴

Vascular trauma may be classified into three types: (1) laceration; (2) pseudoaneurysm; and (3) arteriovenous fistula. Swift recognition, diagnosis, and surgical repair are essential to save the patient's life. Open surgery is an obvious approach, but it bears a high risk of mortality (5–20%).¹

Endovascular repair is minimally invasive, associated with low morbidity and mortality, and is increasingly preferred when it is feasible.^{5,6} One example of equipment used for endovascular repair is the Viabahn (W. L. Gore & Associates, Flagstaff, AZ, USA); which is a flexible, balloon-expandable stent which is suitable for iliac artery injury repair.

In the present case, however, endovascular repair was inapplicable for several reasons. First, the necessary equipment was not kept on site and had to be fetched from a distant facility, a typical situation among small hospitals in Japan. Second, the femoral arteries were too small to detect during hemorrhagic shock. Third, the femoral arteries and external iliac arteries were too small in diameter to insert endovascular devices. Fourth, because the iliac artery was completely dissected, it was considered highly probable that the catheter would not pass the gap. Finally, the long-term outcomes of endovascular repair for young patients were unknown. Emergency laparotomy is still the best option for patients with unstable vital signs when endovascular repair is not suitable.

The Japanese Society for Vascular Surgery reported that about 60% of abdominal aorta-iliac artery trauma

was iatrogenic, and the hospital mortality rate was as high as 15%.⁷⁾ Bleeding control is a critical strategy in the management of arterial injury or rupture cases. Although aortic occlusion is a standard first step to minimize blood loss, open aortic cross-clamping remains controversial in critical settings because of its complications, including a high mortality rate.⁶⁾ Endovascular balloon occlusion of the aorta has been used as an alternative to open cross-clamping, and it might reduce in-hospital mortality compared with open aortic cross-clamping.⁶⁾ Endovascular balloon occlusion, as Ologun et al. pointed out, “is a minimally invasive technique that can be used as an adjunct to massive transfusion resuscitation and laparotomy for life-threatening intraperitoneal hemorrhage.”⁸⁾ A smaller size of occlusion catheter can be delivered to the aorta either via a femoral artery or a brachial artery. In the present case, the femoral arteries were not palpable and a 7Fr. sheath was too large for the radial artery, so we selected the brachial artery as our access site.

There were only two cardiovascular surgeons in our hospital. The lack of manpower in this emergency could have been problematic, but cardiologists and other staff members helped out in this emergency. This allowed the team to prepare for surgery and to explain the situation to the patient’s family which occurred between the patient’s arrival and the time of operation. This reaffirmed the importance of forming a “Heart Team.”

Conclusion

We presented a case of right common iliac artery injury during lumbar discectomy. After lumbar disc surgery, it is very important to be alert for clinical signs of vascular injuries, to avoid a potentially fatal outcome. Endovascular repair is currently the first choice, but sometimes emergent laparotomy is required, especially in cases of laceration and hypovolemic shock. Immediate endovascular intra-aortic balloon occlusion may be effective for hemodynamic stability, and a “Heart Team” approach, including surgeons, cardiologists and other medical staffs, is essential for a small hospital to respond effectively to such emergency cases.

Acknowledgments

I would like to express my gratitude to the staff members of our hospital. I also thank Dr. Piers Vigers for correcting our English.

Disclosure Statement

All authors have no conflict of interest.

Additional Note

This report was presented at the 46th Annual Meeting of Japanese Society for Vascular Surgery, Yamagata, Japan, May 9–11, 2018.

Author Contributions

Data collection: NT, JL

Writing: NT

Final approval of the article: all authors

Accountability for all aspects of the work: all authors

References

- 1) Papadoulas S, Konstantinou D, Kourea HP, et al. Vascular injury complicating lumbar disc surgery. A systematic review. *Eur J Vasc Endovasc Surg* 2002; **24**: 189-95.
- 2) Erkut B, Ünlü Y, Kaygın MA, et al. Iatrogenic vascular injury during to lumbar disc surgery. *Acta Neurochir (Wien)* 2007; **149**: 511-5; discussion, 516.
- 3) DeSaussure RL. Vascular injury coincident to disc surgery. *J Neurosurg* 1959; **16**: 222-8.
- 4) Inamasu J, Guiot BH. Vascular injury and complication in neurosurgical spine surgery. *Acta Neurochir (Wien)* 2006; **148**: 375-87.
- 5) Canaud L, Hireche K, Joyeux F, et al. Endovascular repair of aorto-iliac artery injuries after lumbar-spine surgery. *Eur J Vasc Endovasc Surg* 2011; **42**: 167-71.
- 6) Abe T, Uchida M, Nagata I, et al. Resuscitative endovascular balloon occlusion of the aorta versus aortic cross clamping among patients with critical trauma: a nationwide cohort study in Japan. *Crit Care* 2016; **20**: 400.
- 7) The Japanese Society for Vascular Surgery Database Management Committee Member, NCD Vascular Surgery Data Analysis Team. *Vascular Surgery in Japan: 2011 Annual Report by the Japanese Society for Vascular Surgery. Ann Vasc Dis* 2018; **11**: 377-97.
- 8) Ologun G, Sharpton K, Granet P. Successful use of resuscitative endovascular balloon occlusion of the aorta in the treatment of ruptured 8.5-cm splenic artery aneurysm. *J Vasc Surg* 2017; **66**: 1873-5.