

Available online at www.sciencedirect.com

ScienceDirect

journal homepage: www.elsevier.com/locate/radcr

Case report

Sonographic evaluation of leprosy of ulnar nerve [☆]Helen Zhao, BS^{a,*}, Pankaj Nepal, MD^a, Syed I Alam, MD^b^a Frank H Netter School of Medicine, Quinnipiac University, CT 06473, USA^b Hamad Medical Corporation, Doha, Qatar

ARTICLE INFO

Article history:

Received 16 January 2021

Revised 1 February 2021

Accepted 3 February 2021

Keywords:

Leprosy

Ulnar nerve

Sonography

Nodular thickening

ABSTRACT

Leprosy is a chronic granulomatous infection caused by *Mycobacterium Leprae* that predominantly affects the skin and peripheral nerves. The disease is prevalent in developing countries of Asia and Africa, with occasional cases reported from United States. In this case report we highlight a 33-year-old man from Qatar, who presented with symptoms of progressive weakness in his left wrist and hand for six months and was later found to have a granuloma of the ulnar nerve secondary to leprosy. We will discuss the etiopathogenesis, clinical features, role of imaging, and management of neuropathy due to leprosy. Our case provides an excellent learning example of the utility of ultrasonography to characterize leprosy granulomas of the ulnar nerve.

© 2021 The Authors. Published by Elsevier Inc. on behalf of University of Washington.

This is an open access article under the CC BY-NC-ND license

[\(http://creativecommons.org/licenses/by-nc-nd/4.0/\)](http://creativecommons.org/licenses/by-nc-nd/4.0/)

Introduction

Leprosy, also known as Hansen disease, is a chronic infection caused by *Mycobacterium leprae* thought to be transmitted via respiratory secretions that predominantly affects the skin and peripheral nerves. *M leprae* grows optimally at approximately 33°C, which explains the disease's predilection for the cooler surfaces of the skin and extremities, as well as its association with armadillos, which have a basal temperature of 34°C. Though armadillos are found in the southwest United States, leprosy is not prevalent in the United States and is more commonly reported in developing countries in Asia and Africa [1]. In 2018, world health organization reported 208,619 new cases of leprosy worldwide, of which the United States accounted for 185 or 0.088% of new cases and Southeast Asia accounted for 148,495 or 71% of new cases [2].

The clinical presentation of Leprosy is varied due to individual immune response, which determines the clinical signs and severity of the disease [1,3,4]. Clinical presentation can be broadly divided into tuberculoid leprosy, which is associated with cell-mediated immunity, a strong T helper type 1 reaction and limited disease progression, while lepromatous leprosy is associated with low cell-mediated immunity, a predominant T helper type 2 responses, and a more severe clinical course [1]. Neuropathy is commonly seen early in the presentation of the disease and first presents as a decrease or loss of sensation. The ulnar, median, radial, common fibular and tibial nerves are most commonly affected. Infection of the peripheral nerves is a hallmark of leprosy but the exact mechanism is poorly understood and thought to be due to a combination of the infection of peripheral nerves by *M Leprae* and the immune response to the pathogen. This neuropathy can lead to neuropathic pain, paralysis, and even deformity

[☆] Competing Interest: The authors declare that they have no conflict of interest.

* Corresponding author.

E-mail address: hrzhao95@gmail.com (H. Zhao).<https://doi.org/10.1016/j.radcr.2021.02.003>1930-0433/© 2021 The Authors. Published by Elsevier Inc. on behalf of University of Washington. This is an open access article under the CC BY-NC-ND license (<http://creativecommons.org/licenses/by-nc-nd/4.0/>)

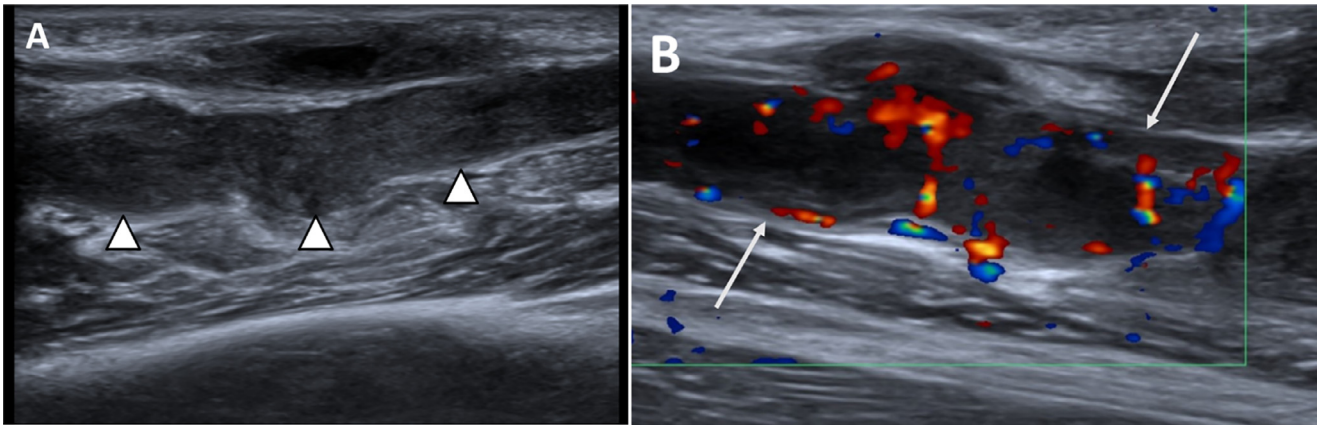


Fig. 1 – Grey-scale (A) and color Doppler ultrasound (B) images of the ulnar nerve in a 33-year-old man with ulnar nerve palsy. (A) Grey-scale ultrasound image shows marked nodular thickening of the ulnar nerve with nodular hypoechoic areas (arrowheads). (B) Color Doppler image of the ulnar nerve shows marked increased vascularity (long white arrows).

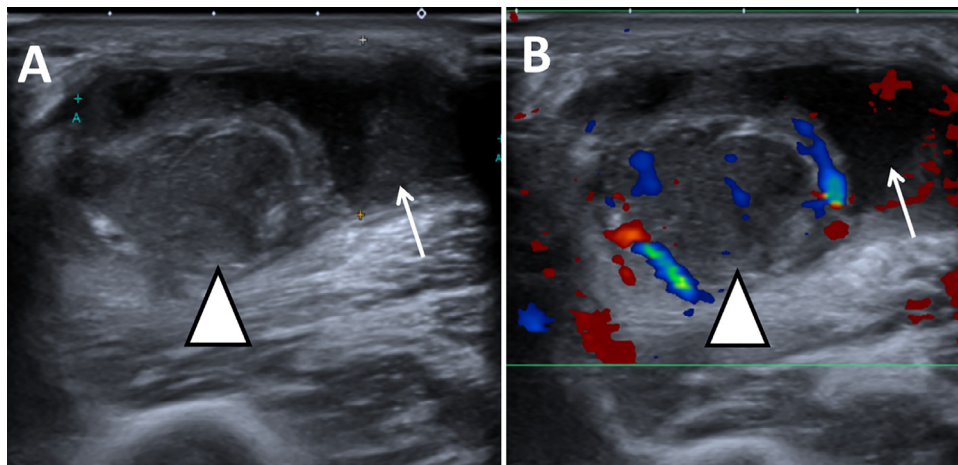


Fig. 2 – Transverse grey-scale (A) and color Doppler sonographic (B) images. (A) Grey-scale ultrasound image shows thickened ulnar nerve measuring 1.1 cm in diameter (arrowhead). There is fluid surrounding the thickened nerve (arrow). (B) Color Doppler image of the transverse section of the thickened ulnar nerve shows increased vascularity (arrowhead).

of the extremities [4]. Other common manifestations of the disease include hypopigmented skin lesions, enlarged peripheral nerves, paresthesia, and late findings include claw fingers, foot drop and facial paralysis [1]. Leprosy can also spread hematogenously, resulting in a multiorgan disease affecting the liver, spleen, cornea, adrenals, and bone marrow [5]. There are many causes of peripheral neuropathy and a good history in combination with physical exam and imaging modalities are useful for narrowing down the differential. In this case report, we demonstrate the utility of ultrasonography in the evaluation of lepromatous ulnar neuropathy.

Case report

A 33-year-old man from Qatar with no significant past medical history presented to orthopedic clinic with symptoms of progressive weakness of left wrist and hand for 6 months. He

also complained of dull aching pain and numbness involving his left medial elbow, forearm, wrist and hand. He denied recent or remote history of trauma. Physical examination was remarkable for hypoesthesia along the ulnar distribution of 4th and 5th digits and dorsum of hand. Motor weakness of fourth and fifth digits was also seen, thus conclusive for ulnar nerve palsy. A cord like structure was palpable on the medial surface of dorsum of forearm which was suspicious for ulnar nerve enlargement. Electrophysiological test supported features of ulnar neuropathy. Ultrasound examination was performed using color Doppler supplementation which showed marked thickening of the ulnar nerve measuring up to 1 cm (Figs. 1A and 2A). Multiple nodular hypoechoic areas were also seen. Hypervascularity was seen on color Doppler evaluation (Figs. 1B and 2B). Intraoperative findings were similar to the ultrasound images. Using electrophysiological monitoring, microscopic dissection of granulomas was performed and nerve fascicles sent for histopathological evaluation (Fig. 3). Nonnecrotizing granulomas with several acid-fast

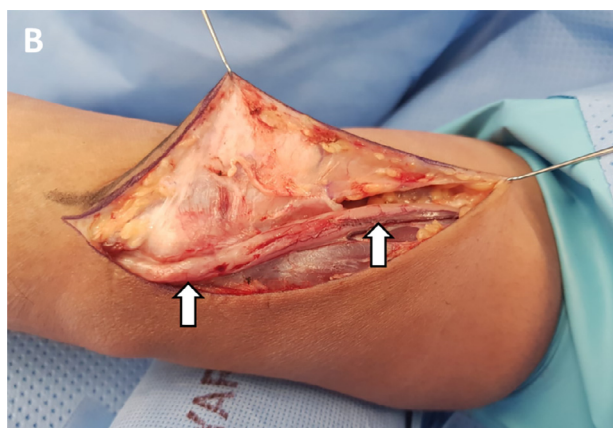


Fig. 3 -- Image obtained during intraoperative microscopic dissection of the granulomas showing cord like thickened ulnar nerve (arrows) correlating with sonographic findings.

bacilli were highlighted by Fite and Ziehl-Neelsen stains compatible with leprosy. The other peripheral nerves such as median, radial, tibial, and peroneal nerves were not involved. Patient was treated with 3-drug regimen including Rifampin, Dapsone and Clofazimine with adjuvant short course of steroid. Patient improved his neurological symptoms in 1-month follow up and scheduled for next visit next month. Peripheral nerve thickening is cardinal feature of leprosy most frequently involving ulnar and common peroneal nerves.

Discussion

Peripheral neuropathy is a hallmark of the disease and motor and autonomic functions may be affected. The most commonly affected nerves are the ulnar, median, radial, common fibular, posterior tibial, and facial nerves [5]. Peripheral neuropathy is a frequently seen condition in the primary care office and is more commonly due to diabetic neuropathy, human immunodeficiency virus - acquired immunodeficiency syndrome neuropathy, vitamin B12 deficiency, drug-induced neurotoxicity, or nerve compression. Other differential diagnoses include amyloidosis, systemic lupus erythematosus, systemic scleroderma, neurofibromatosis, and syringomyelia [5,6]. Since many of the diagnoses on our list of differentials for peripheral neuropathy may present similar clinically, a good history and physical exam will be crucial in narrowing the differential diagnosis. Clinical suspicion for leprosy will be high if the patient is coming from a country where it is endemic and has skin lesions with diminished sensation, and the hallmark feature of the disease and biologic or pathologic samples should be taken for analysis to support clinical diagnoses [1].

Initial assessment of neuropathy in patients may be done with thermal perception testing and nerve palpation. However, these tools are subjective and for more objective assessment we can utilize ultrasonography. Ultrasonography is a useful imaging modality for determining the extent of the neuropathy as well as providing detailed information on localization of focal or entrapment neuropathy, as we demon-

strate in this case report. While it is possible to detect peripheral nerve thickening on physical exam, this is largely subjective and has limited accuracy. Furthermore, there is little evidence to suggest that there is a relationship between nerve morphology and function [7,8]. Ultrasonography allows for objective visualization of peripheral nerves and can detect a greater extent of nerve thickening as compared to clinical assessment [7,9–13]. Ultrasound can provide objective information on nerve cross sectional area, morphological changes, echo texture, and vascularity using color Doppler [14]. In addition, ultrasonography is more commonly used to visualize peripheral nerves, whereas magnetic resonance imaging (MRI) is more typically used to look at nerve roots. Ultrasound, unlike MRI, also has validated scoring-systems to distinguish patterns of nerve enlargement based on structure, anatomy, and fascicular involvement and has demonstrated that nerve size is the most important sonographic parameter in the identification of inflammatory neuropathies. In contrast, only a few retrospective cohort studies have used MRI to identify inflammatory neuropathies and while MRI can produce optimized images of nerves, no objective cut-off values for abnormal diameter exist [7].

Therefore, ultrasonography is the preferred imaging modality for evaluation of peripheral neuropathy due to its standardization, as well as its cost-effectiveness, accessibility, and non-invasiveness [4]. In our case Ultrasound is additionally useful for identifying the extent of neuropathy and guided surgical biopsy. The nodular thickening of the ulnar nerve which demonstrated vascularity on color Doppler was characteristic, and represented lepromatous granulomas. Common differential diagnosis of mass like thickening of the ulnar nerve includes peripheral nerve sheath tumors such as neurofibroma and schwannoma or traumatic neuroma. Peripheral nerve sheath tumors on ultrasound appear as hypoechoic fusiform mass in continuity with the nerve. If clinically worrisome for tumors MRI is helpful, the nerve sheath tumors are isointense on T1 and hyperintense on T-2 weighted images with characteristic “split fat sign.” Traumatic neuromas do not show enhancement on post contrast MRI and demonstrate no vascularity on color Doppler as opposed to tumors or inflammatory neuropathy.

The recommended treatment of leprosy is highly effective multiple-drug therapy (MDT) of rifampin, dapsone, and clofazimine for 6 months in patients with tuberculoid leprosy and 12 months for lepromatous leprosy. Patients with rifampin resistant leprosy may use second line drugs such as fluoroquinolones or clarithromycin but require longer treatment duration of 18-24 months. Skin lesions have been shown to diminish shortly after beginning treatment but may take years to resolve completely. MDT has been shown to be highly effective and useful in preventing resistance so patient compliance to MDT regimen is important and should be emphasized. Patients who have lost sensation should be educated on how to check their extremities for injury and may require special shoes. During treatment, routine lab studies including CMP and urinalysis are required to check for drug toxicity. Upon MDT completion, an annual follow-up for up to 5 years is indicated, depending on severity of disease [9].

Conclusion

In this case report, we highlight the importance and utility of ultrasonography to characterize granulomas of the ulnar nerve secondary to leprosy.

Author contributions

HZ: manuscript writing, PN: manuscript edit, SIA: images contribution.

Dear editor of Radiology Case Reports journal

We present an interesting case of sonographic evaluation of leprosy of ulnar nerve. (Intended for radiology residents, practicing radiologists, abdominal imaging fellows, surgeons, and emergency clinicians).

In this article, our motive is to demonstrate the classic sonographic features of ulnar nerve enlargement in leprosy. We have discussed various other causes of ulnar neuropathy and methods to differentiate the diagnosis. We also discussed about the role of MRI and ultrasound in evaluation of ulnar neuropathy. Intraoperative picture correlates well with the sonographic findings. We acknowledge that radiology case reports is the most suitable journal for submission of this interesting case.

Patient consent

Informed consent is obtained from the patient.

Acknowledgement

We acknowledge our patient, for providing a great learning opportunity.

REFERENCES

- [1] Reibel F, Cambau E, Aubry A. Update on the epidemiology, diagnosis, and treatment of leprosy. *Med Mal Infect* 2015;45(9):383–93.
- [2] WHO, *Weekly epidemiological record*. 2019. Available at: <https://apps.who.int/iris/bitstream/handle/10665/274127/9789290226383-eng.pdf?ua=1>. [Accessed 14.11.20].
- [3] Serrano-Coll H, Salazar-Pelaez L, Acevedo-Saenz L, Cardona-Castro N. *Mycobacterium leprae*-induced nerve damage: direct and indirect mechanisms. *Pathog Dis* 2018;76(6):76.
- [4] Scollard DM, Adams LB, Gillis TP, Krahenbuhl JL, Truman RW, Williams DL. The continuing challenges of leprosy. *Clin Microbiol Rev* 2006;19(2):338–81.
- [5] Talhari C, Talhari S, Penna GO. Clinical aspects of leprosy. *Clin Dermatol* 2015;33(1):26–37.
- [6] Kumar N, Garg RK, Malhotra HS. Ulnar and superficial radial nerve swellings in two patients with leprosy. *Am J Trop Med Hyg* 2018;98(4):939–40.
- [7] Goedee HS, van der Pol WL, Hendrikse J, van den HS, Berg LH. Nerve ultrasound and magnetic resonance imaging in the diagnosis of neuropathy. *Curr Opin Neurol* 2018;31(5):526–33.
- [8] Bathala L, Bathala L, N Krishnam V, Kumar HK, Neladimmanahally V, Nagaraju U, Kumar HM, Telleman JA, Visser LH. Extensive sonographic ulnar nerve enlargement above the medial epicondyle is a characteristic sign in Hansen's neuropathy. *PLoS Negl Trop Dis* 2017;11(7):e0005766.
- [9] Moschella SL. An update on the diagnosis and treatment of leprosy. *J Am Acad Dermatol* 2004;51(3):417–26.
- [10] Schertz M, Mutschler C, Masmajeun E, Silvera J. High-resolution ultrasound in etiological evaluation of ulnar neuropathy at the elbow. *Eur J Radiol* 2017;95:111–17.
- [11] Alrajeh M, Preston DC. Neuromuscular ultrasound in electrically non-localizable ulnar neuropathy. *Muscle Nerve* 2018;58(5):655–9.
- [12] Shukla B, Verma R, Kumar V, Kumar M, Malhotra KP, Garg RK, Malhotra HS, Sharma PK, Kumar N, Uniyal R, Pandey S, Rizvi I. Pathological, ultrasonographic, and electrophysiological characterization of clinically diagnosed cases of pure neuritic leprosy. *J Peripher Nerv Syst* 2020;25(2):191–203.
- [13] Nogueira-Barbosa MH, Lugão HB, Gregio-Júnior E, Crema MD, Kobayashi MTT, Frade MAC, Pavan TZ, Carneiro AAO. Ultrasound elastography assessment of the median nerve in leprosy patients. *Muscle Nerve* 2017;56(3):393–8.
- [14] Chen X, Zhang L, Huang M, Zhai X, Wen Y, Pan C. Coexistence of nerve enlargement and neuratrophy detected by ultrasonography in leprosy patients. *Sci Rep* 2018;8(1):7812.