

Effective examination methods for identifying the primary origins of metastatic bone tumors of unknown primary origin during the initial visit: A retrospective chart review study

SAGE Open Medicine

Volume 10: 1–7

© The Author(s) 2022

Article reuse guidelines:

sagepub.com/journals-permissions

DOI: 10.1177/20503121221097582

journals.sagepub.com/home/smo

Taketsugu Fujibuchi¹, Hiroshi Imai, Teruki Kidani and Hiromasa Miura

Abstract

Objective: To provide appropriate treatment for patients, early diagnosis of the primary origin of skeletal metastases of unknown primary origin is important. This study aimed to assess the examination strategy effective for identifying the primary origin of skeletal metastases of unknown primary origin.

Methods: Sixty-one patients with skeletal metastases of unknown primary origin were reviewed. The primary origin was examined via physical examination, blood test including tumor markers, chest radiography, thoracoabdominal computed tomography scan, positron emission tomography–computed tomography scan, metastatic lesion biopsy, and other assessments. Examination methods considered effective for the diagnosis of the primary origin in a specific type of cancer were investigated.

Results: The lung was the most common primary origin site, followed by the lymph nodes, prostate, and breast. Meanwhile, biopsy was the most effective examination, followed by positron emission tomography–computed tomography scan and thoracoabdominal computed tomography scan. Blood tests are useful for detecting hematological malignancies and prostate cancer. Computed tomography scans can be used to identify cancers in the lung, breast, and kidney, which are the common primary origins. Forty-one (67.2%) of the 61 patients with skeletal metastases of unknown primary origin were diagnosed via the first four steps, that is, physical examination, blood test, chest radiography, and thoracoabdominal computed tomography scan. Finally, two patients were diagnosed with skeletal metastases of unknown primary origin.

Conclusion: The examination steps used in this study, including physical examination, blood test including tumor markers, chest radiography, thoracoabdominal computed tomography scan, positron emission tomography–computed tomography scan, biopsy, and other assessments were effective in determining the primary origin of skeletal metastases of unknown primary origin during the initial visit.

Keywords

Neoplasms, unknown primary, metastasis, bone, diagnosis

Date received: 31 January 2022; accepted: 12 April 2022

Introduction

It was previously believed that bone metastases indicated terminal-stage cancer. The number of cancer patients has been gradually increasing with a longer average life expectancy. The survival rates of various cancers have improved with the development of novel therapies. For example, in England, the 1-year survival rate of all stages of lung cancer has improved $\geq 10\%$ from the 1990s to the 2010s due to advancements in diagnosis and treatment.^{1,2} Moreover, the treatment of renal cell carcinoma also has significantly

progressed in recent years.³ Approximately 10%–15% of cancers metastasize during their clinical course.⁴ The lung is the most common metastatic site, followed by the liver and

Department of Bone and Joint Surgery, Graduate School of Medicine, Ehime University, Toon City, Japan

Corresponding author:

Taketsugu Fujibuchi, Department of Bone and Joint Surgery, Graduate School of Medicine, Ehime University, Shitsukawa, Toon City 791-0295, Ehime, Japan.

Email: buchi@m.ehime-u.ac.jp



Creative Commons Non Commercial CC BY-NC: This article is distributed under the terms of the Creative Commons

Attribution-NonCommercial 4.0 License (<https://creativecommons.org/licenses/by-nc/4.0/>) which permits non-commercial use, reproduction and distribution of the work without further permission provided the original work is attributed as specified on the SAGE and Open Access pages (<https://us.sagepub.com/en-us/nam/open-access-at-sage>).

bone.⁵ The occurrence of metastatic cancer of unknown primary (CUP) origin is rare. However, it is still encountered in daily practice. A histologically defined metastatic malignancy in which the primary site cannot be identified after complete screening is referred to as CUP. CUP is one of the major groups of cancer, with an incidence of 3%–5%. It is among the 10 most common cancer types worldwide.⁶ The bone is a major site according to the initial presentation of CUP. It accounts for about 36% of CUP and is the second most frequent site after the lymph nodes.⁷ CUP is included in metastatic cancers of unknown primary origin at the first visit. Therefore, the bone is considered a common site of metastatic cancers of unknown primary origin during the initial visit. This condition is referred to as skeletal metastases of unknown primary (SMUP) origin. A delay in the diagnosis of the primary origin of SMUP during the initial visit can be a problem, as it can inhibit the timely provision of appropriate treatments for the primary and metastatic lesions. Delayed treatment of the primary cancer and skeletal metastasis leads to disease progression and skeletal-related events (SREs), such as pathological fractures, spinal cord compression, or hypercalcemia. Moreover, it can affect the quality of life. Hence, it is important to establish a diagnostic strategy to identify the primary origin and to initiate timely and appropriate treatments. In the past, there have been reports on strategies for diagnosing the primary origins of SMUP during the initial visit.^{8–10} However, the number of reports is limited and not sufficient to establish an effective strategy; thus, it is necessary to accumulate more reports on this subject.

In our hospital, when a metastatic bone tumor is suspected, an examination of the primary tumor is performed according to a modified strategy based on the previous literature.¹¹ Hence, the primary aim of this study was to retrospectively assess the types and order of examinations that are effective for diagnosing the primary origin of SMUP during the initial visit, and the secondary aim was to evaluate the effectiveness of each test, and, the third aim of this study was to explore the strategy that was useful for the orthopedic primary care doctors who initially examine patients with the SMUP.

Patients and methods

Patients

This retrospective chart review study included patients with SMUP during the initial visit between April 2007 and December 2018. Of the patients diagnosed with metastatic bone tumors during the initial visit, patients with a previous history of a malignant tumor and those initially suspected with another disease but diagnosed with a metastatic bone tumor were excluded. Patients initially suspected with a metastatic bone tumor but diagnosed with another disease were also excluded. In addition, patients who did not undergo the

examinations according to steps described in below for various reasons, for example, due to the deterioration of their general condition, were excluded. Finally, 61 patients were diagnosed as having SMUP during the initial visit and were included in this study. Their data were collected from clinical records and analyzed retrospectively.

Examination steps for identifying the primary origin of cancer

When a metastatic tumor was suspected, the primary origin was examined via physical examination; blood tests, including prostate-specific antigen (PSA), alpha-fetoprotein (AFP), carcinoembryonic antigen, squamous cell carcinoma antigen, soluble interleukin-2 receptor (sIL-2R), and serum protein electrophoresis; chest radiography; thoracoabdominal computed tomography (CT) scan; positron emission tomography (PET)–CT scan; metastatic lesion biopsy; and other assessments. This strategy was a modified version of the strategy that described in a previous literature. This original protocol in the literature included physical examination, chest radiography, thoracoabdominal CT scan, blood tests, urine and fecal occult blood test, common tumor marker test, bone scintigraphy, and gallium scintigraphy as primary examinations followed by bone biopsy, gastrointestinal endoscopy, pelvic magnetic resonance imaging, PET–CT, and additional tumor marker tests as secondary examinations.¹¹ Basically, these examinations were discontinued when the primary origin was identified, except when a test was required for further examination and staging of the primary origin (Figure 1). Biopsy of the primary origin and histopathological diagnosis were not included in examination steps because they were performed by specialist doctors depends on each primary lesion.

Statistical analysis

Data on age during the initial visit, sex, metastatic sites, examinations performed, examination results, and diagnosis of the primary origin were collected from the clinical records. An examination that could almost diagnose the primary origin was defined as effective. The type of examination effective for the diagnosis of the primary origin was investigated. In addition, the sensitivity of each examination including those performed for further evaluation and staging of the primary origin was evaluated. In this context, the sensitivity is the rate that at which it can be pointed out that the lesion that is the primary origin is positive in all the examinations performed, including the tests required for further examination and staging.

This retrospective study was conducted in accordance with the ethical standards described in the Declaration of Helsinki and was approved by the institutional review board of Ehime University Hospital (no. 1911009). Requirement of a written informed consent was waived by the institutional

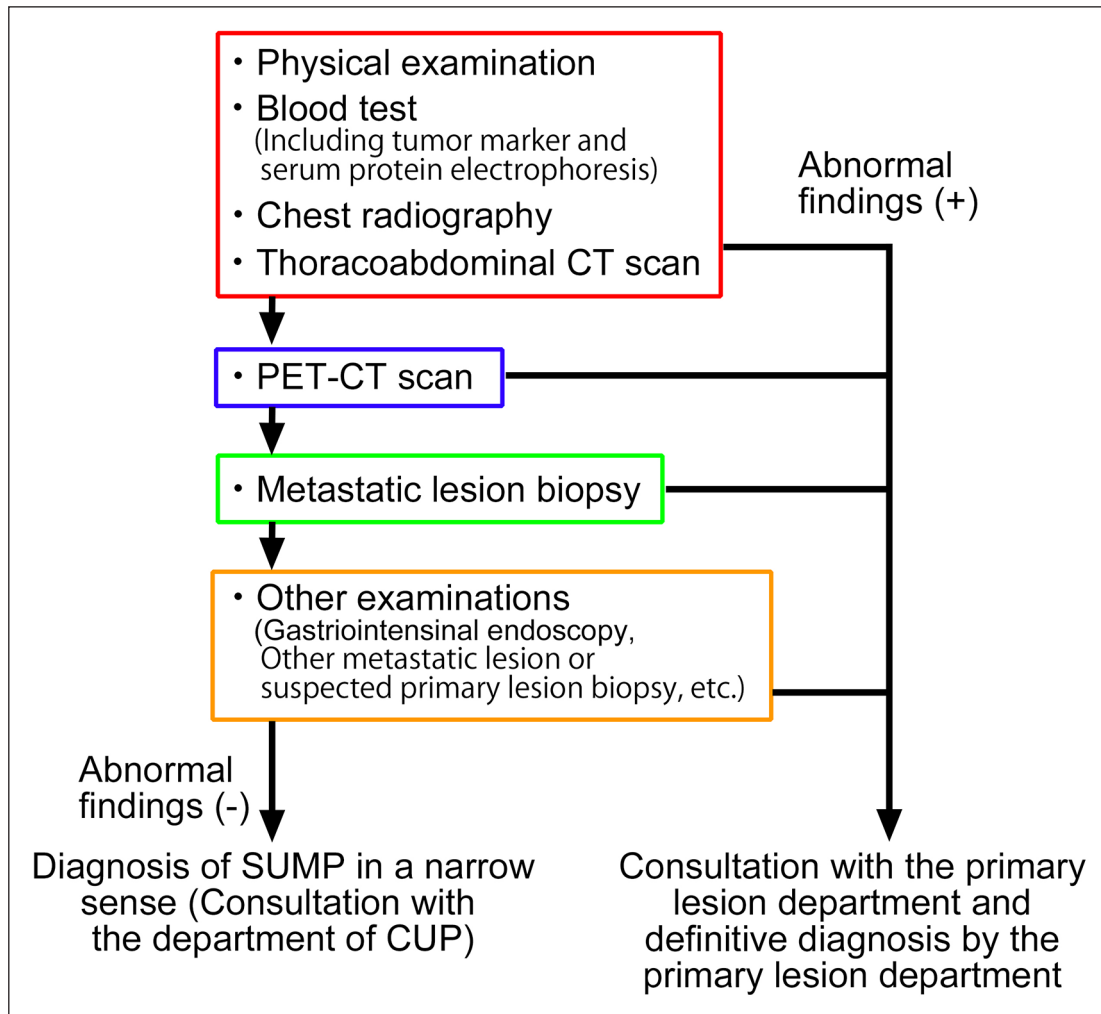


Figure 1. Examination steps for identifying the primary origin of cancer. The primary origin was examined based on these steps. Steps were discontinued when the primary origin was identified and consultation with the primary lesion department was conducted. The border color of box corresponds to each color of the bar in Figure 2. CT: computed tomography; PET: positron emission tomography; CUP: cancer of unknown primary.

review board of Ehime University Hospital owing to the retrospective nature of this study.

Results

Demographic characteristics of the participants

There were 34 men and 27 women, with a mean age of 68.2 (range=28–84) years. The thoracic vertebra (85 lesions) was the most common metastatic site, followed by the lumbar vertebra (61 lesions) and ribs (49 lesions). Except for the axial skeleton, the ilium (33 lesions) and femur (23 lesions) were also frequent metastatic sites. A total of 19 patients presented with solitary lesions and 42 with multiple lesions (a total of 350) (Table 1). The lung (n=14) was the most common primary site, followed by the lymph nodes: malignant lymphoma (n=8), prostate (n=8), breast (n=6), kidney (n=5), plasma cells: multiple myeloma (n=5), and others (Table 2).

Number of primary origins identified

Physical examination was effective to diagnose the primary origin in 4 of 61 patients with breast cancer. In 18 of 57 patients, blood tests were effective in identifying the primary cancers, which were hematological malignancy (n=6, lymphoma and n=5, multiple myeloma) and prostate cancer (n=7). Chest radiography was effective to diagnose the primary origin in 6 of 39 patients, all of whom had lung cancer. Thoracoabdominal CT scan was effective in detecting the primary origins in 13 of 33 patients (n=5, lung cancer; n=3, liver cancer; n=2, kidney cancer; n=1, breast cancer; n=1, ovarian cancer; and n=1, uterine cancer). In 7 of 20 patients (n=2, gastric cancer; n=2, lung cancer; n=1, kidney cancer; n=1, thyroid cancer; and n=1, uterine cancer), PET-CT scan could identify the primary origin. Furthermore, metastatic lesion biopsy was effective in 7 of 13 patients (n=2, kidney cancer; n=2, thyroid cancer; n=1, breast cancer;

Table 1. The site of metastatic lesions.

Site of metastasis	Solitary metastasis (19 lesions in 19 patients)	Multiple metastasis (350 lesions in 42 patients)
	Number of lesions	Number of lesions
Cervical vertebra	1	22
Thoracic vertebra	3	82
Lumbar vertebra	4	57
Sacral vertebra	1	29
Rib	1	48
Cranium		2
Clavícula	1	1
Scapula	2	11
Sternum		4
Humerus	1	8
Ilium	2	31
Pubis		17
Ischium		16
Femur	3	20
Tibia		1
Calcaneus		1

Table 2. The primary origin of skeletal metastasis of unknown primary origin during the initial visit.

Primary cancer	Number of patients (%)
Lung cancer	14 (23.0)
Malignant lymphoma	8 (13.1)
Prostate cancer	7 (11.5)
Breast cancer	6 (9.8)
Kidney cancer	5 (8.2)
Multiple myeloma	5 (8.2)
Liver cancer	4 (6.6)
Thyroid cancer	3 (4.9)
Stomach cancer	2 (3.3)
Uterus cancer	2 (3.3)
Urinary bladder cancer	1 (1.6)
Ovary cancer	1 (1.6)
Anal canal cancer	1 (1.6)
Unknown	2 (3.3)

n=1, lung cancer; and n=1, urinary bladder cancer), and other methods were effective in 4 (n=2, lymphoma; n=1, liver cancer; and n=1, anal canal cancer) of 6 patients. Other methods included biopsies of another metastatic lesion and biopsies of the primary lesion that could not be determined through PET-CT scan. The remaining two patients were diagnosed with unknown primary origin (Figure 2).

Sensitivity of each examination

Metastatic lesion biopsy (86.3%) was the most effective examination, followed by PET-CT scan (62.0%) and thoracoabdominal CT scan (46.8%). Physical examination was effective for diagnosing breast cancer. In terms of blood tests, assessment of sIL-2R, immune electrophoresis, and

PSA were effective for identifying lymphomas, multiple myeloma, and prostate cancer, respectively. Moreover, chest radiography could detect some lung cancers. Thoracoabdominal CT scan, PET-CT scan, and biopsy were effective in identifying all types of cancer (Table 3).

Discussion

A screening strategy for identifying the primary origins of SMUP during the initial visit should be established with consideration of various characteristics of examination strategies. The types of examination strategies and their order in terms of sensitivity should be determined based on the incidence of a specific type of cancer, extent of invasiveness, and time required for and ability and cost of the method. In

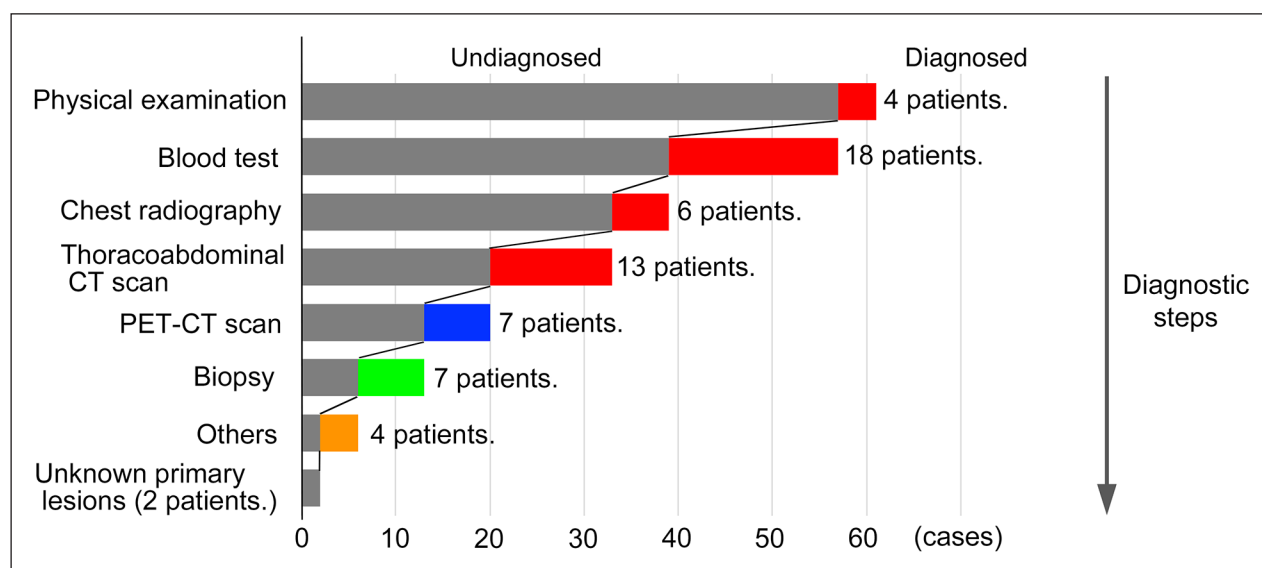


Figure 2. Number of identified primary lesions using the diagnostic methods. Examinations of each step are set on the axis of ordinate, whereas the number of primary origins identified is set on the axis of abscissa. The first four steps of physical examination, blood tests, chest radiography, and thoracoabdominal CT were effective in diagnosing the primary origin in 41 (67.2%) of 61 patients. The color of each bar corresponds to each border color of the box in Figure 2. CT: computed tomography; PET: positron emission tomography.

Table 3. The sensitivity of each examination according to the primary cancer.

Primary lesion	Physical examination	Blood test	Chest radiography	Thoracoabdominal CT scan	PET-CT scan	Metastatic lesion biopsy
Total	4/61 (6.6%)	18/61 (29.5%)	6/61 (9.8%)	22/47 (46.8%)	18/29 (62.0%)	19/22 (86.3%)
Lung cancer	0/14	0/14	6/14	6/10	6/6	4/4
Malignant lymphoma	0/8	6/8	0/8	1/4	0/5	4/5
Prostate cancer	0/7	7/7	0/7	3/6	1/1	0/0
Breast cancer	4/6	0/6	0/6	5/6	3/5	1/1
Kidney cancer	0/5	0/5	0/5	2/5	2/2	4/4
Multiple myeloma	0/5	5/5	0/5	0/4	0/0	0/0
Liver cancer	0/4	0/4	0/4	3/4	0/0	2/2
Thyroid cancer	0/3	0/3	0/3	0/1	2/2	3/3
Stomach cancer	0/2	0/2	0/2	0/2	2/2	0/0
Uterus cancer	0/2	0/2	0/2	1/2	2/2	0/0
Urinary bladder cancer	0/1	0/1	0/1	0/0	0/1	1/1
Ovary cancer	0/1	0/1	0/1	1/1	0/0	0/0
Anal canal cancer ^a	0/1	0/1	0/1	0/0	0/1	0/0
Unknown	0/2	0/2	0/2	0/2	0/2	0/2

PET: positron emission tomography; CT: computed tomography.

Each column shows the number of patients with positive findings regarding primary site and number of examinations.

^aThis patient was diagnosed with anal canal cancer by colonoscopy and biopsy from primary origin.

this study, all patients were Japanese; however, the incidence of a specific type of cancer varies by race and region, and the variation may have to be taken into consideration so as to choose the appropriate examination.

In this study, lung cancer was most commonly associated with metastatic bone tumor, followed by malignant lymphoma; prostate, breast, and kidney cancer; and multiple

myeloma. In patients with known or unknown primary origin at the time of bone metastasis diagnosis, the breast, lung, prostate, and kidney were common primary origin sites.^{12,13} In patients with SMUP during the initial visit, common primary origin sites were the lung, plasma cells, prostate, lymph nodes, kidney, breast, and liver.^{9,10} Whether cancer metastasizes at an early or late stage are based on the

type of cancer. However, the lung, breast, prostate, and kidney were the frequent primary origins of skeletal metastases. Myeloma and lymphoma might not be included in the statistics, and hematological cancer was one of the most common primary origins.

The screening methods used differ based on the type of cancer. For lung cancer, low-grade helical CT scan is recommended.^{14,15} Mammography is used for the screening of breast cancer, and palpation is included in the diagnostic work-up examination.^{16,17} Prostate cancer is usually assessed via blood test, including PSA with or without a digital rectal examination.^{17,18} Paraprotein and sIL-2R are important diagnostic markers for myeloma and malignant lymphoma, respectively.^{19,20} In this study, physical examination was useful for the screening of breast cancer, and blood testing was effective for the detection of malignant lymphoma, prostate cancer, and multiple myeloma. In addition, the thoracoabdominal CT scan was effective for the diagnosis of different types of cancer, particularly lung, breast, and liver cancer. PET-CT scan and metastatic lesion biopsy were useful for the identification of most types of cancer. In contrast, the detection rate of chest radiography was <50% even for lung cancer. Thoracoabdominal CT scans were found to be effective in screening for the primary origin of SMUP, particularly in the diagnosis of patients with lung, hepatocellular, renal cell, and pancreatic carcinomas. Moreover, an elevated serum AFP level is relatively specific to hepatocellular carcinoma.¹⁰

In a previous report, in approximately 53.3% of patients, the primary origin of SMUP was diagnosed via common examinations, such as medical history, physical examinations, chest radiography, blood test, and whole-body CT scan.⁹ Similarly, in our results, more than half of the cases, 41 (67.2%) of 61 patients, could be diagnosed via the first four steps: physical examination, blood test, chest radiography, and thoracoabdominal CT scan. The examinations included in these first four steps of the diagnostic strategy are less invasive, and have fewer side effects, and are useful for the diagnosis of common primary origins. For example, palpation for breast cancer, blood tests for prostate and hematological cancers, and CT scans for lung and breast cancers are extremely useful examinations. The sensitivity of chest radiography may be limited, as it was effective only in evaluating the patients' general condition, such as pleural effusions and large lung lesions. Therefore, if CT scans could be performed quickly, radiography might be omitted from this strategy. PET-CT scan was found to be a useful method in identifying the primary origin of SMUP.^{21,22} In our study, PET-CT scan was found to be effective for the diagnosis of a few cases of advanced-stage gastric cancer, which could not be detected on a CT scan. Furthermore, the diagnostic ability of a PET-CT scan (60.0%) was higher than that of a CT scan (38.6%). However, CT scans were effective in detecting common primary cancers. That is, in more than 60% of cases, the primary origins of SMUP were identified

during the initial visit via common examinations, including CT scans. In addition, a PET-CT scan is more expensive and the primary origin of SMUP can be identified more quickly on a CT scan than on a PET-CT scan.²³ We believe that that a CT scan is an effective examination as the first step of radiological screening to detect the common primary origins of SMUP, such as lung, breast, and kidney cancers. PET-CT scan was also effective, although it should be performed when a CT scan cannot identify the primary origin from a comprehensive perspective.

This study has some limitations. First, the calculation and justification of the sample size selected for this study has not been performed. The number of patients in this study was relatively lower than that in other recent studies. However, we believe that the results were accurate despite the inclusion of only few patients. Next, confounding factors may have been present during the interpretation of the examination results because physical examination, blood tests, chest radiography, and most of the CT scans were performed on the same day. In addition, there may be a problem in evaluating the sensitivity of each examination because definitive diagnosis may be affected by the results of all the previous examinations. Finally, there was no statistical verification of our strategy. There is no documentation on the period required for diagnosis of the primary origin and prognosis of patients with SMUP.^{9,10} Whether this strategy reduces the period required for diagnosing the primary origin of SMUP and whether early diagnosis of the primary origin improves patient prognosis are considerably concerning. However, the overall survival rate in patients with metastatic bone tumors was correlated with various factors, such as the presence of SRE, spinal metastases, performance status, number of metastatic sites, and primary sites.^{9,23} To elucidate the above problem statistically, analyses through large-scale studies are needed. Hence, these issues should be addressed in the future.

Conclusion

The diagnostic strategies used in this study are effective for identifying the primary origin of SMUP during the initial visit. That is, >60% of patients were diagnosed via blood test, radiography, and thoracoabdominal CT scan. However, radiography can be omitted if CT scan is performed immediately. Blood tests are useful for identifying the common primary origins of SMUP. Moreover, a CT scan is effective as the first step of radiological screening to detect the common primary origins of SMUP. A PET-CT scan is also effective, although it should be performed when the primary origin is not detected on a CT scan from a comprehensive perspective.

Acknowledgements

The authors are grateful to the late Dr Joji Miyawaki for valuable discussions.

Declaration of conflicting interests

The author(s) declared no potential conflicts of interest with respect to the research, authorship, and/or publication of this article.

Ethics approval

Ethical approval for this study was obtained from the institutional review board of Ehime University Hospital (no. 1911009).

Funding

The author(s) received no financial support for the research, authorship, and/or publication of this article.

Informed consent

Written informed consent was waived by the institutional review board of Ehime University Hospital owing to the retrospective nature of this study.

ORCID iD

Taketsugu Fujibuchi  <https://orcid.org/0000-0002-7543-4642>

References

- Walters S, Benitez-Majano S, Muller P, et al. Is England closing the international gap in cancer survival? *Br J Cancer* 2015; 113: 848–860.
- Jones GS and Baldwin DR. Recent advances in the management of lung cancer. *Clin Med (Northfield Il)* 2018; 18: s41–s46.
- Jonasch E, Gao J and Rathmell WK. Renal cell carcinoma. *BMJ* 2014; 349: g4797.
- Oien KA and Evans TRJ. Raising the profile of cancer of unknown primary. *J Clin Oncol* 2008; 26: 4373–4375.
- Biermann JS, Holt GE, Lewis VO, et al. Metastatic bone disease: diagnosis, evaluation, and treatment. *J Bone Jt Surg—Ser A* 2009; 91: 1518–1530.
- Pavlidis N and Fizazi K. Carcinoma of unknown primary (CUP). *Crit Rev Oncol Hematol* 2009; 69: 271–278.
- Kolling S, Ventre F, Geuna E, et al. “Metastatic cancer of unknown primary” or “primary metastatic cancer?” *Front Oncol* 2019; 9: 1546.
- Kitagawa Y, Ito T, Mizuno Y, et al. Challenges in the diagnosis of bone metastasis in patients without a history of malignancy at their first clinic visit. *J Nippon Med Sch* 2018; 85(5): 271–278.
- Takagi T, Katagiri H, Kim Y, et al. Skeletal metastasis of unknown primary origin at the initial visit: a retrospective analysis of 286 cases. *PLoS ONE* 2015; 10(6): e0129428.
- Katagiri H, Takahashi M, Inagaki J, et al. Determining the site of the primary cancer in patients with skeletal metastasis of unknown origin: a retrospective study. *Cancer* 1999; 86: 533–537.
- Araki N and Morita T. *Clinical management of metastatic bone disease* (in Japanese). 1st ed. Tokyo, Japan: KANEHARA & Co., 2004.
- Nottebaert M, Exner GU, von Hochstetter AR, et al. Metastatic bone disease from occult carcinoma: a profile. *Int Orthop* 1989; 13(2): 119–123.
- Zacharia B, Subramaniam D and Joy J. Skeletal metastasis—an epidemiological study. *Indian J Surg Oncol* 2018; 9(1): 46–51.
- Oudkerk M, Devaraj A, Vliegenthart R, et al. European position statement on lung cancer screening. *Lancet Oncol* 2017; 18: e754–e766.
- Hoffman RM and Sanchez R. Lung cancer screening. *Med Clin North Am* 2017; 101: 769–785.
- Cardoso F, Kyriakides S, Ohno S, et al. Early breast cancer: ESMO Clinical Practice Guidelines for diagnosis, treatment and follow-up. *Ann Oncol* 2019; 30: 1194–1220.
- Smith RA, Andrews KS, Brooks D, et al. Cancer screening in the United States, 2017: a review of current American Cancer Society guidelines and current issues in cancer screening. *CA Cancer J Clin* 2017; 67(2): 100–121.
- Heijnsdijk EAM, Bangma CH, Borra's JM, et al. Summary statement on screening for prostate cancer in Europe. *Int J Cancer* 2018; 142: 741–746.
- Mehta A. Multiple myeloma. *Hematology* 2015; 20: 58–59.
- Yoshida N, Oda M, Kuroda Y, et al. Clinical significance of sIL-2R levels in B-cell lymphomas. *PLoS ONE* 2013; 8(11): e78730.
- Tamam C, Tamam M and Mulazimoglu M. The accuracy of 18F-Fluorodeoxyglucose positron emission tomography/computed tomography in the evaluation of bone lesions of undetermined origin. *World J Nucl Med* 2016; 15(2): 124–129.
- Park S, Bin Park JM, Moon SH, et al. Role of 18F-FDG PET/CT in patients without known primary malignancy with skeletal lesions suspicious for cancer metastasis. *PLoS ONE* 2018; 13: 1–11.
- Shimada H, Setoguchi T, Yokouchi M, et al. Metastatic bone tumors: analysis of factors affecting prognosis and efficacy of CT and 18F-FDG PET–CT in identifying primary lesions. *Mol Clin Oncol* 2014; 2: 875–881.