

23. Gonna H, Evranos B, Leung L, Grimster A, Gallagher MM. Time effective cavotricuspid isthmus ablation – a comparison between large-tip 8- and 10 mm electrode catheters. A propensity score matched analysis. Heart Rhythm Congress, Birmingham, UK. *Eur J Arrhythm Electrophysiol* 2019;**5**(S1):abstr64.
24. Zagrodzky J, Gallagher MM, Leung LW, Sharkoski T, Santangeli P, Tschabrunn C et al. Cooling or warming the esophagus to reduce esophageal injury during left atrial ablation in the treatment of atrial fibrillation. *J Vis Exp* 2020;**157**:e60733.
25. Winkle RA, Mead RH, Engel G, Kong MH, Patrawala RA. Physician-controlled costs: the choice of equipment used for atrial fibrillation ablation. *J Interv Card Electrophysiol* 2013;**36**:157–65.
26. Di Biase L, Burkhardt JD, Mohanty P, Mohanty S, Sanchez JE, Trivedi C et al. Left atrial appendage isolation in patients with longstanding persistent AF undergoing catheter ablation: BELIEF Trial. *J Am Coll Cardiol* 2016;**68**:1929–40.
27. Rillig A, Tiltz RR, Lin T, Fink T, Heeger CH, Arya A et al. Unexpectedly high incidence of stroke and left atrial appendage thrombus formation after electrical isolation of the left atrial appendage for the treatment of atrial tachyarrhythmias. *Circ Arrhythm Electrophysiol* 2016;**9**:e003461.
28. Heeger C-H, Rillig A, Geisler D, Wohlmuth P, Fink T, Mathew S et al. Left atrial appendage isolation in patients not responding to pulmonary vein isolation. *Circulation* 2019;**139**:712–5.

EP CASE EXPRESS

doi:10.1093/europace/evaa379

Online publish-ahead-of-print 4 January 2021

An accessory pathway with automaticity and bidirectional conductive capacity

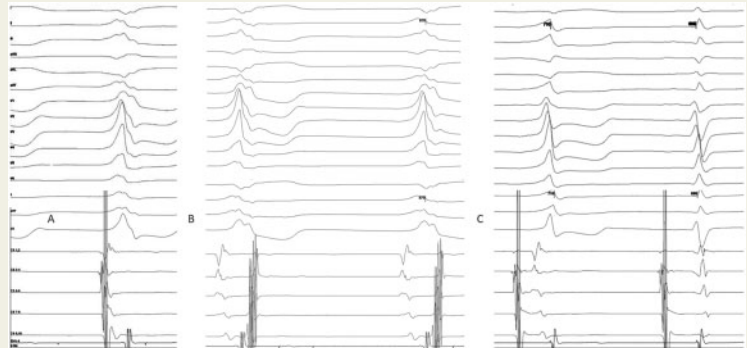
Luc Bruyndonckx ^{1,2,3,4}, Marta de Riva Silva ⁵, Nico A. Blom ^{1,2}, and Robin A. Bertels^{1*}

¹Department of Paediatric Cardiology, Willem-Alexander Children's Hospital, Leiden University Medical Center, Albinusdreef 2, 2333 ZA, Leiden, Netherlands;

²Department of Paediatric Cardiology, Amsterdam University Medical Centers, Meibergdreef 9, 1105 AZ Amsterdam, the Netherlands; ³Laboratory of Experimental Medicine and Paediatrics, University of Antwerp, Universiteitsplein 1, 2610 Antwerp, Belgium; ⁴Department of Paediatric Cardiology, Antwerp University Hospital, Drie Eikenstraat 655, 2650 Edegem, Belgium; and ⁵Department of Cardiology, Leiden University Medical Center, Albinusdreef 2, 2333 ZA, Leiden, Netherlands

* Corresponding author. Tel: +31 71526 2835; fax + 31 71-5248110. E-mail address: r.a.bertels@lumc.nl

We present a case of a 12-year-old boy referred for catheter ablation because of recurrent palpitations with documented paroxysmal supraventricular tachycardia. There was no structural heart disease and baseline electrocardiogram and Holter showed no ventricular pre-excitation. During the electrophysiological study, intermittent pre-excitation with the earliest ventricular activation located halfway the coronary sinus (CS) was observed. Two spontaneous ventricular rhythms with a right bundle branch block morphology were observed: the first showed simultaneous atrial and ventricular activation with atrial and ventricular earliest activation at the mid-CS (*Panel A*) and the second with earliest ventricular activation at mid-CS with retrograde atrial activation via the His bundle (*Panel B*).



Additionally, an atrial rhythm was present arising from mid-CS both with and without pre-excitation (*Panel C* first and second complex, respectively). Transseptal puncture was performed and after radiofrequency ablation, the ectopic rhythms disappeared. Only sinus rhythm without pre-excitation remained, tachycardia was not inducible and both antegrade and retrograde block of the pathway was demonstrated. In conclusion, the electrophysiological study in this patient proved the presence of an accessory pathway that had inherent automaticity and bidirectional conductive capacity.

The full-length version of this report can be viewed at: <https://www.escardio.org/Education/E-Learning/Clinical-cases/Electrophysiology>.

© The Author(s) 2021. Published by Oxford University Press on behalf of the European Society of Cardiology.

This is an Open Access article distributed under the terms of the Creative Commons Attribution Non-Commercial License (<http://creativecommons.org/licenses/by-nc/4.0/>), which permits non-commercial re-use, distribution, and reproduction in any medium, provided the original work is properly cited. For commercial re-use, please contact journals.permissions@oup.com