

Research article

## A study of cytokeratin 20 immunostaining in the urothelium of neuropathic bladder of patients with spinal cord injury

Subramanian Vaidyanathan\*<sup>1</sup>, Ian W McDicken<sup>2</sup>, Anna J Ikin<sup>2</sup>, Paul Mansour<sup>3</sup>, Bakul M Soni<sup>1</sup>, Gurpreet Singh<sup>1</sup> and Pradipkumar Sett<sup>1</sup>

Address: <sup>1</sup>Regional Spinal Injuries Centre, District General Hospital, Southport PR8 6PN, U.K, <sup>2</sup>Department of Pathology, Royal Liverpool University Hospital, Prescot Street, Liverpool L7 8XP, UK and <sup>3</sup>Department of Cellular Pathology, District General Hospital, Southport PR8 6PN, U.K

E-mail: Subramanian Vaidyanathan\* - [vaidyanathansiu@hotmail.com](mailto:vaidyanathansiu@hotmail.com); Ian W McDicken - [IW.McDicken@mail.rlbu.nwest.nhs.uk](mailto:IW.McDicken@mail.rlbu.nwest.nhs.uk); Anna J Ikin - [AJ.Ikin@mail.rlbu.nwest.nhs.uk](mailto:AJ.Ikin@mail.rlbu.nwest.nhs.uk); Paul Mansour - [Paul.Mansour@mail.soh-tr.nwest.nhs.uk](mailto:Paul.Mansour@mail.soh-tr.nwest.nhs.uk); Bakul M Soni - [Bakul.Soni@mail.soh-tr.nwest.nhs.uk](mailto:Bakul.Soni@mail.soh-tr.nwest.nhs.uk); Gurpreet Singh - [Gurpreet.Singh@mail.soh-tr.nwest.nhs.uk](mailto:Gurpreet.Singh@mail.soh-tr.nwest.nhs.uk); Pradipkumar Sett - [Pradip.Sett@mail.soh-tr.nwest.nhs.uk](mailto:Pradip.Sett@mail.soh-tr.nwest.nhs.uk)

\*Corresponding author

Published: 29 July 2002

Received: 19 April 2002

*BMC Urology* 2002, 2:7

Accepted: 29 July 2002

This article is available from: <http://www.biomedcentral.com/1471-2490/2/7>

© 2002 Vaidyanathan et al; licensee BioMed Central Ltd. This article is published in Open Access: verbatim copying and redistribution of this article are permitted in all media for any non-commercial purpose, provided this notice is preserved along with the article's original URL.

### Abstract

**Background:** Normal urothelium is characterised by terminally differentiated superficial cells, which express cytokeratin 20 in the cytoplasm. In contrast, cultured human stratified urothelium, which does not undergo complete terminal differentiation of its superficial cells, does not express cytokeratin 20. If spinal cord injury (SCI) affects urothelial differentiation or induces squamous or other metaplastic change undetected by histological analysis, the superficial urothelial cells of the neuropathic bladder might be expected to show absence of immunostaining for cytokeratin 20.

**Patients and Methods:** We studied immunostaining for cytokeratin 20 in bladder biopsies taken from 63 consecutive SCI patients. Immunostaining was performed on paraffin-embedded tissue using a mouse monoclonal antibody (clone: Ks20.8).

**Results:** Of 63 biopsies, the epithelium was scarce in two. Eight biopsies showed squamous metaplasia and immunostaining for cytokeratin 20 was absent in all the eight biopsies. Of the remaining 53 cases, in which the umbrella cell layer of the urothelium was intact, immunostaining for cytokeratin 20 was seen only in ten biopsies.

**Conclusion:** Superficial cells in the transitional epithelium showed immunostaining for cytokeratin 20 in 10 of 53 bladder biopsies taken from SCI patients. The reasons for this could be either that there is an underlying metaplasia or that changes in the neuropathic bladder affect urothelial differentiation. Taken with evidence from other systems, such as loss of cytokeratin 20 expression from static organ cultures of urothelial tissue, this might suggest that other factors, such as impairment of voluntary voiding in SCI patients, could affect expression of markers such as cytokeratin 20.

### Introduction

Normal urothelium serves as the main source of a major

class of soluble, urine proteins including urokinase, tissue-type plasminogen activator, and a potent serine pro-

tease inhibitor, PP5 [1]; their synthesis requires differentiation of the vesical urothelium. It is speculated that these urinary proteins and their inhibitors play a crucial role in regulating desquamation of urothelium, which constitutes a vital defence mechanism against bacterial attachment. Thus the mammalian urothelium, besides acting as a permeability barrier, may serve important functions in prevention of bacterial cystitis.

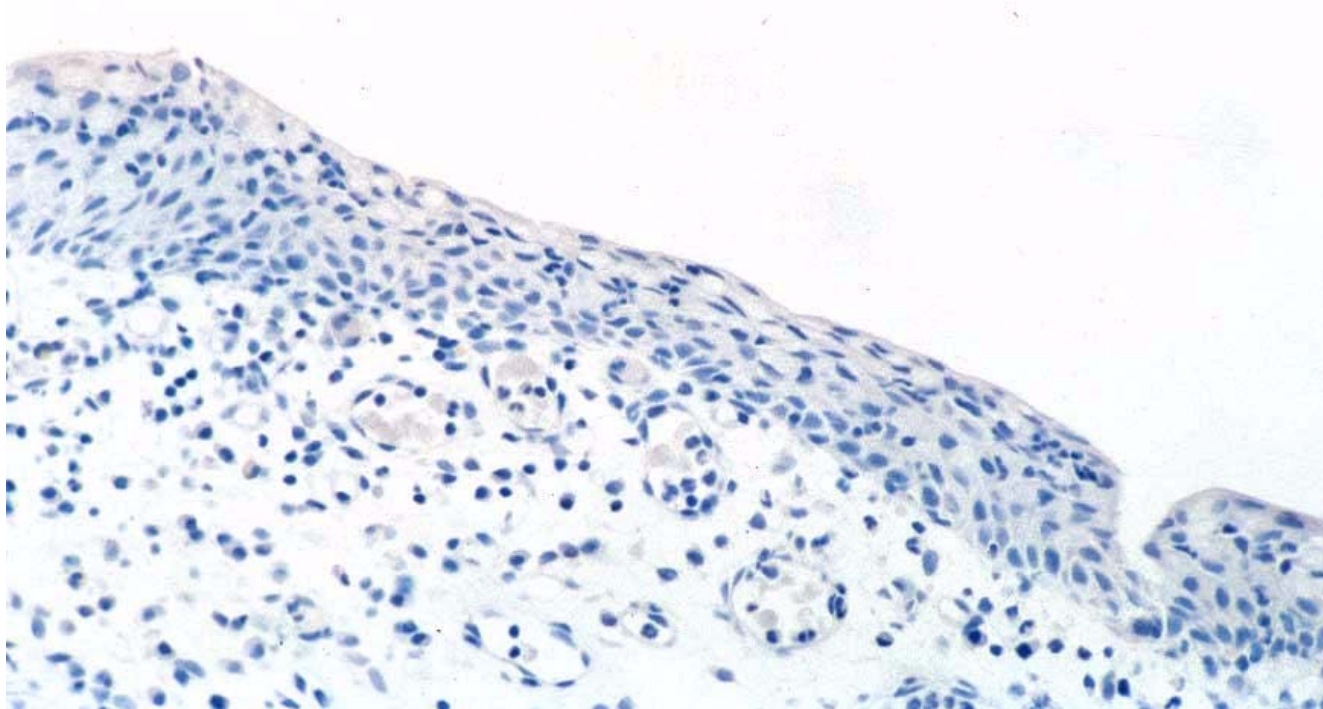
Urothelium is characterised by terminally differentiated superficial cells ("umbrella cells"), that express uroplakins in their luminal plasma membrane and cytokeratin 20 in their cytoplasm. Basal and intermediate cells are cytokeratin 20 negative. [2] In contrast to normal urothelium, cultured human stratified urothelium does not undergo complete terminal differentiation of its superficial cells. Using immunohistochemical staining with specific antibodies, the superficial layer of reconstructed stratified urothelium has been shown to express uroplakins but not cytokeratin 20 [3-5].

We studied cytokeratin-20 immunostaining of bladder biopsies taken from spinal cord injury patients. It is possible that injury to the spinal cord, and consequent lack of

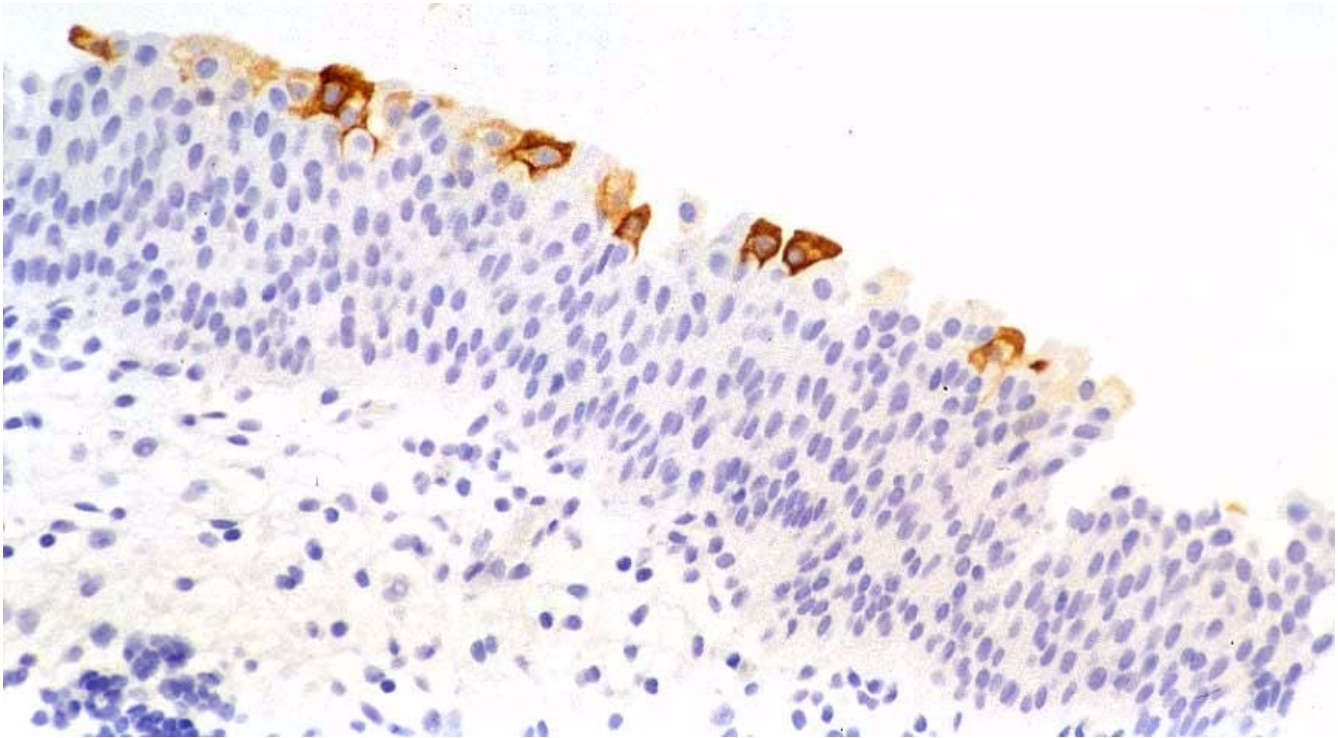
trophic effect upon the urothelium, may lead to incomplete maturation and differentiation. [6]. As normal urothelium is characterised by cytoplasmic cytokeratin 20 expression in terminally differentiated superficial cells, cytokeratin 20 was taken as a marker of complete terminal differentiation of urothelial cells in bladder biopsies. If spinal cord injury does indeed affect urothelial differentiation or induces squamous or other metaplastic change undetected by histological analysis, the superficial urothelial cells in the neuropathic bladder of SCI patients may not show positive immunostaining for cytokeratin 20.

### Patients and Methods

Bladder biopsies were obtained from 63 spinal cord injury patients after obtaining written informed consent. The North Sefton Local Research Ethics Committee approved this study. All were adults with spinal cord injury and neuropathic bladder. They were registered with the Regional Spinal Injuries Centre, Southport, England; were not suffering from acute urinary infection and were undergoing an elective therapeutic procedure in the urinary tract such as endoscopic lithotripsy of bladder stone, insertion of a ureteric stent, or diagnostic cystoscopy.



**Figure 1**  
Bladder biopsy from a male with ventilator-dependent tetraplegia (DC) shows no immunostaining for cytokeratin 20.



**Figure 2**

Bladder biopsy from a male with L-2 paraplegia (MW-37): Immunostaining for cytokeratin 20 shows positive staining in umbrella cells.

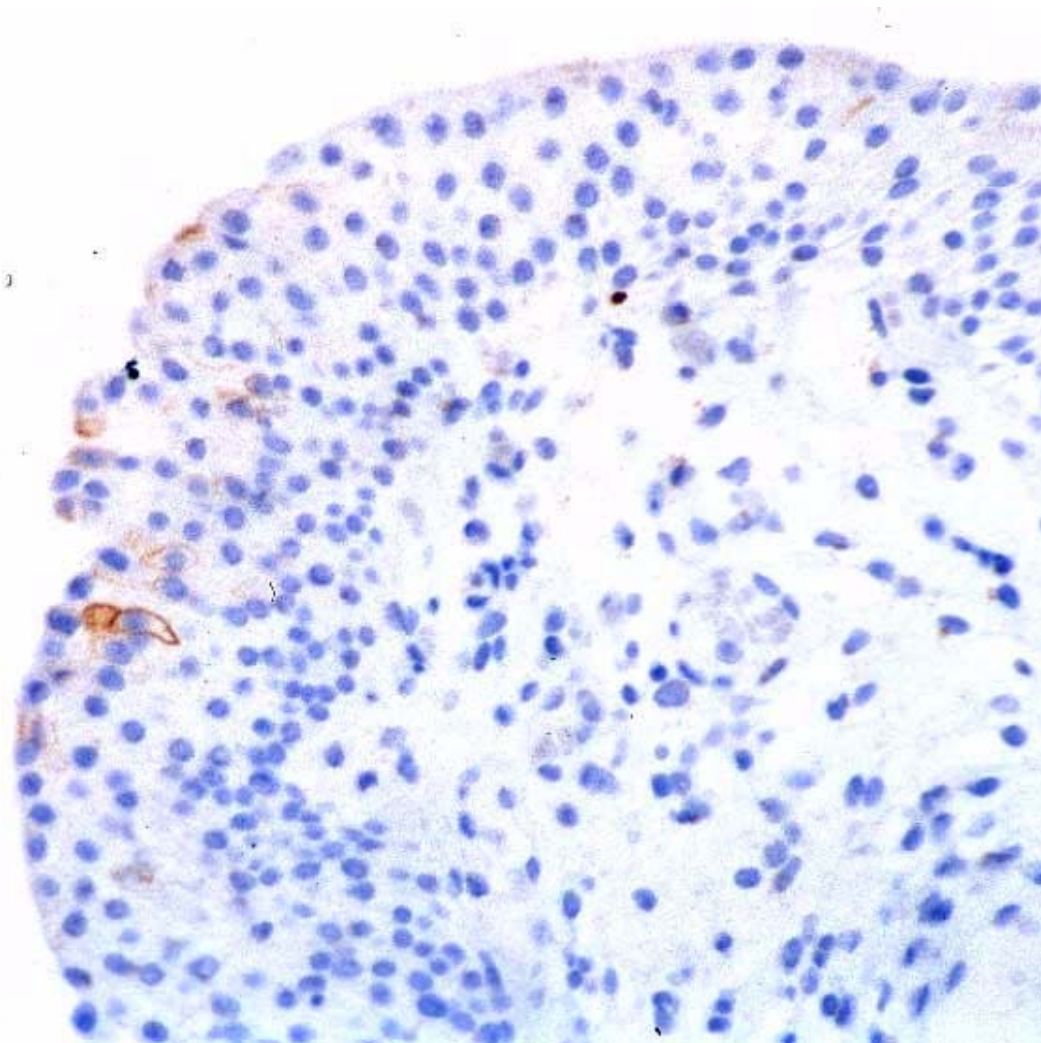
After routine prophylactic intravenous gentamicin, cold cup biopsies of the bladder mucosa were taken from the trigone of the urinary bladder. Thereafter, the biopsy site was fulgurated with diathermy to achieve haemostasis. Indwelling urinary catheter drainage was maintained after the procedure, and all patients remained in hospital for at least 24 hours. Biopsies were fixed in neutral buffered formaldehyde 4%, and then embedded in Paraplast. (Paraplast is a commercial paraffin wax incorporating plasticisers, used for embedding formalin-fixed tissues for histology.)

A Consultant Cellular Pathologist recorded the histopathological features of each bladder biopsy after examining sections stained with haematoxylin and eosin. None of the 63 biopsies from spinal cord injury patients showed evidence of dysplasia or neoplasia. The classical morphological features of dysplasia in the urothelium comprise: increased nucleo-cytoplasmic ratio, nuclear hyperchromatism, abnormal chromatin pattern, prominent nucleoli, and nuclear pleomorphism; and loss of normal polarity leading to a haphazard spatial arrangement of urothelial cells. The affected urothelium is, by definition, flat rather than papillary. In the most severe form of dysplasia (carcinoma-in-situ), the above nuclear characteristics are present to a marked degree, comparable in severity to

those in a grade 3 Transitional Cell Carcinoma. Lesser degrees are termed 'dysplasia not amounting to carcinoma-in-situ'. At the mild end of the spectrum, distinguishing dysplasia from inflammatory or regenerative atypia can be difficult; the abnormal chromatin pattern in dysplasia is usually the most reliable criterion.

In two biopsies, epithelium was scarce. Eight biopsies showed squamous metaplasia with no transitional epithelium present. Umbrella cells were identifiable in the remaining 53 biopsies at least in one microscopic field. Umbrella cells were identified by their morphological characteristics, namely: large, elongated cells with abundant eosinophilic cytoplasm, their long axes parallel to the basement membrane, covering several underlying intermediate urothelial cells. The umbrella cells may occasionally be binucleate.

Immunostaining for cytokeratin 20 was carried out on tissue sections in one lot using a mouse monoclonal antibody, clone Ks20.8 (Novocastra Laboratories Ltd, Balliol Business Park West, Benton Lane, Newcastle upon Tyne NE12 8EW, UK). This is an IgG antibody (IgG2a, kappa), with specificity for human cytokeratin 20 intermediate filament protein, raised against cytoskeletal preparations isolated from microdissected villi of human duodenal



**Figure 3**

Bladder biopsy from a male with C-7 tetraplegia (HW-44): Immunostaining for cytokeratin 20 shows a few faintly positive cells in the superficial layer of urothelium.

mucosa. The normal positive staining pattern for cytokeratin 20 is cytoplasmic. The manufacturer's instructions were followed for immunostaining. Sections were pretreated with proteinase-K, to unmask cytokeratin epitopes masked by the cross-linking effect of formaldehyde during fixation and tissue processing. The antibody was used at a working dilution of 1:25. Immunoperoxidase technique was employed, with primary antibody incubation at 25°C for 60 minutes. Each sample included a negative control, by omitting the primary antibody. Avidin Biotin Complex (ABC) kit was purchased from Vector Laboratories. The version of the kit used was Elite ABC.

The presence of immunostaining in the vesical epithelium was recorded either as negative or positive, and the loca-

tion of any positively staining cells within the transitional epithelium was noted.

### Results

Vesical urothelium in the patients with SCI showed no immunostaining for cytokeratin 20 in 43 of 53 cases, in which transitional epithelium was identifiable (Figure 1). Haematoxylin and eosin sections showed clearly identifiable umbrella cells in these biopsies, thereby excluding false-negative staining due to mechanical denudation of the epithelium. Positive immunostaining for cytokeratin 20 was observed in only ten biopsies (Table 1). Immunostaining was limited to occasional cells in the superficial layer of urothelium (Figures 2 and 3). Immunostaining for CK-20 was absent in all eight biopsies, which showed squamous metaplasia.

**Table 1: Clinical details and histopathology findings of spinal cord injury (SCI) patients in whom bladder biopsies showed positive immunostaining for cytokeratin-20 (CK-20)**

Immuno Number	Age	Year of SCI	Level of SCI C: Cervical T: Thoracic L: Lumbar	Method of bladder drainage	Histology	Distribution of CK-20 Immuno-staining
14	34	1998	C-5	Indwelling urethral catheter	Moderate active chronic inflammation	Few umbrella cells
16	43	1975	C-6	Indwelling urethral catheter	Moderate non-specific chronic inflammation. Focal cystitis glandularis	Individual umbrella cells and intestinal metaplasia.
21	58	1998	T-7	Indwelling urethral catheter	Moderate chronic inflammation	Individual cells in transitional epithelium
23	64	1959	L-1	Clam cystoplasty Intermittent catheterisation	Moderate acute and chronic inflammation. Follicular cystitis	Few umbrella cells
30	44	1989	T-12	Indwelling urethral catheter	Moderate acute and chronic inflammation. Cystitis glandularis	Isolated cells in the superficial layer of transitional epithelium
37	23	1997	L-2	Intermittent catheterisation Haematuria	Patchy chronic inflammation. Patchy cystitis glandularis	Occasional umbrella cells.
44	70	1999	C-7	Indwelling urethral catheter	Moderate acute and chronic inflammation. Follicular cystitis	Individual umbrella cells
45	22	1996	C-6	Indwelling urethral catheter	Marked acute and chronic inflammation	Individual umbrella cells
53	23	1998	C-4	Indwelling urethral catheter	Severe acute and chronic inflammation. Follicular cystitis	Very few umbrella cells
6428/99	65	1991	C-4	Indwelling urethral catheter	Moderate active chronic inflammation. Papillary cystitis	Individual cells in transitional epithelium

**Discussion**

In an earlier study, we observed strong immunostaining for secretory immunoglobulin A (sIgA) in the urothelium of all biopsies taken from non-neuropathic bladders, but in only 18 of 37 biopsies from neuropathic bladders. [7]. This suggested that interruption of the nerve supply to the urinary bladder might be associated with alterations in urothelial differentiation and maturation. In the present study, we observed positive staining for cytokeratin 20, a marker of terminal urothelial differentiation, in only 10 of 53 biopsies taken from spinal cord injury patients, thereby providing further supporting evidence to that hypothesis.

Harnden and associates [8] noted positive immunostaining for cytokeratin 20 in the umbrella cells of all control biopsies, with staining restricted to the umbrella cells in 24 of 30 biopsies; in the remaining six cases, occasional dispersed intermediate cells also stained positively. Basal cells were consistently negative. A similar pattern of immunostaining was observed in the presence of hyperplasia and inflammation. In this study, immunostaining for cytokeratin 20 was absent in 43 of 53 biopsies taken from the neuropathic bladders of SCI patients. This absence of cytokeratin 20 immunostaining raises the question as to whether the transitional epithelium of the neuropathic

bladder in SCI patients does not achieve complete functional differentiation, despite apparently complete morphological differentiation as judged by the presence of umbrella cells. Terminal differentiation of the urothelium plays a crucial role in desquamation of urothelium and hence in prevention of bacterial cystitis; "defective" or "incomplete" differentiation of bladder urothelium may explain why some SCI patients are at greater risk of developing bacterial cystitis.

There appears to be an absence of cytokeratin 20 in a high proportion of urothelium from neuropathic bladders. The reasons for this could be either that there is an underlying metaplasia or that changes in the neuropathic bladder affect urothelial differentiation. This question could be addressed by further analysis of other differentiation markers of urothelium, including cytokeratins and uroplakins. Taken with evidence from other systems, such as loss of cytokeratin 20 expression from static organ cultures of urothelial tissue [3], this might suggest that other factors, such as impairment of normal voiding function in SCI patients, could affect expression of differentiation markers such as cytokeratin 20.

**Competing interests**

None declared.

### Authors' contributions

SV developed the hypothesis; formulated the research protocol; submitted it to the Ethics Committee; and finally wrote the manuscript. IWM interpreted the immunohistochemistry slides. AJI carried out immunohistochemistry. SV and GS performed bladder biopsies. PM interpreted histology slides of bladder biopsies. All authors contributed to the final manuscript.

### Acknowledgement

The authors wish to record their sincere gratitude to Professor Jenny Southgate, Jack Birch Unit of Molecular Carcinogenesis, Department of Biology, University of York, York, United Kingdom, and Professor Jian Yu Rao, Department of Pathology and Lab Medicine, UCLA Medical Centre, Los Angeles, California 90095, USA, for their valuable comments.

We thank AstraZeneca (Ms Charlotte Lawledge), Pharmacia (Ms Joanne Thomas), and Shire Pharmaceuticals (Mr Patrick Tierney) for financial support, which enabled the Regional Spinal Injuries Centre, Southport, United Kingdom to become an institutional member of BioMed Central.

### References

1. Deng F-M, Ding M, Lavker RM, Sun T-T: **Urothelial function reconsidered: A role in urinary protein secretion** *Proceedings of National Academy of Sciences USA Cell Biology* 2001, **98**:154-159
2. Southgate J, Harnden P, Trejdosiewicz LK: **Cytokeratin expression patterns in normal and malignant urothelium: a review of the biological and diagnostic implications.** *Histol Histopathol* 1999, **14**:657-664
3. Scriven SD, Booth C, Thomas DF, Trejdosiewicz LK, Southgate J: **Reconstitution of human urothelium from monolayer cultures.** *J Urol* 1997, **158**(3 Pt 2):1147-1152
4. Sugasi S, Lesbros Y, Bisson I, Zhang YY, Kucera P, Frey P: **In vitro engineering of human stratified urothelium: analysis of its morphology and function.** *Journal of Urology* 2000, **164**(3 Pt 2):951-7
5. Desai S, Lim SD, Jimenez RE, Chun T, Keane TE, McKenney JK, Zavala-Pompa A, Cohen C, Young RH, Amin MB: **Relationship of CK20 and CD44 protein expression with WHO/ISUP grade in pTa and pT1 papillary urothelial neoplasia.** *Modern Pathology* 2000, **13**:1315-1323
6. Vaidyanathan S, McDicken I, Soni BM, Sett P, Krishnan KR: **Possible role of denervation-induced changes in the urothelium in the pathophysiology of cystitis in patients with spinal cord injury: a hypothesis** *Spinal Cord* 1997, **35**:708
7. Vaidyanathan S, McDicken IW, Soni BM, Singh G, Sett P, Nori Husin Mat: **Secretory immunoglobulin A in the vesical urothelium of patients with neuropathic bladder: an immunohistochemical study.** *Spinal Cord* 2000, **38**:378-381
8. Harnden P, Eardley I, Joyce AD, Southgate J: **CK20 as an objective marker of urothelial dysplasia** *British Journal of Urology* 1996, **78**:870-875

### Pre-publication history

The pre-publication history for this paper can be accessed here:

<http://www.biomedcentral.com/1471-2490/2/7/prepub>

Publish with **BioMed Central** and every scientist can read your work free of charge

"BioMedcentral will be the most significant development for disseminating the results of biomedical research in our lifetime."

Paul Nurse, Director-General, Imperial Cancer Research Fund

Publish with **BMC** and your research papers will be:

- available free of charge to the entire biomedical community
- peer reviewed and published immediately upon acceptance
- cited in PubMed and archived on PubMed Central
- yours - you keep the copyright

Submit your manuscript here:

<http://www.biomedcentral.com/manuscript/>



BioMedcentral.com

[editorial@biomedcentral.com](mailto:editorial@biomedcentral.com)