



## CASE REPORT

# Anesthesia or analgesia? New block for shoulder surgery: pericapsular nerve group block

Ilke Küpeli, Merve Yazici Kara \*

Kocaeli Derince Training and Research Hospital, Anesthesiology Department, Kocaeli, Turkey

Received 22 January 2021; accepted 22 May 2021  
Available online 9 June 2021

### KEYWORDS

Regional anesthesia;  
Shoulder surgery;  
Pericapsular Nerve  
Group Block (PENG);  
Postoperative  
analgesia

**Abstract** Interscalene brachial plexus (ISB) block is considered the analgesic technique of choice for shoulder surgery. However, the hemidiaphragmatic paresis that may occur after the block has led to the search for an alternative to the ISB block. In this case report, the pericapsular nerve group (PENG) block was performed for both surgical anesthesia and postoperative analgesia in two patients who underwent shoulder surgery. It is suggested that the PENG block can be safely applied for analgesia and can be part of surgical anesthesia, but alone is not sufficient for anesthesia. The block of this area did not cause motor block or pulmonary complications, nor result in muscle laxity, blocking only the shoulder and the upper third of the humerus. It was demonstrated that the PENG block may be safely applied for both partial anesthesia and analgesia in selected shoulder surgery cases.

© 2021 Published by Elsevier Editora Ltda. on behalf of Sociedade Brasileira de Anestesiologia. This is an open access article under the CC BY-NC-ND license (<http://creativecommons.org/licenses/by-nc-nd/4.0/>).

## Introduction

Early postoperative pain immediately following shoulder surgery is a major concern and cause of distress for patients and orthopedic surgeons.<sup>1</sup> Adequate pain control is vital for all aspects of the patient's recovery.

Multimodal pain management is recommended for early postoperative pain control. Regional anesthesia (RA) is pre-

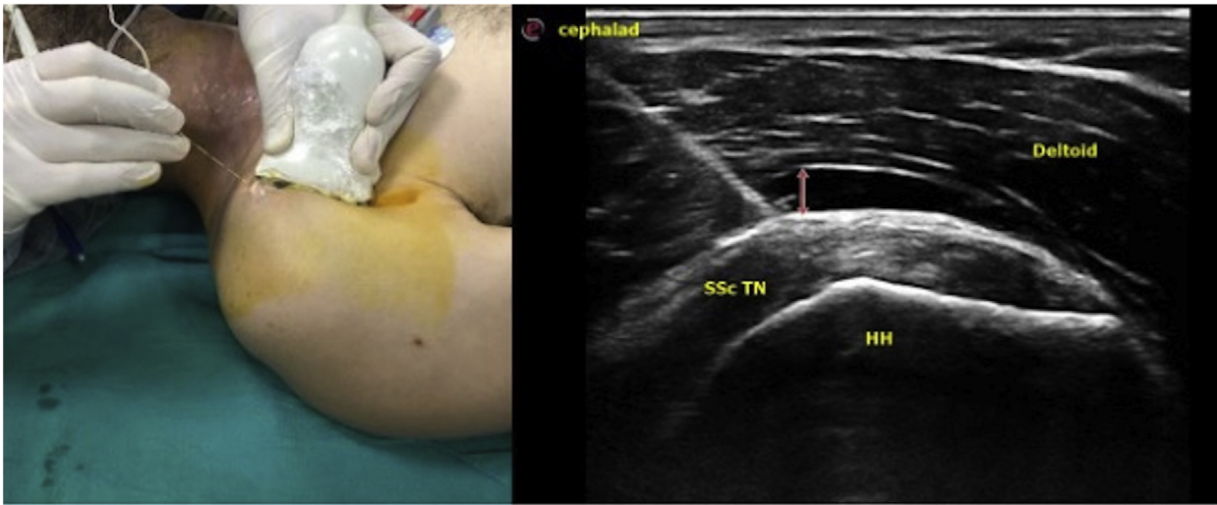
ferred in shoulder surgery as an effective means of providing anesthesia and postoperative analgesia.<sup>1</sup>

Commonly used techniques for shoulder surgery include interscalene brachial plexus (ISB) blocks, continuous ISB (CISB) blocks, suprascapular nerve blocks (SSB), supraclavicular nerve blocks (SCB), local infiltration (LI), and ISB with adjuvants.<sup>2</sup>

In this case report, the pericapsular nerve group (PENG) block was performed for both postoperative analgesia and surgical anesthesia in two patients who underwent shoulder surgery.

\* Corresponding author.

E-mail: [merreset@hotmail.com](mailto:merreset@hotmail.com) (M. Yazici Kara).



**Figure 1** Position of the US probe (A) and the needle (B). HH, humerus head; SSc Tn, subscapularis tendon; Deltoid, deltoid muscle.

### Case 1

A 43-year-old male patient was brought to the emergency room due to a traffic accident. He had right femoral neck fracture, right upper humerus fracture, and multiple rib fractures between the 3–10 ribs at seven levels on the left side. The patient had neither hemothorax nor pneumothorax, but lung contusion was detected. During the preoperative evaluation, conscious communication could not be established with the patient and it was learned from his relatives that he had a known diagnosis of schizophrenia. The patient was tachypneic and his breathing was irregular. We observed that peripheral oxygen saturation (SpO<sub>2</sub>) was 92% (with oxygen). Open surgical reduction was planned for the upper humerus fracture by the surgical team. A PENG block was planned in the right shoulder in order to avoid any regional anesthesia that would cause lung complications, due to left-sided rib fractures and lung contusion. The patient was administered 2 mg of midazolam, and the right shoulder was prepared sterile.

### PENG block

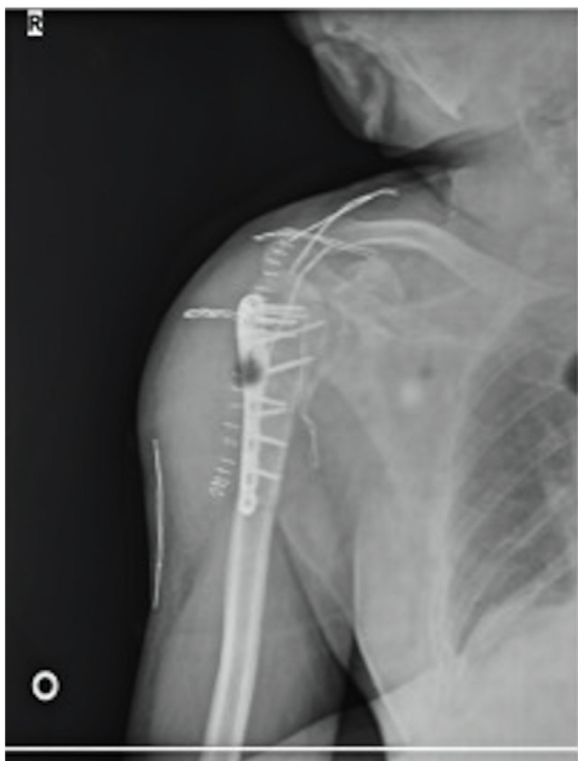The patient's arm was placed in external rotation and abducted at 45 degrees. A linear ultrasound probe was placed longitudinally between the coracoid and the humeral head. After defining the humeral head, the tendon of the subscapular muscle and the deltoid muscle over it, a 50-mm needle was inserted using the "in plane" technique. When the needle passed through the deltoid muscle and touched the subscapularis tendon, a bone-like hard tissue was felt and the needle could not be advanced further. The needle tip was placed between the deltoid muscle and subscapularis tendon, and 20 cc of 0.5% bupivacaine hydrochloride was injected (Fig. 1).

Surgery started successfully with skin incision 30 minutes after the block procedure. However, the patient felt pain during the skin incision in the distal of the upper third of the arm. At this stage, 150 mg of ketamine (2 mg.kg<sup>-1</sup>)

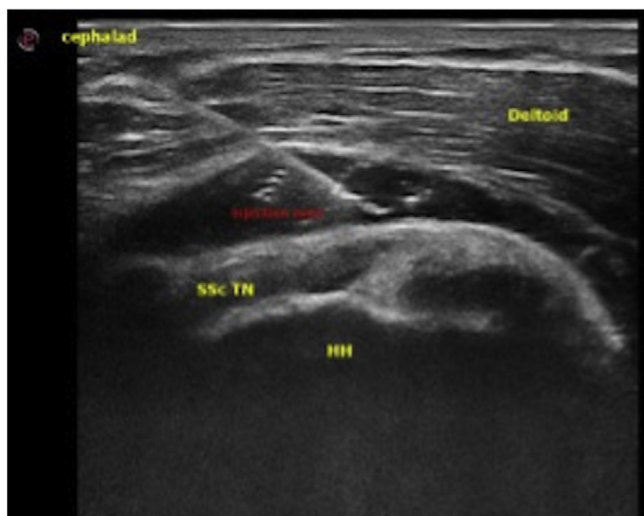
and 100 mcg of fentanyl were added. Although it is known that ketamine may cause schizophreniform symptoms, since we did not want to encounter respiratory problems in this case, it was administered as a single dose after considering the risk-benefit analysis. When it was observed that the block did not provide muscle relaxation, 50 mg of propofol was added at three separate times during the two-hour long surgery. Surgically, open reduction was performed with one proximal humeral plate and a few screws (Fig. 2). The case was completed without any problem. The patient was taken to the intensive care unit. Tramadol 100 mg administered 2 × 1 intravenously in intensive care was sufficient for postoperative analgesia. The 24-h visual analog scale (VAS) for pain scores did not exceed 4. The next day he was transferred to the orthopedic department.

### Case 2

A 45-year-old female patient was admitted to the orthopedic clinic with left shoulder pain. Bankart arthroscopic repair was planned, and general anesthesia was given with intravenous (IV) induction, which was achieved with 100 mcg fentanyl, 200 mg propofol, and 50 mg rocuronium. Maintenance of anesthesia was provided by a mixture of 2 MAC sevoflurane + 50% oxygen + 50% air. For postoperative analgesia, 1000 mg IV paracetamol before the end of the operation and a PENG block with ultrasound was planned before the patient was roused after the operation. As described in the previous case, 15 cc of local anesthetic (0.5% bupivacaine) was injected between the deltoid and the subscapularis tendon (Fig. 3). At the end of the procedure, the patient was awakened with neostigmine + atropine, without any problem, and was taken to the postoperative care unit. The patient reported a VAS score of 0 and was taken to the ward after being kept under observation for half an hour. The first subsequent analgesic need was seen 16 hours later, and the patient received 1.000 mg IV paracetamol. The patient was discharged the next day without any complications.



**Figure 2** Procedure of surgery.



**Figure 3** Local anesthetic infiltration between the deltoid and the subscapularis tendon. HH, humerus head; SSc Tn, subscapularis tendon; deltoid, deltoid muscle.

## Discussion

In these cases, it was demonstrated that the PENG block can be effectively and safely applied under ultrasound guidance in selected shoulder surgery cases for postoperative analgesia. In addition, PENG block was a useful and effective part of anesthetic management but was not sufficient alone for effective anesthesia.

Shoulder surgery is one of the most common outpatient orthopedic procedures. The glenohumeral joint (GHJ) con-

tains the glenoid of the scapula and the humeral head, which are surrounded by a capsule consisting of a fibrous sheath. To ensure adequate postoperative pain control, nerve supply to the synovium, capsule, joint surfaces, ligaments, periosteum, and shoulder muscles should all be blocked.<sup>1,3</sup>

There has been a great deal of research on perioperative pain management and optimal block techniques for shoulder surgery.<sup>4</sup> Interscalene block (ISB) is the most common. ISB targets the brachial plexus, resulting in both sensory and motor blockage in the upper limb. ISB has been studied extensively and is a good method of providing analgesia following shoulder surgery, being considered the gold standard mode of RA.<sup>2</sup> A potential complication of ISB is the spread of local anesthetic to the phrenic nerve.

Tran et al. showed that the posterosuperior quadrant of the GHJ was innervated by the suprascapular nerve and the posteroinferior quadrant was innervated by the posterior branch of the axillary nerve. In addition, the same group reported that the anterosuperior quadrant of this joint is innervated by the subscapularis superior branch and the anteroinferior by the main branch of the axillary nerve.<sup>4</sup> These anatomical data indicated that it would be possible to define new blocks that mainly target the GHJ sensory branches and thus minimize motor blockage. For example, it was suggested that deep pericapsular infiltration of local anesthetic towards the subscapularis may cover the axillary and subscapularis branches that feed the anteroinferior and superior quadrants of the GHJ. Similarly, Altınpulluk et al., in their cadaver studies using methylene blue injection hypothesized that this technique provided a pericapsular distribution and most likely reached the joint branches that innervate the GHJ.<sup>3</sup> Pericapsular nerve block was successfully and safely applied in our patients and contributed to both anesthesia and analgesic management.

PENG block has been studied extensively in hip surgeries,<sup>5</sup> but its place in shoulder surgeries is not yet clear. We achieved successful results with 20 cc 0.5% bupivacaine hydrochloride in our patient for whom we requested surgical anesthesia, and 15 cc 0.5% bupivacaine in our patient requiring postoperative analgesia. For the arm position, we applied the block in external rotation, as described by Altınpulluk et al.<sup>3</sup>

It is notable that while performing these PENG blocks the subscapularis tendon was very hard and was impervious to anesthetic needle penetration. In addition, in our patients this area block did not cause motor block or pulmonary complications and did not provide muscle laxity, blocking only the upper third of the shoulder and humerus. It has some limitations for surgical anesthesia appearing to be more suitable for shoulder arthroscopy. Although our cases appear to show that shoulder PENG block is effective in postoperative analgesia and as a part of anesthesia, there is need for more data including comparative studies with ISB plexus block, SCB, LI, and combined suprascapular and axillary nerve block.

## Conclusion

In this case report, it was demonstrated that the PENG block can be safely applied for both anesthesia and analgesia in selected shoulder surgery cases, can be a part of surgi-

cal anesthesia, but might not be sufficient for anesthesia alone. We believe that with further prospective randomized studies, optimal technique and safety of this block will be clarified.

### Informed consent

The two patients provided consent for the publication of this report.

### Conflicts of interest

The authors declare no conflicts of interest.

### References

1. Patel MS, Abboud JA, Sethi PM. Perioperative pain management for shoulder surgery: evolving techniques. *J Shoulder Elbow Surg.* 2020;29(11):e416–33, <http://dx.doi.org/10.1016/j.jse.2020.04.049>.
2. Sripada R, Bowens C Jr. Regional anesthesia procedures for shoulder and upper arm surgery upper extremity update-2005 to present. *Int Anesthesiol Clin.* 2012;50:26–46.
3. Yamak Altinpulluk E, Teles AS, Galluccio F, et al. Pericapsular nerve group block for postoperative shoulder pain: A cadaveric radiological evaluation. *J Clin Anesth.* 2020;67:110058.
4. Tran J, Peng PWH, Agur AMR. Anatomical study of the innervation of glenohumeral and acromioclavicular joint capsules: implications for image-guided intervention. *Reg Anesth Pain Med.* 2019, rapm-2018-100152.
5. Casas Reza P, Dieguez Garcia P, Gestal Vazquez M, Sampayo Rodriguez L, Lopez Alvarez S. Pericapsular nerve group block for hip surgery. *Minerva Anesthesiol.* 2020;86:463–5.