



Original Article

Evaluation of patient satisfaction and masticatory performance in mandible single implant-assisted overdenture

Swati Kashyap, Sanjeev Mittal*, Navneet Sharma, Urvashi Sukhija, Mohit Kamra, Nitika Gupta

Department of Prosthodontics,
MM College of Dental Sciences
and Research, Mullana, Haryana,
India

ABSTRACT

Objectives: Many authors' have advocated a minimum of two implants to support a mandibular overdenture, but financial restraints specifically among the geriatric population in developing countries made this treatment plan economically difficult. Hence, this study was planned to assess the symphyseal (midline) single implant-assisted complete overdenture for patient satisfaction and masticatory performance. **Materials and Methods:** In this clinical study, 12 edentulous first-time denture wearers underwent placement of a single implant in the mandibular symphyseal region. After 1 week, new complete dentures were fabricated and delivered to the patients. Post 3 months, the denture was fixed with a nylon cap-ball attachment to the anchor implant. Patients were questioned about comparison in the level of satisfaction and complaint before loading the implant (control group) and after 1 week, 1 month, and 3 months. The implant-assisted overdenture was fabricated with the help of a questionnaire. Masticatory performance was calculated with the help of a bite force measuring device at the same time intervals. SPSS 17.0 statistical software was used to analyze the data. **Results:** It was found that single implant anchorage of the mandibular complete denture resulted in a significant increase ($P < 0.05$) in patient's subjective satisfaction and a decrease ($P < 0.05$) in complaints at the end of 3 months. There was a significant ($P < 0.01$) increase in bite force in implant overdenture after 3 months (5.459 kgf) as compared to that of the complete denture (3.406 kgf). **Conclusion:** Single implant-assisted overdenture can be an appropriate treatment modality to treat edentulousness in the geriatric population. It insinuates the remarkable improvement of prosthesis function and oral comfort with minor surgical procedures.

KEYWORDS: Complete edentulous, Dental implant, Mandibular symphysis, Overdenture

Submission : 17-Sep-2020
Revision : 19-Nov-2020
Acceptance : 01-Feb-2021
Web Publication : 05-Apr-2021

INTRODUCTION

An agreeable dentition is of prime importance for a happy and healthy lifestyle. Regardless of various advances in preventive dentistry, edentulism is still a considerable problem all over the world. In the geriatric population, due to their mandibular ridge being more atrophied as compared to the maxillary one, they find a lack of retention, stability, and comfort in their mandibular denture [1]. They also suffer from denture soreness, unclear pronunciation, low chewing efficiency, and nutritional deficiency [2,3].

Although most edentulous patients appear to benefit from complete dentures and report satisfactory oral comfort and masticatory function, it is quite frequent to find patients who have lousy feeling dentures even though those dentures are prosthodontically acceptable [4]. Complete denture wearers needed four to eight times more chewing strokes than the

edentulous individual to attain the same degree of pulverization of the food. Among major factors, one which leads to a decrease in chewing performance is the reduced bite force that denture wearers can develop owing to a lack of retention and stability of the denture [5].

An endosseous implant has been proved as a promising and viable treatment option for oral rehabilitation. Various studies have described an elevated rate of success related to placement and osseointegration of implants. The implant overdenture can be considered a secure and satisfactory method for the anchorage of denture prosthesis in an edentate population [6].

*Address for correspondence:

Dr. Sanjeev Mittal,
Department of Prosthodontics, MM College of Dental Sciences and
Research, Mullana, Haryana, India.
E-mail: ambaladental@yahoo.com

Access this article online

Quick Response Code:



Website: www.tcmjmed.com

DOI: 10.4103/tcmj.tcmj_242_20

This is an open access journal, and articles are distributed under the terms of the Creative Commons Attribution-NonCommercial-ShareAlike 4.0 License, which allows others to remix, tweak, and build upon the work non-commercially, as long as appropriate credit is given and the new creations are licensed under the identical terms.

For reprints contact: WKHLRPMedknow_reprints@wolterskluwer.com

How to cite this article: Kashyap S, Mittal S, Sharma N, Sukhija U, Kamra M, Gupta N. Evaluation of patient satisfaction and masticatory performance in mandible single implant-assisted overdenture. *Tzu Chi Med J* 2021; 33(4): 406-11.

With guidance from The Glossary of Prosthodontic Terms [7], implant overdenture can be defined as removable complete or partial denture supported and retained in part or whole by a dental implant. Hence, implant overdenture may be either implant or implant-mucosa supported, depending on the number of implants and design of the prosthesis.

Many authors have done various studies regarding the minimum number of implants used for anchorage of a complete denture. They advocated a minimum of two implants to support a mandibular overdenture, but financial restraints specifically among the elderly population in developing countries made this treatment plan economically difficult [8].

As compared to the two implant-assisted overdenture, a single midline implant situated in the symphyseal area of the mandible has demonstrated to be more efficient in terms of cost, time, maintenance, and comparatively easier surgical approach which will be more beneficial to the economically unfit population, especially in India. Through an *in vitro* study, it was also verified that a single implant-assisted overdenture has more retention and stability as compared to that of a conventional one [8].

We can enhance the quality of life, improve patient satisfaction and masticatory efficiency with the use of implants but the minimum number used in this concept is still debatable. Efforts to reduce implant numbers are still ongoing. Few studies have shown that a single implant overdenture is superior to the conventional denture in terms of general satisfaction. So, this study was designed to evaluate patient satisfaction and bite force with a single midline implant-retained mandibular overdenture. The null hypothesis was that there would be no difference in patient satisfaction and maximum bite force (MBF) with the conventional denture and single implant-retained mandibular overdenture.

MATERIALS AND METHODS

A total of 12 fully edentulous first-time denture wearers (8 males and 4 females), between the age of 55 and 70 years, who had been edentulous for approximately 1 year, were selected in this within-subject crossover clinical trial. Ethical approval for the study was obtained from the Institutional Ethics Committee (IEC914). After an explanation of the proposed study criteria, including alternate treatment modalities, potential risks, and benefits, patients were asked to fill up an informed consent form before inclusion in the study. The subjects were selected after considering the following inclusion and exclusion criteria.

Inclusion criteria

1. Fully edentulous maxilla and mandible with atrophied mandibular ridge
2. Adequate bone volume for implant configuration which would be a minimum of 3.5 mm in diameter and 8 mm in length
3. Age between 55 and 70 years
4. No history of previous denture wear
5. Cooperative patient willing for surgery and proper follow-up
6. Skeletal class I patients with adequate interarch distance.

Exclusion criteria

1. Chronic smokers with poor oral hygiene
2. Any systemic or neurological diseases, e.g., diabetes, hypertension, and adrenal insufficiency
3. Any history of previous oral implant treatment
4. Insufficient bone quantity
5. Patient having parafunctional habits (e.g., clenching or bruxism) and temporomandibular disorders
6. Irradiated patient or patient undergoing chemotherapy
7. Impossibility to return to follow-up visits.

Before undergoing any surgical procedure, study models were prepared and orthopantomogram was taken for each patient. The edentulous symphyseal area was selected for implant placement and evaluated for length, width of bone, and presence of any kind of undercut buccally or lingually. At rest position, vertical dimension was evaluated for interarch space which should be a minimum of 9 mm for an implant-retained overdenture.

After attaining adequate local anesthesia, a mid crestal incision was given at the implant site and a full-thickness mucoperiosteal flap was raised. Nori's sequential drills were used to prepare the osteotomy site. Implant (Tuff, Noris Medical Pvt Ltd, Neshet, Israel) of the desired dimension was placed into the prepared site (35–45 Ncm) at the crestal bone level and covered with a cover screw. Flap closure was done with silk suture and patients were given postoperative instructions related to diet, oral hygiene, and medication.

After 1 week of implant placement following the healing of soft tissue, the patient was recalled for the fabrication of a complete denture. Dentures were fabricated having class I bilaterally balanced occlusion. Post denture instructions were given and patients were advised to wear the dentures for 3 months during the osseointegration phase. After 3 months, the patients were recalled for the measurement of MBF and to fill the questionnaire of patient satisfaction and complaint. All the recordings before loading the implant were considered as the Control Group.

Three months after the first stage of surgery, the healing abutment was placed for fifteen days. After the removal of the healing abutment, the ball abutment was tightened to 25 Ncm with a hand torque wrench [9,10] [Figure 1]. The separator was placed over the head of the ball abutment as a block out. The standard nylon cap (NM-T3017, NORIS, Neshet, Israel) with metal housing was inserted onto the ball abutment. The mandibular denture was then adjusted by providing a relief hole for the accommodation of metal housing in the denture. Metal housing was picked up in the denture with self-cure resin. During polymerization of the resin, the patient was asked to keep his/her denture in centric occlusion using moderate pressure, so that the denture base was in intimate contact with the supporting tissues [11]. Excess acrylic was trimmed off, finished, and polished [Figure 2]. The stability of mandibular overdenture was checked and the patient was instructed for its easy removal and placement. Then, the patient was recalled for the measurement of MBF and to fill the questionnaire at an interval of 1 week, 1 month, and 3 months. Denture fabrication and all the measurements were recorded by the same doctor.

Examination of patients satisfaction and complaints

The assessment of patient's satisfaction and complaint in complete denture (control group) and in implant overdenture after 1 week, 1 month, and 3 months was done with the help of a questionnaire [Table 1]. To quantify the level of satisfaction, a scale ranging from 1 to 4 ("very good/good/satisfactory/not satisfactory") and for complaint from 1 to 4 ("no/mild/moderate/severe") was used to evaluate the subjective data.

Maximum bite force measurement

Masticatory load generated was recorded using a specially designed bite gauge (LoadMaster, LIL 450, Bangalore, India). The bite gauge used was based on the principle of the strain gauge to measure the bite force. During measuring procedures, patients were seated comfortably upright in the chair with head supported. Bite tongs of the gauge were placed unilaterally in the first molar region, while occlusion was stabilized contralaterally with a block of putty [Figure 3]. Further, the patients were asked to bite onto the tongs with maximum force and were instructed to apply steady continuous pressure for 30 s. Readings that appeared on the bite force device were noted. All the measurements were done by one person.

It was important to determine whether the dentures caused pain during biting and to eliminate any pressure spots in order to avoid any difference on the part of the patients. The procedure was repeated three times for each of the right and left sides and the mean of all the readings recorded as MBF in kgf. Objective data or MBF were recorded in conventional denture (control group) and then at an interval of 1 week, 1 month, and 3 months in the mandibular implant overdenture.

Statistical Analysis: SPSS 17.0 (IBM, Chicago, USA) statistical software was used to analyze the data. Satisfaction outcomes and MBF between various time intervals were compared using Friedmann and *post hoc* Wilcoxon pair *t*-test. The association between masticatory performance and satisfaction level was calculated with the Spearman correlation test.

Table 1: Questionnaire for satisfaction and complaints measurement

Questionnaire

1. How satisfied you are with your dentures?
2. How satisfied you are with the fit of your maxillary denture?
3. How satisfied you are with the fit of your mandibular denture?
4. How satisfied you are with the appearance of your denture?
5. How satisfied you are with the speaking ability with your denture?
6. How satisfied you are with the chewing ability with your denture?
7. Are there any functional complaints (regarding speech, eating, and smiling) with your denture?
8. Is there any complaint in connection with the maxillary denture?
9. Is there any complaint in connection with the mandibular denture?
10. Is there any complaint regarding lip or cheek biting with your denture?
11. Is there any complaint regarding esthetic appearance of your denture?
12. Is there any complaint regarding handling (placement and removal) with your denture?
13. Is there any complaint regarding any kind of possible rotation effects with your denture?
14. Is there any physiognomic complaint (pinched mouth) with your denture?

RESULTS

Friedman test was done to analyze the satisfaction questioners response which showed significant improvement in ($P < 0.05$) subjective satisfaction (oral comfort and prosthesis function) and a significant decrease ($P < 0.05$) in complaints from pretreatment (control group) to all

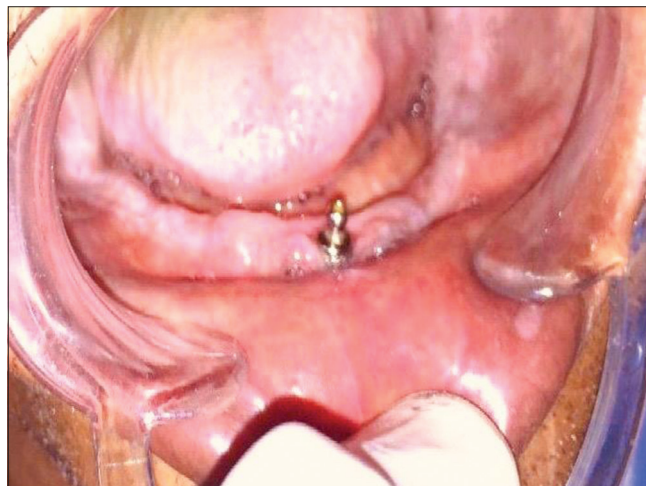

Figure 1: Implant with ball abutment after 3 months of implant placement

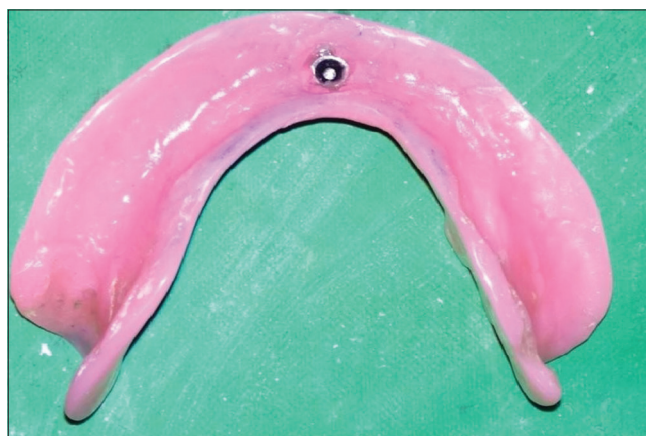

Figure 2: Nylon cap with metal housing picked up in denture using self-cured acrylic

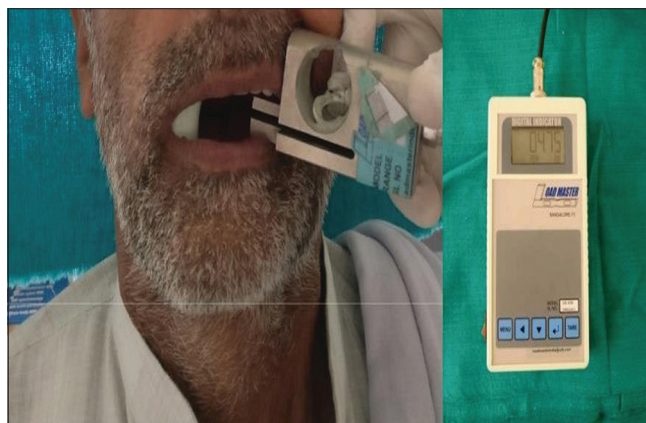


Figure 3: Maximum bite force recording with conventional upper and implant-supported mandibular overdenture

posttreatment recall. Question responses of Q2, Q8, and Q11 were insignificant [Table 2].

MBF continued to increase in implant-assisted overdenture at all the recall examinations when compared with preoperative value (control group) [Table 3]. When the Friedman test and *Post hoc* Wilcoxon pair t-test were applied for intergroup comparison of MBF at different time intervals, a significant difference ($P < 0.01$) was found in all the comparisons [Table 4].

A statistically insignificant correlation was found between MBF values and satisfaction scores at different time intervals in implant overdenture, though patient satisfaction improved over time [Table 5].

DISCUSSION

As far as the location of a single implant in an edentulous mandible is concerned, studies conducted by several authors [1-3,12] stated that the mid-symphysis region constitutes an excellent host site for an implant in terms of quantity and quality of bone. This region is also easily accessible, demands minimal time, and shows less surgical trauma, with the result that, only a few postoperative complications (pain, swelling, ecchymosis, wound dehiscence, sublingual hematoma, and neurosensory problems) were seen. Single implant overdenture needs to be relined over a period of time for a better prognosis in the future.

Patient satisfaction was evaluated with the help of a questionnaire which was also used by Krennmair and Ulm, Paleari *et al.*, and Celebić *et al.* [1,11,13] in their study. Other methods of subjective assessment are the visual analog scale used by Cordioli *et al.* [2], Cheng *et al.* [3], and Walton *et al.* [14] in their studies. In this study, delayed loading after 3 months of implant placement was done. Author Kern *et al.* reported more success rate with delayed loading of single implant overdenture than of that with immediate loading [15]. However, Tavakolizadeh *et al.* [10] and Kronstrom *et al.* [16] reported success with immediate loading of single and two implant-retained overdenture in their one and 5-year study, respectively.

The null hypothesis of the study was rejected; therefore, patient satisfaction and bite force improved in a single implant-retained mandibular overdenture. Improved chewing experience can attribute to the improved stability and retention of implant mandibular overdenture which was in favor of the studies conducted by Cheng *et al.* [3], Geertman *et al.* [17], and Passia *et al.* [18]. Patients experience a reduction ($P < 0.01$) in the functional complaint (speech, smiling, and eating) with time because of gradual adaptation to the prosthesis. Krennmair and Ulm [1] also observed the same in their study, which showed that patient experienced a decrease in complaints in implant overdenture as compared to that of conventional complete denture.

Evaluation of denture handling, i.e., denture removal and placement revealed an overall improvement after initial moderate difficulties. A significant improvement in denture handling was achieved from about 1 month by repetitive practice and active involvement of the patients. In some patients, because of distolingual undercuts, some sort of difficulties were observed during 3–4 days of use of a denture.

One disadvantage of this median ball attachment and implant position was the development of a rotational axis which was absent before anchorage of the ball attachment in the conventional denture. In a study by Emami *et al.* [19], patients with implant-retained mandibular overdenture who perceived no rotational movement were more satisfied with their denture as compared to patients who perceived rotation. Moreover, by keeping proper sublingual extensions, this complication could be prevented. Hence, in this study, we kept a proper sublingual extension to reduce any kind of possible rotation of the denture.

Different types of recording devices had been used for the measurement of MBF. Lassila *et al.* [20] used a piezoelectric device and Haraldson *et al.* [21] used pressure-sensitive films in their study. In this study, the device used to record bite force comprised of two strain gauges connected to a strain gauge measurement system through a cord. Bhat *et al.* [8], Geckili

Table 2: Questions response at various time intervals

Questions	Pre (control group)		1 week		1 month		3 months		P ^a
	Mean	SD	Mean	SD	Mean	SD	Mean	SD	
Q1 [@]	2.083	0.966	1.917	0.900	1.500	0.522	1.417	0.515	0.001* (S)
Q2 [@]	1.750	1.055	1.583	0.669	1.667	0.779	1.417	0.669	0.302 (NS)
Q3 [@]	2.750	0.866	2.00	0.603	1.667	0.492	1.333	0.492	0.0001* (S)
Q4 [@]	1.667	0.651	1.33	0.651	1.333	0.492	1.250	0.452	0.038* (S)
Q5 [@]	2.00	0.853	1.83	0.577	1.417	0.515	1.167	0.389	0.001* (S)
Q6 [@]	2.750	1.055	2.08	0.793	1.750	0.622	1.417	0.515	0.0001* (S)
Q7 [@]	2.250	0.622	1.750	0.452	1.417	0.515	1.083	0.289	0.0001* (S)
Q8 [@]	1.500	1.000	1.450	0.452	1.417	0.515	1.333	0.492	0.597 (NS)
Q9 [@]	2.500	0.674	1.75	0.452	1.58	0.515	1.250	0.452	0.001* (S)
Q10 [@]	1.167	0.651	1.167	0.389	1.000	0.000	1.000	0.000	0.001* (S)
Q11 [@]	1.167	0.389	1.250	0.452	1.083	0.289	1.083	0.289	0.392 (NS)
Q12 [@]	1.417	0.318	1.667	0.492	1.33	0.492	1.000	0.000	0.001* (S)
Q13 [@]	NA	-	1.16	0.389	1.083	0.289	1.000	0.000	0.0001* (S)
Q14 [@]	1.500	0.674	1.250	0.452	1.083	0.289	1.083	0.289	0.035* (S)

^aFriedmann test. S: Significant, NS: Nonsignificant, SD: Standard deviation, NA: Not available

Table 3: Maximum bite force (kgf) at various intervals

MBF total	Mean	SD	SE	Variance	P ^a
Pre (control group)	3.406	1.3940	0.403	1.944	0.0001* (S)
1 week	4.195	2.0730	0.598	4.297	
1 month	4.816	2.0800	0.601	4.327	
3 months	5.459	1.9650	0.567	3.861	

^aFriedmann test. S: Significant, SD: Standard deviation, SE: Standard error, MBF: Maximum bite force

Table 4: Post hoc Wilcoxon pair t-test to compare maximum bite force at different time intervals

Class (I)	Class (J)	Z	Asymptotic significant (two-tailed)
Pre (control group)	1 week	-2.981	0.003
	1 month	-3.059	0.002
	3 months	-3.059	0.002
1 week	1 month	-3.059	0.002
	3 months	-3.061	0.002
1 month	3 months	-2.981	0.003

Table 5: Spearman correlation between satisfaction and maximum bite force at various time intervals

MBF versus Q	Correlation coefficient (r)	Significant (one-tailed)/P
Pre (control) versus pre (control)	0.546	0.033 (S)
1 week versus 1 week	0.305	0.167 (S)
1 month versus 1 month	0.435	0.079 (S)
3 months versus 3 months	0.060	0.426 (S)

MBF: Maximum bite force, Q: Questionnaire response, S: Significant

et al. [22], Rismanchian *et al.* [23], and Müller *et al.* [24] also used the strain gauge measurement system in their studies.

An increase in bite force after implant loading can be explained by the fact that the dental implants help in the improvement of the functional state of the masticatory apparatus by assisting in the establishment of better neuromuscular coordination by improving support, stability, and retention of the prosthesis. The present study confirms the findings of Bakke *et al.* [25], they observed higher MBF values in all implant-treated patients. Similar results were also seen by Fontijn Tekamp *et al.* [5] and Rismanchian *et al.* [23].

A significant difference was found only between MBF pre- and MBF postoperative recall examination at 3 months because of the gradual building up experience and adaptation to the prosthesis. Like the present study, most studies on implant treatment and oral function demonstrated an improvement of masticatory function in implant-assisted overdenture as compared to the conventional denture [18,22,25-28].

Association between masticatory performance and satisfaction level was also calculated with Spearman correlation test which was found to be low with no significant association between the objective (masticatory performance) and subjective (satisfaction level) measurement. In agreement with the present study, Geckili *et al.* [22] also did not find any correlation between the two. Thus, patients with a better masticatory performance are not necessarily more satisfied, because patient satisfaction is shown to be multifactorial.

Satisfaction not only depends on chewing ability but also on esthetics and expectations of the level of retention to implant overdenture.

Different authors found similar bone loss [10,29], functional improvement, implant survival [10,16], implant and prosthetic failure [30,31] in single and two implant-assisted mandibular overdenture. Ahmed *et al.* reported a significant decrease in marginal bone loss and a number of implant failures in a single implant-retained overdenture compared to that with 2 implants [32]. The single implant-retained overdenture proved to be successful and an economic treatment protocol [33]. Hence, a greater number of edentulous patients could benefit from this new treatment modality.

The main limitation of this research was the trivial number of participants along with the short duration of the follow-up period. Considering the strict inclusion and exclusion criteria, most patients evaluated were not included in this study. More studies are required to validate the finding of this study. Further, long-term follow-up studies on this subject with a larger number of participants are recommended. Furthermore, we can compare single and two implant-retained overdenture with different attachment systems e.g., ball, locator, and magnet.

Clinical implication

Less component costs and surgical trauma in treating patients with single-implant retained overdenture as compared to that with two implant-assisted overdenture should make this treatment modality a more affordable option for geriatric patients, who are not satisfied with their conventional mandibular denture but are deterred by the expense of two implants. This treatment option can benefit the economically weaker section of the population of developing countries.

CONCLUSION

Within the limitations of this study, it appears that the single implant-assisted mandibular overdentures increased the comfort, fit, stability, MBF, and decrease the functional complaints, i.e., difficulty to speak and chew as compared with a conventional complete denture.

Financial support and sponsorship

Nil.

Conflicts of interest

There are no conflicts of interest.

REFERENCES

1. Krennmaier G, Ulm C. The symphyseal single-tooth implant for anchorage of a mandibular complete denture in geriatric patients: a clinical report. *Int J Oral Maxillofac Implants* 2001;16:98-104.
2. Cordioli G, Majzoub Z, Castagna S. Mandibular overdentures anchored to single implants: A five-year prospective study. *J Prosthet Dent* 1997;78:159-65.
3. Cheng T, Ma L, Liu LX, Sun FG, He JX, Huo YJ, et al. Use of a single implant to retain mandibular overdenture: A preliminary clinical trial of 13 cases. *J Dent Sci* 2012;7:261-6.
4. Nogueira TE, Esfandiari S, Leles CR. Cost-effectiveness analysis of the

- single-implant mandibular overdenture versus conventional complete denture: study protocol for a randomized controlled trial. *Trials* 2016;17:533.
5. Fontijn-Tekamp FA, Slagter AP, Van Der Bilt A, Van T Hof MA, Witter DJ, Kalk W, et al. Biting and chewing in overdentures, full dentures, and natural dentition. *J Dent Res* 2000;79:1519-24.
 6. Mericske-Stern RD, Taylor TD, Belser U. Management of the edentulous patient. *Clin Oral Implants Res* 2000;11(Suppl 1):108-25.
 7. The Glossary of Prosthodontic Terms: GPT-9. *J Prosthet Dent* 2017;117(Suppl 5):e1-105.
 8. Bhat S, Chowdhary R, Mahoorkar S. Comparison of masticatory efficiency, patient satisfaction for single, two, and three implants supported overdenture in the same patient: A pilot study. *J Indian Prosthodont Soc* 2016;16:182-6.
 9. Varshney N, Aggarwal S, Kumar S, Singh SP. Retention and patient satisfaction with bar-clip, ball and socket and kerator attachments in mandibular implant overdenture treatment: An *in vivo* study. *J Indian Prosthodont Soc* 2019;19:49-57.
 10. Tavakolizadeh S, Vafae F, Khoshhal M, Ebrahimzadeh Z. Comparison of marginal bone loss and patient satisfaction in single and double-implant assisted mandibular overdenture by immediate loading. *J Adv Prosthodont* 2015;7:191-8.
 11. Paleari AG, Oliveira Junior NM, Marin DOM, Rodriguez LS, Arioli Filho JN, Pero AC, et al. One-year prospective clinical study comparing patient satisfaction and masticatory performance of mandibular overdentures supported by one versus two implants. *J Appl Oral Sci* 2018;26:e20160628.
 12. Liddelow G, Henry P. The immediately loaded single implant-retained mandibular overdenture: a 36-month prospective study. *Int J Prosthodont* 2010;23:13-21.
 13. Celebić A, Knezović-Zlatarić D. A comparison of patient's satisfaction between complete and partial removable denture wearers. *J Dent* 2003;31:445-51.
 14. Walton JN, Pros C, Glick N, MacEntee MI, Pros D. A randomized clinical trial comparing patient's satisfaction and prosthetic outcomes with mandibular overdentures retained by one or two implants. *Int J Prosthodont* 2009;22:331-9.
 15. Kern M, Att W, Fritzer E, Kappel S, Luthardt RG, Mundt T, et al. Survival and complications of single dental implants in the edentulous mandible following immediate or delayed loading: A randomized controlled clinical trial. *J Dent Res* 2018;97:163-70.
 16. Kronstrom M, Davis B, Loney R, Gerrow J, Hollender L. Satisfaction and Clinical Outcomes Among Patients with Immediately Loaded Mandibular Overdentures Supported by One or Two Dental Implants: Results of a 5-Year Prospective Randomized Clinical Trial. *Int J Oral Maxillofac Implants* 2017;32:128-36.
 17. Geertman ME, Slagter AP, van 't Hof MA, van Waas MA, Kalk W. Masticatory performance and chewing experience with implant-retained mandibular overdentures. *J Oral Rehabil* 1999;26:7-13.
 18. Passia N, Wolfart S, Kern M. Six-year clinical outcome of single implant-retained mandibular overdentures--a pilot study. *Clin Oral Implants Res* 2015;26:1191-4.
 19. Emami E, de Souza RF, Bernier J, Rompré P, Feine JS. Patient perceptions of the mandibular three-implant overdenture: a practice-based study. *Clin Oral Implants Res* 2015;26:639-43.
 20. Lassila V, Holmlund I, Koivumaa KK. Bite force and its correlations in different denture types. *Acta Odontol Scand* 1985;43:127-32.
 21. Haraldson T, Jemt T, Stålblad PA, Lekholm U. Oral function in subjects with overdentures supported by osseointegrated implants. *Scand J Dent Res* 1988;96:235-42.
 22. Geckili O, Bilhan H, Mumcu E, Tuncer N. The influence of maximum bite force on patient satisfaction and quality of life of patients wearing mandibular implant overdentures. *J Oral Implantol* 2012;38:271-7.
 23. Rismanchian M, Bajoghli F, Mostajeran Z, Fazel A, Eshkevari Ps. Effect of implants on maximum bite force in edentulous patients. *J Oral Implantol* 2009;35:196-200.
 24. Müller F, Heath MR, Ott R. Maximum bite force after the replacement of complete dentures. *Gerodontology* 2001;18:58-62.
 25. Bakke M, Holm B, Gotfredsen K. Masticatory function and patient satisfaction with implant-supported mandibular overdentures: a prospective 5-year study. *Int J Prosthodont* 2002;15:575-81.
 26. Carlsson GE, Kronström M, de Baat C, Cune M, Davis D, Garefis P, et al. A survey of the use of mandibular implant overdentures in 10 countries. *Int J Prosthodont* 2004;17:211-7.
 27. Naert I, Alsaadi G, Quirynen M. Prosthetic aspects and patient satisfaction with two-implant-retained mandibular overdentures: a 10-year randomized clinical study. *Int J Prosthodont* 2004;17:401-10.
 28. van Kampen FM, van der Bilt A, Cune MS, Fontijn-Tekamp FA, Bosman F. Masticatory function with implant-supported overdentures. *J Dent Res* 2004;83:708-11.
 29. Kant B, Ranjan M, Kumar A, Mukherjee B, Pandey SM, Agarwal M, et al. A randomized controlled trial comparing the radiographic evaluation of crestal bone resorption in single implant versus two implant-retained overdentures. *J Family Med Prim Care* 2019;8:1594-8.
 30. Kronstrom M, Davis B, Loney R, Gerrow J, Hollender L. A prospective randomized study on the immediate loading of mandibular overdentures supported by one or two implants: a 12-month follow-up report. *Int J Oral Maxillofac Implants* 2010;25:181-8.
 31. Gonda T, Meda Y, Walton JN, MacEntee MI. Fracture incidence in mandibular overdentures retained by one or two implants. *J Prosthet Dent* 2010;103:178-81.
 32. Ahmed Elawady DM, Kaddah AF, Talaat Khalifa M. Single vs 2 Implants on Peri-implant Marginal Bone Level and Implant Failures in Mandibular Implant Overdentures: A Systematic Review With Meta-analysis. *J Evid Based Dent Pract* 2017;17:216-25.
 33. Mahoorkar S, Bhat S, Kant R. Single implant supported mandibular overdenture: A literature review. *J Indian Prosthodont Soc* 2016;16:75-82.