








BRIEF COMMUNICATION

Syndrome of Reversible Cardiogenic Shock and Left Ventricular Ballooning in Obstructive Hypertrophic Cardiomyopathy

Mark V. Sherrid , MD; Daniel G. Swistel, MD; Iacopo Olivetto , MD; Maurizio Pieroni , MD; Omar Wever-Pinzon , MD; Katherine Riedy, MD; Richard G. Bach, MD; Mustafa Husaini , MD; Sharon Cresci , MD; Alex Reyentovich, MD; Daniele Massera , MD; Martin S. Maron, MD; Barry J. Maron, MD; Bette Kim, MD

BACKGROUND: Cardiogenic shock from most causes has unfavorable prognosis. Hypertrophic cardiomyopathy (HCM) can uncommonly present with apical ballooning and shock in association with sudden development of severe and unrelenting left ventricular (LV) outflow obstruction. Typical HCM phenotypic features of mild septal thickening, outflow gradients, and distinctive mitral abnormalities differentiate these patients from others with Takotsubo syndrome, who have normal mitral valves and no outflow obstruction.

METHODS AND RESULTS: We analyzed 8 patients from our 4 HCM centers with obstructive HCM and abrupt presentation of cardiogenic shock with LV ballooning, and 6 cases reported in literature. Of 14 patients, 10 (71%) were women, aged 66 ± 9 years, presenting with acute symptoms: LV ballooning; depressed ejection fraction ($25\pm 5\%$); refractory systemic hypotension; marked LV outflow tract obstruction (peak gradient, 94 ± 28 mm Hg); and elevated troponin, but absence of atherosclerotic coronary disease. Shock was managed with intravenous administration of phenylephrine ($n=6$), norepinephrine ($n=6$), β -blocker ($n=7$), and vasopressin ($n=1$). Mechanical circulatory support was required in 8, including intra-aortic balloon pump ($n=4$), venoarterial extracorporeal membrane oxygenation ($n=3$), and Impella and Tandem Heart in 1 each. In refractory shock, urgent relief of obstruction by myectomy was performed in 5, and alcohol ablation in 1. All patients survived their critical illness, with full recovery of systolic function.

CONCLUSIONS: When cardiogenic shock and LV ballooning occur in obstructive HCM, they are marked by distinctive anatomic and physiologic features. Relief of obstruction with targeted pharmacotherapy, mechanical circulatory support, and myectomy, when necessary for refractory shock, may lead to survival and normalization of systolic function.

Key Words: cardiogenic shock ■ hypertrophic cardiomyopathy ■ hypertrophic obstructive cardiomyopathy ■ left ventricular ballooning ■ left ventricular outflow tract obstruction ■ supply-demand ischemia ■ Takotsubo syndrome

The course of obstructive hypertrophic cardiomyopathy (HCM) can uncommonly but dramatically be punctuated by an acute syndrome with features resembling an acute coronary syndrome, with left ventricular (LV) apical ballooning, that may occur in association with LV outflow gradients that become severe and unrelenting.¹⁻³ Indeed, 30% of an unselected cohort of admitted patients with Takotsubo syndrome have typical phenotypic features of obstructive

HCM, including mild septal thickening, high outflow gradients, elongated mitral leaflets, anterior position of the valve, and anomalous anterior papillary muscles/shortened chordae.¹ In these patients however, obstructive HCM may be overlooked because of the dramatic presentation, because the septal thickening is mild (average, 15 mm),^{1,2} and because obstruction may be latent. In this study, we report 14 patients with HCM who developed cardiogenic shock because of

Correspondence to: Mark V. Sherrid, MD, 530 First Ave, HCC 4H, New York, NY 10016. E-mail: mark.sherrid@nyulangone.org

Supplementary Material for this article is available at <https://www.ahajournals.org/doi/suppl/10.1161/JAHA.121.021141>

For Sources of Funding and Disclosures, see page 8.

© 2021 The Authors. Published on behalf of the American Heart Association, Inc., by Wiley. This is an open access article under the terms of the Creative Commons Attribution-NonCommercial-NoDerivs License, which permits use and distribution in any medium, provided the original work is properly cited, the use is non-commercial and no modifications or adaptations are made.

JAHA is available at: www.ahajournals.org/journal/jaha

this syndrome, whose treatment importantly differed from other causes of shock. Diagnosis is key, as the extent of permanent myocardial damage is diminutive despite the extensive short-term decrease in ejection fraction, and permits rapid return of normal LV systolic function and normal hemodynamics when obstruction is abolished.

METHODS

Data Sources

To appreciate this unique syndrome, we compiled information from our previously published reports in the literature of 7 patients who presented to our 4 HCM centers. One recent case that we cared for is described herein for the first time without personal health information. We also summarized 6 relevant single case reports from other authors reported in the literature.⁴⁻⁹ Because in the present article we review the previously published data in 13 patients and there is no identifying patient information, our institutional review board determined that this work did not meet the definition of human subject research and therefore, approval was not required. The materials used for this report will be shared with researchers on request. Summary statistics are presented as mean±SD.

RESULTS

Fourteen patients, aged 65.6±9 years, with 10 women (71%), had hypotension at admission (systolic blood pressure [BP], 74±9 mm Hg) and evidence of shock and greatly reduced LV ejection fraction (25±5%). Echocardiographic LV outflow peak gradient at rest was 94±28 mm Hg. Septal thickness was 16±3 mm (range, 12–20 mm). At angiography, no patient had significant coronary atherosclerotic stenosis (Tables S1 and S2).

All patients showed LV ballooning with akinesia or dyskinesia of the apical-mid segments with preservation of basal contraction. During the LV ballooning event, there was marked mitral valve systolic anterior motion (SAM) with mitral-septal contact. Severe mitral regurgitation attributable to SAM was present in 5 patients, whereas the other patients showed milder degrees (Table S2). Figures 1 and 2 show multimodality imaging of a recent representative patient. ECG abnormalities were as follows: ST-segment elevation (n=7), ST depression or diffuse T-wave inversion (n=4), or left bundle-branch block (n=2). Low-grade cardiac biomarker elevations were noted in all.

One patient had survived a prior episode of apical ballooning. Inciting events to acute deterioration included 7 patients with new-onset medical illness (including 4 with new onset of atrial fibrillation as

a contributing factor), 4 with emotional triggers, 1 after severe physical exertion, and 2 with no evident trigger.

Details of treatment administered are shown in the Table. Copious intravenous fluids were administered in 4 patients. There was no improvement from conventional inotropic therapy with dopamine and dobutamine. These agents were terminated in favor of phenylephrine, norepinephrine, or vasopressin. Intravenous β-blockade was administered to 7 patients despite the low BP and low cardiac output state; in 6 patients, β-blockers were administered concomitantly with phenylephrine to support BP. Pharmacotherapy stabilized 6 (43%) patients, allowing weaning from vasoactive medications, with return of baseline systolic LV function.

However, 8 patients required mechanical interventions, sometimes multiple: intra-aortic balloon counterpulsation (n=4), venoarterial extracorporeal membrane oxygenation (VA-ECMO) (n=3), and Impella and Tandem Heart in 1 each. Failing these measures, 5 patients had urgent surgical myectomy, 2 with concomitant mitral valve replacement because maximal septal thickness was only 16 and 17 mm, respectively. One patient with multisystem failure, too ill for myectomy, underwent alcohol septal ablation. All patients survived their acute shock events; LV systolic function normalized hours to weeks after relief of outflow obstruction. In 2 patients, there was marked improvement in systolic function within 2 hours of their operation. One additional patient with HCM required myectomy for limiting symptoms 4 months after his LV ballooning event.

DISCUSSION

The 14 patients with HCM analyzed herein developed cardiogenic shock attributable to high LV outflow peak gradients (average, 94 mm Hg) associated with LV ballooning with apical and mid-LV wall motion abnormality. These patients present with features resembling an acute coronary syndrome, but are found to have normal coronary angiograms; as such, their presentation mimics Takotsubo syndrome. However, such patients with HCM have distinctive anatomic and physiologic characteristics that set them apart from the larger group of patients with Takotsubo syndrome who have no outflow obstruction, normal mitral valves, and normal septal thickness.^{1,2} Such distinction is important in both the short-term clinical phase because of requirement for HCM-specific treatment options that differ from Takotsubo syndrome management and long-term.

LV systolic dysfunction in patients with mild septal thickening HCM is thought to be caused by supply-demand ischemia and afterload mismatch.

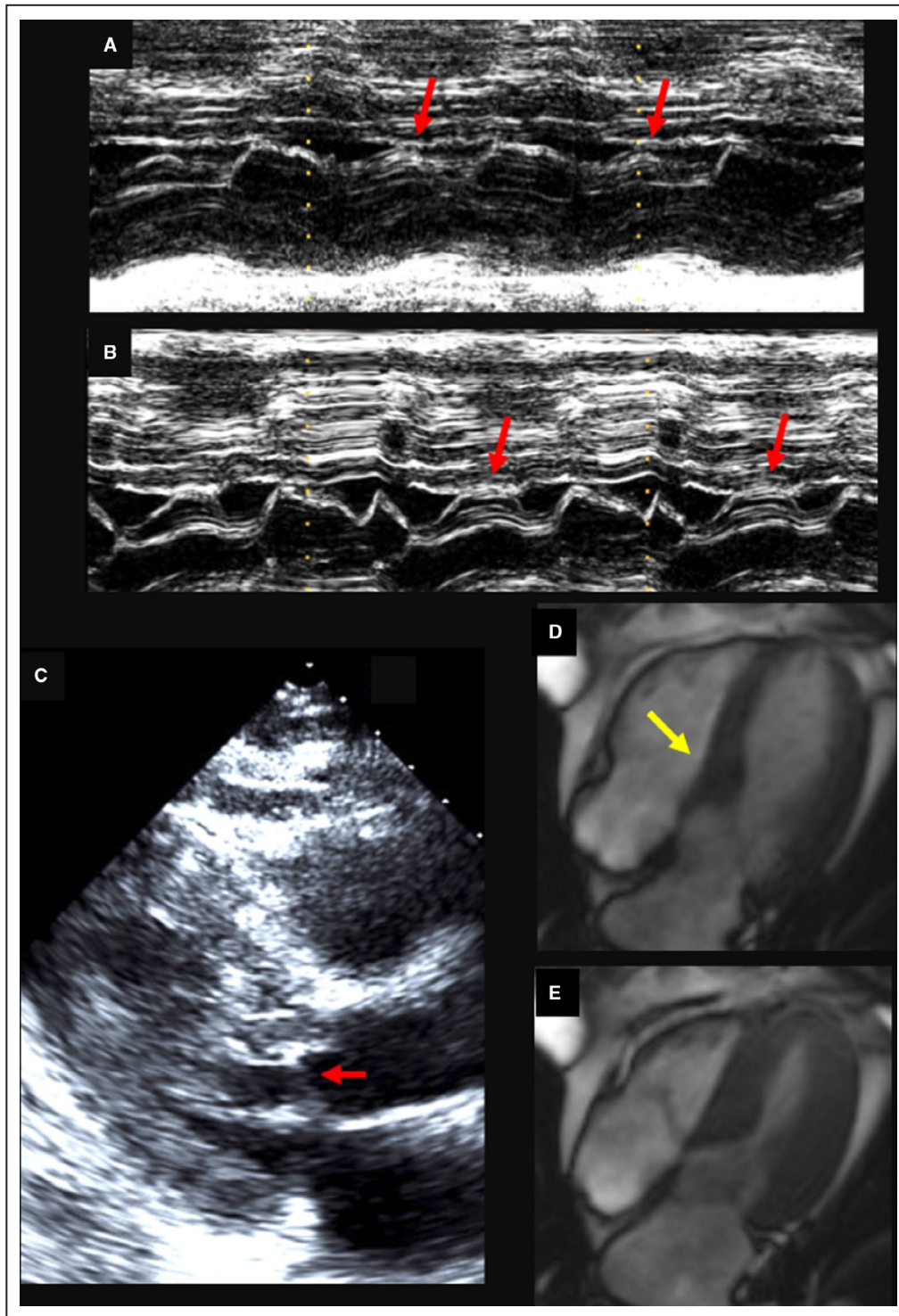


Figure 1. A 58-year-old man with hypertrophic cardiomyopathy, mild resting gradients, and provokable severe gradients, who subsequently developed severe persistent resting gradients, left ventricular (LV) ballooning, and shock.

A, Before the ballooning event, an m-mode echocardiogram is shown at rest through the mitral valve tips, showing systolic anterior motion (SAM) with transient mitral-septal contact (red arrows). **B**, Performed after Valsalva shows prolonged mitral-septal contact. Resting LV outflow gradient was 40 mm Hg, increasing to 84 mm Hg after Valsalva. **C**, Systolic parasternal long-axis view after Valsalva with SAM and mitral-septal contact (red arrow). **D**, Cardiovascular magnetic resonance imaging diastolic 4-chamber view with 17-mm anterior septal bulge (yellow arrow). **E**, Systolic frame. LV systolic function is normal. He was treated with β -blockade and then, when intolerant of that, verapamil, with stable course.

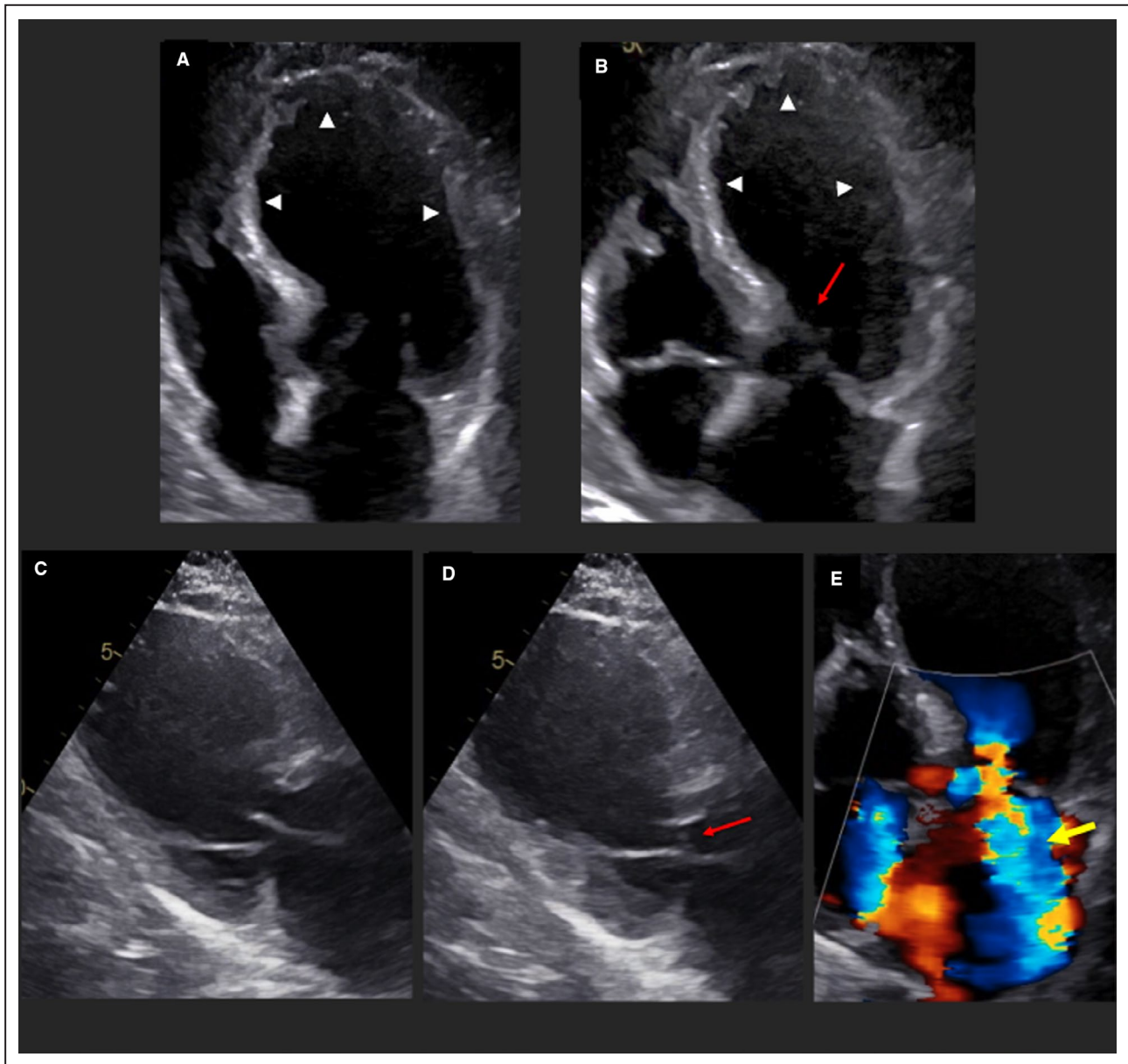


Figure 2. Same patient as Figure 1. Two years later, after 3 hours of physical labor, he developed resting chest discomfort, hypotension (blood pressure, 78/50 mm Hg), pulmonary edema, new ST-segment elevation anteriorly, and an elevated troponin I of 6 ng/mL.

His echocardiogram then showed the following: **A**, Diastolic apical 4-chamber view showing the ballooned apical and mid left ventricular (LV) segments (arrowheads). There is mild asymmetric hypertrophy. Anterior mitral valve leaflet was elongated at 29 mm. **B**, Systolic apical 4-chamber view showing mitral-septal contact and the ballooned dyskinetic and akinetic mid and apical segments (arrowheads) with systolic anterior motion (SAM) of the mitral valve and mitral-septal contact (red arrow). The resting Doppler LV outflow tract gradient was 135 mm Hg. **C**, Diastolic parasternal long-axis view showing apical mid ballooning. **D**, Systolic parasternal long-axis view showing apical-mid ballooning and mitral-septal contact (red arrow). **E**, Severe, laterally directed mitral regurgitation (yellow arrow). He was treated with intravenous (IV) metoprolol and IV phenylephrine. After 2 days of shock and persistent hypotension, he could be weaned from parenteral therapy and was discharged on oral β -blocker. Echocardiogram performed 6 weeks later showed hypertrophic cardiomyopathy (HCM), mild septal hypertrophy (13–14 mm), normal thickness of remaining segments, normal LV systolic function, resting SAM, and gradient of 40 mm Hg. Over the ensuing months, he had limiting symptoms and higher resting gradients with mitral regurgitation despite pharmacologic treatment, and thus was referred for extended surgical septal myectomy, with improvement of symptoms. He is now New York Heart Association class II 4 months after surgery. Case demonstrates how a patient with stable HCM and provokable obstruction with normal LV systolic function can suddenly develop unrelenting severe obstruction, apical ballooning, severe LV systolic dysfunction, and cardiogenic shock.

Table 1. Short-Term Treatment Received by 14 Patients With Cardiogenic Shock

Study	Copius IVF	IV β -block	Phenylephrine	Vasopressin	Norepinephrine	IABP	Impella	TH	ECMO	ASA	Acute surg
Sherrid 2011 ³	+		+								+
Sherrid 2011 ³	+	+	+		+	+					+
Sherrid 2019 ²		+									
Sherrid 2019 ²		+	+			+					
Sherrid 2019 ²			+								
Husaini 2020 ¹⁴						+	+		+		+
Caniato 2021 ¹⁵		+			+				+		+
Wever-Pinzon (Figures 1 and 2)*		+			+						
Yasutoni 1989 ^{9†}		+			+						
Cevik 2018 ^{4†}	+		+					+			+
Arakawa 2018 ^{5†}				+							
Nalluri 2018 ^{6†}			+			+					
Sosalla 2019 ^{7†}									+	+	
Sato 2020 ^{8†}	+	+			+						

Acute surg indicates urgent surgery for gradient relief; ASA, alcohol septal ablation; ECMO, venoarterial extracorporeal membrane oxygenation; IABP, intra-aortic balloon pump; IV β -block, intravenous β -blocker; IVF, intravenous fluids; and TH, Tandem Heart.

*Case reported herein for the first time. Patient had myectomy for resistant limiting symptoms from obstructive hypertrophic cardiomyopathy 4 months after recovery from his acute shock-ballooning event.

[†]Six cases previously reported by other authors.

Four lines of evidence support this pathophysiology: (1) Severe LV outflow obstruction can cause severe ischemia, documented by coronary vein lactate production and nuclear and positron emission tomography techniques. Supply-demand ischemia results from elevated LV systolic pressure and work, lowered diastolic BP with coronary underperfusion, narrowed intramural coronaries, and microvascular dysfunction. (2) Doppler evidence of inability to overcome afterload. With gradients ≥ 60 mm Hg, there is a ubiquitous *reversible* midsystolic decrease in LV pulsed Doppler ejection velocities and flow¹⁰ attributable to premature termination of segmental contraction.¹¹ This is an afterload mismatch phenomena, first observed in patients with obstructive HCM 24 years ago,¹⁰ collectively termed “paradoxical reversible systolic dysfunction.” Systolic impairment is paradoxical because HCM is understood as a hyperdynamic condition. This is evidence of instantaneous systolic heart failure attributable to afterload. We believe that ballooning in HCM is a more severe manifestation of dynamic systolic dysfunction attributable to sudden outflow obstruction. (3) We have not observed LV ballooning in our patients with nonobstructive HCM, nor, to our knowledge, has it been reported in the literature. This underscores the causative importance of high gradients in ballooning. (4) The rapid resolution of refractory shock and severe LV systolic dysfunction after septal reduction in 6 of our patients is compelling evidence that obstruction causes the LV dysfunction. Two patients had rapid improvement in LV function within 2 hours of surgery.³

In apical ballooning, it has been proposed that outflow obstruction results from a narrowed hyperkinetic outflow tract, with development of Venturi forces there, attributable to functional alteration of LV geometry. However, the weight of evidence about SAM in HCM is that it is caused by flow drag, the pushing force of flow, and not by a Venturi effect. Outflow velocities are low in obstructive HCM when SAM begins, precluding Venturi forces as a mechanism.^{12,13} In patients with obstructed HCM with apical ballooning, we propose that mitral-septal contact is not a result of wall motion abnormalities, but instead may be their cause.¹⁻³

We previously reported that an episode of acute apical ballooning occurred in about 1% of patients in our prospectively acquired database of patients with HCM.² Of those with ballooning, cardiogenic shock occurred in a third. A common denominator of the patients with obstructive HCM with ballooning has been relatively mild septal thickening, about 15 mm, less than in our other patients with HCM, 20 mm,^{1,2} and now, in patients with obstructive HCM with shock, where septal thickness was 16 mm. We hypothesize

that in the typical patient with HCM, severe hypertrophy acts as a buttress to prevent the development of ballooning. In contrast, in patients with ballooning, mildly thickened walls may be unprepared to perform in the face of high LV pressures, and extremely high wall stress. (Wall thickness is in the denominator of the wall stress equation.)

In obstructive HCM, mitral regurgitation is caused by SAM and dynamic deformation of the mitral valve. Of the 14 patients, 5 had severe mitral regurgitation associated with outflow gradients that undoubtedly contributed to their low stroke volume and shock.

Therapy

Because LV outflow gradients are the cause of the acute deterioration, therapy is targeted to abolish SAM and mitral-septal contact. Initial measures designed to reverse provoking causes are administered: intravenous fluids for volume depletion, blood transfusion for anemia, and urgent cardioversion for rapid atrial fibrillation. The mainstay of therapy of patients with HCM with apical ballooning, but without hemodynamic instability, is β -blocker therapy, administered intravenously.² Although it may seem counterintuitive to treat with β -blockers when BP is borderline or low, nevertheless in our experience, LV outflow gradients often decrease, and BP either increases or remains unchanged. We typically administer intravenous metoprolol, 15 mg, over 15 minutes with careful monitoring of BP and heart rate. We have found such therapy to be safe in this scenario. Esmolol infusion is an alternative; however, titration may require time. We therefore prefer metoprolol. However, when hypotension and poor tissue perfusion are evident, pharmacologic choices become limited. We are reticent to administer metoprolol alone to patients with systolic BP < 80 mm Hg; when this occurs, the combination of phenylephrine to support BP along with metoprolol is preferred.

Positive inotropic agents, such as dopamine, dobutamine, and milrinone, should be explicitly avoided because the drugs worsen dynamic obstruction and exacerbate shock. Six of our patients could be successfully managed by reversing outflow obstruction with pharmacotherapy, whereas the majority required advanced invasive therapy.

Mechanical Circulatory Support

The differences between methods of invasive circulatory support have previously been described. Although intra-aortic balloon counterpulsation improves coronary perfusion during diastole, the presystolic deflation decreases afterload and may thus worsen, or produce de novo LV outflow obstruction. The Impella catheter delivers blood into the proximal aorta, decreases

preload, and offers partial LV support. However, decreasing LV cavity size in HCM may promote SAM and increase LV outflow obstruction. The same phenomenon may occur with the Tandem Heart. In contrast, VA-ECMO increases afterload by retrograde flow, while augmenting cardiac output and coronary perfusion. Obstructive HCM physiology generally responds well to mildly increased afterload. VA-ECMO offers full circulatory support for the sickest patients, and can be initiated rapidly at the bedside.

Of the 14 patients, intra-aortic balloon counterpulsation was used in 4 and may have aided recovery in 2, but failed to improve shock in the other 2. VA-ECMO stabilized BP in 3 patients who were supported for 4 to 13 days; its use has been successful in 2 other prior reports of shock attributable to LV outflow obstruction. When it is locally available, VA-ECMO may be the best choice for temporary circulatory support, to allow the LV to recover, or as a bridge to septal reduction therapy. Weaning should be tried after stabilization. However, when tapering from VA-ECMO cannot be achieved, because of recurrent obstruction, septal reduction is the next step. Durable LV assist devices have been used successfully in patients with HCM as a bridge to transplantation, although small chamber sizes and LV muscle bundles can impede the inflow cannula. We do not advocate for durable LV assist device use herein because relatively rapid, complete reversal of abnormal systolic function is expected on abolition of outflow obstruction.

Septal Myectomy

Surgical relief of LV outflow obstruction is the definitive therapy to immediately and permanently abolish LV outflow gradient, and to reduce afterload and supply-demand ischemia. Of the 14 patients, 5 required urgent surgical myectomy, 2 with concomitant mitral valve replacement in 2007. In the current era, these 2 patients, with septal thicknesses of 16 and 17 mm, respectively, would not have mitral valve replacement; rather, with refined surgical techniques developed since then, shallow but extended myectomy would be performed with consideration of ancillary mitral valve repair (ie, mitral shortening for an elongated anterior leaflet or chordal cutting when these structures position the mitral valve in the flow stream). However, in that era of \approx 2007, mitral valve replacement was the norm for patients with thin septum. In that era, at that time, our judgement was to definitively abolish LV outflow obstruction without the potential need for a second pump run that the patient might not survive. In making these judgements in critically ill patients, the risk of "undertreating" is greater than that of "overtreating." One additional patient required surgical myectomy for limiting symptoms and

gradient 4 months after recovery from the LV ballooning event.

One patient had "bail-out" alcohol septal ablation performed because multisystem failure precluded myectomy. Because alcohol ablation causes a septal infarct, there is the potential for exacerbating hemodynamic instability. Also, surgery provides immediate and reliable relief of obstruction, compared with ablation, which may require weeks for effect. For these reasons, we recommend surgery over alcohol ablation. The institution of cardiopulmonary bypass itself can reverse the ischemic process. Indeed, in 2 patients, after the bypass run and abolishing outflow obstruction, we observed improvement in LV function almost immediately.³ Although there is understandable reticence to operate on patients with acute myocardial ischemia, cardiogenic shock, and systemic acidosis, when pharmacotherapy fails to reverse shock, surgical intervention is necessary. Indeed, this clinical scenario is one of the few in HCM requiring emergent surgical intervention. When LV outflow gradients cause obstruction and ballooning, the patients with HCM may be confused with the larger group of patients with non-HCM Takotsubo syndrome. In this clinical scenario, decisions must be made in hours, often in the emergency department, and misdiagnosis of the true pathophysiology can result in fatal missteps, underscoring the need for a prepared team. Familiarity with the many anatomic variants found in HCM, particularly of the mitral valve, can speed recognition. Figure S1 summarizes our recommended approach for these critically ill patients.

We acknowledge the possibility of publication bias; patients who do not do well may not be the subject of case reports, and patients who have succumbed from this syndrome may not have come to our attention. We also acknowledge that natural history of LV ballooning syndrome often results in spontaneous and complete resolution. We believe this would not have been the case for our patients who required mechanical support and septal reduction who were in extremis before their interventions.

CONCLUSIONS

When shock occurs in obstructive HCM with LV ballooning, therapy targeted to reduce or abolish obstruction may lead to survival with complete recovery of LV systolic function. Reversing provoking factors, like dehydration, anemia, and atrial fibrillation, should be instituted first. Pharmacologic therapy with β -blockade and vasoconstrictor medication may reverse outflow obstruction and shock. However, if initial measures do not improve shock

or if the patient cannot be weaned from intravenous therapy, circulatory support with VA-ECMO or other modalities should be promptly instituted. If mechanical support cannot be discontinued, and high gradients persist, surgical relief of obstruction should be undertaken urgently.

ARTICLE INFORMATION

Received February 2, 2021; accepted August 17, 2021.

Affiliations

Hypertrophic Cardiomyopathy Program (M.V.S., K.R., D.M.); and Department of Cardiothoracic Surgery (D.G.S.), NYU Langone Health, New York, NY; Cardiomyopathy Unit, Division of Cardiology, Careggi University Hospital, Florence, Italy (I.O.); Cardiovascular Department, San Donato Hospital, Arezzo, Italy (M.P.); University of Utah Health, Salt Lake City, UT (O.W.); Washington University Medical Center, St. Louis, MO (R.G.B., M.H., S.C.); Leon Charney Division of Cardiology, Heart Failure Advanced Care Center, NYU Langone Health, New York, NY (A.R.); Tufts Medical Center, Boston, MA (M.S.M., B.J.M.); and Mount Sinai West, New York, NY (B.K.).

Sources of Funding

None.

Disclosures

Dr Olivetto reports grants and personal fees from MyoKardia BMS, Sanofi Genzyme, Shire Takeda, and Amicus; and grants from Bayer and Menarini International. Dr Bach reports grants from MyoKardia, Cytokinetics, and CSL Behring; and personal fees from Novo Nordisk, NGM Biopharmaceuticals, Pharmacosmos, and Cirus. Dr Massera reports personal fees from Bristol Myers Squibb. All other authors have no disclosures to report.

Supplementary Material

Figure S1

Tables S1–S2

REFERENCES

- Sherrid MV, Riedy K, Rosenzweig B, Massera D, Saric M, Swistel DG, Ahluwalia M, Arabadjian M, DeFonte M, Stepanovic A, et al. Distinctive hypertrophic cardiomyopathy anatomy and obstructive physiology in patients admitted with Takotsubo syndrome. *Am J Cardiol*. 2020;125:1700–1709. doi: 10.1016/j.amjcard.2020.02.013
- Sherrid MV, Riedy K, Rosenzweig B, Ahluwalia M, Arabadjian M, Saric M, Balam S, Swistel DG, Reynolds HR, Kim B. Hypertrophic cardiomyopathy with dynamic obstruction and high left ventricular outflow gradients associated with paradoxical apical ballooning. *Echocardiography*. 2019;36:47–60. doi: 10.1111/echo.14212
- Sherrid MV, Balaran SK, Korzeniecki E, Chaudhry FA, Swistel DG. Reversal of acute systolic dysfunction and cardiogenic shock in hypertrophic cardiomyopathy by surgical relief of obstruction. *Echocardiography*. 2011;28:E174–E179. doi: 10.1111/j.1540-8175.2011.01459.x
- Cevik C, Nguyen HU, Civitello AB, Simpson L. Percutaneous ventricular assist device in hypertrophic obstructive cardiomyopathy with cardiogenic shock: bridge to myectomy. *Ann Thorac Surg*. 2012;93:978–980. doi: 10.1016/j.athoracsur.2011.07.079
- Arakawa K, Gondo T, Matsushita K, Himeno H, Kimura K, Tamura K. Takotsubo cardiomyopathy in a patient with previously undiagnosed hypertrophic cardiomyopathy with latent obstruction. *Intern Med*. 2018;57:2969–2973. doi: 10.2169/internalmedicine.0675-17
- Nalluri N, Asti D, Anugu VR, Ibrahim U, Lafferty JC, Olkovsky Y. Cardiogenic shock secondary to Takotsubo cardiomyopathy in a patient with preexisting hypertrophic obstructive cardiomyopathy. *CASE (Phila)*. 2018;2:78–81. doi: 10.1016/j.case.2017.09.008
- Sossalla S, Meindl C, Fischer M, Lubnow M, Müller T, Maier LS. Bail-out alcohol septal ablation for hypertrophic obstructive cardiomyopathy in a patient with takotsubo cardiomyopathy-induced cardiogenic shock. *Circ Cardiovasc Interv*. 2019;12:e007425. doi: 10.1161/CIRCINTERVENTIONS.118.007425
- Sato Y, Matsumoto K, Sakai J, Nakamura T, Tanaka H, Hirata K. "Incompatible housemates": hypertrophic obstructive cardiomyopathy and Takotsubo syndrome. *Intern Med*. 2020;59:957–962. doi: 10.2169/internalmedicine.3890-19
- Yasutomi N, Kogame T, Kawakami K, Komasa N, Iwasaki T. Stunned myocardium in hypertrophic cardiomyopathy with normal coronary arteries. *Am Heart J*. 1989;118:1069–1073. doi: 10.1016/0002-8703(89)90251-2
- Sherrid MV, Gunsburg DZ, Pearle G. Mid-systolic drop in left ventricular ejection velocity in obstructive hypertrophic cardiomyopathy—the lobster claw abnormality. *J Am Soc Echocardiogr*. 1997;10:707–712. doi: 10.1016/S0894-7317(97)70112-3
- Barac I, Upadya S, Pilchik R, Winson G, Passick M, Chaudhry FA, Sherrid MV. Effect of obstruction on longitudinal left ventricular shortening in hypertrophic cardiomyopathy. *J Am Coll Cardiol*. 2007;49:1203–1211. doi: 10.1016/j.jacc.2006.10.070
- Ro R, Halpern D, Sahn DJ, Homel P, Arabadjian M, Lopresto C, Sherrid MV. Vector flow mapping in obstructive hypertrophic cardiomyopathy to assess the relationship of early systolic left ventricular flow and the mitral valve. *J Am Coll Cardiol*. 2014;64:1984–1995. doi: 10.1016/j.jacc.2014.04.090
- Sherrid MV, Gunsburg DZ, Moldenhauer S, Pearle G. Systolic anterior motion begins at low left ventricular outflow tract velocity in obstructive hypertrophic cardiomyopathy. *J Am Coll Cardiol*. 2000;36:1344–1354. doi: 10.1016/S0735-1097(00)00830-5
- Husaini M, Baker JN, Cresci S, Bach R, LaRue SJ. Recurrent Takotsubo cardiomyopathy in a patient with hypertrophic cardiomyopathy leading to cardiogenic shock requiring VA-ECMO. *JACC Case Rep*. 2020;2:1014–1018.
- Caniato F, Andrei V, Bernardo P, Agostini C, Cappelli R, Stefano PL, Olivetto I, Pieroni M, Bolognese L, Di Mario C. Cardiogenic shock in obstructive hypertrophic cardiomyopathy plus apical ballooning: management with VA-ECMO and myectomy. *JACC Case Rep*. 2021;3:433–437. doi: 10.1016/j.jaccas.2020.11.029

SUPPLEMENTAL MATERIAL

Figure S1. Treatment paradigm for obstructive HCM with LV ballooning and cardiogenic shock

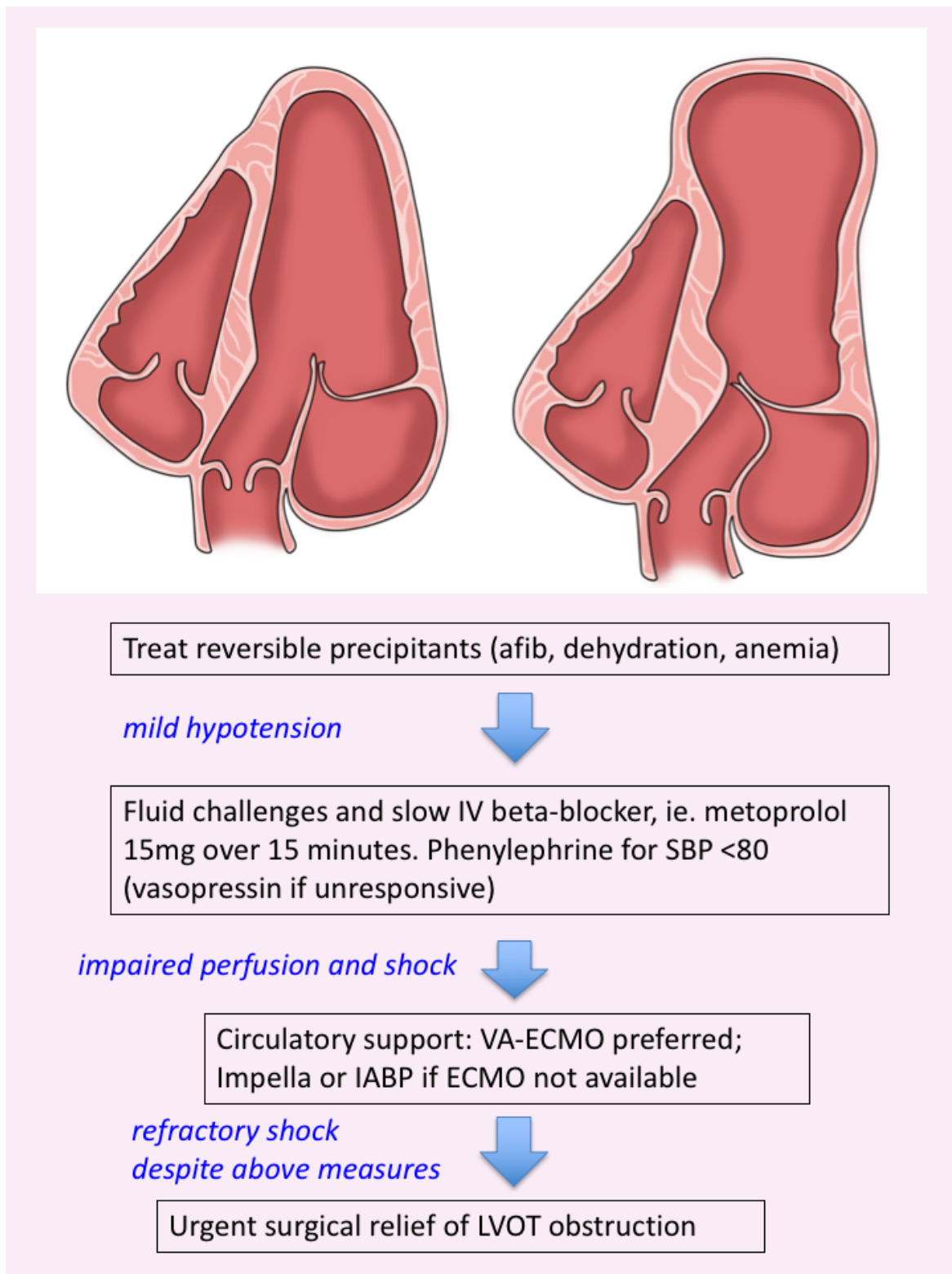


Table S1. Clinical characteristics of 14 Obstructive HCM Patients with Cardiogenic Shock and Acute LV Ballooning

Author	Sex	Age	Precipitant	ECG	Trop I ng/ml CPK (U/dl)	Shock BP (mmHg)	Pedema
Sherrid 2011 ³	M	70	Gastroenteritis with diarrhea	LVH with more ST depressions laterally	Trop I 1.2	77/42	+
Sherrid 2011 ³	M	52	None	Diffuse ST depressions; enzyme elevations.	NM	80/50	0
Sherrid 2019 ²	F	63	gastroenteritis	ST elevation and Q waves anteriorly	Trop I 2.4	80/60	0
Sherrid 2019 ²	F	66	Delivered eulogy	ST depression and TWI	Trop I 1.4	82/59	+
Sherrid 2019 ²	F	61	None	LVH, ST elev 1, AvL	Trop I 2.72	83/61	0
Husaini 2020 ⁴	F	68	Husband's severe illness	LBBB	Trop T 0.46	83/59	+
Caniato 2021 ⁵	M	49	pulmonary infection, atrial fibrillation	Repolarization abnormalities	hsTnT 165 pg/mL; CK-MB 7.2mcg/L	80/50	+
*Wever-Pinzon, Fig 1,2	M	58	Exhaustion p 3 hrs labor	Anterior ST elevations	Trop 6	78/50	+
Yasutoni 1989 ^{11†}	F	63	Uterine CA chemo, dehydration	ST elevation and TWI 2,3,AvF,V2-V6;	CPK 257 MB 9%.	58/	0
Cevik 2018 ^{6†}	F	69	New onset Afib	Afib, LBBB with LAD	NM	70/50	+
Arakawa 2018 ^{7†}	F	62	Severe emotional stress	ST elevation I, aVL, V3-V6	Trop I 1.53	78/50 to 48/24	0
Nalluri 2018 ^{8†}	F	81	GI bleeding, anemia, Afib	Precordial TWI	Trop I 1.26	60/40	+
Sosalla 2019 ^{9†}	F	78	Extreme weather	NM	Trop elevated	NM	-
Sato 2020 ^{10†}	F	81	Influenza; afib	Anterior ST elevation with loss of R waves	Trop I 8.86 CKMB 11	132/96 to 74/40	0

*Patient reported here for the first time. † Six cases reported by other authors.

Coro Sten=coronary stenosis; hsTnT=high sensitivity troponin T; NM=not mentioned in case report; pedema=pulmonary edema; Trop=troponin; TWI=T wave inversion

Table S2. Acute echocardiographic findings in 14 patients with shock

Author	LVOT gradient (mmHg)	LVEF(%)	Septal thick (mm)	MR (0-4);	Mitral morphology
Sherrid 2011³	90	25	17	2	Elong leaf
Sherrid 2011³	135	25	16	2	Anom PM
Sherrid 2019²	60	30	14	4	Elong leaf; Anom PM
Sherrid 2019²	80	25	13	4	Elong leaf
Sherrid 2019²	100	25	12	NM	NM
Husaini 2020⁴	46 initially and then severe	30	19	1	Elong leaf
Caniato 2021⁵	90	15	18	3-4	Elong leaf
*Wever-Pinzon, Fig 1,2	135	30	19	3-4	Elong leaf
Yasutoni 1989¹¹ †	120	NM	20	NM	-
Cevik 2018⁶ †	>50 "severe"	20	NM	NM	-
Arakawa 2018⁷ †	59	NM	mild basal bulge	4	-
Nalluri 2018⁸ †	>90	20-25	ASH	4	-
Sosalla 2019⁹ †	120	30	16-17	4	-
Sato 2020¹⁰ †	107	NM	mild basal bulge	3	-

*Patient reported here for the first time. † Six cases reported by other authors.

Anom PM=anomalous papillary muscle; Elong leaf=Elongated mitral leaflet(s);

NM=not mentioned in case report

Additional Resources

Rowin EJ, Maron BJ, Chokshi A, Kannappan M, Arkun K, Wang W, Rastegar H, Maron MS. Clinical Spectrum and Management Implications of Left Ventricular Outflow Obstruction With Mild Ventricular Septal Thickness in Hypertrophic Cardiomyopathy. *Am J Cardiol* 2018;122:1409-1420.

Alhaj EK, Kim B, Cantales D, Uretsky S, Chaudhry FA, Sherrid MV. Symptomatic Exercise-Induced Left Ventricular Outflow Tract Obstruction without Left Ventricular Hypertrophy. *J Am Soc Echocardiog* 2013;26:556-565.

Patel P, Dhillon A, Popovic ZB, Smedira NG, Rizzo J, Thamilarasan M, Agler D, Lytle BW, Lever HM, Desai MY. Left Ventricular Outflow Tract Obstruction in Hypertrophic Cardiomyopathy Patients Without Severe Septal Hypertrophy: Implications of Mitral Valve and Papillary Muscle Abnormalities Assessed Using Cardiac Magnetic Resonance and Echocardiography. *Circ Cardiovasc Imaging* 2015;8:e003132.

Sherrid MV, Balam S, Kim B, Axel L, Swistel DG. The Mitral Valve in Obstructive Hypertrophic Cardiomyopathy: A Test in Context. *J Am Coll Cardiol* 2016;67:1846-1858.

Sherrid MV, Manner J, Swistel DG, Olivotto I, Halpern DG. On the Cardiac Loop and Its Failing: Left Ventricular Outflow Tract Obstruction. *J Am Heart Assoc* 2020;9:e014857.

Sherrid MV, Wever-Pinzon O, Shah A and Chaudhry FA. Reflections of inflections in hypertrophic cardiomyopathy. *J Am Coll Cardiol*. 2009;54:212-9.

Breithardt OA, Beer G, Stolle B, Lieder F, Franke A, Lawrenz T, Hanrath P, Kuhn H. Mid systolic septal deceleration in hypertrophic cardiomyopathy: clinical value and insights into the pathophysiology of outflow tract obstruction by tissue Doppler echocardiography. *Heart* 2005;91:379-380.

Ormerod JO, Frenneaux MP, Sherrid MV. Myocardial energy depletion and dynamic systolic dysfunction in hypertrophic cardiomyopathy. *Nat Rev Cardiol* 2016;13:677-687.

Cannon RO, 3rd, Schenke WH, Maron BJ, Tracy CM, Leon MB, Brush JE, Jr., Rosing DR and Epstein SE. Differences in coronary flow and myocardial metabolism at rest and during pacing between patients with obstructive and patients with nonobstructive hypertrophic cardiomyopathy. *J Am Coll Cardiol*. 1987;10:53-62.

Cecchi F, Sgalambro A, Baldi M, Sotgia B, Antonucci D, Camici PG, Sciagra R and Olivotto I. Microvascular dysfunction, myocardial ischemia, and progression to heart failure in patients with hypertrophic cardiomyopathy. *J Cardiovasc Transl Res*. 2009;2:452-61.

Sherrid MV, Razzouk L, Massera D. Letter by Sherrid et al Regarding Article, "Bail-Out Alcohol Septal Ablation for Hypertrophic Obstructive Cardiomyopathy in a Patient With Takotsubo Cardiomyopathy-Induced Cardiogenic Shock". *Circ Cardiovasc Interv* 2019;12:e007977.

Yoshioka T, Hashimoto A, Tsuchihashi K, Nagao K, Kyuma M, Ooiwa H, Nozawa A, Shimoshige S, Eguchi M, Wakabayashi T et al. Clinical implications of midventricular obstruction and intravenous propranolol use in transient left ventricular apical ballooning (Tako-tsubo cardiomyopathy). *Am Heart J*. 2008;155.

Santoro F, Ieva R, Ferraretti A, Fanelli M, Musaico F, Tarantino N, Martino LD, Gennaro LD, Caldarola P, Biase MD and Brunetti ND. Hemodynamic Effects, Safety, and Feasibility of Intravenous Esmolol Infusion During Takotsubo Cardiomyopathy With Left Ventricular Outflow Tract Obstruction: Results From A Multicenter Registry. *Cardiovasc Ther.* 2016;34:161-6.

Kyuma M, Tsuchihashi K, Shinshi Y, Hase M, Nakata T, Ooiwa H, Abiru M, Hikita N, Adachi T, Shoji T et al. Effect of intravenous propranolol on left ventricular apical ballooning without coronary artery stenosis (ampulla cardiomyopathy): three cases. *Circ J.* 2002;66:1181-4.

Schafer A, Werner N, Westenfeld R, Moller JE, Schulze PC, Karatolios K, Pappalardo F, Maly J, Staudacher D, Lebreton G et al. Clinical scenarios for use of transvalvular microaxial pumps in acute heart failure and cardiogenic shock - A European experienced users working group opinion. *Int J Cardiol.* 2019;291:96-104.

Cohen R, Rivagorda J and Elhadad S. Asymmetric septal hypertrophy complicated by dynamic left ventricular obstruction after intra-aortic balloon counterpulsation placement in the setting of anterior myocardial infarction. *J Invasive Cardiol.* 2006;18:E207-8.

Tse RW, Masindet S, Stavola T, Dervan JP and Lawson WE. Acute myocardial infarction with dynamic outflow obstruction precipitated by intra-aortic balloon counterpulsation. *Cathet Cardiovasc Diagn.* 1996;39:62-6.

Coddens J, Van Alphen J, Deloof T and Hendrickx J. Dynamic left ventricular outflow tract obstruction caused by afterload reduction induced by intra-aortic balloon counterpulsation. *J Cardiothorac Vasc Anesth.* 2002;16:749-51.

Fernandes A, Toledano K, Saczkowski R, Laliberte E, El-Hamamsy I and Denault A. Systolic Anterior Motion of the Mitral Valve Triggered by the Intra-Aortic Balloon Pump. *J Cardiothorac Vasc Anesth.* 2016;30:432-6.

Bonacchi M, Maiani M, Harmelin G and Sani G. Intractable cardiogenic shock in stress cardiomyopathy with left ventricular outflow tract obstruction: is extra-corporeal life support the best treatment? *Eur J Heart Fail.* 2009;11:721-7.

Oxlund CS, Poulsen MK, Jensen PB, Veien KT and Moller JE. A case report: haemodynamic instability due to true dynamic left ventricular outflow tract obstruction and systolic anterior motion following resuscitation: reversal of haemodynamics on supportive veno-arterial extracorporeal membrane oxygenation. *Eur Heart J Case Rep.* 2018;2:ty134.