

Catastrophic Failure of the Acetabular Polyethylene Liner in Ceramic-on-Polyethylene Total Hip Arthroplasty

Givenchy Manzano¹, Rayna A. C. Levine², Michael B. Mayor², Ran Schwarzkopf¹

What to Learn from this Article?

Unusual and Rare Complication of THR with its Management.

Abstract

Introduction: Catastrophic polyethylene failure is a rare complication of ceramic-on-polyethylene total hip arthroplasty due to the favorable tribological characteristics of ceramic. Failure of the polyethylene liner can be disastrous, increasing periprosthetic osteolysis, metallosis, and risk of dislocation. Complications associated with ceramic-on-polyethylene articulations have been studied extensively, however, only few reports have described its catastrophic wear. We report such a case of complete wear of the acetabular liner in a ceramic-on-polyethylene prosthesis in a 57-year adult male.

Case Report: A 57-year adult male with a history of bilateral total hip arthroplasty presented to our institution with bilateral hip pain worst on the right. Range of motion was limited by pain on the right hip at the extremes of motion. Radiographs revealed severe osteolysis, heterotopic ossification, complete wear of the acetabular liner, bony impingement of the femoral greater trochanter on the acetabular rim and superior migration of the femoral head. All findings were confirmed intraoperatively. Revision of the acetabular components was performed, which successfully alleviated the patient's symptoms.

Conclusion: Failure of the ceramic-on-polyethylene liner in our patient is due to the use of a non-cross linked polyethylene liner, a highly active lifestyle, and poor follow up. Arthroplasty surgeons should be aware of this complication especially in highly active patients with a conventional polyethylene liner and chronic hip pain.


Keywords: Total hip arthroplasty; polyethylene wear; ceramic femoral head; metallosis; osteolysis.

Introduction

Wear of the acetabular polyethylene liner is an expected complication of total hip arthroplasty. Polyethylene wear contributes to both periprosthetic osteolysis and aseptic loosening after total hip arthroplasty. Failure of the polyethylene liner depends on patient, implant, and

surgery related factors [1]. When metal femoral heads are used, there is an increased risk of complete wear through of the polyethylene acetabular liner and metal shell, increasing the risk of wear induced osteolysis, which is one of the most important factors contributing to failure of total hip arthroplasty[2].

Author's Photo Gallery




Dr. Givenchy Manzano



Dr. Rayna A. C. Levine



Dr. Michael B. Mayor



Dr. Ran Schwarzkopf

Reviewer's Photo Gallery



Dr. Aditya Pathak



Dr. Mohamed Saleh Moustafa Hassan

¹Department of Orthopaedic Surgery, University of California Irvine Medical Center.

²Dartmouth Biomedical Engineering Center, Thayer School of Engineering, Dartmouth College.

Address of Correspondence

Dr. Ran Schwarzkopf, Department of Orthopaedic Surgery, University of California Irvine, 101 The City Drive South, Orange, CA 92868.
Phone No. 714 456 5759. E-mail: schwarzr@uci.edu

In efforts to reduce polyethylene wear, the use of ceramic bearings has become an appealing option in total hip arthroplasty. Ceramic's higher resistance to scratching compared to chromium cobalt (CoCr), and inert qualities in an aqueous environment contribute to the lower linear and volumetric polyethylene wear rates seen in ceramic on polyethylene bearings compared to CoCr on polyethylene bearings[3]. Alumina and zirconia comprise the two main ceramic bearings available, with the former having lower polyethylene wear rates[4] due to phase transformation seen in zirconia causing increased surface roughness[5]. Several studies have shown alumina ceramic heads to produce consistent polyethylene wear rates of 0.03mm/year [6-8], while other studies report variable outcomes in polyethylene wear reporting 0.01-0.34mm/year[5,9,10]. A wear rate of 0.2mm/year and higher has been shown to be predictive of failure[11]. Reports in the literature of catastrophic wear of the ceramic-polyethylene articulation have implicated acetabular inclination $>45^\circ$, use of gamma sterilized polyethylene, increased activity level, age <50 , and backside wear as causes of failure[12,13]. We report a case of catastrophic polyethylene failure where the ceramic femoral head completely wore through the polar region of the polyethylene liner and imprinted in to the metal acetabular shell resulting in aseptic loosening, severe osteolysis, and periarticular metallosis. We suggest that this failure is mainly due to the use of a non-crosslinked polyethylene liner, the patient's highly active lifestyle, and poor follow up.

Case Report

A 57-year-old African American male with a history of

bilateral total hip arthroplasty, presented to our clinic with progressively worsening bilateral hip pain that is worst on the right. The patient underwent bilateral total hip arthroplasty in 1994 and 1995 with a Wright Technology Interseal Ceramic-on-Non-Crosslinked Polyethylene Hip System (Wright Technologies; Arlington, TN) for a diagnosis of avascular necrosis. The acetabular cup measured 54mm(O.D)/28mm(ID) and the ceramic head measured 28mm. The patient underwent replacement of the acetabular components and femoral head of his left total hip arthroplasty in 1999 at an outside facility due to implant failure after an athletic injury. In 2004, he began complaining of pain, which was localized to both his hips but worst on the right. Despite this pain, he remained engaged in light athletic activities 7 days a week and did not follow up with his physician for annual check-ups. 1 month prior to his presentation, the patient noticed pain radiating into his right groin. On physical examination there was no gross deformity or swelling present, however, there was diffuse tenderness to palpation over bilateral hips. In the right hip, range of motion was limited to 40° of flexion, 100° of internal rotation, and 25° of abduction. In the left hip, range of motion was limited to 70° of flexion, 15° of internal rotation, and 30° of abduction with pain elicited in the extremes of motion.

Infection work up was negative revealing a slightly elevated ESR of 16 mm/hr (N 0-15) but normal CRP of 0.5 mg/dl (N 0 to 0.7), hip joint aspiration revealed a cell count of 212 white blood cells (WBC) cells/cu mm and 63% polymorphonuclear cells. Radiographs of bilateral hips revealed severe osteolysis, heterotopic ossification, wear of the acetabular liner, bony impingement of the femoral

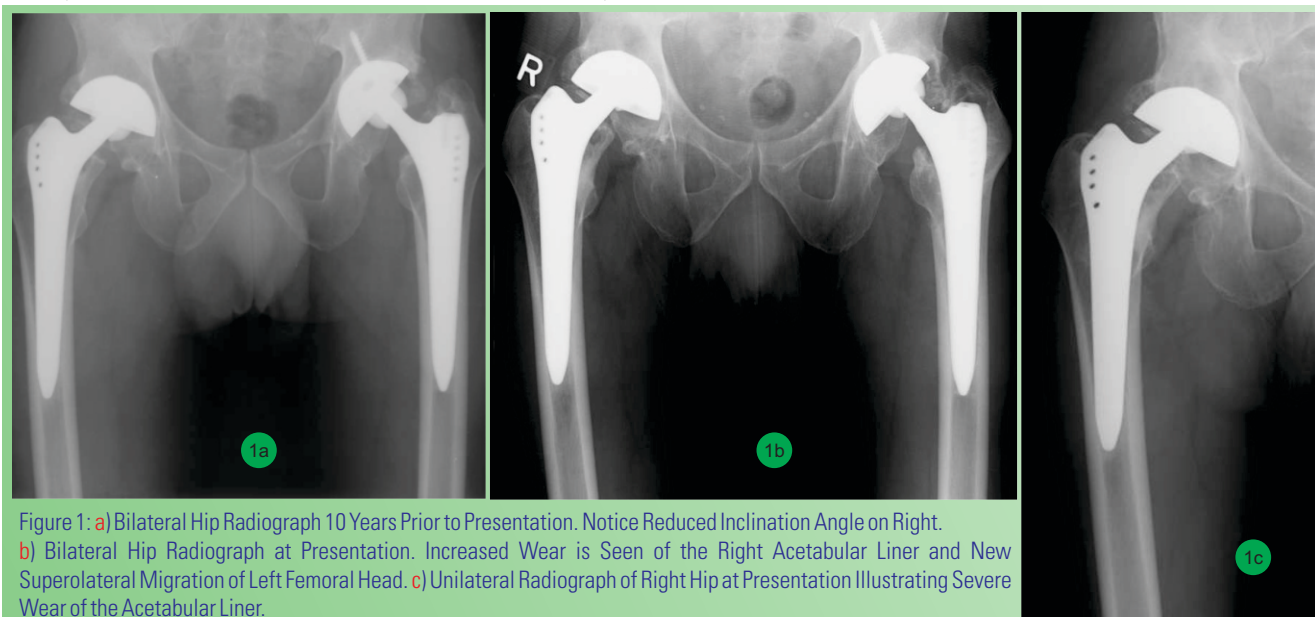


Figure 1: a) Bilateral Hip Radiograph 10 Years Prior to Presentation. Notice Reduced Inclination Angle on Right. b) Bilateral Hip Radiograph at Presentation. Increased Wear is Seen of the Right Acetabular Liner and New Superolateral Migration of Left Femoral Head. c) Unilateral Radiograph of Right Hip at Presentation Illustrating Severe Wear of the Acetabular Liner.

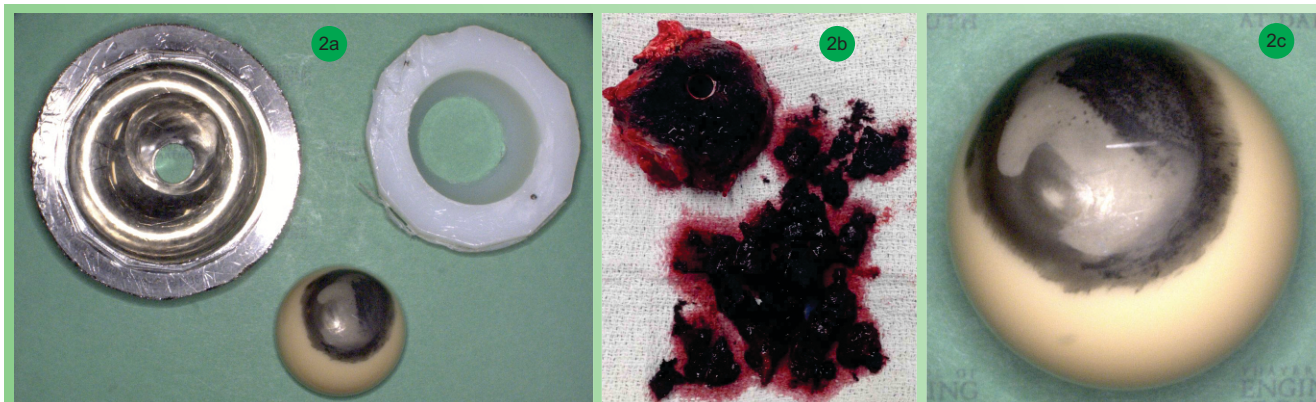


Figure 2: a) Retrieved Components from the Right Hip Illustrating Complete Wear through the Acetabular Liner and Metallosis on the Ceramic Bearing. b) Intraoperative Illustration of Severe Metallosis Periarticularly due to Long Term Wear of the Acetabular Cup by the Ceramic Bearing. c) Retrieved Ceramic Head Showing Metallosis and Loss of Surface Smoothness.

greater trochanter on the acetabular rim and superior migration of the femoral head [Fig 1]. Acetabular cup abduction angles were 21° and 50° in the right and left hip respectively. Femoral offset was 5.6cm (right) and 4.0cm (left). Due to the severe wear and pain in both hips with failure to respond to conservative non-surgical treatment, the patient was indicated for staged bilateral total hip arthroplasty revision.

On the right, intraoperative findings revealed complete wear of the ceramic femoral head through the polar aspect of the polyethylene liner into the acetabular cup [Fig 2A], causing severe metallic wear and indentation in the cup with severe metallosis and tissue destruction in the periarticular region [Fig 2B]. Extensive heterotopic ossification in the abductor muscles was also noted. Severe osteolysis and bone loss was present behind the acetabular cup, especially at the medial and superior posterior walls as well as part of the posterior column. Cancellous bone was used to repair contained areas of gross osteolysis. A new acetabular trabecular metal cup (Zimmer; Warsaw, IN) was press fit, in the position of maximum bony contact, with the support of multiple screws. A cemented highly cross-linked polyethylene liner was cemented into the acetabular cup at 45° of inclination and 20° of anteversion. The ceramic bearing was replaced with a VerSys Hip System 36mm femoral head with a 12/14 taper (Zimmer; Warsaw, IN). Revision of the left hip was performed a few months following the right hip revision, moderate proximal femur osteolysis was present with moderate polyethylene liner wear. On both the left and the right hip it was decided to retain the femoral stem after it was inspected intraoperatively and found to be stable and in proper version.

Analysis of the severely worn right hip components revealed $>50\%$ wear on the articular surface of the polyethylene insert and ceramic bearing according to the

HSS scoring system (Table 1 and 2). The articular surface of the ceramic femoral head showed an area of ceramic-on-metal contact, severe metal transfer, and a severe loss of surface smoothness [Fig 2C]. The unworn areas of the ceramic head had an average surface roughness (Ra) of 1nm to 2nm while the worn areas had Ra of 2500nm to 3500nm. With regards to the cemented titanium acetabular cup, the non-articular surface showed abundant bony ingrowth with good interdigitation, and no in vivo damage. The articular surface showed an area of central wear caused by the ceramic-on-metal contact.

Post-operative weight bearing status was foot flat weight bearing for a period of 6 weeks with weight bearing progressively increased during a period of 6 weeks to full weight bearing at 3 months. At last follow up (12 months), the patient was ambulating with no assistive devices without any complaints or pain. Postoperative radiographs showed no signs of loosening, misalignment, fracture or increased osteolysis [Fig 3]. The patient agreed to have his case used for publication.

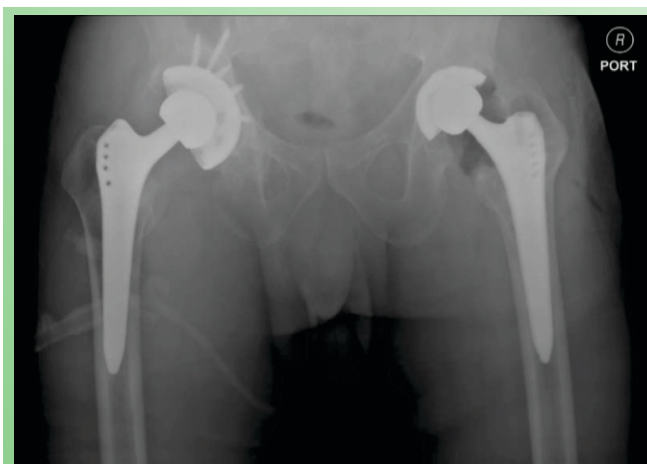

Figure 3: Post-operative Bilateral Hip Radiograph Showing Stable Components.

Discussion

Polyethylene wear debris, and the resulting inflammatory response leading to osteolysis and loosening, is the primary mode of failure limiting the longevity of total hip arthroplasty patients. In efforts to decrease polyethylene wear debris, improvements have been made to polyethylene articulating surfaces (decreasing polyethylene oxidation and increasing crosslinking) and femoral head bearing surfaces (ceramic-on-polyethylene, ceramic-on-ceramic, and metal-on-metal). Compared to CoCr, ceramic bearings are harder and more resistant to scratching, have superior surface characteristics and a more rounded surface profile with fewer sharp edges, and are chemically inert in the aqueous environment of the body. Ceramic bearings have been shown to cause less polyethylene wear, osteolysis and loosening compared to CoCr. Despite their superior resistance to wear, lab studies have shown that a single scratch with an Ra of 10-20nm on an articulating femoral head surface can significantly increase polyethylene failure through third body wear. Our patient had an Ra of 1-2nm on unworn areas, making surface roughness a less likely contributor to failure in this case.

In catastrophic polyethylene failure the femoral head completely penetrates the polyethylene liner resulting in articulation of the head with the metal acetabular cup causing metallosis, osteolysis, and tissue damage in the periarticular area. Catastrophic failure of total hip arthroplasty is a rare occurrence with reported rates of 0.29% to 10.9%. Survival of primary ceramic-on-polyethylene arthroplasty has been promising at up to 10 years with survival rates of 95% to 98.1%. However, long-term survival rates from 10 to 20 years have been more variable ranging from 70% to 89%. Reports of catastrophic failure of the ceramic-on-polyethylene arthroplasty, including our patient, fall into this latter time range with failure being attributed to patient, surgical, and implant related factors.

The use of non-crosslinked polyethylene was a major risk factor for catastrophic failure in this patient. Non-crosslinked polyethylene has been shown to have higher

wear rates than crosslinked polyethylene. Engh and colleagues performed a prospective randomized control trial comparing 10 year outcomes in non crosslinked and crosslinked polyethylene liners and reported a survivorship of 94.7% in non-crosslinked and 100% in crosslinked polyethylene over 10 years. Average, penetration rates were 0.22mm/year for non-crosslinked liners and 0.06mm/year for crosslinked liners. 91% of the non-crosslinked group had a wear rate of 0.1mm/year while 10% of the crosslinked group had a wear rate of 0.1mm/year. A polyethylene wear rate of more than 0.1mm/year has been correlated with a risk for osteolysis with a 43% risk in hips with a wear rate of 0.1mm/year to 0.2mm/year, a 80% risk in hips with a wear rate of 0.2mm/year to 0.3mm/year, and a 100% risk in hips with a wear rate >0.3mm/year. Given this, the use of a non-crosslinked polyethylene liner in our patient placed him at high risk of failure over the course of the 18-year implantation time.

Many of the reports of catastrophic polyethylene failure have also attributed the acetabular abduction angle of more than 45° to be a risk factor for polyethylene wear, which is consistent with reports of a 5% to 8% increase in the linear wear rate when the abduction angle is raised from 45° to 55°. However, our patient had an abduction angle of 21°, which would not explain the severe wear seen in this case. Other mechanisms of wear related to abduction angle have been proposed. Kligman and colleagues suggested that a difference of >18.3° of acetabular inclination between contralateral sides increased risk for polyethylene wear. This may explain one mechanism of wear in our patient, who had a 29° difference in abduction angles between contralateral sides.

The polar polyethylene wear pattern and degree of volumetric wear observed in our patient was surprising [Fig 2A]. It is plausible that the continued participation in athletic activities despite the patient's chronic hip pain contributed to a “boring” mechanism of wear, which together with a 21° abduction angle would concentrate wear towards the center of the cup. Charnley and colleagues were the first to report that prosthetic femoral heads “bored” into polyethylene liners, creating for itself a cylindrical path. Multiple wear vectors most likely added another component to the degree of

| | Wear | Burnishing | Scratching | Abrasion | Delamination | Creep | Cracking | Pitting |
|-----------------------|------|------------|------------|----------|--------------|-------|----------|---------|
| Articular Surface | 3 | 2 | 3 | 3 | 0 | 2 | 0 | 0 |
| Non-Articular Surface | 1 | 2 | 1 | 0 | 0 | 2 | 0 | 0 |

Table 1: Acetabular Wear Graded with the HSS Scoring System. Scores are Defined as follows: 0=no wear, 1=less than 10%, 2=10%-50%, 3=greater than 50%.

| | Wear | Burnishing | Scratching | Abrasion |
|-------------------|------|------------|------------|----------|
| Articular Surface | 3 | 3 | 3 | 3 |

Table 2: Ceramic Head Wear Graded with the HSS Scoring System. Scores are Defined as follows: 0=no wear, 1=less than 10%, 2=10%-50%, 3=greater than 50%.



volumetric wear in this patient. The multiple wear vectors may have been caused by minor loosening and shifting of the acetabular liner, a change in the gait cycle due to pain or muscle weakness, and progressive changes in biomechanical conditions such as contact stress, sliding distance, and friction coefficient.

While it is rare to have failure of the ceramic-on-polyethylene articulation, arthroplasty surgeons should be aware of this complication especially in highly active patients, who have had a total hip arthroplasty with non-crosslinked polyethylene. This case also stresses the importance of routine follow up, including radiological studies, in total hip arthroplasty with more vigilant observation recommended in patients with longer than 10 year implantation time and among patients complaining of chronic hip pain.

Conclusion

Ceramic-on-polyethylene prosthetic wear is a rare complication with grave consequences such as metallosis, osteolysis, and local tissue damage. The use of non-crosslinked polyethylene increases the risk of wear and should be avoided in patients undergoing total hip arthroplasty. Close follow up of total hip arthroplasty patients with non-crosslinked polyethylene should be instituted to prevent complications associated with polyethylene wear.

Clinical Message

Though rare, ceramic-on-polyethylene wear presents a major challenge for the arthroplasty surgeon. Routine follow up for total hip arthroplasty patients is a basic part of patient care. It is essential to evaluate patients complaining of hip pain for component wear and early detection may help prevent associated complications.

References

- Patil S, Bergula A, Chen PC, Colwell CW, Jr., D'Lima DD. Polyethylene wear and acetabular component orientation. *The Journal of bone and joint surgery American volume*. 2003;85-A Suppl 4:56-63.
- Urban JA, Garvin KL, Boese CK, Bryson L, Pedersen DR, Callaghan JJ, et al. Ceramic-on-polyethylene bearing surfaces in total hip arthroplasty. Seventeen to twenty-one-year results. *The Journal of bone and joint surgery American volume*. 2001 Nov;83-A(11):1688-94.
- Meftah M, Klingenstein GG, Yun RJ, Ranawat AS, Ranawat CS. Long-term performance of ceramic and metal femoral heads on conventional polyethylene in young and active patients: a matched-pair analysis. *The Journal of bone and joint surgery American volume*. 2013 Jul 3;95(13):1193-7.
- Liang B, Kawanabe K, Ise K, Iida H, Nakamura T. Polyethylene wear against alumina and zirconia heads in cemented total hip arthroplasty. *The Journal of arthroplasty*. 2007 Feb;22(2):251-7.
- Hernigou P, Bahrami T. Zirconia and alumina ceramics in comparison with stainless-steel heads. Polyethylene wear after a minimum ten-year follow-up. *The Journal of bone and joint surgery British volume*. 2003 May;85(4):504-9.
- Schuller HM, Marti RK. Ten-year socket wear in 66 hip arthroplasties. Ceramic versus metal heads. *Acta orthopaedica Scandinavica*. 1990 Jun;61(3):240-3.
- TO, SI, KK. The clinical wear rate of acetabular component accompanied with alumina ceramic head. In: HO, HA, KS, editors. *Bioceramics*. St. Louis: Ishiyaki EuroAmerica; 1989. p. 278.
- Wroblewski BM, Siney PD, Dowson D, Collins SN. Prospective clinical and joint simulator studies of a new total hip arthroplasty using alumina ceramic heads and cross-linked polyethylene cups. *The Journal of bone and joint surgery British volume*. 1996 Mar;78(2):280-5.
- Haraguchi K, Sugano N, Nishii T, Sakai T, Yoshikawa H, Ohzono K. Analysis of survivorship after total hip arthroplasty using a ceramic head. *Clinical orthopaedics and related research*. 2001 Oct(391):198-209.
- Kim SY, Kim DH, Oh CW, Kim PT, Ihn JC, Kim SY. Total hip arthroplasty with the use of nonmodular cementless acetabular component. *The Journal of arthroplasty*. 2005 Aug;20(5):632-8.
- Sochart DH. Relationship of acetabular wear to osteolysis and loosening in total hip arthroplasty. *Clinical orthopaedics and related research*. 1999 Jun(363):135-50.
- Mariconda M, Silvestro A, Mansueto G, Marino D. Complete polyethylene wear-through and secondary breakage of the expansion cup in a ceramic-polyethylene total hip. *Archives of orthopaedic and trauma surgery*. 2010 Jan;130(1):61-4.
- Needham J, Burns T, Gerlinger T. Catastrophic failure of ceramic-polyethylene bearing total hip arthroplasty. *The Journal of arthroplasty*. 2008 Jun;23(4):627-30.
- Hood RW, Wright TM, Burstein AH. Retrieval analysis of total knee prostheses: a method and its application to 48 total condylar prostheses. *Journal of biomedical materials research*. 1983 Sep;17(5):829-42.
- Fisher J, Firkins P, Reeves EA, Hailey JL, Isaac GH. The influence of scratches to metallic counterfaces on the wear of ultra-high molecular weight polyethylene. *Proceedings of the Institution of Mechanical Engineers Part H, Journal of engineering in medicine*. 1995;209(4):263-4.
- Berry DJ, Barnes CL, Scott RD, Cabanela ME, Poss R. Catastrophic failure of the polyethylene liner of uncemented acetabular components. *The Journal of bone and joint surgery British volume*. 1994 Jul;76(4):575-8.
- Min BW, Song KS, Kang CH, Won YY, Koo KH. Polyethylene liner failure in second-generation Harris-Galante acetabular components. *The Journal of arthroplasty*. 2005 Sep;20(6):717-22.

18. Heck DA, Partridge CM, Reuben JD, Lanzer WL, Lewis CG, Keating EM. Prosthetic component failures in hip arthroplasty surgery. *The Journal of arthroplasty*. 1995 Oct;10(5):575-80.
19. Topolovec M, Milosev I. A Comparative Study of Four Bearing Couples of the Same Acetabular and Femoral Component: A Mean Follow-Up of 11.5 Years. *The Journal of arthroplasty*. 2013 Apr 29.
20. Lewis PM, Al-Belooshi A, Olsen M, Schemitch EH, Waddell JP. Prospective randomized trial comparing alumina ceramic-on-ceramic with ceramic-on-conventional polyethylene bearings in total hip arthroplasty. *The Journal of arthroplasty*. 2010 Apr;25(3):392-7.
21. Park YS, Park SJ, Lim SJ. Ten-year results after cementless THA with a sandwich-type alumina ceramic bearing. *Orthopedics*. 2010 Nov;33(11):796.
22. Migaud H, Putman S, Krantz N, Vasseur L, Girard J. Cementless metal-on-metal versus ceramic-on-polyethylene hip arthroplasty in patients less than fifty years of age: a comparative study with twelve to fourteen-year follow-up. *The Journal of bone and joint surgery American volume*. 2011 May;93 Suppl 2:137-42.
23. Engh CA, Jr., Hopper RH, Jr., Huynh C, Ho H, Sritulanondha S, Engh CA, Sr. A prospective, randomized study of cross-linked and non-cross-linked polyethylene for total hip arthroplasty at 10-year follow-up. *The Journal of arthroplasty*. 2012 Sep;27(8 Suppl):2-7 e1.
24. Dowd JE, Sychterz CJ, Young AM, Engh CA. Characterization of long-term femoral-head-penetration rates. Association with and prediction of osteolysis. *The Journal of bone and joint surgery American volume*. 2000 Aug;82-A(8):1102-7.
25. T Y, H K, K P. Bilateral catastrophic acetabular component failure after ceramic-on-polyethylene total hip arthroplasty-A case report. *Hip & Pelvis*. 2012;24(2):148-52.
26. Kligman M, Michael H, Roffman M. The effect of abduction differences between cup and contralateral acetabular angle on polyethylene component wear. *Orthopedics*. 2002 Jan;25(1):65-7.
27. Charnley J, Kamangar A, Longfield MD. The optimum size of prosthetic heads in relation to the wear of plastic sockets in total replacement of the hip. *Medical & biological engineering*. 1969 Jan;7(1):31-9.
28. Yamaguchi M, Bauer TW, Hashimoto Y. Three-dimensional analysis of multiple wear vectors in retrieved acetabular cups. *The Journal of bone and joint surgery American volume*. 1997 Oct;79(10):1539-44.

Conflict of Interest: Nil
Source of Support: None

How to Cite this Article:

Manzano G, Levine Rayna AC, Mayor MB, Schwarzkopf R. Catastrophic Failure of the Acetabular Polyethylene Liner in Ceramic-on-Polyethylene Total Hip Arthroplasty. *Journal of Orthopaedic Case Reports* 2014 April-June;4(2): 51-56

visit - aaajournalonline.com