



## Case report

Cavitary lung lesion suspicious for malignancy reveals *Mycobacterium xenopi*Sumit Fogla<sup>a,\*,\*\*</sup>, Vaishali M. Pansare<sup>a</sup>, Luis G. Camero<sup>a</sup>, Uzma Syeda<sup>a</sup>, Naveen Patil<sup>b</sup>,  
Arun Chaudhury<sup>c,\*</sup><sup>a</sup> Beaumont Hospital, Grosse Pointe, MI, USA<sup>b</sup> Arkansas Department of Health, Little Rock, USA<sup>c</sup> GIM Foundation, Little Rock, AR, USA

## A B S T R A C T

We report the case of a 68-year-old gentleman who presented with musculoskeletal chest pain which appeared suddenly when he bent over with his dog. The chest pain was localized to the left lower chest and increased with movement and deep breathing. The patient did not complain weight loss, night sweat, fever or chill. He complained of mild cough, with expectoration of whitish mucus. Imaging revealed cavitary chest lesion in the right upper lobe, which was initially suspected to be lung cancer. The patient had a 50-year-old history of smoking 2 packs per day. PET CT imaging did not reveal any specific activity. Needle biopsy and bronchoalveolar lavage, however, did not reveal any malignant cells. Rather, necrotic tissues were observed. A wedge resection of the lung mass was performed. No common organisms or fungi could be grown. However, acid fast bacilli were observed in clumps. The morphology hinted towards non-tuberculous mycobacterial organism(s). Molecular studies revealed infection with *Mycobacterium xenopi*. The patient was started on an anti-tuberculous regimen of INH, rifampicin, ethambutol and PZA, with pyridoxine. The patient is a Vietnam veteran and complained of exposure to dust from a bird's nest and asbestos exposure in childhood, but no specific exposure to tuberculosis. The patient had an uneventful recovery post-surgery. He complained of some nausea after initiation of the antituberculous medications, but his pain subsided with time. The patient had diabetes, though specific reasons of compromise of immune status could not be pinpointed as causative of his nontuberculous mycobacterial lung infection.

## 1. Case report

A 68-year-old gentleman presented to the ambulatory clinic with sudden onset of pain in the left lower chest region and upper abdomen. The pain has been persisting for some time, with flare-ups while coughing or rolling over.

Significant past medical history included hypertension, diabetes mellitus, hypercholesterolemia, chronic renal insufficiency, renal stones, erectile dysfunction, diverticulosis, colon polyps, obstructive sleep apnea on continuous positive airway pressure (CPAP), peripheral arterial disease, allergic rhinitis and benign prostatic hypertrophy (BPH). Significant surgeries include those for adenoidectomy and tonsillectomy, extracapsular cataract extraction with intraocular lens implantation and lithotripsy for stones. The patient is a chronic smoker and has smoked 2 packs per day for the last 50 years. He consumes 10.5 oz. of alcohol (21 cans of beer) per week. The subject's mother suffered from type 1 diabetes mellitus and his father had undergone colectomy,

likely due to cancer. The patient's paternal uncle had cancer of larynx. Current medications included metformin, enalapril, amlodipine, simvastatin and aspirin. The patient worked in a telephone company where he "fixed things". He was exposed to asbestos in childhood. He was also exposed to "thick dust" from a large bird's nest. The patient is a Vietnam veteran.

Patient's review of systems did not reveal any fever, sweats, chills or fatigue. Review of all systems were largely within normal limits, except respiratory system elaborated below. There was no frank weight loss. Examination of all systems were normal, and no nodes or masses were palpable anywhere in the body. The lungs were clear to auscultation with normal vesicular breathing but some tenderness over the lower rib margin.

An initial electrocardiogram (EKG) performed was normal. Patient was advised for chest X ray and counseled for cessation of smoking. The chest X-ray (CXR) revealed a loculated mass in the right upper lobe (Fig. 1A). His left lower lobe was normal, where he was reporting

\* Corresponding author. GIM Foundation, PO Box 250099, Little Rock, 72225, USA.

\*\* Corresponding author. Beaumont Hospital, 468 Cadieux Road, Grosse Pointe, MI, 48230, USA.

E-mail addresses: [drsumitfogla@gmail.com](mailto:drsumitfogla@gmail.com) (S. Fogla), [arunchaudhury.boston@gmail.com](mailto:arunchaudhury.boston@gmail.com) (A. Chaudhury).

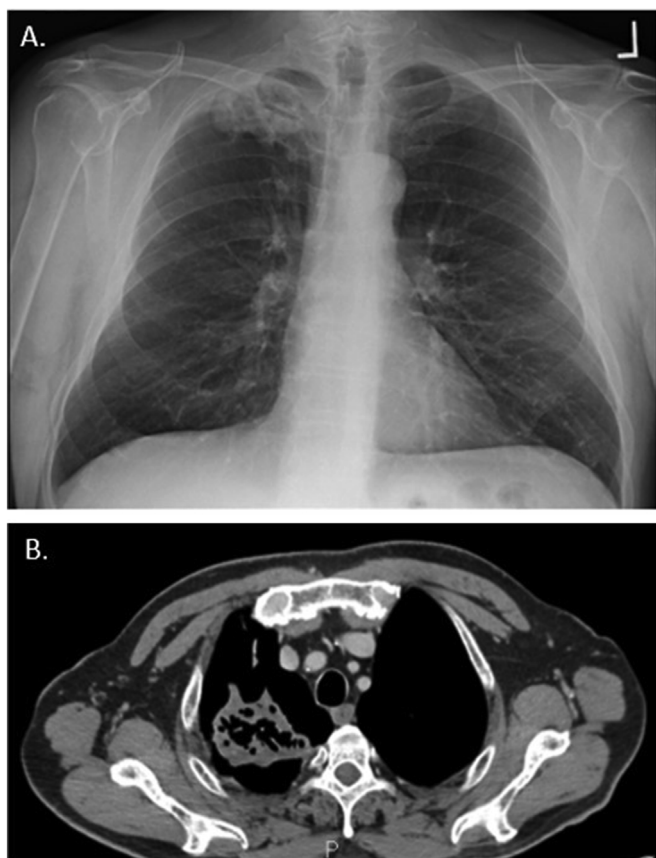


Fig. 1. A. Chest X-ray showing a rounded mass in right upper lobe B. Chest CT scan showing a loculated mass with thickened border and central cavity zones.

symptoms. Patient was advised further chest CT scan; given his long smoking history, he was advised to rule out any potential tumor. The scan revealed a 6-cm mass in the right apex with cystic areas centrally, which could represent either necrosis or air bronchogram (Fig. 1B). Patchy ground-glass opacities were seen adjacent to the mass. A 0.2 cm noncalcified nodule was seen in the right upper lobe. No mediastinal lymphadenopathy was observed. Positron emission tomography computerized tomography (PET CT) scan showed some activity, which could result from either infection or malignancy.

The chest pain was gone after a month. He though had a productive cough, expectorating whitish mucus. He had mild exertional dyspnea and could climb two flights of stairs before he became short of breath. Otherwise, his energy levels were fine. The patient did not have any unintentional weight loss, neither had any exposure to tuberculosis. Further examination during this follow-up visit revealed severely diminished breath sounds throughout. There was however no pain on inspiration and no tenderness on the chest. The tongue revealed deep brown discoloration. No clubbing, cyanosis or edema were detected in the periphery.

The patient was advised needle biopsy of the lung mass. Computerized tomography (CT) guided biopsy was used to obtain tissues from the inferior aspect of the lesion, which contained solid mass. The patient tolerated the procedure well. Pathological examination of the mass revealed necrosis, fibrosis and inflammation. The patient remained on high suspicion for lung cancer, despite the initial histopathology report.

The patient was followed up with a thoracic surgery consult after a month. The highest on the differential for the necrotic mass was fungal infection. For the first time, the possibility of tuberculosis was assumed. The possibility of lung cancer was also kept on the list. Tuberculin skin test was ordered, and a bronchoscopy was planned with tuberculosis

(TB) precautions. Bronchoscopy brushings revealed anaerobic infection with Gram negative non-Bacillus fragilis group organism. Histopathological examination revealed no malignancy, only necrotic material.

Plan for right upper lobe lobectomy was planned with the patient after the results of the lung mass cultures came back. The necrotic process could result in massive hemoptysis or purulent sepsis, thus favoring the decision for surgery.

After two weeks, the patient underwent wedge resection of the right upper lobe cavitary mass. Frozen section showed no evidence of malignancy or any specific infection; only necrotic lung tissues were observed. Intraoperatively, a lot of adhesions were observed. The tumor firmly adhered to the chest wall, so an extrapleural dissection was performed to deliver the mass ex vivo.

The histopathological examination of the surgical specimen revealed acid fast bacilli, raising strong possibilities for tuberculosis. The patient was isolated with airborne precautions, pending further identification. The patient recovered uneventfully from surgery. The patient was started on an antituberculous regimen with isoniazid (INH), rifampicin, pyrazinamide (PZA) and pyridoxine. The patient was advised for monthly liver function tests and to abstain from alcohol and quit smoking.

The histopathological examination of the lung mass revealed caseating necrosis, surrounded by few granulomas with Langhan's giant cells. Acid fast bacilli (AFB) revealed bacilli in clumps. This morphology does not favor *Mycobacterium tuberculosis*. Multiple sections were forwarded to University of Washington for molecular diagnosis. In paraffin embedded tissues, *Mycobacterium xenopi* was detected using 16s rRNA (ribosomal ribonucleic acid) gene primer set. No *Mycobacterium tuberculosis* or *Mycobacterium avium complex* was detected with hsp65 (heat shock protein 65) amplified probe.

## 2. Discussion

*Mycobacterium xenopi* was initially reported by Schwabacher in 1959 [1]. The organism was isolated from skin lesions in a *Xenopus laevis* kept in an aquarium, thus the namesake. These slow-growing mycobacteria have been recovered from heated water systems in many countries, including natural waters in Finland [2]. Currently, advanced diagnostics like INNO-LiPA MYCOBACTERIA (Innogenetics, Gent, Belgium) reverse hybridization multiple DNA probe assay are used to differentiate between the more common species of nontuberculous mycobacteria, including *M. xenopi* [3]. This has largely replaced the 16S rRNA gene sequence analysis.

Transmission to humans is likely environmental, through aerosol inhalation or ingestion; human to human transmission is not known [4]. Pulmonary disease is common, but there are reports of disseminated infections as well. Impaired immunity seems to be the driving factor for infection. These include human immunodeficiency virus infection/acquired immunodeficiency syndrome (HIV/AIDS), immunosuppressive medications, hematologic malignancy, a pre-existing lung disease and diabetes mellitus [4,5].

The British Thoracic Society (BTS) trial in 2001 recommended that treatment for pulmonary infections should consist of a 2-year course of rifampin and ethambutol [6]. The American Thoracic Society (ATS) treatment guidelines are like those by the BTS, although the ATS guidelines advocate macrolide-containing regimens [7]. Recent updates to the American Thoracic Society guidelines, however, states that it is unknown whether macrolides are effective in treatment [8].

The initial presentation of our patient revealed strong suspicion for malignancy. However, absence of malignant cells upon repeated observations of tissue materials and necrotic debris raised the possibility of tuberculosis or fungal infection. Advanced molecular diagnostics are leading us to identify different species of tuberculosis [4]. Culture-sensitivity enabled us to make specific decisions for the choice of antibiotics. It is intriguing that there are several hundred species of

tuberculosis, and an intact cell-mediated immune status protect us daily from infection, despite random exposure in our environments [9,10]. The diagnosis for atypical mycobacteria should be kept in mind presenting with cavitary lung lesions, especially in a subject with impaired immune status. Though the precise reasons for acquiring infection in our patient remained unknown, his diabetes may have contributed to immunosuppression. Largely, however, the mechanism(s) of disease susceptibility to these ubiquitously present environmental mycobacteria remains largely unknown.

### Funding

None.

### Conflict of interest

None; explicit patient consent was obtained prior to drafting the report. All authors approved the final version of the manuscript.

### References

- [1] H. Schwabacher, A strain of mycobacterium isolated from skin lesions of a cold-blooded animal, *Xenopus laevis*, and its relation to atypical acid-fast bacilli occurring in man, *J. Hyg. Lond.* 57 (1959) 57–67.
- [2] J. van Ingen, M.J. Boeree, W.C. de Lange, W. Hoefsloot, S.A. Bendien, C. Magis-Escorra, et al., *Mycobacterium xenopi* clinical relevance and determinants, *The Netherlands, Emerg. Infect. Dis.* 14 (3) (2008) 385–389.
- [3] E. Tortoli, A. Mariottini, G. Mazzeoli, Evaluation of INNO-LiPA MYCOBACTERIA v2: improved reverse hybridization multiple DNA probe assay for mycobacterial identification, *J. Clin. Microbiol.* 41 (2003) 4418–4420.
- [4] D.R. Prevots, T.K. Marras, Epidemiology of human pulmonary infection with nontuberculous mycobacteria: a review, *Clin. Chest Med.* 36 (1) (2015 Mar) 13–34.
- [5] F. Blanco-Guillot, G. Delgado-Sánchez, N. Mongua-Rodríguez, P. Cruz-Hervert, L. Ferreyra-Reyes, E. Ferreira-Guerrero, M. Yanes-Lane, R. Montero-Campos, M. Bobadilla-Del-Valle, P. Torres-González, A. Ponce-de-León, J. Sifuentes-Osornio, L. Garcia-Garcia, Molecular clustering of patients with diabetes and pulmonary tuberculosis: a systematic review and meta-analysis, *PLoS One* 12 (9) (2017 Sep 13) e0184675.
- [6] Research Committee of the British Thoracic Society, First randomised trial of treatments for pulmonary disease caused by *M. avium intracellulare*, *M. malmoense*, and *M. xenopi* in HIV negative patients: rifampicin, ethambutol and isoniazid versus rifampicin and ethambutol, *Thorax* 56 (2001) 167–172.
- [7] American Thoracic Society, Diagnosis and treatment of disease caused by nontuberculous mycobacteria, *Am. J. Respir. Crit. Care Med.* 156 (1997) S1–S25.
- [8] D.E. Griffith, T. Aksamit, B.A. Brown-Elliott, A. Catanzaro, C. Daley, F. Gordin, S.M. Holland, R. Horsburgh, G. Huit, M.F. Iademarco, M. Iseman, K. Olivier, S. Ruoss, C.F. von Reyn, R.J. Wallace Jr., K. Winthrop, ATS mycobacterial diseases subcommittee; American thoracic society; infectious disease society of America. An official ATS/IDSA statement: diagnosis, treatment, and prevention of nontuberculous mycobacterial diseases, *Am. J. Respir. Crit. Care Med.* 175 (4) (2007 Feb 15) 367–416 Review. No abstract available. Erratum in: *Am J Respir Crit Care Med.* 2007 Apr 1;175(7):744-5. Dosage error in article text.
- [9] J.O. Falkingham 3rd, Current epidemiologic trends of the nontuberculous mycobacteria (NTM), *Curr. Environ. Health Rep.* 3 (2) (2016 Jun) 161–167.
- [10] M.A. Lake, L.R. Ambrose, M.C. Lipman, D.M. Lowe, “Why me, why now?” Using clinical immunology and epidemiology to explain who gets nontuberculous mycobacterial infection, *BMC Med.* 14 (2016 Mar 23) 54.