

Received: 2020.06.18

Accepted: 2020.08.12

Available online: 2020.09.01

Published: 2020.10.21

Clinical Utility of 3-Dimensional Reconstruction Images to Predict Conservative Treatment Outcomes of Intra-Articular Distal Radius Fractures

Authors' Contribution:

Study Design A
Data Collection B
Statistical Analysis C
Data Interpretation D
Manuscript Preparation E
Literature Search F
Funds Collection G

ABCF 1 **Lingde Kong***
BCD 2 **Zuzhuo Zhang***
CDF 1 **Jian Lu**
EF 1 **Bing Zhang**
BCD 1 **Yanqing Zhou**
AEF 1 **Dehu Tian**

1 Department of Orthopedics, The Third Hospital of Hebei Medical University, Shijiazhuang, Hebei, P.R. China
2 Department of Radiology, The Third Hospital of Hebei Medical University, Shijiazhuang, Hebei, P.R. China

* Lingde Kong and Zuzhuo Zhang contributed equally to this work

Corresponding Author: Dehu Tian, e-mail: tianhdhand@qq.com

Source of support: Departmental sources

Background: Three-dimensional (3D) images can provide additional information on bone fractures, especially in patients with intra-articular distal radius fractures (DRFs). We aimed to identify possible risk factors for adverse outcomes using a 3D reconstruction technique.





Material/Methods: We retrospectively reviewed adult patients who underwent plaster immobilization with or without closed reduction for DRFs in our hospital between February 2016 and May 2019. The 3D reconstruction image of DRFs was viewed from multiple angles to determine the existence of gaps or steps. Then, a semiquantitative standard was used to assess the severity of fracture. The patients' basic data and radiographic data were collected, and multiple linear regression analyses were used to identify possible risk factors associated with adverse outcomes.

Results: A total of 89 cases were analyzed in our study. There were 28, 39, and 22 patients with level 1, 2, or 3 fractures, respectively, based on the semiquantitative standard. In a multiple linear regression, preoperative severity degree (β , 0.393; 95% confidence interval [CI], 0.260–0.526) and postoperative rehabilitation exercise (β , 0.352; 95% CI, 0.023–0.681) were associated with the Patient-Rated Wrist Evaluation during follow-up.

Conclusions: Our study presents a new method based on 3D reconstruction images to assess the severity of intra-articular DRFs. Patients who were identified as having severe fractures based on this method were found to have worse functional outcome.

MeSH Keywords: **Fractures, Closed • Imaging, Three-Dimensional • Intra-Articular Fractures • Radius Fractures**

Full-text PDF: <https://www.medscimonit.com/abstract/index/idArt/926894>

 2035  4  2  19



Background

Distal radius fractures (DRFs) are among the most common fractures presenting in the Emergency Department. They can be caused by a simple fall in elderly individuals who have weak bone or by high-energy trauma in young adults [1]. The management for DRFs is variable, and both conservative and surgical treatment methods have been used for patients [2,3]. Regardless of the method, the main goal is to restore the articular surface and the anatomical alignment of the distal radius. Among these fractures, intra-articular fractures account for nearly 25% of all DRFs [4]. According to previous studies, treating intra-articular DRFs with caution is important because step-off or gap distance can increase the risk of complications, such as tendon adhesion and arthrofibrosis [5,6]. For most patients with apparent displacement, surgical treatment is recommended to fix important articular fragments and restore the articular surfaces to achieve early rehabilitation, while closed reduction and plaster immobilization constitute the first choice of treatment for those with little dislocation [7,8].

Three-dimensional (3D) images of articular surface can be reconstructed by use of images from computed tomography (CT). In 3D reconstruction images, articular surface details such as the fossa and ankle are clearly displayed. Compared with traditional CT images, this technique could provide important information for surgeons from many angles [3]. For example, Schnetzke et al. [9] used intraoperative 3D imaging and uncovered pathological findings in 54 of 307 patients (17.6%). These details were not seen on conventional fluoroscopy, and immediate intraoperative revision was necessary.

The clinical outcomes of conservative treatment for intra-articular DRFs vary, and step-offs as well as gaps are considered to have a substantial effect on the final results. For common intra-articular DRFs, X-ray is still the most common test. X-rays are easily performed, but they can only recognize apparent intra-articular fractures and tend to miss small step-offs or gaps because only a single projection angle is possible and other bones can block a clear view. CT images can reveal small fractures, but it has limited capacity to capture a full view of the overall fracture.

We assumed that 3D images could provide additional information, especially in patients with intra-articular DRFs. However, it was unknown whether this technique could predict the outcomes of conservative treatment for intra-articular DRFs. In this study, patients with intra-articular DRFs were followed up after conservative treatment. We assessed their clinical outcomes, and with the assistance of a 3D reconstruction technique, we identified predictive factors that may be correlated with adverse outcomes.

Material and Methods

Patient population

This study retrospectively reviewed patients with DRFs who underwent plaster immobilization with or without closed reduction between February 2016 and May 2019. The inclusion criteria were patients over 18 years with stable intra-articular DRFs confirmed by CT examination. Patients with open fractures, associated carpal bone fractures, inflammatory joint disease, gout, a combined nerve compression, or history of hand or upper extremity surgery were excluded from this study. Patients with incomplete follow-up data were also excluded from this study. The Ethics Committee of the Third Hospital of Hebei Medical University approved this research and waived the need for informed consent because this study was a retrospective observational study and all data were anonymized.

Treatment

At the initial visit of each patient, both X-ray and CT examinations were performed. Plaster immobilization was used for patients with little fracture displacement or those who expressed unwillingness for other treatment. For patients with apparent fracture displacement, closed reduction was performed first, and plaster immobilization was performed if the reduction was considered to be acceptable; otherwise, surgical treatment was recommended. Acceptable alignment was defined by a radial inclination of $>15^\circ$, dorsal angulation of $<10^\circ$, or ulnar positive variance of <3 mm. Experienced surgeons performed all reduction procedures. After reduction, additional X-ray and CT examinations were performed, and the final radiological outcome was evaluated.

Patients were followed up at 1, 2, 4, and 6 weeks after immobilization. An X-ray test was performed at each routine follow-up time. When the fracture healed, the plaster was removed and range of motion exercises were started.

At the 1-year follow-up, additional clinical assessment was performed. The functional outcome was assessed using the Patient-Rated Wrist Evaluation (PRWE), which is a self-administered region-specific outcome measurement instrument developed for use in evaluating disability and pain of the wrist [10].

Data collection and parameter evaluation

The following data were collected from the patients: age, sex, side of injury, dominant hand, plaster position, presence of osteoporosis, and preoperative swelling. Preoperative swelling was assessed on the first day of hospitalization. If the wrist was swollen compared with the contralateral side but the skin texture could be recognized, the swelling was considered to be slight. If the skin texture could not be recognized or

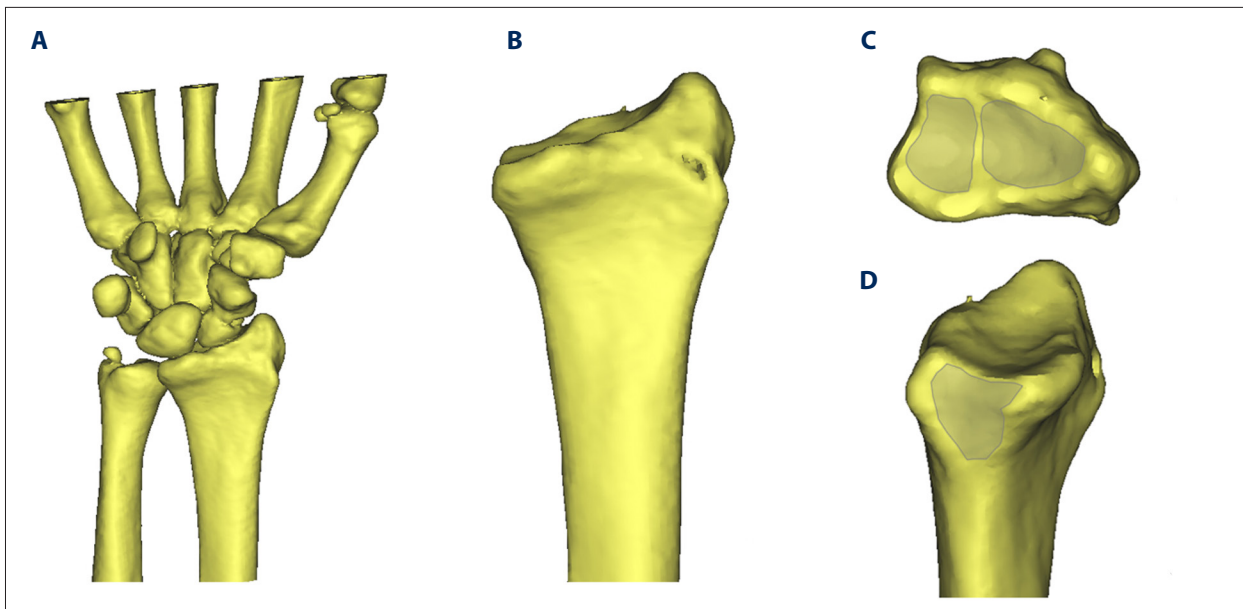


Figure 1. Three-dimensional (3D) images of articular surface were reconstructed by use of computed tomography images: (A) 3D images of wrist joint; (B) 3D images of distal radius; (C) scaphoid fossa and lunate fossa from the upper view; (D) sigmoid notch of distal radius from the ulnar view.

blisters were present, the swelling was considered to be severe. Radiographs were assessed to determine the fracture type, AO classification, and ulna status. We also performed measurements for ulnar inclination, volar angulation, and ulnar variance according to the radiographs after reduction. Wrist exercise advice was given by surgeons according to the status of fracture healing. Patients who followed the advice were considered as having performed proper wrist rehabilitation exercise.

A 1.0-mm CT scan (Aquilion 64; Toshiba, Tokyo, Japan) of the distal radius was performed for each patient after completion of plaster immobilization. The data were kept in DICOM format and were 3D reconstructed using Mimics 18.0 (Materialise, Belgium). The software's editing function was used to separate the distal radius from the carpal bone and remove the ulnar bone image. The 3D reconstruction image of the fractured distal radius was viewed from multiple angles to determine the existence of gaps or steps and the position of fracture lines. Based on the anatomical structure of the distal radius, there were 3 parts to focus on: scaphoid fossa, lunate fossa, and sigmoid notch (Figure 1). Gaps or steps were considered when the distances of fracture borders were more than 1 mm. The cutoff value was used to distinguish gaps or steps from common fracture lines. The severity degree regarding the articular surface was determined based on the criteria in Table 1.

Statistical analysis

Data analyses were performed using SPSS version 18 for Windows (SPSS, Inc., Chicago, IL, USA). Data are presented as

Table 1. Classification of intra-articular distal radius fractures according to 3-dimensional reconstruction images.

Severity degree	Characteristics of images
1	Any fracture line pass through the articular surfaces without gap or step
2	A gap or step on one articular surface
3	Gaps or steps on two or three articular surfaces

the number of subjects in each group or mean±standard deviation (SD). We used Pearson and Spearman correlation coefficients to assess correlations between the dependent variable (PRWE) and independent variables (age, sex, side of injury, dominant hand, fracture type, associated ulna fracture, AO classification, severity degree, time of reduction, radial inclination, volar tilt, ulnar variance, and rehabilitation exercise). After univariate analyses, variables found to be potentially associated with the PRWE ($P<0.10$) were included in the multiple linear regression models. Backward stepwise selection was performed with PRWE as an outcome and other factors as explanatory variables. $P<0.05$ was considered statistically significant.

Results

A total of 89 cases were analyzed in this study. The patients included 39 men and 50 women. The mean age at the time of

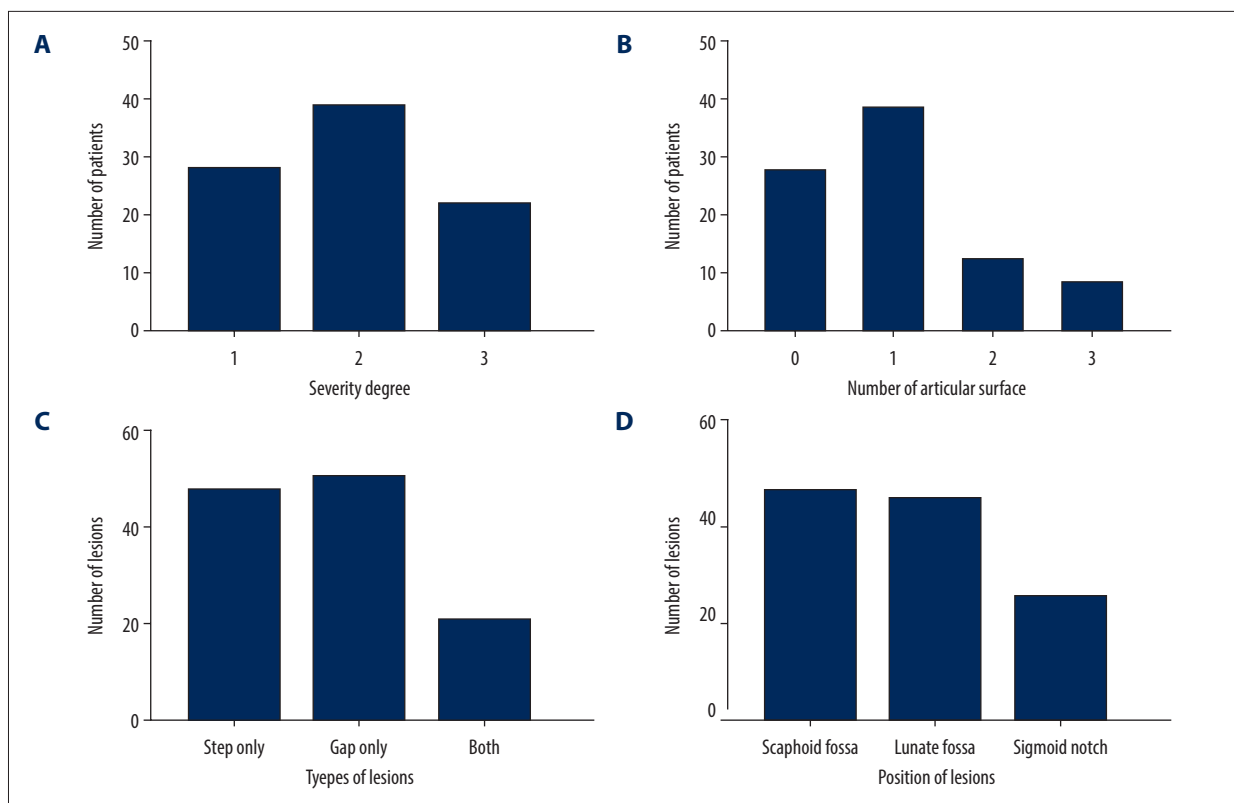


Figure 2. The details of lesions according to 3-dimensional reconstruction images: (A) the number of patients with different severity degree; (B) the number of patients with different numbers of articular surfaces involved; (C) the number of lesions with different types of lesions; (D) the number of lesions with different positions of lesions.

fracture was 56.8 ± 7.3 years. Forty-one patients injured their left wrist, and 48 patients hurt their right one. Forty wrist injuries involved the patient’s dominant hand, and 49 affected the nondominant hand. Seventy-two injuries resulted from low-energy trauma, while 17 were due to high-energy trauma. Forty patients did not undergo closed reduction, 44 patients underwent reduction once, and 5 patients underwent reduction twice or more. According to the 3D reconstruction images of DRFs, we divided patients into 3 groups according to the level of fracture. There were 28, 39, and 22 patients with level 1, 2, or 3 fracture, respectively. A total of 61 patients had steps or gaps on the articular surface. Thirty-nine patients had a step or gap on 1 articular surface, 13 patients had gaps or steps involving 2 articular surface, and 9 patients had gaps or steps involving 3 articular surfaces (Figure 2). After a more than 1 year of follow-up, the average PRWE of patients was 15.3 ± 4.7 . The data are summarized in Table 2.

Table 3 presents the results of the Pearson and Spearman correlations. Fracture type, associated ulna fracture, severity degree, and rehabilitation exercise were significantly correlated with PRWE ($P < 0.10$), while correlations were nonsignificant for age, sex, side of injury, dominant hand, plaster position, osteoporosis, preoperative swelling, AO classification, displaced

Table 2. Baseline characteristics of patients with intra-articular distal radius fractures.

Variable	Value
Number	89
Age (years), mean±SD	56.8±7.3
Gender (Male/Female)	39: 50
Sides of injury (left/right)	41: 48
Dominant hand (yes/no)	40: 49
Fracture type (simple/multiple)	22: 67
Associated ulna fracture (yes/no)	28: 61
AO classification (type B/type C)	37: 52
Severity degree (1/2/3)	28: 39: 22
Times of reduction (0/1/2~)	40: 44: 5
Ulnar inclination (°), mean±SD	19.8±6.4
Volar tilt (°), mean±SD	10.8±4.1
Ulnar variance (mm), mean±SD	1.8±0.8
Rehabilitation exercise (yes/no)	72: 17
PRWE, mean±SD	15.3±4.7

PRWE – the patient-rated wrist evaluation system.

Table 3. Correlation analysis results between patient-rated wrist evaluation and potential factors.

Variable	Correlation coefficient	P value
Age	0.556	0.122
Gender	0.238	0.942
Sides of injury	0.146	0.664
Dominant hand	0.255	0.992
Plaster position	0.462	0.877
Osteoporosis	0.312	0.589
Preoperative swelling	0.287	0.328
Fracture type	0.673	<0.001
Associated ulna fracture	0.459	0.020
AO classification	0.334	0.383
Displaced fracture	0.287	0.210
Severity degree	0.887	<0.001
Times of reduction	0.348	0.458
Ulnar inclination	-0.677	0.137
Volar tilt	-0.432	0.080
Ulnar variance	0.366	0.134
Rehabilitation exercise	0.784	<0.001

PRWE – the patient-rated wrist evaluation system.

fracture, time of reduction, ulnar inclination, volar tilt, and ulnar variance. In the further stepwise multiple linear regression for PRWE, preoperative severity degree (β , 0.393; 95% confidence interval [CI], 0.260–0.526) and postoperative rehabilitation exercise (β , 0.352; 95% CI, 0.023–0.681) were associated with the PRWE during follow-up (Table 4).

Table 4. Results of multiple regression linear analysis. ($R^2=0.68$).

Variables	β	95% CI for β	P
Fracture type	1.910	-2.042–5.862	0.287
Associated ulna fracture	0.903	0.789–1.017	0.176
Severity degree	0.393	0.260–0.526	<0.001
Rehabilitation exercise	0.352	0.023–0.681	0.034

β – partial regression coefficient; S_{β} – standard error of mean.

Discussion

Identification of the predictive factors for adverse outcomes may help surgeons to identify patients at risk for a poor prognosis and subsequently change their treatment plan and adjust follow-up decisions as needed. In our study, patients with intra-articular DRFs who underwent conservative treatment were carefully reviewed. Our investigation revealed that adverse outcomes after conservative treatment are likely to arise from multiple factors. Patients with severe fracture or improper rehabilitation exercise have a higher risk of a poor prognosis.

DRFs are considered to be one of the most common type of fractures. Although the anatomical structure of the distal radius is complex, the following 3 intra-articular areas are key regions to focus on: scaphoid fossa, lunate fossa, and sigmoid notch. These areas are in direct contact with the proximal row of carpal bones or capitulum ulnae, and thus play an important role in the process of wrist movement [11]. As the functions of the wrist joint mostly depend on the integrity and smoothness of the articular surface, a rough articular surface is the main cause for increased risk of traumatic osteoarthritis and unsatisfactory function recovery [12]. Previous studies have described arthroscopically assisted fracture reduction in the operative treatment of DRFs, and concluded that 2-dimensional fluoroscopy is prone to misinterpretation of steps or gaps [13,14]. However, these findings confirmed that joint incongruities and concavity of the joint surface cannot be clearly revealed with standard 2-dimensional fluoroscopy.

Three-dimensional printing technology is being rapidly developed in the medical field and has become accessible and feasible for use in orthopedic surgery [15]. Details of the articular surface can be reconstructed from 3D images based on data from preoperative CT examination [16]. According to previous studies, 3D printing is extremely helpful for preoperative evaluation and planning as well as for intraoperative navigation. With the use of 3D printing, a 1:1 size model of the injured elbow helped in evaluating the fracture type and fragments and improved the accuracy of reduction [3,17,18]. However, no previous studies have used this approach to predict the outcomes of conservative treatment of DRFs.

Through 3D studies of the osteoarticular surface, steps or gaps resulting from fracture lines can be investigated stereoscopically [19], which led to a new method for assessing the severity of intra-articular DRFs. By analyzing accurate morphometric information, we set a semiquantitative standard, in which the fracture severity was divided into 3 levels to assess the smoothness of the wrist joint. The current study showed that the fracture severity was associated with adverse outcomes, and this method could allow doctors to characterize a fracture more specifically and to better predict the final outcomes after conservative treatment.

Our study had several limitations. First, only patients who underwent conservative treatment were included in the study, and the findings do not permit generalization to patients receiving surgical treatment. Second, in patients with severely comminuted fractures, the current technology cannot differentiate the smallest fracture fragments. Third, only limited prognostic factors were analyzed; inclusion of other factors could

make the results more reliable. Finally, the 3D printing technology used in our study was based on CT images that did not provide information on the adjacent soft tissue. Further studies using data from MR images will be carried out in the future and will certainly provide more accurate morphometric information.

Conclusions

This study proposed a new method for assessing the severity of fractures that is based on 3D reconstruction images. Fractures identified as severe according to this method were associated with worse functional outcome. This information may help surgeons to identify patients at risk of a poor prognosis, which would enable changing the treatment plan and adjusting follow-up decisions to increase the possibility of a better prognosis.

References:

1. Levin LS, Rozell JC, Pulos N: Distal radius fractures in the elderly. *J Am Acad Orthop Surg*, 2017; 25: 179–87
2. Kong L, Kou N, Wang Y et al: The necessity of restoration of radiologic parameters by closed reduction in elderly patients with distal radius fractures. *Med Sci Monit*, 2019; 25: 6598–604
3. Kong L, Yang G, Yu J et al: Surgical treatment of intra-articular distal radius fractures with the assistance of three-dimensional printing technique. *Medicine (Baltimore)*, 2020; 99: e19259
4. Macintyre NJ, Dewan N: Epidemiology of distal radius fractures and factors predicting risk and prognosis. *J Hand Ther*, 2016; 29: 136–45
5. Abe Y, Fujii K: Arthroscopic-assisted reduction of intra-articular distal radius fracture. *Hand Clin*, 2017; 33: 659–68
6. Omokawa S, Abe Y, Imatani J et al: Treatment of intra-articular distal radius fractures. *Hand Clin*, 2017; 33: 529–43
7. Bruyere A, Vernet P, Botero SS et al: Conservative treatment of distal fractures after the age of 65: A review of literature. *Eur J Orthop Surg Traumatol*, 2018; 28: 1469–75
8. Kong L, Lu J, Zhou Y et al: Incidence and risk factors for redisplacement after closed reduction and instant rigid cast immobilization for paediatric distal radius fractures: A case control study. *J Orthop Surg Res*, 2020; 15: 140
9. Schnetzke M, Fuchs J, Vetter SY et al: Intraoperative three-dimensional imaging in the treatment of distal radius fractures. *Arch Orthop Trauma Surg*, 2018; 138: 487–93
10. MacDermid JC, Turgeon T, Richards RS et al: Patient rating of wrist pain and disability: A reliable and valid measurement tool. *J Orthop Trauma*, 1998; 12: 577–86
11. Thiar M, Ikram A, Lamberts RP: How well can step-off and gap distances be reduced when treating intra-articular distal radius fractures with fragment specific fixation when using fluoroscopy. *Orthop Traumatol Surg Res*, 2016; 102: 1001–4
12. Trumble TE, Schmitt SR, Vedder NB: Factors affecting functional outcome of displaced intra-articular distal radius fractures. *J Hand Surg Am*, 1994; 19: 325–40
13. Edwards CN, Haraszti CJ, McGillivray GR, Gutow AP: Intra-articular distal radius fractures: Arthroscopic assessment of radiographically assisted reduction. *J Hand Surg Am*, 2001; 26: 1036–41
14. Ono H, Furuta K, Fujitani R et al: Distal radius fracture arthroscopic intra-articular displacement measurement after open reduction and internal fixation from a volar approach. *J Orthop Sci*, 2010; 15: 502–8
15. Wan L, Zhang X, Zhang S et al: Clinical feasibility and application value of computer virtual reduction combined with 3D printing technique in complex acetabular fractures. *Exp Ther Med*, 2019; 17: 3630–36
16. Tanabe K, Nakajima T, Sogo E et al: Intra-articular fractures of the distal radius evaluated by computed tomography. *J Hand Surg Am*, 2011; 36: 1798–803
17. Chen C, Cai L, Zhang C et al: Treatment of die-punch fractures with 3D printing technology. *J Invest Surg*, 2018; 31: 385–92
18. Shuang F, Hu W, Shao Y et al: Treatment of intercondylar humeral fractures with 3D-printed osteosynthesis plates. *Medicine (Baltimore)*, 2016; 95: e2461
19. Zhang X, Zhang Y, Fan J et al: Analyses of fracture line distribution in intra-articular distal radius fractures. *Radiol Med*, 2019; 124: 613–19