

# Early improvement of pacing threshold following primary right coronary angioplasty



Fernando Pivatto Júnior, MD,<sup>\*</sup> Diego Chemello, MD, ScD,<sup>\*</sup> Geris Mazzutti, MD,<sup>\*</sup> Maurício Pimentel, MD, ScD,<sup>\*</sup> Paola Rabaioli, MD,<sup>\*</sup> Leandro Zimmerman, MD, ScD<sup>\*†</sup>

From the <sup>\*</sup>Hospital de Clínicas de Porto Alegre (HCPA), Porto Alegre, Brazil, and <sup>†</sup>Universidade Federal do Rio Grande do Sul (UFRGS), Porto Alegre, Brazil.

## Introduction

Permanent pacemaker failure to capture can occur owing to several causes, including battery depletion, circuit problems, lead dislodgement, metabolic abnormalities, and drugs.<sup>1</sup> Although acute coronary syndrome (ACS) can cause this phenomenon, there are few reports in the literature describing pacemaker malfunction as a consequence of ACS.<sup>1-5</sup>

The effect of temporary myocardial ischemia and reperfusion on myocardial conduction properties is well known in animal models.<sup>6,7</sup> In the literature, only 2 case reports<sup>1,5</sup> have described the recovery of stimulation thresholds after reperfusion, and, in both, this occurred after weeks. We report a unique case of pacemaker malfunction associated with acute myocardial infarction (MI) with early normalization of the pacing threshold following angioplasty of the right coronary artery (RCA).

## Case report

An 87-year-old woman was admitted to the emergency department because of syncope that occurred 1 hour earlier. She denied other complaints. Her past medical history included hypertension, diabetes, ischemic stroke with mild cognitive impairment, and complete atrioventricular (AV) block requiring implantation of a permanent single-chamber pacemaker 10 months before (Zephyr SR, St Jude Medical, St Paul, MN). The choice for a single-chamber device was owing to cost concerns and the patient's clinical status and because the AV block was intermittent at the time of implantation. A previous elective evaluation of the pacemaker revealed a stable stimulation threshold (consistently 0.75 V @ 0.5 ms) and right ventricular (RV) sensing (R wave: 9.3 mV). The pacemaker was programmed to VVI mode at 60 beats per minute, output 2.5 V @ 0.5 ms. The rate

response (VVIR mode) was not selected because the patient was physically inactive.

Physical examination at admission revealed jugular venous distention, heart rate of 42 beats per minute, and blood pressure of 90/40 mm Hg. Her presenting electrocardiogram showed pacemaker loss of capture, intermittent R-wave undersensing, AV dissociation, junctional escape rhythm, and marked ST-segment elevation in the inferior leads (II, III, and aVF), consistent with inferior MI (Figure 1A). Immediate pacemaker interrogation showed a significant increase in RV pacing thresholds (4.0 V @ 0.5 ms) with intermittent RV sensing at 2 mV. Lead impedance was within normal ranges. There were no electrolyte abnormalities or lead dislodgement. Immediate, consistent RV capture was obtained by increasing the RV stimulation output to 7.0 V @ 1.5 ms (Figure 1B), and hemodynamic stability was achieved. Urgent cardiac catheterization showed proximal thrombotic occlusion of the dominant RCA (Video 1, available online). After RCA reperfusion, several coronary branches to the right ventricle could be identified, some of them in close proximity to the pacemaker lead tip (Figure 2). A bare metal stent was successfully deployed and the patient was transferred to the Coronary Care Unit hemodynamically stable. Pacemaker interrogation 3 hours after stent placement showed improvement in RV pacing thresholds (2.0 V @ 0.5 ms).

## Discussion

The present case illustrates the unique relationship between acute myocardial injury, reperfusion, and transient pacemaker malfunction. To the best of our knowledge, to date, no case reports have demonstrated this relationship in a clinical setting. The RV infarction that occurred in the setting of an occluded RCA resulted in increased RV pacing thresholds, with temporary loss of capture and undersensing. Other potential causes of pacemaker failure (lead dislodgement, fracture or insulation break, and electrolyte disturbances) were excluded. After RCA stenting, reperfusion was observed and the RV threshold decreased almost immediately.

**KEYWORDS** Pacemaker; Increased threshold; Myocardial infarction; Myocardial ischemia; Angioplasty; Myocardial reperfusion (Heart Rhythm Case Reports 2017;3:90-92)

**Address reprints and correspondence:** Dr Fernando Pivatto Júnior, Hospital de Clínicas de Porto Alegre (HCPA), Rua Ramiro Barcelos, 2350 - 90035-903 - Porto Alegre, RS, Brazil. E-mail address: fpivatto@gmail.com.

## KEY TEACHING POINTS

- Right ventricular (RV) myocardial infarction (MI) is a potential reason for sudden increase in pacemaker stimulation thresholds and RV undersensing.
- In situations of sudden pacemaker malfunction, especially in devices with previously stable parameters, such possibility should always be considered despite the lack of typical MI symptoms.
- Routine pacemaker reprogramming in RV MI patients until coronary reperfusion is obtained is a possible practical implication, considering the potential transient threshold elevation.

Myocardial resistivity changes dramatically when local ischemia is induced over a period of 30 minutes to several hours.<sup>6</sup> Some mechanisms have been proposed to explain how ischemia affects myocardial conduction properties. Hypoxia, as a constituent of ischemia, produces electrical uncoupling of myocardial cells, leading to an increase in intracellular resistance of 50%–100% within 30 minutes.<sup>6</sup> This cell-to-cell electrical uncoupling induced by ischemia is reversible after reperfusion, as demonstrated by Cascio et al.<sup>7</sup> Coronary artery occlusion also causes an accumulation of  $K^+$  in the extracellular space, which has been associated with a number of electrophysiological changes.<sup>6</sup> Laird et al<sup>8</sup> used a swine model to characterize intracoronary pacing capture thresholds and their response to acute ischemia. Most animals showed a stabilization or reduction in threshold at 1 minute and a more varied response after 8 minutes. The baseline capture threshold was  $4.0 \pm 0.5$  mA. The mean capture threshold was  $3.3 \pm 0.3$  mA at 1 minute and  $4.5 \pm 0.9$  mA at 8 minutes of ischemia. Cui et al,<sup>9</sup> also using pigs, demonstrated that acute ischemia for more than 30 minutes could increase

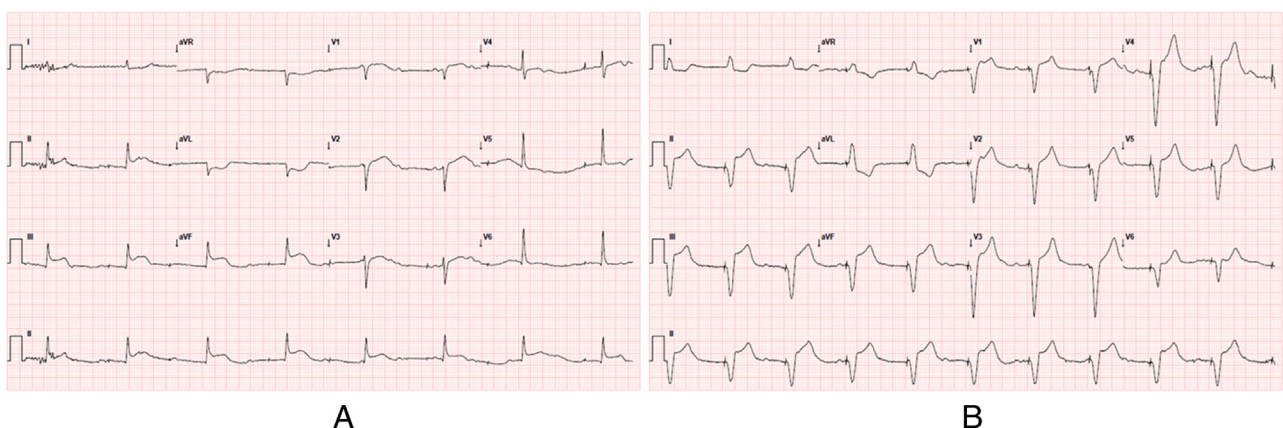
transcoronary pacing threshold almost 3-fold to the baseline level, and reperfusion could decrease it. The baseline pacing threshold ( $0.71 \pm 0.24$  V) significantly increased 30 minutes after ischemia, reached peak value at 40 minutes ( $1.99 \pm 1.36$  V), decreased significantly 5 minutes after reperfusion ( $1.06 \pm 0.46$  V), and then remained stable.

There are only 2 cases in the literature describing pacemaker malfunction secondary to MI with subsequent normalization of the parameters.<sup>1,5</sup> Chen et al<sup>1</sup> and Upadhyay et al<sup>5</sup> reported that pacemaker function returned back to normal at 40 and 45 days, respectively, after stent implantation in the proximal segment of the RCA. Unlike these 2 cases, our patient showed an almost immediate recovery of pacemaker function, probably owing to the very early revascularization.

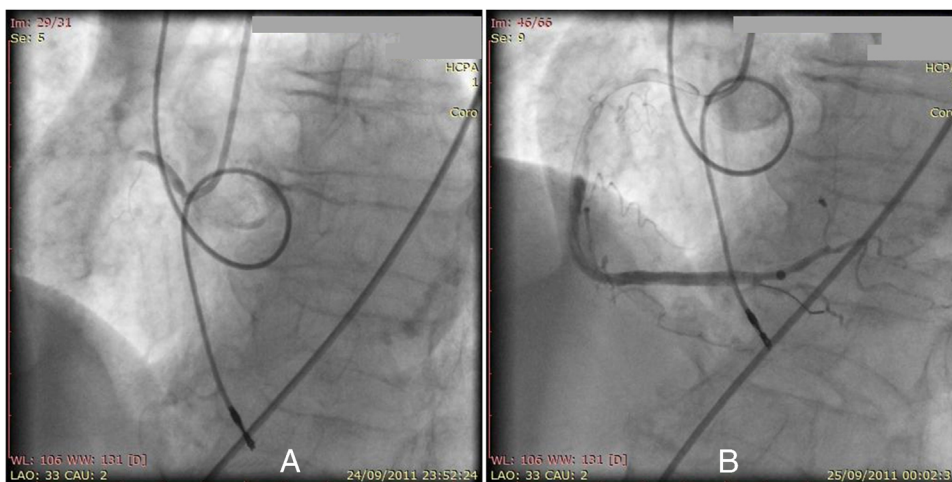
The diagnosis of acute MI in pacemaker-dependent patients may be difficult, and the absence of typical symptoms makes this diagnosis even more challenging. Acute MI with no chest discomfort occurs in up to one-third of cases. These patients are more likely to be older, diabetic, and female, as in the present case. Acute MI patients without chest pain at presentation are less likely to receive appropriate treatment (including primary angioplasty) and experience higher mortality rates.<sup>10</sup> In our case, syncope contributed to the early diagnosis of MI. Syncope as the sole symptom of pacemaker malfunction is a very uncommon presentation of acute MI. Considering that rapid reperfusion improves the prognosis of acute MI and can restore pacemaker normal function very early in the course of MI, it is fundamental to keep this unusual form of presentation in mind.

## Conclusion

RV MI may cause a sudden increase in pacemaker stimulation thresholds and RV undersensing. In situations of sudden presentation, especially in devices with previously stable parameters, such possibility should always be considered despite the lack of typical MI symptoms. This pacemaker malfunction may be transitory, and normalization can be achieved with revascularization. We presented here a



**Figure 1** Electrocardiogram (ECG) showing sinus rhythm at approximately 100 beats per minute (bpm) with complete heart block and a junctional escape rhythm of 47 bpm with intermittent ventricular undersensing and complete loss of ventricular capture. **A:** There was up to 4 mm ST-segment elevation in the inferior leads (II, III, and aVF) with minor ST elevation in the anterior leads and ST-segment depression in the lateral leads. **B:** ECG after pacemaker reprogramming (increased amplitude and pulse width) showing consistent right ventricular capture.



**Figure 2** Right coronary angiography in the left anterior oblique (LAO) position (A) and in the right anterior oblique (RAO) position (B) showing the right coronary artery and its branches in close proximity to the pacemaker lead tip.

patient in whom early revascularization was associated with early improvement of the pacing threshold. Routine pacemaker reprogramming in RV MI patients until coronary reperfusion is obtained, considering the potential transient threshold elevation, is a possible practical implication of the present case report.

## Appendix

### Supplementary data

Supplementary data are available in the online version of this article at <http://dx.doi.org/10.1016/j.hrcr.2016.09.007>.

## References

- Chen C, Fang CC, Wang SP. Reversible atrial lead dysfunction of DDD pacemaker after recent inferior myocardial infarction—a case report. *Angiology* 2004;55:451–454.
- Belhassen B, Pelleg A, Lavotzkin J, Laniado S. Conduction disturbances between a pacemaker electrode and the myocardium in right ventricular infarction. *J Electrocardiol* 1981;14:101–103.
- Little T. External cardiac pacing in right ventricular infarction. *Ann Emerg Med* 1988;17:640–642.
- Mittal SR, Mahar MS, Gokhroo RK. Transvenous pacing in the presence of acute right ventricular infarction. *Int J Cardiol* 1992;34:100–101.
- Upadhyay S, Marshalko S, McPherson C. The stunned atrial lead: transient malfunction of a permanent atrial pacer lead following acute myocardial infarction. *Int J Crit Illn Inj Sci* 2011;1:161–163.
- Steendijk P, van Dijk AD, Mur G, van der Velde ET, Baan J. Effect of coronary occlusion and reperfusion on local electrical resistivity of myocardium in dogs. *Basic Res Cardiol* 1993;88:167–178.
- Cascio WE, Yang H, Johnson TA, Muller-Borer BJ, Lemasters JJ. Electrical properties and conduction in reperfused papillary muscle. *Circ Res* 2001;89:807–814.
- Laird JR, Hull R, Stajduhar KC, Weston LT, Kufs W, Wortham DC. Transcoronary cardiac pacing during myocardial ischemia. *Cathet Cardiovasc Diagn* 1993;30:162–165.
- Cui W, Liu F, Xie R, Lu J, Li B, Wu J, Yang X, Hao Y, Du J. Abstract 3263: the effect of ischemia/reperfusion on the pacing threshold by transcatheter pacing. *Circulation* 2006;114(Suppl18):691.
- Canto JG, Shlipak MG, Rogers WJ, Malmgren JA, Frederick PD, Lambrew CT, Ornato JP, Barron HV, Kiefe CI. Prevalence, clinical characteristics, and mortality among patients with myocardial infarction presenting without chest pain. *JAMA* 2000;283:3223–3229.