

# Delayed radiofrequency ablation efficacy in slow pathway ablation: a case report

Ivan Zeljković\*, Nikola Pavlović, Vjekoslav Radeljić, and Šime Manola

Department of Cardiology, Sestre Milosrdnice University Hospital, Vinogradska cesta 29, 10 000 Zagreb, Croatia

Received 3 June 2020; first decision 15 July 2020; accepted 3 November 2020

## Background

The delayed effect of radiofrequency (RF) ablation was described in cases of accessory pathway and premature ventricular contraction ablation, as well as delayed atrioventricular (AV) block after slow pathway ablation.

## Case summary

We report a case of a female patient with AV nodal re-entry tachycardia (AVNRT), in whom the first electrophysiology study ended with acute failure of slow pathway ablation, despite using long steerable sheath, both right and left-sided ablation with >15 min of RF energy application and repeatedly achieving junctional rhythm. Six weeks afterwards, during scheduled three-dimensional electroanatomical mapping procedure, there was no proof of dual AV nodal conduction nor could the tachycardia be induced. Also, the patient did not have palpitations between the two procedures nor during the 12-month follow-up period.

## Discussion

This case illustrates that watchful waiting for delayed RF ablation efficacy in some cases of AVNRT ablation could be reasonable, in order to reduce the risk of complications associated with slow pathway ablation.

## Keywords

Delayed • Efficacy • Radiofrequency ablation • AVNRT • Slow pathway • Case report

## Learning points

- Radiofrequency (RF) ablation produces the region of acute necrosis which fits the size of the catheter tip, while the extent of tissue injury is larger within the border zone.
- Delayed efficacy of RF ablation is described in cases of accessory pathway and premature ventricular contraction ablation.
- Waiting for delayed RF ablation efficacy during slow pathway ablation could be reasonable, especially in difficult cases, in order to reduce the risk of complications associated with aggressive approach.

## Introduction

Electrophysiology study (EPS) with catheter ablation is a treatment of choice of paroxysmal supraventricular tachycardia according to current guidelines.<sup>1</sup> Slow pathway ablation using radiofrequency (RF) energy for treatment of atrioventricular (AV) nodal re-entry tachycardia (AVNRT) has a high acute and chronic success rates as well as low complication rates.<sup>1</sup> Although the possibility of a delayed RF efficacy is a well-known phenomenon, especially in ventricular arrhythmia ablation, it was not described in case of a slow pathway ablation so far.<sup>2,3</sup> We report a case of a female patient with AVNRT, in whom the 1st EPS ended with acute failure of slow pathway ablation,

\* Corresponding author. Tel: +385 1 3787 733, Email: [ivanzeljkov@gmail.com](mailto:ivanzeljkov@gmail.com)

Handling Editor: Philipp Sommer

Peer-reviewers: Konstantinos Iliodromitis and Nikos Papageorgiou

Compliance Editor: Linh Ngo

Supplementary Material Editor: Vassilios Parisis Memtsas

© The Author(s) 2021. Published by Oxford University Press on behalf of the European Society of Cardiology.

This is an Open Access article distributed under the terms of the Creative Commons Attribution Non-Commercial License (<http://creativecommons.org/licenses/by-nc/4.0/>), which permits non-commercial re-use, distribution, and reproduction in any medium, provided the original work is properly cited. For commercial re-use, please contact [journals.permissions@oup.com](mailto:journals.permissions@oup.com)

however during the 2nd procedure the delayed RF efficacy was noted resulting in no proof of dual AV nodal conduction nor the tachycardia could be induced.

## Timeline

Clinical presentation	Repeated palpitations with 'on-off' phenomenon for the last 4 years + narrow QRS tachycardia documented in the 12-lead electrocardiogram (ECG)
Index date	First procedure—conventional electrophysiology (EP) study: atrioventricular nodal re-entry tachycardia proven with acute failure of slow pathway ablation
6 weeks	Second procedure—three-dimensional mapping catheter + conventional EP study: no signs of dual AV nodal conduction + no tachycardia inducible
6 months	No palpitations
12 months	No palpitations, no tachycardia on 7-day Holter-ECG

## Case presentation

A 22-year old female Caucasian underwent an EPS due to episodes of palpitations with 12-lead electrocardiogram (ECG) documented regular, narrow QRS-complex tachycardia. Baseline ECG showed normal sinus rhythm without ventricular pre-excitation. Her medical history revealed no significant comorbidity. Physical examination on admission was without any pathology. Echocardiography done prior to the EPS showed structurally normal heart.

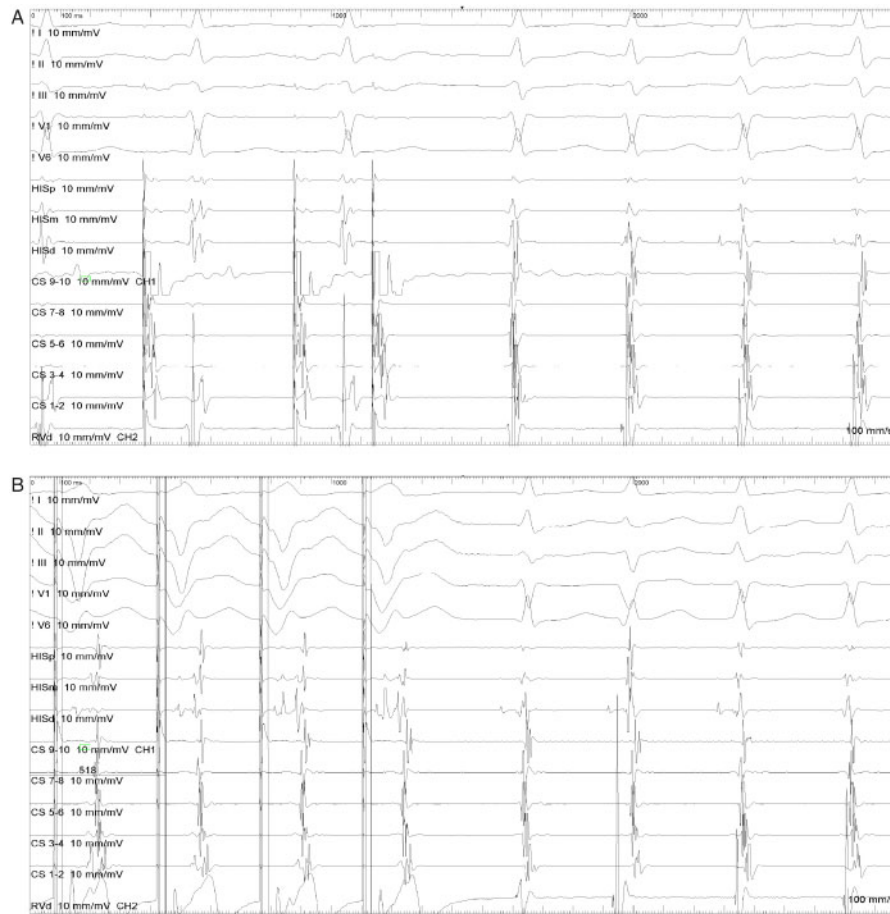
An EPS was performed with the patient in a non-sedated state. Quadripolar diagnostic catheters JSN 5F (St. Jude Medical, St. Paul, MN, USA) were positioned in right ventricular apex and His area, and steerable decapolar catheter EZ Steer (Biosense Webster, Diamond Bar, CA, USA) was positioned into coronary sinus. At baseline, sinus cycle length, AH and HV intervals were within normal range.

During the EPS, existence of dual AV nodal physiology was found (jump noted at programmed pacing interval 500/260 ms from the right atrium with the echo beat) and clinical narrow QRS tachycardia was induced during programmed stimulation of right atrium.<sup>4</sup> The diagnosis of typical (slow-fast) AVNRT was made using standard manoeuvres: overdrive stimulation from the right ventricle (VAV pattern, post-pacing interval—tachycardia cycle length > 115 ms, ventriculo-atrial interval < 30 ms) (Figure 1A and B).<sup>5,6</sup> Despite using long steerable sheath (Agilis™ NxT, Abbot) and both right and left-sided (using antegrade approach), multiple RF ablations reaching total of >15 min of RF energy application (temperature controlled mode, 50W, 60°C) in the triangle of Koch region, with 4-mm tip non irrigated catheter (Blazer II Standard Curve, Boston Scientific, USA) as well as achieving junctional rhythm repeatedly (>10 min in total) (Figure 2), AVNRT was still inducible. AV junctional tachycardia was

excluded with overdrive pacing from the right atrium (Figure 3), there was still evidence of dual AV node physiology, while diagnosis of AVNRT was repeatedly proven with right ventricular overdrive pacing.<sup>4–6</sup> Six weeks later, repeated EPS using three-dimensional electro-anatomical mapping system was scheduled due to AVNRT inducibility at the end of the 1st procedure. During the repeated procedure, there was no sign/proof of conduction through the slow pathway nor could AVNRT be induced neither in the baseline settings nor during isoproterenol infusion (up to 16 µg per minute) (Figure 4A and B). Hence, the procedure was aborted. In addition, the patient did not have any palpitations between the two EPS. Moreover, the patient, with no antiarrhythmic drug prescribed, did not have palpitations during 12-month follow-up period after the 2nd EPS or any tachycardia on 7-day Holter-ECG done 12 months after the 2nd EPS.

## Discussion

We presented a case of a patient with AVNRT with acute failure of slow pathway ablation despite aggressive approach during the 1st EPS and a delayed RF ablation efficacy noted 6 weeks later, during the 2nd procedure. To the authors' best knowledge, this is the first report of a delayed RF efficacy in a case of a slow pathway ablation. On the other hand, the delayed RF ablation efficacy was described in cases of fast-pathway, accessory pathway and premature ventricular contractions (PVC) ablation, including ones with para-His origin.<sup>2,3,7–10</sup> This could be explained by the fact that RF energy causes resistive heating of tissue consequently producing the region of acute coagulation necrosis which corresponds to the size of the catheter tip, while the extent of tissue injury is larger within the border zone of viable myocardium.<sup>10,11</sup> Secondary inflammatory response with ischaemia consequent to microvascular damage causes progression of tissue injury within the border zone.<sup>11</sup> In addition to modalities used during the 1st procedure, we could have used irrigated RF catheter or bipolar ablation which causes deeper lesions, however with higher risk of AV node and/or His-bundle damage. We surmise that delayed extension of the RF lesion damages the pathway conduction and/or PVC focus.<sup>7–11</sup> Moreover, there are several studies indicating that RF ablation can have delayed proarrhythmic potential.<sup>7,8</sup> However, RF ablation of slow pathway in patients with prolonged PR interval was reported to be safe and feasible during short and mid-term follow-up, with a significant improvement in antegrade fast pathway conduction properties in some cases.<sup>12,13</sup> In addition, there is data on delayed occurrence of high-degree AV block after RF ablation of slow-pathway with incidence of approximately 1.5% which is 3-time higher than that in the general population in very long-term follow-up (>10 years).<sup>14</sup> If this is a consequence of delayed RF efficacy or it has other pathophysiological explanation, remains unknown. Nonetheless, this could mean that watchful waiting for delayed RF ablation efficacy could be reasonable in some cases, in order to avoid excessive ablation in Koch's triangle and reduce the risk of complications during slow pathway ablation. Also, stepwise approach is advisable: standard setup with focal RF ablation, followed by long deflectable sheath usage and left-sided ablation with transseptal/antegrade approach, and three-dimensional mapping system in the end or during 2nd procedure, especially if the 1st procedure is long-lasting,




**Figure 1** (A) Narrow complex QRS tachycardia induction with programmed right atrial stimulation (from CS/corony sinus/9-10 channel) with S1-S2 500/280 ms. Note short ventriculo-atrial interval. (B) Overdrive pacing from right ventricular apex proving atrioventricular nodal re-entry tachycardia diagnosis with VAV postpacing pattern, postpacing interval—tachycardia cycle length of 210 ms (514–304 ms).

while we discourage the use of irrigated RF catheter and/or bipolar ablation in the Koch's triangle due to AV node and His-bundle vicinity and consequently high complication risk.

Moreover, this could also require the need for AV node conduction monitoring in long-term follow-up due to possibility of high-degree AV block, despite not having any AV node conduction disturbances during EPS.<sup>1,14</sup>

## Lead author biography



Ivan Zeljkovic is a cardiology consultant, specialized in arrhythmology, at the Department of Cardiology, Sestre milosrdnice University Hospital, Zagreb, Croatia. His field of interest includes typical supraventricular tachycardia, atrial fibrillation and ventricular arrhythmia ablation as well as cardiac device implantation and sudden cardiac death prevention.

## Supplementary material

Supplementary material is available at *European Heart Journal - Case Reports* online.

## Acknowledgements

The authors are grateful to Ivica Benko, RN, MSN, for his valuable expert assistance with the data extraction and figure presentation.

**Funding:** None declared.

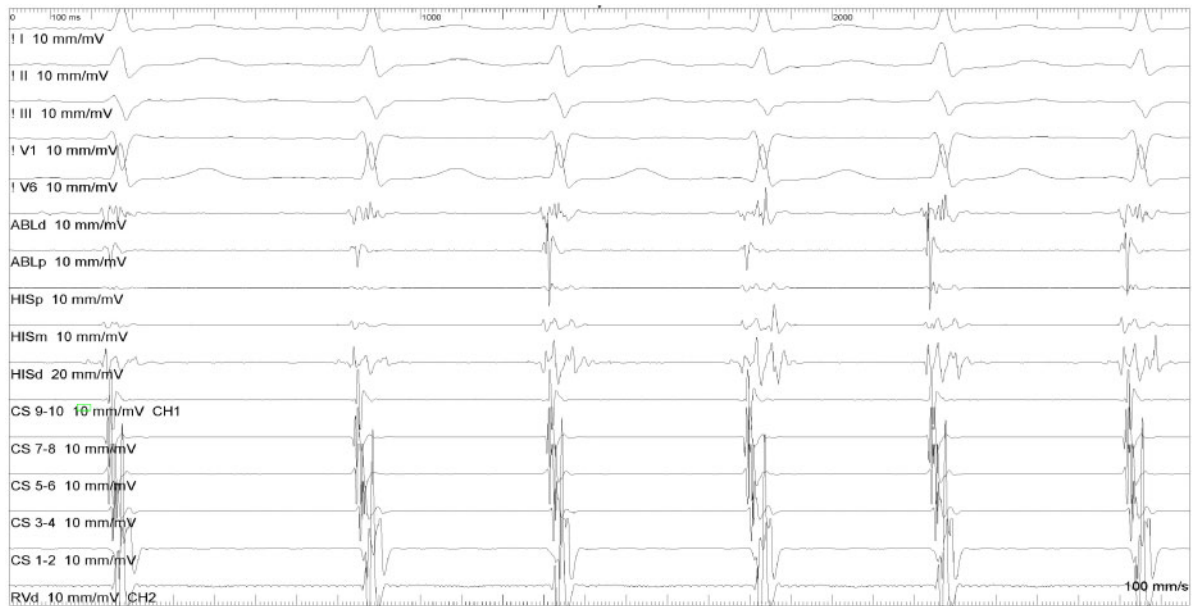
**Slide sets:** A fully edited slide set detailing this case and suitable for local presentation is available online as [Supplementary data](#).

**Consent:** The author/s confirm that written consent for submission and publication of this case report including image(s) and associated text has been obtained from the patient in line with COPE guidance.

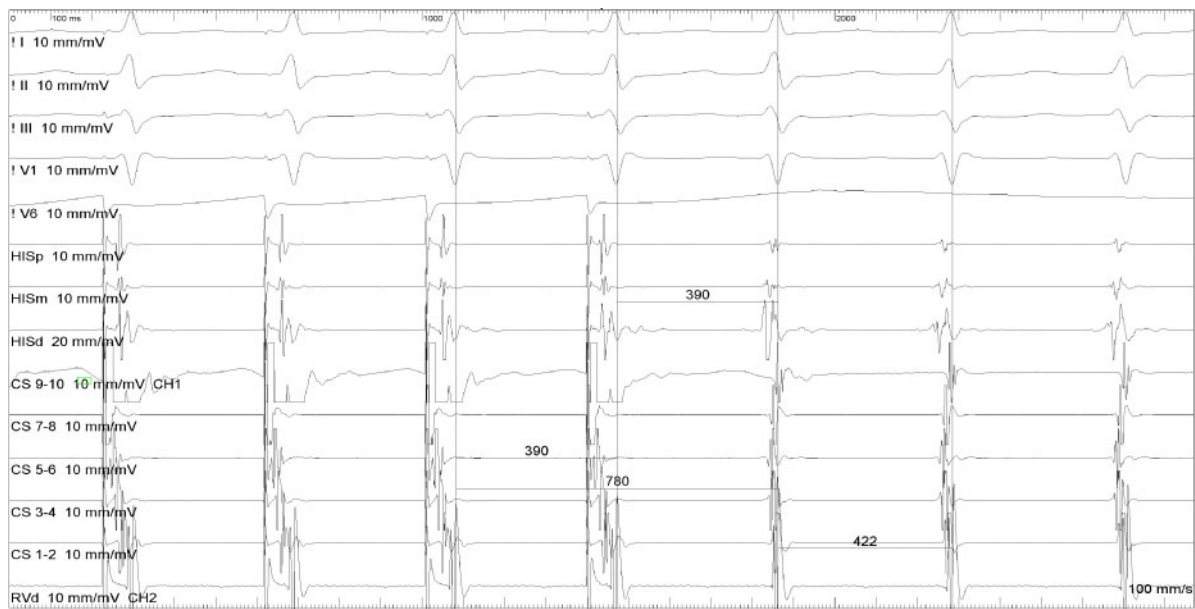
**Conflict of interest:** None declared.

## References

1. Brugada J, Katritsis DG, Arbelo E, Arribas F, Bax JJ, Blomström-Lundqvist C et al.; ESC Scientific Document Group. 2019 ESC Guidelines for the management of



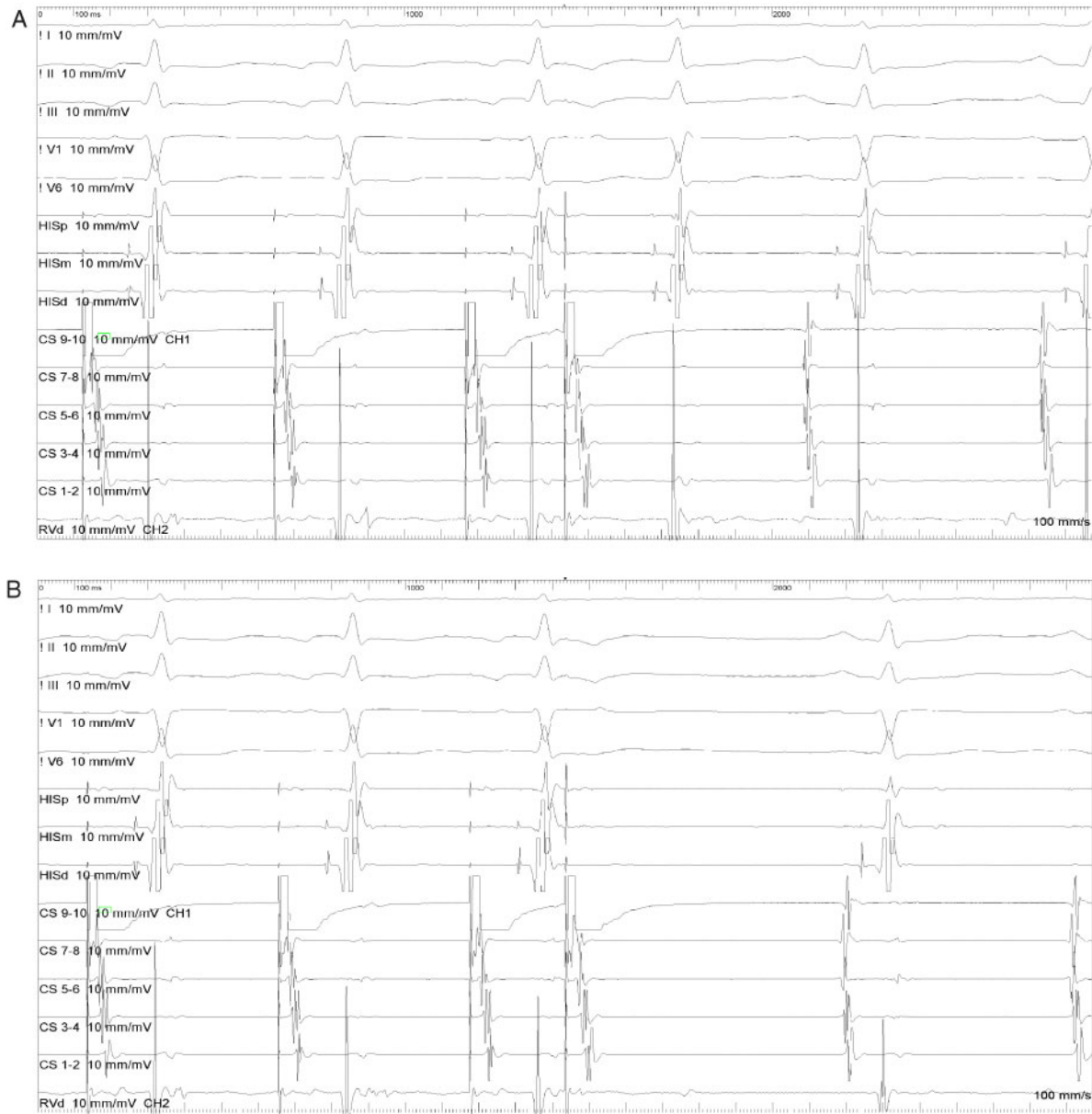
**Figure 2** Junctional rhythm as a result of radiofrequency energy application at the anatomy area of Koch's triangle.



**Figure 3** Overdrive pacing from the right atrium which excludes the possibility of junctional tachycardias.

- patients with supraventricular tachycardia. The Task Force for the management of patients with supraventricular tachycardia of the European Society of Cardiology (ESC). *Eur Heart J* 2020;**41**:655–720.
- Langberg JJ, Borganelli SM, Kalbfleisch SJ, Strickberger SA, Calkins H, Morady F. Delayed effects of radiofrequency energy on accessory atrioventricular connections. *Pacing Clin Electrophysiol* 1993;**16**:1001–1005.
  - Ju W, Gu K, Yang B, Zhang F, Chen H, Yang G et al. Late cure of focal ventricular arrhythmias post-catheter ablation: electrophysiological characteristics and long-term outcome. *J Interv Card Electrophysiol* 2018;**52**:31–37.

- Srivathsan K, Gami AS, Barrett R, Monahan K, Packer DL, Asirvatham SJ. Differentiating atrioventricular nodal reentrant tachycardia from junctional tachycardia: novel application of the delta H-A interval. *J Cardiovasc Electrophysiol* 2008;**19**:1–6.
- Katrtsis DG, Josephson ME. Classification, electrophysiological features and therapy of atrioventricular nodal reentrant tachycardia. *Arrhythm Electrophysiol Rev* 2016;**5**:130–135.
- Knight BP, Ebinger M, Oral H, Kim MH, Sticherling C, Pelosi F et al. Diagnostic value of tachycardia features and pacing maneuvers during paroxysmal supraventricular tachycardia. *J Am Coll Cardiol* 2000;**36**:574–582.



**Figure 4** No sign of dual atrioventricular node conduction properties during programmed atrial pacing: (A) at programmed right atrial stimulation 500/280 ms no sign of sudden atrioventricular conduction delay/slow pathway conduction. (B) Atrioventricular block at programmed right atrial stimulation 500/270 ms without previous sudden atrioventricular conduction delay.

7. Mujović N, Grujić M, Mrdja S, Kocijancić A, Mujović N. The occurrence of new arrhythmias after catheter-ablation of accessory pathway: delayed arrhythmic side-effect of curative radiofrequency lesion? *Srp Arh Celok Lek* 2011;**139**: 458–464.
8. Kimman GP, Bogaard MD, van Hemel NM, van Dessel PF, Jessurun ER, Boersma LV et al. Ten year follow-up after radiofrequency catheter ablation for atrioventricular nodal reentrant tachycardia in the early days forever cured, or a source for new arrhythmias? *Pacing Clin Electrophysiol* 2005;**28**:1302–1309.
9. Ding L, Hou B, Wu L, Qiao Y, Sun W, Guo J et al. Delayed efficacy of radiofrequency catheter ablation on ventricular arrhythmias originating from the left ventricular anterobasal wall. *Heart Rhythm* 2017;**14**:341–349.
10. Stein KM, Lerman BB. Delayed success following radiofrequency catheter ablation. *Pacing Clin Electrophysiol* 1993;**16**:698–701.
11. Fenelon G, Brugada P. Delayed effects of radiofrequency energy: mechanisms and clinical implications. *Pacing Clin Electrophysiol* 1996;**19**:484–489.
12. Pasquié JL, Scalzi J, Macia JC, Leclercq F, Grolleau-Raoux R. Long-term safety and efficacy of slow pathway ablation in patients with atrioventricular nodal reentrant tachycardia and pre-existing prolonged PR interval. *Europace* 2006;**8**: 129–133.
13. Cheniti G, Glover BM, Frontera A, Denis A, Haissaguerre M, Derval N. Impairment of the antegrade fast pathway in patients with atrioventricular nodal reentrant tachycardia can be functional and treated by slow pathway ablation: a case report study. *Eur Heart J Case Rep* 2018;**2**:ty078.
14. Kesek M, Lindmark D, Rashid A, Jensen SM. Increased risk of late pacemaker implantation after ablation for atrioventricular nodal reentry tachycardia: a 10-year follow-up of a nationwide cohort. *Heart Rhythm* 2019;**16**:1182–1188.