

Contents lists available at [ScienceDirect](https://www.sciencedirect.com)

International Journal of Surgery Case Reports

journal homepage: www.casereports.com

Rerouting of the pectoralis major muscle for breast animation deformity in sub-pectoral autologous breast reconstruction: A case report and review of the literature

Ennie Bijkerk^{a,b}, Tiara R. Lopez Penha^a, René R.W.J. van der Hulst^{a,b}, Stefania M.H. Tuinder^{a,b,*}

^a Department of Plastic and Reconstructive Surgery, Maastricht University Medical Center, Maastricht, the Netherlands

^b GROW – School for Oncology and Developmental Biology, Maastricht University, Maastricht, the Netherlands

ARTICLE INFO

Article history:

Received 3 July 2020

Accepted 9 October 2020

Available online 22 October 2020

Keywords:

Breast animation deformity

Breast reconstruction

DIEP flap

Pectoralis major muscle

Reinsertion

ABSTRACT

INTRODUCTION: Breast animation deformity (BAD) is a known complication of sub-pectoral implant placement that is usually corrected by simply repositioning the implant to a pre-pectoral position. However, when this complication occurs in the case of a sub-pectorally placed free-flap, the solution becomes a lot less straightforward: repositioning of the flap carries the risk of possible damage to the pedicle. In order to avoid having to re-do the anastomoses we opted for a rerouting of the pectoralis major muscle around the vascular anastomoses.

PRESENTATION OF CASE: We present a 26-year old patient with unsatisfactory aesthetic outcomes of her bilateral deep inferior epigastric perforator (DIEP) flap breast reconstruction. The flaps were placed sub-pectorally, in the already existing pocket that was created during her first breast reconstruction with silicone implants, resulting in severe BAD. Repositioning the free flap from the sub-pectoral to the pre-pectoral plane allowed for reinsertion of the pectoralis major muscle to its anatomical position without jeopardizing the vascular anastomoses. The patient was satisfied with the increased projection of the breasts.

DISCUSSION: Changing the plane from sub-pectoral to pre-pectoral remains the best treatment option for patients experiencing BAD. In combination with an acellular dermal matrix, this would have been a good option for our patient. However, when choosing to perform autologous breast reconstruction instead, our recommendation would be to always place the flap in the pre-pectoral plane to avoid BAD.

CONCLUSION: The report shows that the plane of a flap can be successfully changed without jeopardizing the pedicle of the flap.

© 2020 Published by Elsevier Ltd on behalf of IJS Publishing Group Ltd. This is an open access article under the CC BY-NC-ND license (<http://creativecommons.org/licenses/by-nc-nd/4.0/>).

1. Introduction

Implant-based breast reconstruction (IBBR) counts for the majority of breast reconstructions worldwide. The implant is either placed pre-pectoral or partially sub-pectoral (dual-plane) [1]. The dual-plane technique combines the advantages of both pockets. However, with movement of the pectoralis major muscle (PM), the (partially) sub-pectoral implant can cause breast animation deformity (BAD). Patients experiencing BAD often choose to reposition the implants to a pre-pectoral pocket [2–4], or replace the implants with free tissue [5–9]. Contradictory statements have been made

about using the already existing sub-pectoral pocket of the implant [6] or changing the pocket to pre-pectoral for free tissue inset [5,7]. Sub-pectoral placement of a flap might lead to BAD as well, with aesthetically displeasing results. We present a case report of a patient experiencing BAD after a sub-pectorally placed deep inferior epigastric perforator (DIEP) flap breast reconstruction. In order to avoid having to re-do the anastomoses we opted for rerouting the PM around the vascular anastomoses. Surgical details and our personal experience regarding the repositioning of a free flap from sub-pectoral to pre-pectoral for BAD are discussed. Related literature regarding the pocket placement of a free flap after IBBR is reviewed.

2. Case description

A 26-year old woman was referred to our institution for a second opinion regarding unsatisfactory aesthetic results after multiple reconstructive breast procedures. The patient was known with Von Willebrand disease (VWD) and had a history of BRCA gene

Abbreviations: ADM, acellular dermal matrix; BAD, breast animation deformity; DIEP, deep inferior epigastric perforator; IBBR, implant-based breast reconstruction; PM, pectoralis major muscle; VWD, Von Willebrand disease.

* Corresponding author at: Maastricht University Medical Center, P. Debyeelaan 25, 6229 HX, Maastricht, the Netherlands.

E-mail address: s.tuinder@mumc.nl (S.M.H. Tuinder).

<https://doi.org/10.1016/j.ijscr.2020.10.044>

2210-2612/© 2020 Published by Elsevier Ltd on behalf of IJS Publishing Group Ltd. This is an open access article under the CC BY-NC-ND license (<http://creativecommons.org/licenses/by-nc-nd/4.0/>).

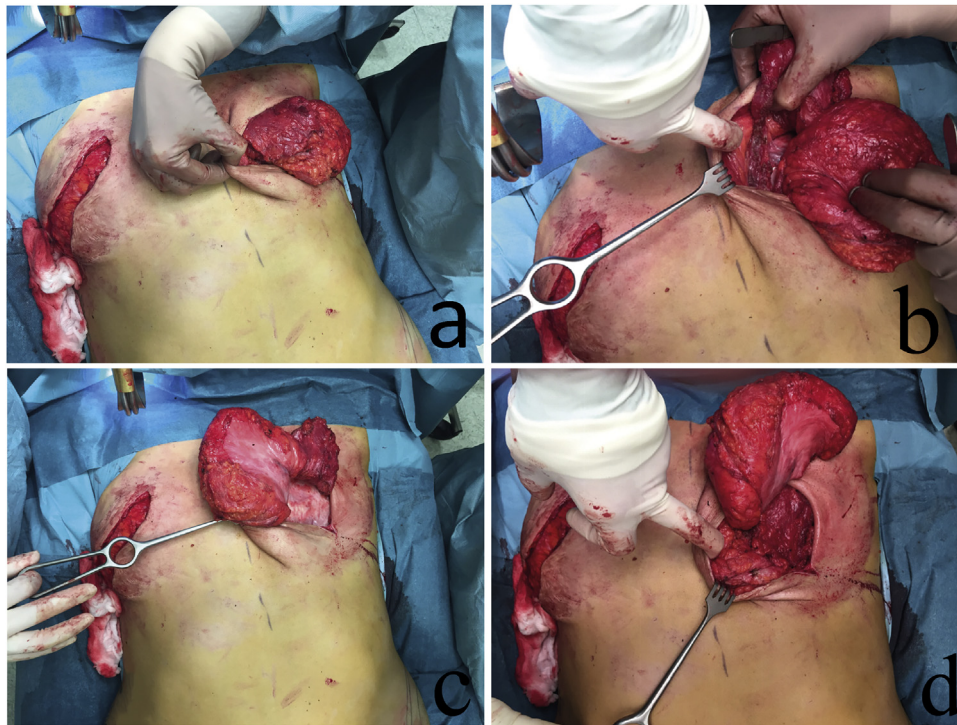

Fig. 1. The surgical technique step-by-step, including dividing the skin from the pectoralis major muscle (1a), dividing the insertion of the pectoralis major muscle from the sternum (1b), repositioning the pectoralis major muscle under the DIEP flap (1c), and reattaching the pectoralis major muscle to the sternum (1d).

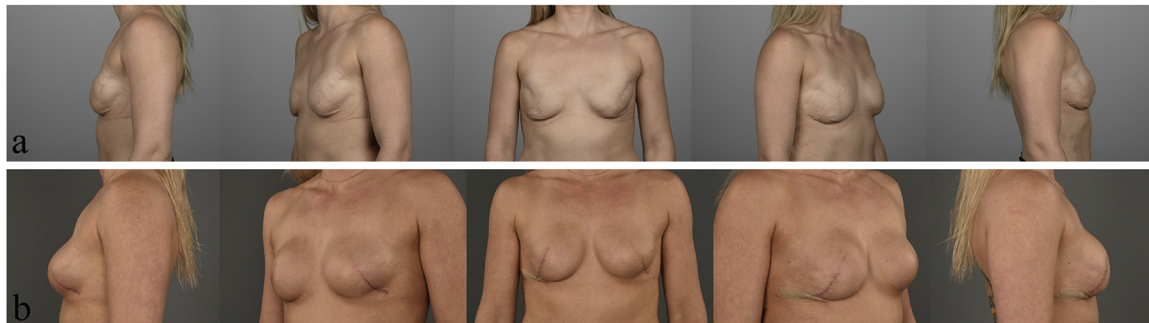


Fig. 2. (2a) Preoperative photos after bilateral tertiary breast reconstruction using DIEP flaps; (2b) Postoperative photo's showing rerouting of the pectoralis major muscle resulted in better projection of the breasts, without secondary touch-up surgeries (5 months postoperative).

mutation and underwent bilateral prophylactic mastectomy and two-stage IBBR with 475 cc silicone breast implants in 2011. Due to an aesthetically unfavorable result, the patient underwent a tertiary autologous breast reconstruction in 2013 using the DIEP flap. The flaps were placed in the original sub-pectoral pockets of the silicone implants. This resulted in two problems: bilateral BAD and dissatisfaction with the shape and volume of the breast mounds. Her bra-size changed from a full D-cup before mastectomy to a flat B-cup (European size). The lean physique of the patient (BMI = 23,31 kg/m²) and minimal breast pinch covering the flap amplified the BAD. Repositioning of the flaps carried the risks of jeopardizing the vascular pedicle. We offered to bilaterally re-route the PM around the vascular pedicle and add lipofilling to further increase volume.

3. Surgical technique and outcome

The surgical procedure was performed by an experienced microsurgeon (ST). The patient was given desmopressin nasal spray preoperatively and tranexamic acid postoperative for her VWD.

Surgical access was through the old scar and the skin was divided from the PM in a mastectomy like fashion (Fig. 1a). Secondly, the PM was separated from the flap, taking care not to damage the pedicle. The insertion of the PM to the sternum was divided all the way up to the level of the second intercostal space (Fig. 1b). The PM was then free to be repositioned underneath the flap (Fig. 1c). The PM was reattached to its insertion on the sternum (Fig. 1d). The new position of the flap allowed us to mould the breasts in a more aesthetically pleasing shape (Fig. 2). Additional lipofilling was limited to 40cc in the right breast and 20cc in the left breast. Operative time was 128 min and blood loss was minimal. On postoperative day 2 she was discharged from the hospital with standard instructions after breast surgery and prophylactic antibiotics for 5 days in total. No postoperative complications occurred and the patient was satisfied with the results.

4. Discussion

Body habitus is a leading factor in assessing the appropriate reconstructive procedure. For slim patients, autologous reconstructive

tive options are limited. Implants are often a good option in these patients, because they usually have rather small and non-ptotic breasts. This was also the case in the discussed patient. The initial choice for bilateral IBBR after prophylactic mastectomy appears appropriate. Due to the very thin mastectomy skin envelopes, the implants were placed under the PMs, to ensure adequate soft-tissue coverage [10]. The sub-muscular placement, however, lead to bilateral BAD. Different treatment options have been described in the literature to reduce BAD. Botulinum toxin A injections may provide temporary relief [11,12] and numerous surgical interventions have shown to be highly successful, but pre-pectoral pocket change is most often preferred [2,4,13,14]. This technique could have been an option in this patient, preferably with additional fat grafting and/or the use of acellular dermal matrix (ADM) to limit implant visibility [2,4,15,16]. Perhaps this option was discussed with the patient in the past, but the choice for autologous reconstruction was made instead elsewhere. Flaps are generally placed pre-pectorally and in tertiary reconstructions the question arises on what the best location for the flap is. To the best of our knowledge, guidelines regarding this topic do not yet exist. The available literature on autologous breast reconstruction after IBBR is limited and the majority of the studies do not mention surgical details about the location of the flap [8,17–23]. One study explicitly mentioned to have only performed capsulotomy instead of capsulectomy, which lead us to the assumption that the sub-pectoral pocket was used [23]. The statements by the authors that addressed the location of the flap were contradictory. Some authors stated that they repositioned the PM and changed the pocket from sub-pectoral to pre-pectoral [5,7,24], while others used the existing sub-pectoral pocket [6,25]. Rabey et al. pleads for the conversion from a sub-pectoral to pre-pectoral plane, as the original pocket tends to develop excessive scar-tissue [7]. Marquez et al. stated that changing the pocket would lead to increased bleeding and time in the operating room. They achieved aesthetically pleasing results using the sub-pectoral pocket. However, they did not mention the BMI of their patients. Reasoning from the patients' photos, we assumed that these women would have had a higher BMI than our patient [6]. A thicker mastectomy skin envelope possibly benefits the aesthetic outcome and breast projection. Literature comparing pocket use for placement of the flaps is rare. Gravvanis et al. evaluated the breast shape in patients undergoing a single-plane (pre-pectoral) compared to patients undergoing a dual-plane DIEP flap reconstruction. They found that the fullness in the upper pole of the breast was significantly better retained over time after dual-plane placement [26,27]. Volume-loss in the upper pole is seen in Fig. 2 as well, but also clearly shows good projection and conus, even without secondary touch-up surgeries. Another argument for repositioning the PM is that in delayed-immediate autologous breast reconstruction, the tissue-expanders are first placed sub-pectorally for adequate coverage during pre-expansion, but the PM is replaced to its anatomic position and the free flap is placed pre-pectoral instead of dual-plane [28].

5. Conclusion

According to our experience, we recommend changing the plane from sub-pectoral to pre-pectoral in autologous salvage breast reconstruction after IBBR to avoid BAD. The current case demonstrates the possibility to reposition the PM to its original position without having to re-do the vascular anastomosis or jeopardizing the pedicle, even after sub-pectoral free flap breast reconstruction.

Declaration of Competing Interest

The authors report no declarations of interest.

Funding

None.

Ethical approval

The analysis of one case report is intended to develop information to be shared for medical or educational purposes. Therefore, in consultation with the local ethical committee, it does not meet the criteria of research and it does not require any kind of ethical review.

Consent

The authors confirm the patient has given written informed consent for publication of this case report and accompanying images. Moreover, the images have been altered, so distinguish and identifying characteristics, i.e. tattoo's, were removed. These alterations did not distort the scientific meaning of the case report.

Author contribution

Ennie Bijkerk: Conceptualization, data extraction, interpretation of data, drafting and revising the manuscript, approval of the final manuscript.

Tiara Lopez Penha: Plastic surgeon, conceptualization, interpretation of data, drafting and revising the manuscript, approval of the final manuscript.

René van der Hulst: Head of department, supervision, revising and editing the manuscript, approval of the final manuscript.

Stefania Tuinder: Plastic surgeon, conceptualization, supervision, revising and editing the manuscript, approval of the final manuscript.

Registration of research studies

1. Name of the registry: N.A. The analysis or description of one case report is intended to develop information to be shared for medical or educational purposes. In consultation with the local medical ethical committee (METC azM/UM, Maastricht), it does not meet the criteria of research/clinical trials/human studies and, therefore, does not require registration. Moreover, repositioning the pectoralis major muscle to its anatomical position after implant-based breast reconstruction has been performed and reported in the literature before. Therefore, the surgical technique is not experimental, but has been applied in a different setting (after autologous breast reconstruction).
2. Unique identifying number or registration ID: N.A.
3. Hyperlink to your specific registration (must be publicly accessible and will be checked): N.A.

Guarantor

Dr. Stefania M.H. Tuinder.

Provenance and peer review

Not commissioned, externally peer-reviewed.

References

- [1] J.B. Tebbetts, Dual plane breast augmentation: optimizing implant-soft-tissue relationships in a wide range of breast types, *Plast. Reconstr. Surg.* 107 (5) (2001) 1255–1272.
- [2] D.C. Hammond, W.P. Schmitt, E.A. O'Connor, Treatment of breast animation deformity in implant-based reconstruction with pocket change to the subcutaneous position, *Plast. Reconstr. Surg.* 135 (6) (2015) 1540–1544.

- [3] R.B. Lentz, M.L. Piper, C. Gomez-Sanchez, H. Sbitany, Correction of breast animation deformity following prosthetic breast reconstruction, *Plast. Reconstr. Surg.* 140 (4) (2017) 643e–644e.
- [4] N. Alnaif, T. Safran, A. Vezel-Mathieu, B. Alhalabi, T. Dionisopoulos, Treatment of breast animation deformity: a systematic review, *J. Plast. Reconstr. Aesthet. Surg.* 72 (5) (2019) 781–788.
- [5] R.J. Bramhall, I. Hernan, P.A. Harris, A single-centre, retrospective proof-of-concept review of salvage of infected or exposed implant breast reconstructions with explantation and one-stage free flap replacement, *J. Plast. Reconstr. Aesthet. Surg.* 71 (2) (2018) 194–200.
- [6] M.P. Marquez, R. Fernandez-Riera, H.V. Cardona, J.M.R. Flores, Immediate implant replacement with DIEP flap: a single-stage salvage option in failed implant-based breast reconstruction, *World J. Surg. Oncol.* 16 (1) (2018) 80.
- [7] N.G. Rabey, K.H. Lie, D. Kumiponjera, E. Erel, J.W. Simcock, C.M. Malata, Salvage of failed prosthetic breast reconstructions by autologous conversion with free tissue transfers, *Eplasty* 13 (2013) e32.
- [8] R. Zhao, B.N.N. Tran, A.F. Doval, G. Broadwater, K.J. Buretta, J.P. Orr, B.T. Lee, S.T. Hollenbeck, A multicenter analysis examining patients undergoing conversion of implant-based breast reconstruction to abdominally based free tissue transfer, *J. Reconstr. Microsurg.* 34 (9) (2018) 685–691.
- [9] S.R. Ali, W.J.M. Holmes, M. Quinn, A.T. Emam, E. Prouskaia, S.M. Wilson, Tertiary breast reconstruction for salvage of the failed implant-based reconstruction using the deep inferior epigastric perforator flap, *J. Reconstr. Microsurg.* 34 (9) (2019) e1–e2, <http://dx.doi.org/10.1055/s-0039-1679885>.
- [10] M. Dieterich, A. Dragu, A. Stachs, J. Stubert, Clinical approaches to breast reconstruction: what is the appropriate reconstructive procedure for my patient? *Breast Care (Basel)* 12 (6) (2017) 368–373.
- [11] A. Figus, M. Mazzocchi, L.A. Dessy, G. Curinga, N. Scuderi, Treatment of muscular contraction deformities with botulinum toxin type A after latissimus dorsi flap and sub-pectoral implant breast reconstruction, *J. Plast. Reconstr. Aesthet. Surg.* 62 (7) (2009) 869–875.
- [12] A. Richards, M. Ritz, S. Donahoe, G. Southwick, Botox for contraction of pectoral muscles, *Plast. Reconstr. Surg.* 108 (1) (2001) 270–271.
- [13] A. Gabriel, S. Sigalove, N.M. Sigalove, T.L. Storm-Dickerson, J. Rice, N. Pope, G.P. Maxwell, Prepectoral revision breast reconstruction for treatment of implant-associated animation deformity: a review of 102 reconstructions, *Aesthet. Surg. J.* 38 (5) (2018) 519–526.
- [14] R. Lentz, A. Alcon, H. Sbitany, Correction of animation deformity with subpectoral to prepectoral implant exchange, *Gland Surg.* 8 (1) (2019) 75–81.
- [15] R.A. Baxter, Acellular dermal matrices in breast implant surgery: defining the problem and proof of concept, *Clin. Plast. Surg.* 39 (2) (2012) 103–112.
- [16] S.L. Spear, S.R. Sher, A. Al-Attar, T. Pittman, Applications of acellular dermal matrix in revision breast reconstruction surgery, *Plast. Reconstr. Surg.* 133 (1) (2014) 1–10.
- [17] S. Bruner, O. Frerichs, W. Schneider, H. Fansa, Autologous tissue transplantation (TRAM/DIEP) as an option of therapy in capsular contracture, *Handchir. Mikrochir. Plast. Chir.* 36 (6) (2004) 362–366.
- [18] M. Coriddi, D. Shenaq, E. Kenworthy, J. Mbabuike, J. Nelson, A. Pusic, B. Mehrara, J.J. Disa, Autologous breast reconstruction after failed implant-based reconstruction: evaluation of surgical and patient-reported outcomes and quality of life, *Plast. Reconstr. Surg.* 143 (2) (2019) 373–379.
- [19] L.J. Feng, K. Mauceri, B.E. Berger, Autogenous tissue breast reconstruction in the silicone-intolerant patient, *Cancer* 74 (1 Suppl) (1994) 440–449.
- [20] W.J.M. Holmes, M. Quinn, A.T. Emam, S.R. Ali, E. Prouskaia, S.M. Wilson, Salvage of the failed implant-based breast reconstruction using the Deep Inferior Epigastric Perforator Flap: a single centre experience with tertiary breast reconstruction, *J. Plast. Reconstr. Aesthet. Surg.* 72 (7) (2019) 1075–1083.
- [21] S.M. Levine, M.E. Lester, B. Fontenot, R.J. Allen Sr., Perforator flap breast reconstruction after unsatisfactory implant reconstruction, *Ann. Plast. Surg.* 66 (5) (2011) 513–517.
- [22] N.J. Visser, T.H. Damen, R. Timman, S.O. Hofer, M.A. Mureau, Surgical results, aesthetic outcome, and patient satisfaction after microsurgical autologous breast reconstruction following failed implant reconstruction, *Plast. Reconstr. Surg.* 126 (1) (2010) 26–36.
- [23] A. Mosahebi, D. Atherton, V. Ramakrishnan, Immediate bilateral autologous breast reconstruction for silicone intolerance, *Br. J. Plast. Surg.* 58 (5) (2005) 714–716.
- [24] M. Hamdi, B. Casaer, P. Andrades, F. Thiessen, A. Dancy, S. D'Arpa, K. Van Landuyt, Salvage (tertiary) breast reconstruction after implant failure, *J. Plast. Reconstr. Aesthet. Surg.* 64 (3) (2011) 353–359.
- [25] R. Gurunluoglu, M. Shafiqhi, A. Schwabegger, M. Ninkovic, Secondary breast reconstruction with deepithelialized free flaps from the lower abdomen for intractable capsular contracture and maintenance of breast volume, *J. Reconstr. Microsurg.* 21 (1) (2005) 35–41.
- [26] A. Gravvanis, D. Kakagia, G. Samouris, E. Galani, D. Tsoutsos, Tips and outcomes of a new DIEP flap inset in delayed breast reconstruction: the dual-plane technique, *J. Reconstr. Microsurg.* 32 (5) (2016) 366–370.
- [27] A. Gravvanis, G. Samouris, E. Galani, D. Tsoutsos, Dual plane diep flap inset: optimizing esthetic outcome in delayed autologous breast reconstruction, *Microsurgery* 35 (6) (2015) 432–440.
- [28] S.J. Kronowitz, Delayed-immediate breast reconstruction: technical and timing considerations, *Plast. Reconstr. Surg.* 125 (2) (2010) 463–474.

Open Access

This article is published Open Access at [sciencedirect.com](https://www.sciencedirect.com). It is distributed under the [IJSCR Supplemental terms and conditions](#), which permits unrestricted non commercial use, distribution, and reproduction in any medium, provided the original authors and source are credited.