

# Anatomical mapping of lymph nodes in patients receiving salvage lymphadenectomy based on a positive 11C-choline positron emission tomography/computed tomography scan

Steven Deconinck<sup>1,3</sup>, Lorenzo Tosco<sup>2,3</sup>, Luc Merckx<sup>4</sup>, Olivier Gheysens<sup>5,6</sup>, Christophe M. Deroose<sup>5,6</sup>, Marcella Baldewijns<sup>7</sup>, Birgit Weynand<sup>7</sup>, Koen Van Laere<sup>7</sup>, Raymond Oyen<sup>8</sup>, Hein Van Poppel<sup>2</sup>, Steven Joniau<sup>2</sup>, Karolien E. Goffin<sup>5,6</sup>

<sup>1</sup>Department of Urology, AZ Sint-Blasius, Dendermonde, Belgium

<sup>2</sup>Urology, Department of Development and Regeneration, University Hospitals Leuven, Leuven, Belgium

<sup>3</sup>Department of Urology, Humanitas Gradenigo Hospital, Turin, Italy

<sup>4</sup>Department of Urology, AZ Sint-Lucas, Ghent, Belgium

<sup>5</sup>Nuclear Medicine, UZ Leuven, Leuven, Belgium

<sup>6</sup>Nuclear Medicine & Molecular Imaging, Department of Imaging and Pathology, KU Leuven, Leuven, Belgium

<sup>7</sup>Histopathology, UZ Leuven, Leuven, Belgium

<sup>8</sup>Radiology, UZ Leuven, Leuven, Belgium

**Citation:** Deconinck S, Tosco L, Merckx L, et al. Anatomical mapping of lymph nodes in patients receiving salvage lymphadenectomy based on a positive 11c-choline positron emission tomography/computed tomography (PET/CT) scan. Cent European J Urol. 2019; 72: 232-239.

## Article history

Submitted: June 3, 2019

Accepted: Aug. 9, 2019

Published online: Sept. 5, 2019

## Corresponding author

Steven Deconinck  
Department of Urology  
AZ Sint-Blasius  
50 Kroonveldlaan  
9200 Dendermonde  
Belgium  
steven84.deconinck@gmail.com

**Introduction** This paper aims to assess the diagnostic accuracy of an 11C-choline positron emission tomography/computed tomography (PET/CT) scan in the detection of lymph node (LN) metastases in patients with biochemical recurrence after radically treated prostate cancer (PCa), as compared to histology. The secondary goal is to depict spreading patterns of metastatic LNs in recurrent PCa.

**Material and methods** A single center retrospective study comprising of 30 patients who underwent retroperitoneal and/or pelvic salvage lymph node dissection (LND) due to 11C-choline PET/CT-positive nodal recurrences after radical treatment (median Prostate Specific Antigen (PSA) 1.5 ng/ml, range 0.2–11.4). Positive nodes on the preoperative PET/CT scans were mapped and compared to post-operative pathology results.

LNs were marked as true positive, false positive, true negative and false negative and a patient- and a region-based analysis was performed. Sensitivity, specificity and positive/negative predictive value (PPV/NPV) were calculated.

**Results** Sixty positive LNs were detected on PET/CT with a median number of two positive nodes per patient (range 1–6). In 29 patients, a super-extended pelvic LND (PLND) was performed combined with a retroperitoneal LND (RPLND) in 13 of those cases. One patient underwent an inguinal LND. One hundred thirty-seven of 644 resected LNs contained metastases. The 11C-choline PET/CT scan correctly predicted 31 positive nodes (55%) while 25 nodes were falsely positive (45%). One hundred and six histologically proven metastatic nodes were not detected on the 11C-choline PET/CT scan (77%). Sensitivity, specificity, PPV and NPV of the 11C-choline PET/CT were 23%, 95%, 55% and 82%, respectively.

**Conclusions** 11C-choline PET/CT has a relatively low detection rate and a moderate PPV for metastatic LNs in patients with biochemical recurrence after radically treated PCa.

**Key Words:** 11C-choline PET/CT <> biochemical recurrence <> prostate cancer <> salvage lymphadenectomy

## INTRODUCTION

Radical treatments such as radical prostatectomy (RP) and external beam radiotherapy (EBRT) are well-established therapeutic options in the management of localized prostate cancer (PCa). Despite all of the technical improvements, 20–30% of patients after RP [1] and 30–40% of men after EBRT [2, 3] will experience recurrence. PCa recurrence can be local, in regional pelvic lymph node metastases (LNM) or in distant metastases (distant LNM, bone or soft tissue metastases). Local PCa recurrence can be treated by salvage radiotherapy (RT) of the prostate fossa with good results [4]. In contrast, a rise in prostate specific antigen (PSA) in patients without recurrence in the prostatic fossa, often points to (micro) metastatic disease making its treatment challenging. Salvage lymph node dissection (LND) has recently been brought forward as an option in the treatment of oligometastatic PCa with up to 40% of men being without clinical recurrence after a median follow-up of 81 months [5, 6]. Therefore, accurate imaging to assess the extent and localization of the relapse is of great importance and has been the subject of many research projects. The European Association of Urology (EAU) guidelines acknowledge the low diagnostic yield of bone scan and abdominopelvic CT [7].

Before the introduction of the Prostate-Specific Membrane Antigen-based (PSMA) PET/CT, 11C-choline [8] and 18F-fluorocholine [9] PET/CT were considered to be amongst the most accurate tools available for detection of metastatic lesions in patients with biochemical recurrence [4]. However, the level of evidence remains limited since many of the supporting studies are retrospective, explorative and without pathological verification. Moreover, resection templates are often limited and targeted on the PET-positive lesions [2, 10, 11, 12].

We performed a histology verified retrospective analysis comparing the preoperative 11C-choline PET/CT with histology in patients after salvage LND for PSA relapse after treatment with curative intention. Furthermore, all resected lymph nodes (LNs) were anatomically mapped in an attempt to depict the spreading patterns of metastatic LNs in recurrent PCa.

## MATERIAL AND METHODS

### Patients

Medical records of all patients who underwent salvage LND at our institution between December 2011 and December 2014 were reviewed retrospectively. Patients with biochemically recurrent PCa after pri-

mary treatment with RP, EBRT, brachytherapy (BT) or high intensity focused ultrasound (HIFU) and with evidence of nodal 11C-choline PET/CT-positivity were considered for inclusion. PSA relapse was defined as two consecutive rises of PSA greater than 0.2 ng/ml after RP or three consecutive rises of PSA above the nadir after EBRT, BT or HIFU [13, 14]. Patients with one to a maximum of six positive lesions on an 11C-choline PET/CT scan were eligible for salvage LND. Patients with symptomatic metastases, inoperable disease or previous treatment with cytotoxic agents for PCa were excluded. Thirty patients with inclusion criteria provided consent for surgery and for data collection for scientific publication. Eight of them were on androgen deprivation therapy (ADT) at the moment of the PET by / CT. Detailed patient characteristics are reported in Table 1. The local ethical review board approved the study.

### 11C-choline PET/CT

11C-choline PET/CT images were acquired using a Siemens Biograph Hirez 16-slice or TruePoint 40-slice PET/CT system (Siemens Medical, Erlangen, Germany) after at least 6 hours of fasting, as previously described [15]. Immediately after injection of 740 to 1000 MBq of 11C-choline, a contrast-enhanced CT scan was performed with 120 ml of a non-ionic contrast agent injected intravenously (Ultravist, Schering), followed by the 11C-choline PET-emission scan. PET data were acquired in six bed positions with a 5 minute scanning time per bed position, starting from the pelvis at approximately 4 minutes after injection. Images were iteratively reconstructed using Ordered Subsets Expectation Maximization (5 iterations and 8 subsets) with an isotropic Gaussian postreconstruction smoothing of 6 mm. Attenuation correction was performed using CT. All scans were retrospectively analyzed by an experienced nuclear medicine specialist (K.E.G.), who was blinded from all other data, using Hermes Hybrid Viewer (Hermes Medical Solutions, Stockholm, Sweden). Sites of pathological 11C-choline uptake were compared with background activity and were assigned to a LN region based on the overlaid CT images.

### Surgery

Surgery was performed by two experienced surgeons (H.V.P., S.J.). The surgical plan was based on the 11C-choline PET/CT-scans. All but one patient underwent pelvic LND (PLND), associated with a retroperitoneal LND (RPLND) in 13 of those cases. One patient received superficial and deep inguinal LND

**Table 1.** Patient characteristics

Age at salvage therapy median (range)	67 years (56–75)
Initial PSA median (range)	8.5 ng/ml (2.0–40.0)
Primary treatment (%)	26 (87%) Radical prostatectomy 2 (7%) Brachytherapy 1 (3%) Radiotherapy 1 (3%) HIFU
T stage at initial treatment	
T1 (%)	1 (3%)
T2	8 (27%)
T3	20 (67%)
Unknown	1 (3%)
Primary LND at radical prostatectomy (%)	20 (67%)
pN stage	
Nx (%)	10 (33%)
N0	18 (60%)
N1	2 (7%)
Gleason Score (GS)	
GS ≤6	1
GS 7	12
GS 8–10	15
NA	2
Adjuvant/salvage radiotherapy (%)	19 (63%)
Years to salvage LND in years median (range)	6.8 years (0.65–16.4)
PSA at salvage LND median (range)	1.5 ng/ml (0.22–11.4)
Patients with ADT at salvage LND (%)	8 (26.6%)
Salvage PLND (%)	16 (53.3%)
Salvage PLND + RPLND (%)	13 (43.3%)
Salvage inguinal LND (%)	1 (3.3%)
Nodes resected median (range)	17 (3–76)
Nodes positive (%)	137/644 (21.3%)
Nodes positive median (range)	2 (0–33)

PSA – prostate specific antigen; HIFU – high intensity focused ultrasound; LND – lymph node dissection; ADT – androgen deprivation therapy; PLND – pelvic lymph node dissection

**Table 2.** Per-patient analysis: Table indicating the patients with only true positive (TP) lymph nodes (LNs), only false positive (FP) LNs or TP and FP LNs at the same time. The vertical rows indicate in which patients extra false negative (FN) nodes were diagnosed at pathology

	Without extra FN	With extra FN	Total
Pt with only TP	6 (20%)	9 (30%)	15 (50%)
Pt with only FP	7 (23%)	5 (17%)	12 (40%)
Pt with TP+FP	0 (0%)	3 (10%)	3 (10%)
Total	13 (43%)	17 (57%)	

without PLND. During surgery, a super-extended (se) PLND was always attempted, as previously described [16]. RPLND was performed if positive nodes were seen in the retroperitoneal lymph node regions. The following anatomic regions were used to locate the nodes on the 11C-choline PET/CT scan as well as for the surgical resection template as previously

described [17]: para-aortic, paracaval, preaortic, precaval, interaortocaval, common iliac, external iliac, obturator fossa, internal iliac, presacral, pararectal, inguinal.

All dissected nodes were sent to pathology in separate containers according to the region of dissection. In four cases, adjacent regions were dissected en bloc and sent together for histological evaluation. Histopathological data were compared with the results of the preoperative 11C-choline PET/CT scans in a per-region analysis. Four nodes were positive on the a posteriori revision of the PET scans without pathology available for analysis.

All LNs were mapped on a vascular map according to their status.

## Histopathology

All specimens were delivered in separate boxes labeled according to the anatomical area. In four patients the specimen of a few adjacent regions was sent en bloc. LNs were fixed in 6% formalin. All stations were examined by visual inspection, palpation and sectioning. Each identified LN was cut in two before paraffin embedding. From these blocks, one 5 μm section was cut per LN. The pathologist microscopically evaluated the presence of metastases in each section after staining with hematoxylin and eosin.

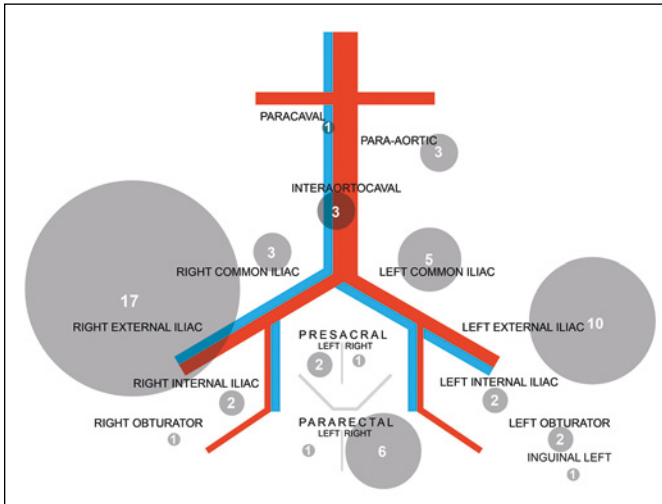
## Statistics

A comparison of the different proportions was performed by the Chi square test or Fisher's exact test. Sensitivity and specificity, as well as positive and negative predictive (PPV/NPV) value were calculated according to their standard definitions. All significance levels were set at 0.05 (MedCalc Software, Mariakerke, Belgium).

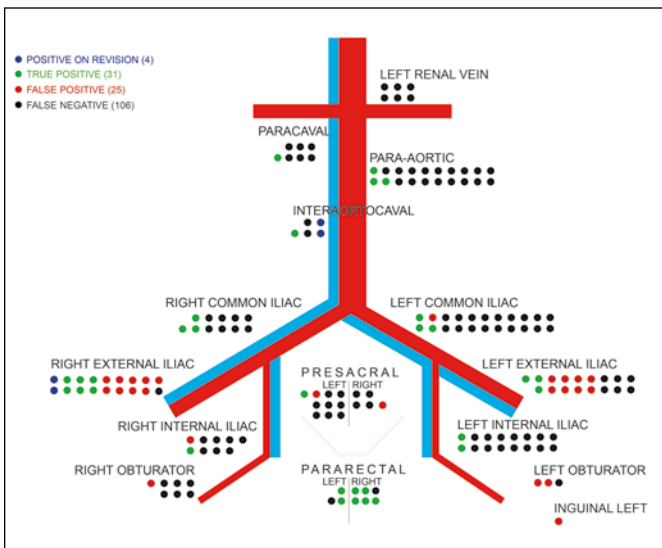
## RESULTS

11C-choline PET/CT detected 60 suspicious LNs with a median of two positive nodes per patient (range 1–6). These PET/CT-positive nodes were seen in the following 16 regions: right external iliac (17), left external iliac (10), right pararectal (6), left common iliac (5), para-aortic / interaortocaval / right common iliac (3), left obturator / right internal iliac / left internal iliac / left presacral (2), precaval / right obturator / right presacral / left pararectal / inguinal (1) (Figure 1).

A total of 644 LNs were resected with a median of 17 nodes per patient (range 3–76). Ninety nodes were retroperitoneal nodes resected during RPLND in 13 patients. Five hundred forty six nodes were



**Figure 1.** Distribution of all 60 positive nodes on 11C-choline PET/CT-scan. The nodes are depicted according to their anatomic location on the PET-scan.



**Figure 2.** True positive (green), false positive (red) and false negative (black) lymph nodes and their anatomic distribution. Nodes positive on revision but not resected are depicted in blue.

pelvic nodes resected during PLND in 29 patients and 8 nodes were resected during inguinal dissection in one patient. One hundred thirty-seven nodes were positive at final pathology (21%) with a median of two nodes per patient (range 0–33). Thirty-six of these positive nodes were retroperitoneal (26%), while there were no positive inguinal nodes. In seven patients (23%), no positive nodes were found at final pathology.

In a region-based analysis, 31 (55%) of the PET-positive nodes were true positives (TP), while 25 (45%) were false positives (FP) (Figure 2). Four nodes were only seen at the time of the revision of the PET/CT scans and were not resected. As many as 106 (77%) of the histologically-positive nodes were false negatives (FN) on the PET/CT (Figure 2). This results in a per-region sensitivity, specificity and PPV of 23%, 95% and 55%, respectively.

In a per-patient analysis, 15 (50%) patients had TP without FP nodes, 12 (40%) had FP nodes without TP and 3 (10%) patients had both (Table 2). No pathologic LNs were found in 7 patients (23%).

In 17 (57%) patients, additional FN LNs were diagnosed after histological examination. Table 3 and 4 show the relative distribution of LNs according to the anatomical regions. Attention should be brought to the fact that retroperitoneal sensitivity was 14% compared to 26% in the pelvic region. Specificity was 100% in the retroperitoneal area and 95% in the pelvic area. In addition, it is remarkable that 17 (68%) of the 25 FP LNs were situated in the external iliac regions, while the retroperitoneal nodes did not reveal any FPs. Furthermore, all seven PET-positive pararectal nodes were confirmed malignant by histology.

**DISCUSSION**

Few studies assessing the diagnostic accuracy of 11C-choline PET/CT and 18F-fluorocholine PET/CT for LN staging in recurrent PCa have used histological verification as their reference standard [2, 11, 12,

**Table 3.** This table indicates a detailed view on the distribution of the retroperitoneal lymph nodes. Sensitivity and specificity for retroperitoneal lymph node dissection (RPLND) were 14% and 100%

	Nodes resected	True positive	False positive	False negative	True negative nodes
Para-aortic	43	3 (7%)	0 (0%)	17 (40%)	23 (54%)
Left renal vein	11	0 (0%)	0 (0%)	6 (55%)	5 (46%)
Para-caval	23	1 (4%)	0 (0%)	6 (26%)	16 (70%)
Pre-aortic	4	0 (0%)	0 (0%)	0 (0%)	4 (100%)
Pre-caval	1	0 (0%)	0 (0%)	0 (0%)	1 (100%)
Interaortocaval	8	1 (13%)	0 (0%)	2 (25%)	5 (63%)
RPLND	90	5 (6%)	0 (0%)	31 (34%)	54 (60%)



**Table 4.** This table indicates a detailed view on the distribution of the retroperitoneal lymph nodes. Sensitivity and specificity for pelvic lymph node dissection (PLND) were 26% and 95%

	Nodes resected	True positive	False positive	False negative	True negative nodes
Common Iliac Right	52	3 (6%)	0 (0%)	8 (15%)	41 (79%)
Common Iliac Left	67	3 (5%)	1 (2%)	18 (27%)	45 (67%)
External Iliac Right	79	6 (8%)	9 (11%)	1 (1%)	63 (80%)
External Iliac Left	76	3 (4%)	8 (11%)	6 (8%)	59 (78%)
Obturator Right	51	0 (0%)	1 (2%)	6 (12%)	44 (86%)
Obturator Left	39	0 (0%)	2 (5%)	1 (3%)	36 (92%)
Internal Left	48	2 (4%)	0 (0%)	14 (29%)	32 (67%)
Internal Right	48	1 (2%)	1 (2%)	7 (15%)	39 (81%)
Presacral Right	42	0 (0%)	1 (2%)	4 (10%)	37 (88%)
Presacral Left	30	1 (3%)	1 (3%)	8 (27%)	20 (67%)
Para-rectal Right	6	5 (83%)	0 (0%)	1 (17%)	0 (0%)
Para-rectal Left	8	2 (25%)	0 (0%)	1 (13%)	5 (63%)
PLND	546	26 (4.8%)	24 (4.4%)	75 (13.7%)	421 (77.1%)

17–20, 34]. Moreover, patient groups were often heterogeneous and resection templates limited and not standardized. Jilg et al. [20] described a retrospective series of 72 patients with nodal recurrence on 11C-choline or 18F-fluoroethylcholine PET/CT undergoing salvage PLND and/or RPLND. Metastases were present in 681 of 2122 resected LNs. Region-, sub-region- and lesion-based sensitivity, specificity, PPV, NPV and accuracy were 91.9%, 83.7%, 92.7%, 82.0% and 89.4% (region-based), 80.7%, 93.5%, 91.9%, 84.1% and 87.3% (sub-region-based), and 57.0%, 98.4%, 94.5%, 82.6% and 84.9% (lesion-based), respectively. To our knowledge, there are only a few prospective studies that used histological verification to evaluate the staging accuracy of 11C-choline PET/CT in detecting LNMs in recurrent PCa. Scattoni et al. [18] performed a prospective trial comprising of 21 patients with positive lesions on 11C-choline PET/CT. A per-lesion analysis revealed a sensitivity of 64%, specificity of 90% and a relatively low NPV of 72%. Passoni et al. [19] prospectively included 46 patients with a single positive LN on 11C-choline PET/CT. They report a poor PPV of 34.8% on a lesion-based analysis. Our series consists of a retrospective analysis of 30 patients treated with salvage LND. Resected LNs were kept separate according to small anatomic regions when sent for histology in an attempt to make per-region analysis and mapping as accurate as possible. A total of 644 nodes were resected with a median of 17 LNs (range 3–76) per patient, indicating the extent of the salvage LNDs.

All TP, FP and FN LNs were mapped on a vascular map in Figure 2. A brief look at the map reveals the most striking observations of this series.

Firstly, 11C-choline PET/CT indicated a large number of FP nodes (25 of 56 LNs, 45%). More importantly, as many as 17 (68%) of these FP LNs were seen in the left and right external iliac area and none were situated in the retroperitoneum. In a per-patient analysis, no positive nodes were found in seven (23%) of 30 patients, accounting for 12 of the 25 FP nodes. Seven of those were in the external iliac region, four in the obturator or sacral region and one in the inguinal region. FP nodes have previously been reported. Martini et al. [21], Scattoni et al. [18], Passoni et al. [19] and Schilling et al. [11] respectively reported 2 out of 8 (25%), 2 out of 21 (9.5%), 8 out of 46 (17%) and 3 out of 10 (30%) FP patients in a per-patient analysis.

Secondly, 106 out of 137 pathologically proven LN metastasis (77%) were not seen on the preoperative 11C-choline PET/CT and thus were FN. Out of the 36 positive nodes in the retroperitoneal area 31 (86%) were FN, whereas 75 (74%) of the 101 positive LNs in the pelvic region were FN. This difference was not significant ( $p = 0.2$ , Fisher's exact test). The most obvious reason for the high FN rate has already been described by Scattoni et al. [18] and Jilg et al. [20]. Scattoni et al. [18] reported that the mean maximum diameter of TP nodes (15.0 mm) was significantly larger than the diameter in FN nodes (6.3 mm;  $p = 0.0004$ ). These findings were confirmed by Jilg et al. [20]. They measured LN diameters and infiltration depth and performed a per-lesion analysis. A gradual increase of the imaging sensitivity was reported according to the tumor infiltration depth. Imaging sensitivity was 0.0%, 13%, 57% and 82% for a tumor infiltration depth of <2 mm, 2–3 mm,

5–6 mm and 10–11 mm, respectively. Unfortunately, we do not have data on the diameters of the positive LNs in our series. However, these results indicate that a minimal cancer volume is required in order to be detected by 11C-choline PET/CT. One can assume that the low sensitivity of choline PET/CT for the detection of LNs in our study is caused by the limited spatial resolution of our PET-systems (spatial resolution with a Full-Width-At-Half-Maximum (FWHM) of 6–8 mm). It is known that novel targeted radiotracers with high tumor-to-background ratios, such as 68Ga-PSMA ligands, result in superior sensitivity and specificity [22, 23]. In addition, more sensitive PET-detection systems could allow for higher spatial resolution [24] and possibly higher detection rates. Furthermore, it has been reported that the detection rates of choline PET/CT improve with increasing serum PSA concentrations [25, 26, 27]. In our series, the median PSA was relatively low at 1.5 ng/ml (range 0.22–11.4). One might argue that PSA levels lower than 1.5 ng/ml might be beyond the detection threshold.

However, a sub-analysis of the 15 patients with PSA levels higher than 1.5 ng/ml (median 2.54 ng/ml) compared to the 15 other patients (median 0.77 ng/ml) showed no significant difference in sensitivity, specificity and PPV being 25.8% vs. 20.0%, 94.0% vs. 96.4% and 48.5% vs. 65.2%, respectively.

The third important observation regards the mapping of the pathologically proven LN metastasis. Recurrent nodes were present from the pararectal area up to the renal vein. It is a notable observation that 16% (22/137) of recurrent positive nodes were situated in the presacral and pararectal areas. Moreover, up to 9% of patients with high risk PCa have been described with pathologic nodes in the presacral regions after primary RP with seLND [16]. This might support the argument for a standard presacral LND at the time of primary treatment in high risk PCa patients.

The limitations of this study are its retrospective nature and its relatively small number of patients primarily and secondarily treated with different techniques (RP, EBRT, HIFU or BT, ADT). The effect of ADT on the efficacy of 11C-choline PET/CT is controversial. Hormone therapy (HT) was ( $p < 0.05$ ) associated with a significantly increased risk in positive choline PET/CT results in an univariate analysis performed by Giovacchini et al. However, this effect was no longer significant

in multivariate analysis [28]. It should also be acknowledged that standard histopathology techniques were used, examining only one section of the lymph node histologically.

Notwithstanding, our data suggest that 11C-choline PET/CT tends to underestimate the extent of the disease and is consequently not the ideal staging study in biochemical recurrent PCa. One may conclude that there is an urgent need for more accurate and sensitive imaging. Particularly, on the background of the results reported on oligometastatic directed therapies [5, 6, 29, 30, 34]. 68Ga-PSMA PET/CT is widely believed to be the most potent alternative for choline PET/CT in PCa recurrence [23, 24, 31, 33]. Morigi et al. [23] prospectively compared the results of 68Ga-PSMA versus 18F-choline PET/CT scan in 38 patients with PCa recurrence and found significantly higher detection rates for 68Ga-PSMA (50% vs. 12.5% for PSA <0.5 ng/ml and 86% vs. 57% in PSA >0.5 and <2 ng/ml) with a higher tumor-to-background ratio. Eiber et al. performed a retrospective analysis in 248 patients with recurrence after RP [31], reporting detection rates as high as 96.8%, 93%, 72.7% and 57.9% for PSA levels >2 ng/ml, 1 to 2, 0.5 to 1 and <0.5 ng/ml, respectively. Prospective and pathology verified studies on the results 68Ga-PSMA PET/CT in recurrent PCa are, however, still scarce. Jilg et al. described a retrospective series of 30 patients in whom salvage LND was performed, reporting a sub-region sensitivity, specificity, PPV and NPV of 81.2%, 99.5%, 98.6%, 92.7 and 94.1% [32].

## CONCLUSIONS

In conclusion, positive 11C-choline PET/CT for lymph node involvement underestimates the number of invaded nodes at salvage pelvic or retroperitoneal lymph node dissection. In addition, our observations indicated a high rate of false positive nodes, which were mainly located in the external iliac regions. These findings suggest the limitations of 11C-choline PET/CT in the staging of patients with biochemical recurrence after radically treated PCa. Novel tracers combined with developments in PET hardware might allow for more accurate detection of sites of recurrent PCa in the near future.

## CONFLICTS OF INTEREST

The authors declare no conflicts of interest.

## References

1. Han M, Partin AW, Zahurak M, Piantadosi S, Epstein JI, Walsh PC. Biochemical (prostate specific antigen) recurrence probability following radical prostatectomy for clinically localized prostate cancer. *J Urol.* 2003; 169: 517-523.
2. Rinnab L, Mottaghy FM, Blumstein NM, et al. Evaluation of [11C]-choline positron-emission/computed tomography in patients with increasing prostate-specific antigen levels after primary treatment for prostate cancer. *BJU Int.* 2007; 100: 786-793.
3. Chism DB, Hanlon AL, Horwitz EM, Feigenberg SJ, Pollack A. A comparison of the single and double factor high-risk models for risk assignment of prostate cancer treated with 3D conformal radiotherapy. *Int J Radiat Oncol Biol Phys.* 2004; 59: 380-385.
4. Rischke HC, Knippen S, Kirste S, Grosu AL. Treatment of recurrent prostate cancer following radical prostatectomy: the radiation-oncologists point of view. *Q J Nucl Med Mol Imaging.* 2012; 56: 409-420.
5. Suardi N, Gandaglia G, Gallina A, et al. Long-term outcomes of salvage lymph node dissection for clinically recurrent prostate cancer: results of a single-institution series with a minimum follow-up of 5 years. *Eur Urol.* 2015; 67: 299-309.
6. Karnes RJ, Murphy CR, Bergstralh EJ, et al. Salvage lymph node dissection for prostate cancer nodal recurrence detected by 11C-choline positron emission tomography/computerized tomography. *J Urol.* 2015; 193: 111-116.
7. Heidenreich A, Bastian PJ, Bellmunt J, et al. EAU guidelines on prostate cancer. Part II: Treatment of advanced, relapsing, and castration-resistant prostate cancer. *Eur Urol.* 2014; 65: 467-479.
8. Picchio M, Briganti A, Fanti S, et al. The Role of Choline Positron Emission Tomography/Computed Tomography in the Management of Patients with Prostate-Specific Antigen Progression After Radical Treatment of Prostate Cancer. *Eur Urol.* 2011; 59: 51-60.
9. Bauman G, Belhocine T, Kovacs M, Ward A, Beheshti M, Rachinsky I. 18F-fluorocholine for prostate cancer imaging: a systematic review of the literature. *Prostate Cancer Prostatic Dis.* 2012; 15: 45-55.
10. Evangelista L, Zattoni F, Guttilla A, et al. Choline PET or PET/CT and biochemical relapse of prostate cancer: a systematic review and meta-analysis. *Clin Nucl Med.* 2013; 38: 305-314.
11. Schilling D, Schlemmer HP, Wagner PH, et al. Histological verification of 11C-choline-positron emission/computed tomography-positive lymph nodes in patients with biochemical failure after treatment for localized prostate cancer. *BJU Int.* 2008; 102: 446-451.
12. Husarik DB, Miralbell R, Dubs M, et al. Evaluation of [(18)F]-choline PET/CT for staging and restaging of prostate cancer. *Eur J Nucl Med Mol Imaging.* 2008; 35: 253-263.
13. Cookson MS, Aus G, Burnett AL, et al. Variation in the definition of biochemical recurrence in patients treated for localized prostate cancer: the American Urological Association prostate guidelines for localized prostate cancer update panel report and recommendations for a standard in the reporting of surgical outcomes. *J Urol.* 2007; 177: 540.
14. American Society for Therapeutic Radiology Oncology Consensus Panel. Consensus Statement: Guidelines for PSA following radiation therapy. *Int J Radiat Oncol Biol Phys.* 1997; 37: 1035-1041
15. Van den Bergh L, Lerut E, Haustermans K, et al. Final analysis of a prospective trial on functional imaging for nodal staging in patients with prostate cancer at high risk for lymph node involvement. *Urol Oncol.* 2015; 33: 109.e23-31.
16. Joniau S, Van den Bergh L. Mapping of pelvic lymph node metastases in prostate cancer. *Eur Urol.* 2013; 63: 450-458.
17. Budiharto T, Joniau S, Lerut E, et al. Prospective evaluation of 11C-choline positron emission tomography/computed tomography and diffusion-weighted magnetic resonance imaging for the nodal staging of prostate cancer with a high risk of lymph node metastases. *Eur Urol.* 2011; 60: 125-130.
18. Scattoni V, Picchio M, Suardi N, et al. Detection of lymph-node metastases with integrated [11C]choline PET/CT in patients with PSA failure after radical retropubic prostatectomy: results confirmed by open pelvic-retroperitoneal lymphadenectomy. *Eur Urol.* 2007; 52: 423-429.
19. Passoni NM, Suardi N, Abdollah F, et al. Utility of [11C]choline PET/CT in guiding lesion-targeted salvage therapies in patients with prostate cancer recurrence localized to a single lymph node at imaging: results from a pathologically validated series. *Urol Oncol.* 2014; 32: 38.e9-38.e16.
20. Jilg CA, Schultze-Seeman W, Drendel V, et al. Detection of Lymph Node Metastasis in Patients with Nodal Prostate Cancer Relapse Using 18F/11C-Choline Positron Emission Tomography/Computerized Tomography. *J Urol.* 2014; 192: 103-110.
21. Martini T, Mayr R, Trenti E, et al. The role of C-Choline-PET/CT-Guided Secondary Lymphadenectomy in Patients with PSA Failure After Prostatectomy: Lessons Learned from Eight Cases. *Adv Urol.* 2012; 60:1572.
22. Perera M, Papa N, Christidis D, et al. Sensitivity, Specificity, and Predictors of Positive 68Ga-Prostate-specific Membrane Antigen Positron Emission Tomography in Advanced Prostate Cancer: A Systematic Review and Meta-analysis. *Eur Urol.* 2016; 70: 926-937.
23. Morigi JJ, Stricker P, van Leeuwen PJ, et al. Prospective Comparison of the detection rate of 18F-Fluoromethylcholine and 68Ga-PSMA-HBED PET/CT in men with prostate cancer with rising PSA post curative treatment, being considered for targeted therapy. *J Nucl Med.* 2015; 56: 1185-1190.
24. Conti M. New prospects for PET in prostate cancer imaging: a physicist's viewpoint. *EJNMMI Phys.* 2014; 1: 11.
25. Krause BJ, Souvatzoglou SM, Tuncel M, et al. The detection rate of (11C)choline PET/CT depends on the serum PSA-value in patients with biochemical recurrence of prostate cancer. *Eur J Nucl Med Mol Imaging.* 2008; 35: 18-23.
26. Castellucci P, Fuccio C, Nanni C, et al. Influence of trigger PSA and PSA kinetics on 11C-choline PET/CT detection rate in patients with biochemical relapse after radical prostatectomy. *J Nucl Med.* 2009; 50: 1394-1400.
27. Castellucci P, Fuccio C, Rubello D, et al. Is there a role for 11C-choline PET/CT in the early detection of metastatic disease in surgically treated prostate cancer patients with a mild PSA increase <1.5 ng/ml? *Eur J Nucl Med Mol Imaging.* 2011; 38: 55-63.

28. Giovacchini G, Picchio M, Coradeschi E, et al. Predictive factors of  $^{11}\text{C}$ choline PET/CT in patients with biochemical failure after radical prostatectomy. *Eur J Nucl Med Mol Imaging*. 2010; 37: 301-309.
29. Ost P, Bossi A, Decaestecker K, et al. Metastasis-directed therapy of regional and distant recurrences after curative treatment of prostate cancer: a systematic review of the literature. *Eur Urol*. 2015; 67: 852-863.
30. Decaestecker K, De Meerleer G, Ameye F, et al. Surveillance or metastasis-directed Therapy for OligoMetastatic Prostate cancer recurrence (STOMP): study protocol for a randomized phase II trial. *BMC Cancer*. 2014; 14: 671-676.
31. Eiber M, Maurer T, Souvatzoglou M, et al. Evaluation of Hybrid  $^{68}\text{Ga}$ -PSMA Ligand PET/CT in 248 patients with Biochemical Recurrence After Radical Prostatectomy. *Eur J Nucl Med Mol Imaging*. 2015; 42: 197-209.
32. Jilg, E, Drendel V, Rischke HC, et al. Diagnostic Accuracy of  $^{68}\text{Ga}$ -HBED-CC-PSMA-Ligand-PET/CT before Salvage Lymph Node Dissection for Recurrent Prostate Cancer. *Theranostics*. 2017; 7: 1770-1780.
33. Ong WM, Zargar-Shoshtari K, Siva S, Zargar H. Prostate specific membrane antigen: the role in salvage lymph node dissection and radio-ligand therapy. *Minerva Urol Nefrol*. 2018; 70: 450-461.
34. Kolontarev K, Govorov A, Kasyan G, Rasner P, Vasiliev A, Pushkar D. Extended robotic salvage lymphadenectomy in patients with 'node-only' prostate cancer recurrence: initial experience. *Cent European J Urol*. 2018; 71: 162-167. ■