

## THE DEPRESSOR EFFECT OF SPLENO-RENO-PEXY ON HYPERTENSION DUE TO RENAL ISCHEMIA

BY DAVID M. WEEKS, M.D., ALFRED STEINER, M.D.,  
JAMES S. MANSFIELD, M.D., AND JOSEPH VICTOR, M.D.

*(From the Research Service, First Division, Welfare Hospital, Department of Hospitals, City of New York, and the Department of Medicine, College of Physicians and Surgeons, Columbia University, New York)*

(Received for publication, July 9, 1940)

Goldblatt (12), and many others (18, 33, 20, 32, 4, 8, 24) have shown that constriction of the renal arteries in dogs results in a sustained elevation of blood pressure. All procedures to relieve this type of hypertension, with the exception of bilateral suprarenalectomy (15, 2, 27, 7, 28) and possibly total extirpation of the pituitary gland (26, 9), have failed. Such varied procedures as renal denervation (25, 27, 8, 31), sympathectomy (1, 9, 19, 31), anterior nerve root section (14), splanchnicectomy (13, 2), thyroidectomy (11), shunting of renal vein blood through the liver (5, 21), destruction of the spinal cord (10), castration (27), and excision of the carotid sinuses (17) do not prevent or abolish the hypertension produced by renal ischemia.

Occasionally, even though the clamps on the renal arteries have been properly applied, a sustained rise in blood pressure does not occur. In these instances, an accessory arterial supply to the kidney has been found, going by way of the capsular or ureteral vessels, or both (12). These observations suggest that the collateral circulation in kidneys with constricted renal arteries, may prevent the production of persistent hypertension (16). It seemed of interest, therefore, to find out whether a collateral circulation to the ischemic kidney could be established, and to study the influence of such a circulation on the hypertension resulting from renal ischemia.

In a previous report (23) it was noted that pexis of omentum with one ischemic kidney produced a temporary fall in the blood pressure of hypertensive dogs. This pexis was carried out by wrapping omentum around a decapsulated kidney. On the other hand, unilateral spleno-reno-pxy in dogs rendered hypertensive by bilateral constriction of the renal arteries resulted in a fall in blood pressure to the normal level for the succeeding 9 weeks. Experiments of a similar nature have been reported by Cerqua and

Samaan (3). The latter found that unilaterally nephrectomized dogs developed hypertension when the renal artery of the remaining kidney was constricted. This hypertension was reduced following spleno-reno-pexy and returned after the fused organs were separated.

The object of the experiments described in this report was to study the production of collateral circulation to one ischemic kidney and its influence on the blood pressure of hypertensive dogs with bilateral renal ischemia. Three phases of this problem were examined; first, the influence of the pexis of spleen and one ischemic kidney on the blood pressure of dogs with bilateral renal ischemia; second, the demonstration of collateral circulation between the fused organs; and third, the effect of removal of the fused organs on the lowered blood pressure of the previously hypertensive dogs.

### *Methods*

Adult mongrel male dogs weighing 7 to 18 kg. were employed. Systolic blood pressure was determined by the Van Leersum carotid loop method (30). Readings were obtained by palpation distal to the pressure cuff by the same observer each day and under the same conditions. Hypertension was produced by the silver clamp technique described by Goldblatt *et al.* (12).

The spleen and one kidney were joined in nine dogs that were hypertensive for periods up to 4 months. The technique is as follows: Under nembutal anesthesia a cruciate incision, about 1 cm. deep, was made in the kidney. The long axis ran over the convex surface from pole to pole. The shorter axis ran transversely at the midpoint of the longitudinal incision. The edges of this incision were undercut to give a flat raw surface. The spleen was incised from the free distal edge almost to the pedicle and undercut to give a flat surface the size of the cut kidney. The cut surfaces of spleen and kidney are then apposed, and maintained in that position by means of three sutures of ribbon catgut. The catgut was brought through the substance of the kidney by means of an aneurysm needle to prevent its slipping off the rounded poles. It was then continued around the spleen between the vessels of the pedicle and the ends were fixed with a silk suture. The wide catgut was drawn tight enough to stop bleeding but not enough to cause pressure necrosis. In two control operations on hypertensive animals a similar cut surface of spleen was joined to the muscles of the abdominal wall.

After the spleno-reno-pexy was performed the blood pressure of the dogs was determined at frequent intervals for the ensuing 2 to 10 months. Two animals were sacrificed after 4 and 6 months. Six were operated upon to remove the fused organs. Three of these survived this last operation, one for 2 weeks and two were still alive 4 and 4½ months later. The blood pressures of the dogs that survived were observed to see what effect removal of the fused kidney and spleen had on the lowered blood pressures. The ninth dog is still being followed 2 months after a spleno-reno-pexy was performed.

To study the collateral circulation in the fused kidney and spleen the splenic artery was injected at a pressure of 125 mm. Hg with India ink suspended in 0.9 per cent NaCl after the joined organs were removed from the dog. This was performed with seven preparations. Following the injection, the organs were sliced perpendicular to the plane of fusion. From 9 to 15 cut surfaces of each pexis were examined histologically for the presence of ink.

### Protocols

The following are the individual records of each of the nine animals:

Dog 1 (Fig. 1). Male, mongrel, weight 11.8 kg.

Between *June 23* and *July 5, 1939*, the control systolic blood pressure varied between 135 and 170 mm. Hg. On *July 6* a clamp was placed on the right renal artery (R.C.) and the systolic blood pressure rose to 230 and then gradually fell to 185 mm. Hg. The left renal artery (L.C.) was clamped on *July 25* and thereafter the systolic blood pressure was maintained at 210–230 mm. Hg.

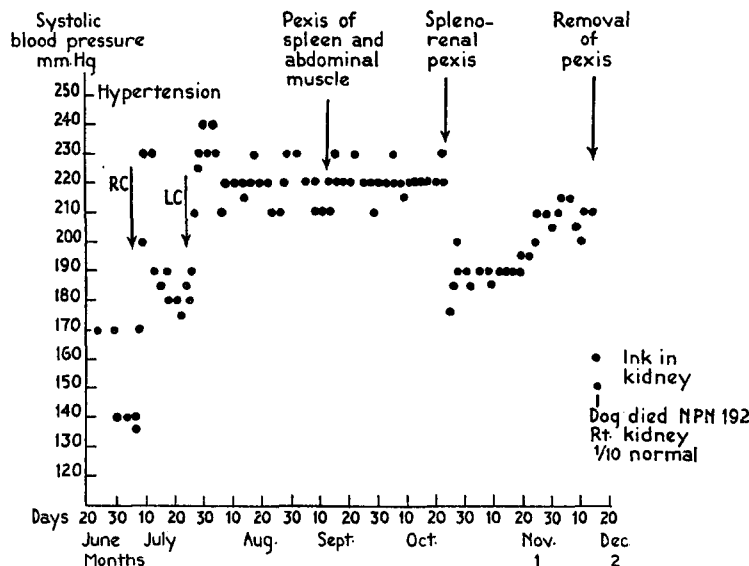


FIG. 1. Dog 1. Effect of spleno-renal pexis on experimental hypertension

A control operation joining the cut surface of the spleen with the abdominal wall was performed on *Sept. 12*. No change in blood pressure occurred during the 6 weeks of observation to *Oct. 24* when it still was 210–230 mm. Hg.

Pexis of the free edge of the spleen and the left kidney was performed on *Oct. 24*. The blood pressure abruptly fell to 175 and remained there until *Nov. 9*. Then it slowly rose to 190–210 mm. Hg.

The spleno-reno-pxy was removed on *Dec. 14* and the dog died 2 days later with lower blood pressure, the last reading being 140 mm. Hg, and a non-protein nitrogen of 192 mg. per cent. The right kidney was found to be shrunken at autopsy.

India ink was injected through the splenic artery into the excised fused organs and was found in the sinusoids of the spleen and the capillaries about the convoluted and collecting tubules of the kidney. None was present in the renal arteries nor in the glomeruli.

In summary, pexis of spleen and muscles of the abdominal wall had no effect on the elevated blood pressure whereas fusion of the spleen and one

ischemic kidney lowered the blood pressure during 2 months of observation. A collateral circulation was demonstrated between the sinusoids of the spleen and the capillaries about the renal tubules. None was present in the glomeruli.

Dog 7-5 (Fig. 2). Male, mongrel, weight 10.7 kg.

The control systolic blood pressure was 145-150 from *Apr. 22-25, 1937*. On *Apr. 26* a clamp to the right renal artery (R.C.) was followed by an elevation of the systolic

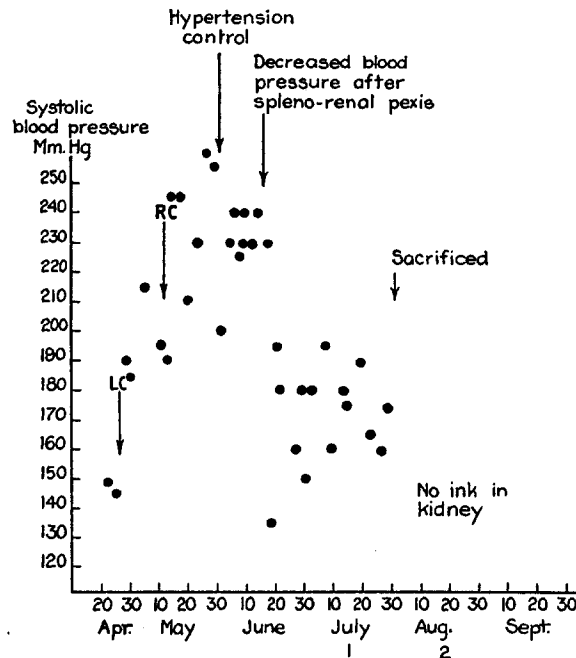


FIG. 2. Dog 7-5. Effect of spleno-renal pexis on experimental hypertension

blood pressure to 215. It then fell to 195 mm. Hg. A clamp was placed on the left renal artery (L.C.) on *May 12* and the systolic blood pressure then ranged from 210-255 mm. Hg.

A control operation, in which the omentum was manipulated, was carried out on *May 31*, without any effect on blood pressure for 2½ weeks during which time the pressure ranged from 200-240 mm. Hg.

Spleno-reno-pxy was performed on *June 17*. The systolic blood pressure immediately fell to 150-190 for the next 6 weeks. The dog was sacrificed on *July 28*.

The splenic artery of the excised preparation was not injected with ink.

In summary, a dog with hypertension of 5 weeks duration due to bilateral renal ischemia showed no change in blood pressure for 2½ weeks after laparotomy and manipulation of the omentum. However, immediately

after unilateral spleno-reno-pxy, the blood pressure fell for the ensuing 6 weeks during which the dog was observed. No attempt was made to study a collateral circulation between the excised fused organs.

Dog 7-2 (Fig. 3). Male, mongrel, weight 10.7 kg.

The control systolic blood pressure was 150 mm. Hg between *Apr. 14-18, 1938*. Following constriction of the right renal artery (R.C.) on *Apr. 19*, it rose to 240 and then fell to 175 mm. Hg within 3 weeks. The left renal clamp (L.C.) was applied on *May 24*

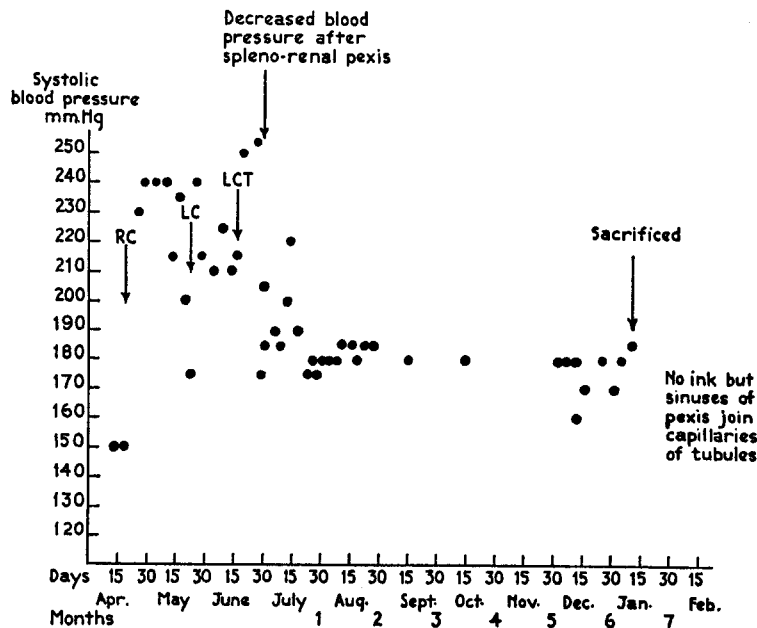


FIG. 3. Dog 7-2. Effect of spleno-renal pexis on experimental hypertension

and the systolic blood pressure rose to 215 mm. Hg. On *June 17*, the left renal clamp was tightened (L.C.T.) and the systolic blood pressure rose to 255 mm. Hg.

Pexis of the spleen and left kidney was carried out on *June 28*. The systolic blood pressure gradually fell to 175 and remained at about this level until 6½ months later at which time the dog was sacrificed, on *Jan. 12, 1939*.

No ink test for collateral circulation was made. However, large sinusoids of the scar between the joined organs communicated with the capillaries of the convoluted tubules.

In summary the hypertension that persisted in this dog for 2 months was lowered for 6½ months by unilateral spleno-reno-pxy.

Dog B (Fig. 4). Mongrel, male, weight 12.7 kg.

The control systolic blood pressure was 160-200 mm. Hg between *Oct. 27* and *Nov. 14, 1938*. The right renal clamp (R.C.) was applied *Nov. 16* and the blood pressure rose

to 300 mm. Hg and then fell to 200 mm. Hg within 3 weeks. After applying the left clamp (L.C.) on Dec. 20, the blood pressure ranged between 220–245 until Jan. 18, 1939.

Pexis of spleen and left kidney on Jan. 18, 1939, was followed by a slow decline in blood pressure to 170 mm. Hg 2 weeks later. It ranged between 130–180 until Oct. 13, a period of 9 months.

The spleno-reno-pexy was excised on Oct. 14, and the dog died within 12 hours because of hemorrhage from the renal pedicle.

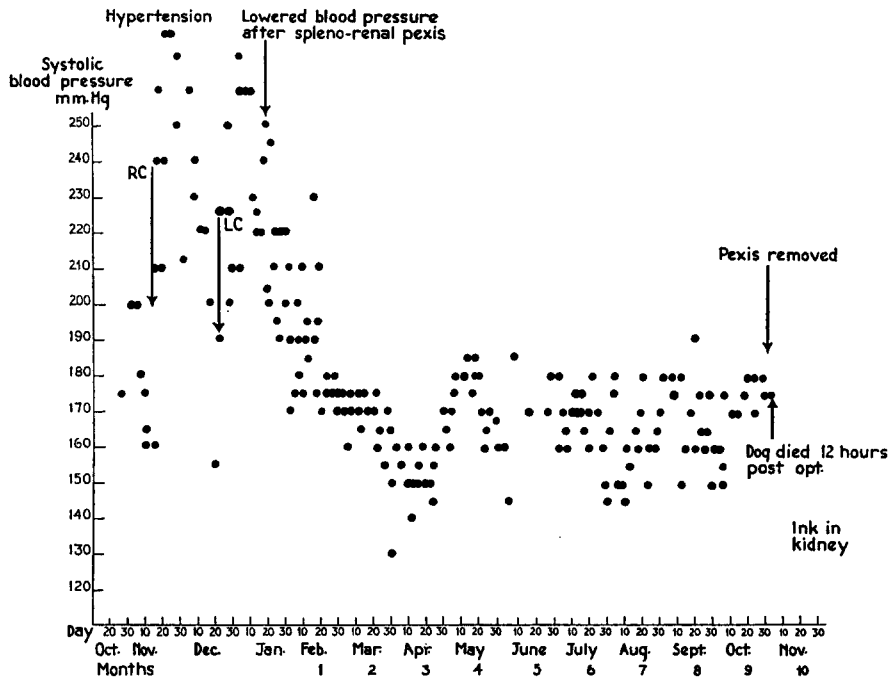


FIG. 4. Dog B. Effect of spleno-renal pexis on experimental hypertension

The India ink injected into the splenic artery of the fused preparation was found in the capillaries about the renal tubules, in the splenic sinusoids, and in the sinuses of the scar. None was seen in the renal arteries or glomeruli.

In summary this dog had hypertension for 2 months associated with clamping of both renal arteries. Following unilateral spleno-reno-pexy there was a fall in blood pressure to the prehypertensive level lasting 9 months, at which time the dog died after removal of the fused organs. A collateral circulation between the fused organs was demonstrated between the sinusoids of the spleen and the capillaries of the renal tubules.

Dog C (Fig. 5). Mongrel, male, weight 10.7 kg.

Between May 23–25, 1939, the control systolic blood pressure varied from 130–140 mm. Hg. After clamping the left kidney (L.C.) the blood pressure rose to 180 mm. Hg.

On *June 13* the application of the right renal clamp (R.C.) was followed by a rise to 270 and for a month remained between 230–260 mm. Hg.

Pexis of the spleen to the right kidney was performed on *July 13*. For the next 2½ months the blood pressure was normal ranging between 130 and 155 mm. Hg.

The fused organs were removed on *Sept. 26*. The dog died in shock 48 hours later. Following the last operation one reading of 110 mm. Hg was obtained.

India ink injected into the splenic artery, after removal of the fused organs, was not found at the site of pexis. Obviously the area supplied by the injected splenic artery

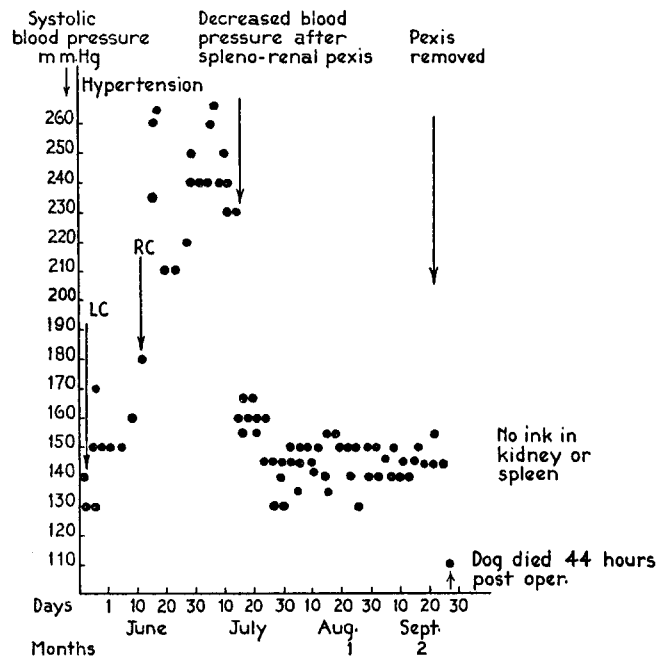


FIG. 5. Dog C. Effect of spleno-renal pexis on experimental hypertension

did not include the entire spleen since about one-third of this organ, near the pexis, did not contain ink. No ink was found in the kidney either.

In summary, spleno-reno-pexy to one kidney of an hypertensive dog with bilateral renal ischemia lowered the blood pressure to the prehypertensive level. No collateral circulation was demonstrated between the fused organs. Undoubtedly this was due to a faulty injection of the India ink.

Dog 6 (Fig. 6). Male, mongrel, weight 9.5 kg.

Between *Nov. 3, 1938*, and *Jan. 2, 1939*, the control systolic blood pressure was 120–150 mm. Hg. On *Jan. 3* a clamp on the right renal artery (R.C.) brought the systolic blood pressure to 210 and it then fell to 140 mm. Hg. Clamping the left renal artery (L.C.) on *Jan. 10* raised the pressure to 200 and then it fell to 130. On *Jan. 24* the left clamp was tightened (L.C.T.) and the systolic blood pressure rose to 175 mm. Hg. On

*Feb. 15*, the right clamp was tightened (R.C.T.) and the systolic blood pressure ranged between 175–190. The left clamp was again tightened (L.C.T.), on *Mar. 23* and the systolic pressure ranged between 190–200 mm. Hg.

Pexis of spleen and left kidney on *Mar. 29*, was followed by a fall of the systolic blood pressure to 140 within a week. The blood pressure went lower and finally ranged from 115–160 mm. Hg until *Oct. 16*, a period of 6½ months.

The fused organs were excised on *Oct. 17*, and the blood pressure rose to 235 mm. Hg during the next 2 weeks. The dog died on Nov. 1 with a non-protein nitrogen of 400 mg. per cent.

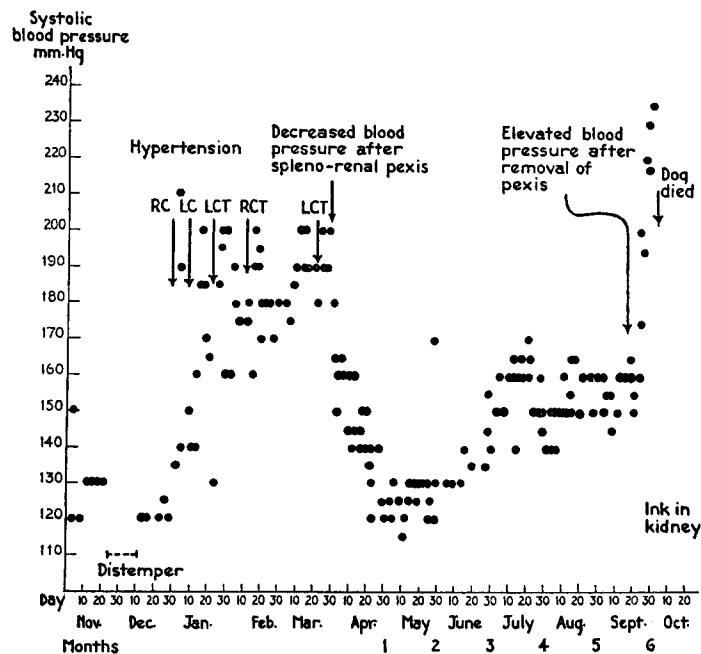


FIG. 6. Dog 6. Effect of spleno-renal pexis on experimental hypertension

Following injection of the India ink suspension into the splenic artery of the excised preparation, ink particles were found in the capillaries about the renal tubules as well as in the veins. In one of the 15 blocks obtained from this pexis ink was found in arteries and arterioles and glomeruli of a scarred area. Serial sections through this block showed that the ink came from a splenic artery brought into the scar by the operation. This artery anastomosed with smaller arteries of the kidney that finally reached the glomeruli. It should be emphasized that this was the only block showing ink within the renal arteries in this entire series.

In summary a dog with hypertension of 2 months duration due to bilateral renal ischemia had a reversal of the hypertension to normal levels following unilateral spleno-reno-pxy. This normal blood pressure persisted for 6½ months of observation. After removal of the fused organs the blood pres-



sure rose to hypertensive levels and the dog died in uremia 2 weeks later. Collateral circulation was demonstrated between the splenic sinusoids and the capillaries of the renal tubules. In only one of 15 blocks through the pexis was there ink in arteries or glomeruli and this was shown to be due to anastomosis of one of the splenic and one of the renal arteries.

Dog D (Fig. 7). Mongrel, male, weight 12.7 kg.

From *May 23-25, 1939*, the control systolic blood pressure was 120 mm. Hg. On *May 26* the right renal clamp (R.C.) was applied and the blood pressure rose to 170 mm.

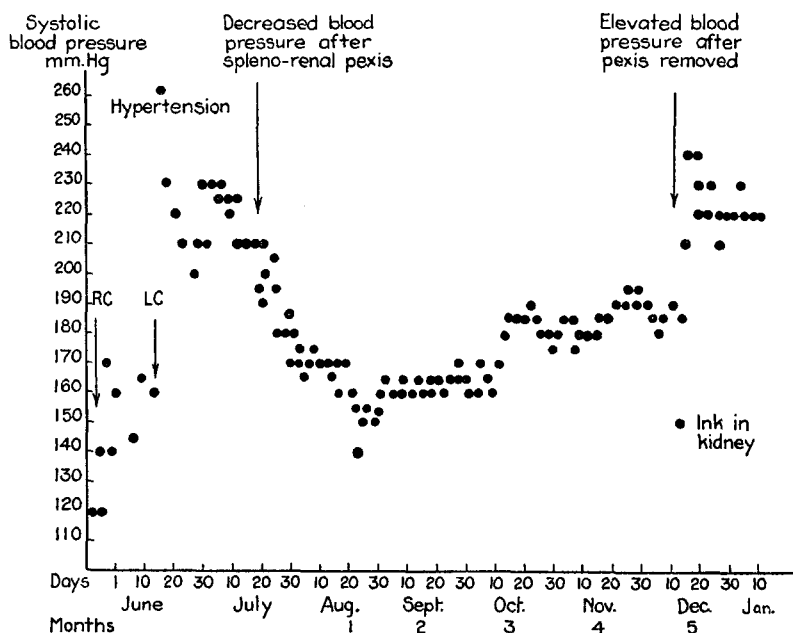


FIG. 7. Dog D. Effect of spleno-renal pexis on experimental hypertension

**Hg.** Following constriction of the left renal artery (L.C.) the systolic blood pressure ranged between 210-230 mm. Hg until *July 17*.

Pexis of the spleen and left kidney was performed on *July 19*. The systolic blood pressure slowly decreased to 150-160 during the following month, then slowly rose to 180-190, 5 months after the pexis was made.

The spleno-reno-pxy was excised on *Dec. 12*. The blood pressure rose to between 220-240 mm. Hg within 2 days and has remained at that level, 4 months later.

India ink injected into the splenic artery of the excised preparation was found in the splenic sinusoids and pulp, the capillaries about the renal tubules of the cortex and medulla, and also in the larger veins of the medulla. None was present in the arteries or glomeruli.

In summary, after 7 weeks of hypertension, unilateral spleno-reno-pxy lowered the systolic blood pressure. 5 months later, removal of the pexis

resulted in a return of hypertension. Collateral circulation was demonstrated between the sinusoids of the spleen and the capillaries about the renal convoluted and collecting tubules.

Dog 8 (Fig. 8). Male, mongrel, weight about 10 kg.

The control blood pressure was 135–155 mm. Hg from *Nov. 3–17, 1938*. After clamping the right renal artery (R.C.) raised the blood pressure to 230 mm. Hg, it was

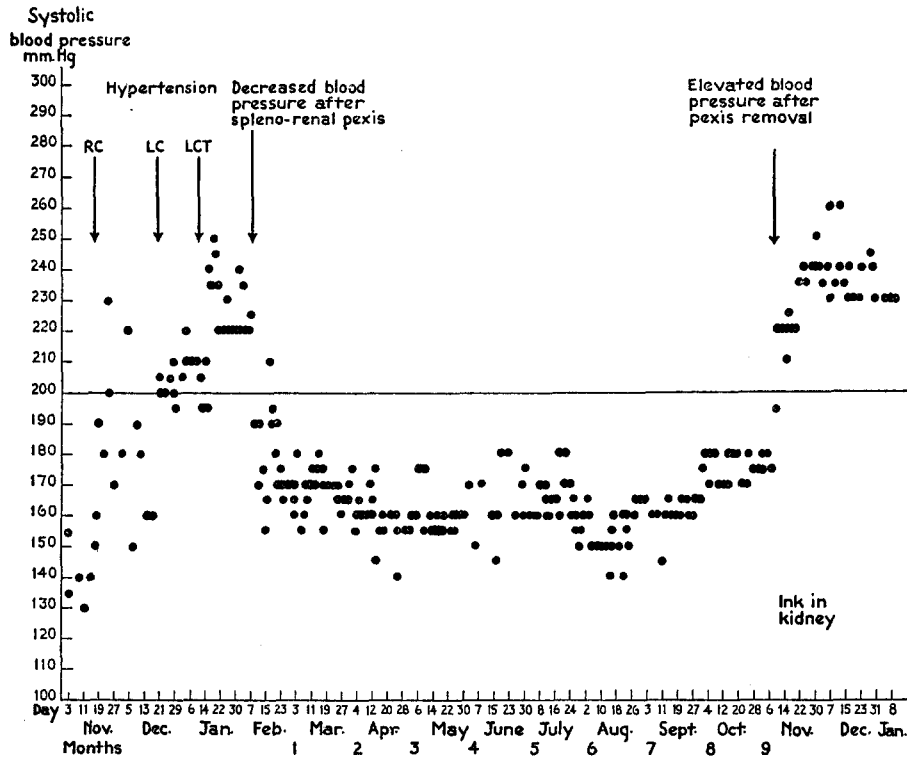


FIG. 8. Dog 8. Effect of spleno-renal pexis on experimental hypertension

followed by a fall to 160 mm. Hg within 3 weeks. On *Dec. 20*, the clamp to the left renal artery (L.C.) elevated the blood pressure to 195–210 mm. Hg. Tightening the left clamp (L.C.T.) on *Jan. 13, 1939*, raised the systolic pressure to 220–240 mm. Hg.

Pexis of the spleen and left kidney on *Feb. 8* was followed by a fall in blood pressure to 140–180 mm. Hg for 9 months.

Removal of the fused organs on *Nov. 8, 1939*, was followed by an elevation of blood pressure to 220–240 mm. Hg for the next 5 months. The dog is still hypertensive 6 months later.

The India ink injected into the splenic artery of the excised fused organs was found in the capillaries about the renal tubules. None was seen in the renal arteries or glomeruli.

In summary, in this hypertensive dog with bilateral renal ischemia, unilateral spleno-reno-pxy lowered the blood pressure to normal values for 9 months. Removal of the fused organs from the animal produced a return in the hypertension for 6 months. A collateral circulation was demonstrated between the capillaries of the renal tubules and the sinusoids of the spleen.

Dog 9. Male, mongrel, weight 10 kg.

The control systolic blood pressure was 170–180 mm. Hg between *Dec. 4–6, 1939*. On *Dec. 7*, a clamp was placed on the right renal artery and the blood pressure was maintained at 220–230 mm. Hg. A clamp was then applied to the left renal artery (L.C.) on *Dec. 19*, and the pressure went to 230–260 mm. Hg.

A control operation in which the cut surface of the spleen was sutured to the muscle of the anterior abdominal wall, was performed on *Jan. 16, 1940*. There was no significant change in the blood pressure level which ranged from 220–245 mm. Hg until *Mar. 27*.

Pexis of the other end of the spleen to the left kidney on *Mar. 27* resulted in a gradual fall in blood pressure to 175–190 in 2 weeks where it remained for the 2 months during which it was observed.

In summary, this dog had hypertension for 6 weeks. No significant change in blood pressure followed pexis of its spleen with the abdominal wall. 3 months later, or after 4½ months of hypertension, spleno-reno-pxy lowered the blood pressure significantly.

#### *Analysis of the Findings*

*Influence of Unilateral Spleno-Reno-Pxy on Hypertension of Dogs with Bilateral Renal Ischemia.*—Unilateral spleno-reno-pxy was performed on nine hypertensive dogs with bilaterally constricted renal arteries. The blood pressure was reduced in every instance after this procedure. In six cases the decreased blood pressure reached the prehypertensive levels.

The decreased blood pressure persisted throughout the period of observation, that is from 2 to 9½ months in eight instances. In one dog (Fig. 1) there was a temporary fall for 1 month, followed by a gradual elevation toward the hypertensive level. This case differed from the others in that the pexis was made by joining the cut surface of the spleen with the decapsulated cortex of the kidney instead of the cut surface of the kidney.

The rate at which the blood pressure fell after the spleno-reno-pxy varied in the different animals. In three the fall was precipitous (Figs. 1, 2, and 5). The other cases showed a gradual decline over a period of 2 to 4 weeks.

That the fall of blood pressure was not due to laparotomy or splitting the spleen is shown by the three controls in which these procedures produced no

significant changes in blood pressure, dogs 1, 7-5, and 9. That postoperative shock plays no rôle in this fall in blood pressure is apparent from the fact that the dogs walk about and eat well the day after the operation.

*Effect of Removal of the Spleno-Reno-Pexy on the Lowered Blood Pressure of Previously Hypertensive Dogs.*—The fused spleen and kidney were excised in six of the dogs. Three of these survived this operation more than 3 days. In each of the animals that survived the blood pressure returned to the hypertensive level, or above, in from 3 to 7 days (Figs. 6 to 8).

The three dogs that lived only 12, 44, and 60 hours after this operation died from hemorrhage, shock, or uremia, Figs. 4, 5, and 1, respectively.

*Demonstration of Collateral Circulation between the Spleens and Ischemic Kidneys That Were Joined by Pexis.*—After intervals of from 2 to 10 months following spleno-reno-pexy, the fused organs were removed. A suspension of India ink was injected into the splenic artery of six of these excised preparations. In all instances the spleen became dark during the injection and occasionally the ink flowed from the renal veins. The joined organs were then sliced perpendicular to the plane of fusion. From 9 to 15 cut surfaces of each pexis were examined histologically. Five of the six preparations showed ink in the kidney, in the gross and microscopically. The other showed ink in about two-thirds of the spleen but none was present near the pexis or in the kidney. This was probably due to the fact that the artery that was injected did not supply the entire spleen with blood.

With respect to the collateral circulation the most significant points were found in the histological preparations. In the kidney, the ink particles were present in the capillaries about the renal tubules of the cortex and medulla as well as in the smaller and larger renal veins. No ink was found in the arteries, arterioles, or glomeruli, of four of the five preparations. In the exceptional case, dog 6 (Fig. 6), ink was found in the arterial and glomerular circulation in one small region adjacent to the scar of the pexis. Serial sections through this locus showed that a small splenic artery coursed through the scar and anastomosed with renal arteries, arterioles, and finally glomerular capillaries. This picture was seen in only one of the 15 blocks studied in this kidney. Elsewhere ink was seen in the capillaries about the renal tubules, just like the distribution in the four other spleen-kidney preparations.

The spleens injected with ink showed the black granules in their arteries, sinusoids, pulp, and veins. Many of the dilated endothelial lined channels extending into the scar between the kidney and spleen were rich in ink. A somewhat similar distribution of collateral circulation has been observed following omento-reno-pexy with normal kidneys (22).

From these studies it appears that the circulation from the spleen to the fused ischemic kidney goes through the splenic sinusoids and the sinusoids and capillaries of the scar between the fused organs. From these vessels there are communications with the capillaries about the renal tubules of the cortex and of the medulla, and from these to the renal veins.

#### DISCUSSION

Spleno-reno-pxy lowered the systolic blood pressure in each of nine dogs rendered hypertensive by bilateral renal ischemia. In a previous experiment it was found that omento-reno-pxy produced a temporary fall in the blood pressure of hypertensive dogs. The present observations show that spleno-reno-pxy produced persistent decreases in systolic blood pressure of hypertensive dogs. Cerqua and Samaan (3) have recently reported that spleno-reno-pxy in unilaterally nephrectomized dogs with hypertension due to constriction of the remaining renal artery lowers the blood pressure. The duration of the lowered blood pressure is not indicated in the data of their experiments. The difference in the duration of blood pressure response to pexis of the ischemic kidney with spleen or omentum may be due to quantitative differences in collateral circulation or to some other factors, possibly humoral.

Removal of the spleno-reno-pxy by excision caused a return of the previous hypertension in three dogs that survived the operation. These combined data indicate that the splenic pexis with one ischemic kidney neutralizes the effects of arterial constriction not only in that kidney but also in the other ischemic kidney. Cerqua and Samaan found that separation of the splenic-renal pexis in two unilaterally nephrectomized dogs with lowered blood pressure was followed by a return of the original hypertension. Whether this neutralization of pressor action by the collateral circulation between spleen and kidney, is due to the prevention of formation of pressor material or its more efficient destruction or elimination, has not been ascertained.

The spleno-reno-pxy produces a collateral circulation between the splenic sinusoids and the capillaries about the renal tubules. Ordinarily no collateral circulation from the spleen to the glomeruli of the kidneys can be demonstrated. These observations suggest that in dogs with renal ischemia, the lowering of the blood pressure by means of collateral circulation may be due to neutralization of pressor material or the inhibition of its formation or to both processes in the tubules of the kidney. In other words, they indicate that if pressor substances are formed in the kidney due to ischemia they are probably formed in the renal tubules.

In conclusion it can be stated that:

1. In hypertensive dogs with bilateral renal ischemia, unilateral spleno-reno-pexy lowers the systolic blood pressure for as long as  $9\frac{1}{2}$  months.
2. Following removal of the fused spleen and kidney the decreased blood pressure of the dogs with renal ischemia returns to the hypertensive level.
3. The spleno-reno-pexy produces a collateral circulation between the splenic sinusoids and the capillaries about the renal tubules. The glomeruli are not usually involved in this collateral circulation.

#### BIBLIOGRAPHY

1. Alpert, L. K., Alving, A. S., and Grimson, K. S., *Proc. Soc. Exp. Biol. and Med.*, 1937, **37**, 1.
2. Blalock, A., and Levy, S. E., *Ann. Surg.*, 1937, **106**, 826.
3. Cerqua, S., and Samaan, A., *Clin. Sc. Inc. Heart*, 1939, **4**, 113.
4. Child, C. G., *J. Exp. Med.*, 1938, **67**, 521.
5. Child, C. G., and Glenn, F., *Arch. Surg.*, 1938, **36**, 376.
6. Collins, D. A., *Am. J. Physiol.*, 1936, **116**, 616.
7. Collins, D. A., and Wood, E. H., *Am. J. Physiol.*, 1938, **123**, 224.
8. Elaut, C. R., *Compt. rend. Soc. biol.*, 1936, **123**, 1244.
9. Enger, R., Lindner, F., and Sarre, H., *Z. ges. exp. Med.*, 1938, **104**, 10.
10. Glenn, F., Child, C. G., and Page, I., *Am. J. Physiol.*, 1938, **122**, 506.
11. Glenn, F., and Lasher, E. P., *Proc. Soc. Exp. Biol. and Med.*, 1938, **38**, 58.
12. Goldblatt, H., Lynch, J., Hanzal, R. F., and Summerville, W. W., *J. Exp. Med.*, 1934, **59**, 347.
13. Goldblatt, H., Gross, J., and Hanzal, R. F., *J. Exp. Med.*, 1937, **65**, 233.
14. Goldblatt, H., and Wortman, W. B., *J. Exp. Med.*, 1937, **66**, 527.
15. Goldblatt, H., *Ann. Int. Med.*, 1937, **11**, 69.
16. Goldblatt, H., *Harvey Lectures*, 1937-38, **33**, 237.
17. Goldblatt, H., Kahn, J. R., Bayliss, F., and Simon, M. A., *J. Exp. Med.*, 1940, **71**, 175.
18. Hartwich, A., *Z. ges. exp. Med.*, 1930, **69**, 462.
19. Heymans, C., Bouckaert, J. J., Elaut, L., Bayliss, F., and Samaan, A., *Compt. rend. Soc. biol.*, 1937, **126**, 434.
20. Levy, S. E., Light, R. A., and Blalock, A., *Am. J. Physiol.*, 1938, **122**, 38.
21. Levy, S. E., and Blalock, A., *Surgery*, 1938, **3**, 899.
22. MacNider, W. deB., and Donnelly, G. L., *Proc. Soc. Exp. Biol. and Med.*, 1939, **40**, 271.
23. Mansfield, J. S., Weeks, D. M., Steiner, A., and Victor, J., *Proc. Soc. Exp. Biol. and Med.*, 1939, **40**, 708.
24. Mason, M. F., Evers, R., and Blalock, A., *Proc. Soc. Exp. Biol. and Med.*, 1937, **36**, 819.
25. Page, I. H., *Am. J. Physiol.*, 1935, **112**, 166.
26. Page, I. H., and Sweet, J. E., *Am. J. Physiol.*, 1937, **120**, 238.
27. Page, I. H., *Am. J. Physiol.*, 1938, **122**, 352.

28. Rogoff, J. M., Nixon, E. N., and Stewart, G. N., *Proc. Soc. Exp. Biol. and Med.*, 1939, **41**, 57.
29. Samaan, A., *J. Egypt. Med. Assn.*, 1939, **22**, 141.
30. Van Leersum, E. C., *Arch. ges. Physiol.*, 1911, **142**, 377.
31. Verney, E. B., and Vogt, M., *Quart. J. Exp. Physiol.*, 1938, **28**, 253.
32. Wilson, C., and Pickering, G. W., *Clin. Sc. Inc. Heart*, 1938, **3**, 343.
33. Wood, J. E., Jr., and Cash, J. R., *J. Clin. Inv.*, 1936, **15**, 543.