

Immunohistochemical analysis and correlation of cyclooxygenase-2 expression status with clinicopathological parameters in head and neck squamous cell carcinomas: An Indian perspective

Prerna Chadha, Richa Ranjan, Nikhilesh Kumar, Rig Vardhan, Prashant Sengupta, Rakhi Negi

Department of Laboratory Medicine, Command Hospital (Central Command), Lucknow, Uttar Pradesh, India

Abstract

Context: Head and neck squamous cell carcinoma (HNSCC) poses a major health problem and despite the advancements in its diagnosis and management the overall survival has not improved significantly. A search for newer diagnostic and prognostic markers along with fresh molecular targets is required for its prevention and cure.

Aims: The study aims to study the expression of cyclooxygenase-2 (COX-2) in HNSCCs and investigate its correlation with the clinicopathological profile of these cases. This study was performed to determine the significance of COX-2 expression in the Indian context.

Settings and Design: This study incorporated 90 cases of HNSCCs; both prospectively and retrospectively in a tertiary care center.

Materials and Methods: Expression of COX-2 on immunohistochemistry (IHC) was evaluated in correlation with the histological grade, maximum tumor size, tumor depth, nodal status and lymphovascular/perineural invasion (lvi/pni). The study received a waiver from the institutional ethics committee.

Statistical Analysis Used: Statistical analysis of the data was done using SPSS software.

Results: COX-2 expression was found in 97.8% of the cases. A statistically significant correlation of COX-2 immunopositivity was found with the histological grade, clinical staging (tumor size and nodal status), maximum tumor depth and lvi/pni in our study ($P < 0.05$).

Conclusions: COX-2 is expressed by most of the cases in this study. Its expression is related to tumor growth, differentiation and aggressiveness and therefore can be used as a good independent prognostic marker in HNSCCs. There is also possible scope of using it for targeted therapy in HNSCCs.

Keywords: Cyclooxygenase-2, head and neck squamous cell carcinoma, immunohistochemistry

Address for correspondence: Dr. Prerna Chadha, Department of Laboratory Sciences, Rajiv Gandhi Cancer Institute and Research Centre, Sector 5, Rohini, New Delhi - 110 085, India.

E-mail: chadha.prerna@gmail.com

Submitted: 01-Apr-2020, **Revised:** 28-Sep-2020, **Accepted:** 05-Oct-2020, **Published:** 09-Jan-2021

Access this article online

Quick Response Code:



Website:

www.jomfp.in

DOI:

10.4103/jomfp.JOMFP_128_20

This is an open access journal, and articles are distributed under the terms of the Creative Commons Attribution-NonCommercial-ShareAlike 4.0 License, which allows others to remix, tweak, and build upon the work non-commercially, as long as appropriate credit is given and the new creations are licensed under the identical terms.

For reprints contact: WKHLRPMedknow_reprints@wolterskluwer.com

How to cite this article: Chadha P, Ranjan R, Kumar N, Vardhan R, Sengupta P, Negi R. Immunohistochemical analysis and correlation of cyclooxygenase-2 expression status with clinicopathological parameters in head and neck squamous cell carcinomas: An Indian perspective. J Oral Maxillofac Pathol 2020;24:583-4.

INTRODUCTION

Head and neck squamous cell carcinoma (HNSCC) is the sixth most common neoplasm worldwide and poses a major health problem. India contributes its fair share to the worldwide disease burden and accounts for about 30% of all new cases annually.^[1]

Despite the advancements in the diagnosis and management of patients with HNSCCs, the overall survival has not improved significantly.^[2] Moreover, second primary cancers are very common in these patients.^[3] In view of these observations, a search for newer diagnostic and prognostic markers along with fresh molecular targets is required for the prevention and cure of HNSCCs and related tumors.

Cyclooxygenases (COXs) are enzymes which catalyze the synthesis of prostaglandins (PGs) from arachidonic acid. PGs are well known to be associated with cell proliferation and angiogenesis, thus playing a pivotal role in carcinogenesis.^[4,5] Overexpression of COX-2 has been documented in various cancers, such as those of the colon, stomach, lung, esophagus and oral cancers. However, there is ambiguity regarding the COX-2 expression in HNSCCs and its correlation with tumor size, grade, tumor depth, nodal status, distant metastasis and lymphovascular/perineural invasion (lvi/pni).^[6-10]

This study aims to assess the immunohistochemical expression of COX-2 in HNSCCs and investigate its correlation and significance with the clinicopathological profile of these cases in an Indian context. The importance of studying COX-2 expression status lies in the fact that targeted therapy against this protein is available and has great potential.

MATERIALS AND METHODS

This study incorporated 90 cases of HNSCCs, both prospectively and retrospectively presenting to the oncology department of this institute between December 2012 and May 2015. The cases were retrieved from the departmental archives. Hematoxylin and eosin (H and E) staining and immunohistochemistry (IHC) was performed for COX-2 on relevant sections as per the standard protocol. Negative and positive control slides were included in each IHC run (as recommended by the manufacturers). Relevant clinical data in the form of case sheets, laboratory and radiological investigations were collected and noted.

Small biopsy specimens, cases with recurrent HNSCC postchemo/radiotherapy, cases other than squamous cell carcinoma and cancers of the thyroid and salivary glands were excluded from the study.

Immunohistochemistry staining procedure

IHC was performed on 4 μ m formalin-fixed paraffin-embedded sections. The COX-2 (clone SP21) rabbit monoclonal antibody; ready to use kit (thermo scientific) was used on sections fixed on poly L lysine coated slides. Heat-induced antigen retrieval was performed for 1 h followed by endogenous peroxidase blocking. After which primary antibody (COX-2 clone SP21) and visualization reagent (labeled horse radish peroxidase secondary antibody) were added. In the end, substrate chromogen solution diaminobenzidine (DAB) was used. Sections were then counterstained and mounted.

ASSESSMENT OF IHC RESULTS

The assessment of IHC results was done on the basis of percentage of tumor cells showing membrane/cytoplasmic staining and intensity of staining as described in Table 1.

For the purpose of our study, cytoplasmic staining with a score 2+, 3+ and 4+ were taken as overexpression while 1+ was taken as underexpression. A score of 0 was taken as negative expression. This was done as per guidelines described by Abrahao *et al.*^[11]

Statistical analysis

The statistical analysis was done using Company name SPSS Inc., Chicago, Illinois, U.S.A statistical analysis software. The values were represented in number (%) and mean \pm standard deviation. Student's *t*-test was used to test the significance of two means. Analysis of variance test was used to compare the within group and between group variances amongst the study groups. The level of significance “*P*” value was considered statistically significant if <0.05 .

Ethical approval

The study received a waiver from the institutional ethics committee.

Table 1: Interpretation and scoring of cyclooxygenase-2 immunohistochemical staining

Score	Surgical specimen - Staining pattern	COX2 expression assessment
0	Weak staining in 0%- 10% of tumor cells	Negative
1+	Weak to moderate staining in 10%- 25% of tumor cells	Equivocal
2+	Moderate to strong staining in 25%- 50% of tumor cells	Positive
3+	Strong staining in 50%- 75% of tumor cells	Positive
4+	Strong staining in 75%- 100% of tumor cells	Positive

COX-2: Cyclooxygenase-2

RESULTS

Clinicopathological data

The study sample comprised of 90 cases of HNSCCs which included 72 males (80%) and 18 females (20%). Most of the cases were well differentiated histopathologically ($n = 52$; 57.8%) [Figure 1a] while 37 cases (41.1%) were moderately differentiated [Figure 1b]. Only one case (1.1%) was poorly differentiated [Figure 1c]. Maximum number of cases in this study presented with a clinical stage of T2 ($n = 45$; 50.0%) and most of the patients did not show nodal involvement at presentation ($n = 67$; 74.4%). In our study, the depth of tumor ranged from 0.1 cm to 3.5 cm. 48.9% of the patients ($n = 44$) had a tumor depth between 0.5 and 1 cm.

EVALUATION OF IHC RESULTS

COX-2 expression score was 1+ in 19 (21.1%) [Figure 2b] of the cases, 2+ in 57 (63.3%) [Figure 3a], 3+ in 5 (5.6%) [Figure 3b] and 4+ in 7 (7.8%) [Figure 3c] cases respectively. No expression was observed in 2 (2.2%) [Figure 2a] of the cases. For the purpose of our present study, score of 2+, 3+ and 4+ were taken as indicators of overexpression. Hence, 76.7% ($n = 69$) of the cases showed COX-2 overexpression.

Association between cyclooxygenase-2 expression and clinicopathological parameters

COX-2 expression showed a significant association with the histopathological grade of the tumor, clinical staging, maximum tumor depth, nodal status and lvi/pni ($P < 0.05$). No significant association was found with distant metastasis at presentation ($P = 0.939$) [Table 2].

DISCUSSION

COX, officially known as PG-endoperoxide synthase, is an enzyme that is responsible for the formation of PGs from arachidonic acid. The PGs are autocoid mediators that

affect virtually all known physiological and pathological processes via their reversible interaction with G-protein coupled membrane receptors. There are two isoforms of COX, namely, *COX-1* and *COX-2* which are almost identical in their structure, but for the substitution of isoleucine at position 523 in *COX-1* with valine in *COX-2*.^[12]

Earlier studies showed that while both enzymes carry out essentially the same catalytic reaction and have similar primary protein structures^[5] many of the inflammatory or inducible effects of *COX* appear to be mediated by *COX-2*, while many of the “housekeeping” effects of *COX* appear to be mediated by *COX-1*. Later studies revealed that the *COX-1* and *COX-2* proteins are derived from distinct genes. *COX-2* gene can be induced by hormones, growth factors, phorbol esters, cyclic adenosine monophosphate, inflammatory factors and cytokines.^[13]

Enhanced synthesis of PGs, due to the upregulation of *COX-2*, increases the proliferative activity of neoplastic cells, cancer invasiveness and metastasis.^[14] Despite extensive studies, there is limited data available on *COX-2* expression in HNSCC and its relation with different clinicopathological parameters in the Indian context. The *COX-2* initiated signaling pathways can control cell proliferation and accumulating evidence shows that *COX-2* is widely overexpressed in HNSCC.^[3,4,15]

Demographic profile

In our study, performed on 90 cases of HNSCCs, 51.1% of the patients were aged above 60 years. The mean age of the patients was 61.33 ± 10.38 years. The majority of the patients were males ($n = 72/90$; 80%) and there were 18 (20%) females. The ratio of males to females was 4:1. A bias may be present in the study as it was conducted in an armed forces hospital where there is a male preponderance. The majority of the patients hailed from a rural background in this study (71.1%).

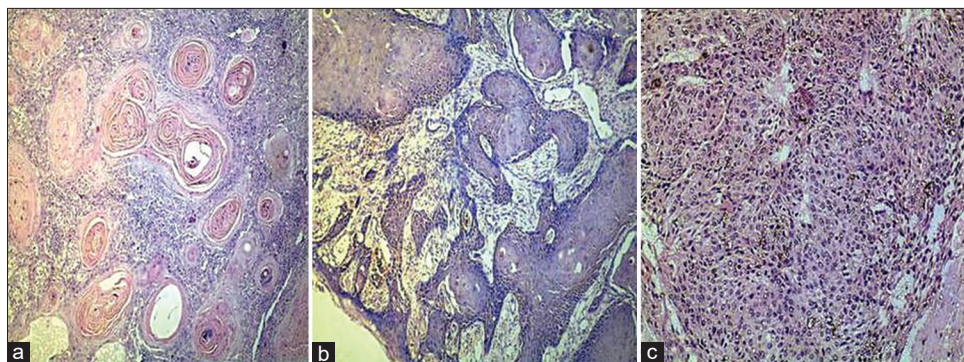


Figure 1: H and E stain ($\times 200$). (a) Well differentiated squamous cell carcinoma. (b) Moderately differentiated squamous cell carcinoma. (c) Poorly differentiated squamous cell carcinoma

As opined by various authors, head and neck cancer is known to occur primarily in older adults, with most patients being more than the age of 45 years.^[16] Although recent studies have demonstrated a steady rise in the incidence of HNSCCs in younger adults (18–45 years) due to human papillomavirus (HPV) related etiology,^[17] such a trend was not seen in our study. This possibly indicates that HNSCC in India has predominantly a non HPV related, tobacco and alcohol-associated etiology.

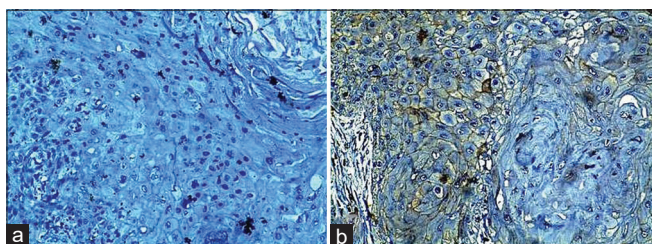


Figure 2: Cyclooxygenase-2 expression on immunohistochemistry (x200). a: 0, b: 1+

The disease shows a male preponderance in almost all countries, with rates two to four times higher among males than females.^[8] This was in concordance with our findings and may be suggestive of a lower incidence of tobacco and alcohol consumption by females in India.

As opposed to our results, most of the studies available in literature show a higher prevalence of HNSCCs in urban as compared to rural areas.^[18] The possible reason for this variation in our results might be because, in an Indian scenario, the practices of betel quid chewing, consumption of “khaini” or supari, smoking or alcohol consumption, which are well recognized risk factors for HNSCCs, are more common in the rural population.

In this study, most of the HNSCCs (57.8%) were well-differentiated histopathologically ($n = 52$), while 41.1% were moderately differentiated ($n = 37$). Only 1.1% ($n = 1$) of the cases was poorly differentiated. This is in keeping

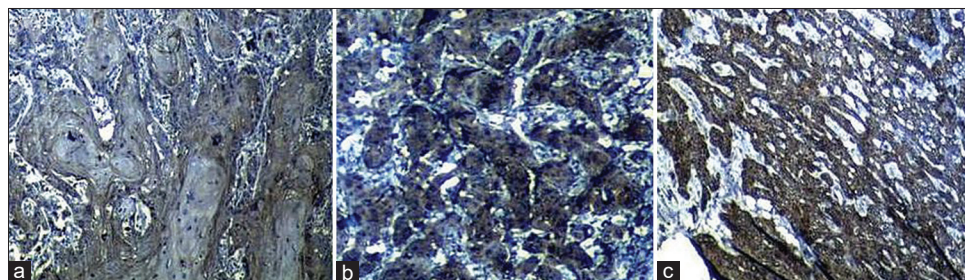


Figure 3: Cyclooxygenase-2 expression on immunohistochemistry (x200) a: 2+, b: 3+, c: 4+

Table 2: Association of cyclooxygenase-2 expression with clinicopathological and tumor, node, metastasis staging parameters

Characteristic	Number of cases	Mean expression	SD	Statistical significance, P
Grade				
Well differentiated	52	1.73	0.77	0.002
Moderately differentiated	37	2.30	0.78	
Poorly differentiated	1	1.00	0.00	
Tumor size/clinical stage (T)				0.001
T ₁	21	1.71	0.46	
T ₂	46	1.91	0.79	
T ₃	11	1.64	0.81	
Nodal status (N)				0.024
N ₀	67	1.84	0.665	
N ₁	15	2.47	0.83	
	N ₂	8	2.00	1.51
Distant metastasis (M)				0.939
M ₀	88	1.95	0.83	
	M ₁	2	2.00	0.00
Tumor depth (maximum) (cm)				0.019
≤0.5	7	1.57	0.54	
0.5-1	44	2.05	0.81	
1- 1.5	17	1.65	0.86	
1.5- 2	12	1.75	0.62	
>2	10	2.60	0.84	
Lvi/Pni				0.005
None	71	1.85	0.71	
Lymphovascular	17	2.24	1.03	
Lympho + perineural	2	3.50	0.71	

Lvi: Lymphovascular invasion, Pni: Perineural invasion, SD: Standard deviation

with other studies mentioned in literature, wherein the most commonly found histological grade was well differentiated although extensive search in indexed journals did not yield any comment on the prevalence of carcinoma based on differentiation.^[7,8,11]

Pattern of immunostaining

The staining intensity and extent was mainly localized or was seen to be stronger in the peripheries of tumor islands. This observation is in accordance with other studies. The justification for such a pattern lies in the fact that the staining reaction varies with cellular differentiation and therefore reiterates the presence of these receptors in undifferentiated cells.^[6,19]

Immunoreactivity for COX-2 was patchy and also seen in stromal cells including macrophages and neutrophils. These findings might be suggestive of an interaction between the stromal cells and tumor cells thus affecting COX-2 expression.

Prevalence of cyclooxygenase-2 expression

Our observed prevalence of COX-2 protein positivity by immunohistochemistry was 97.8% ($n = 88$). Negative expression was seen in 2.2% ($n = 2$) cases. These results are in close proximation to those obtained by Goto *et al.*,^[9] who demonstrated 97.3% immunostaining in HNSCCs and Søland *et al.*^[20] who showed 98% COX-2 staining in oral squamous cell carcinomas (OSCCs). Overexpression was observed in 76.7% of the cases. These results are similar to those observed by other researchers.^[21]

Correlation of histological grade/degree of differentiation with cyclooxygenase-2 expression

In this study, positive expression was found to be higher in moderately differentiated tumors while negative expression was more commonly seen in well-differentiated tumors. This is in agreement with the results reported by other investigators.^[6,9] This finding suggests that, with decreasing differentiation of tumor, COX-2 immunostaining intensity increases ($P = 0.001$; highly significant).

Assuming that moderately and poorly differentiated tumors behave more aggressively, intensity of COX-2 expression may correlate well with the aggressiveness of disease. However, not all studies agree on this, and there lies some ambiguity in the matter. Shigeto Itoh *et al.* could not find any correlation of COX-2 status with the histological grade of tumors in HNSCCs.^[7]

Correlation of tumor size and maximum tumor depth with cyclooxygenase-2 expression

Significant correlation was found between COX-2 overexpression and tumor size in our study. T₃ and T₄

tumors were associated with a higher percentage of COX-2 overexpressed cases as compared to T₁ and T₂ tumors. These results are in concordance with earlier studies.^[22]

The mean expression of COX-2 was seen to increase significantly with increasing tumor depth ($P = 0.019$). These results are in concurrence with those obtained by Woś *et al.*^[23]

This finding is another indication of the high prognostic value of COX-2 in HNSCCs, as tumor depth is a well-identified prognostic indicator in HNSCCs.

In our study, nodal metastasis was present in only 23 cases. Out of these, COX-2 positivity was present in 22 cases, while negative expression was noted only in a single case. COX-2 overexpression was found in 18 cases. Significant association was found between nodal metastasis and COX-2 overexpression ($P = 0.024$). Other Indian studies have also given similar results.^[6]

Correlation of lymphovascular/perineural invasion with cyclooxygenase-2 expression

In our study, 78.9% of the patients ($n = 71$) did not show either lvi/pni. A total of 17 patients (18.9%) showed only lvi, while 2 (2.2%) showed both lvi and pni. Perineural invasion alone was not seen in any of the cases in our study. We found a significant association between lvi/pni and COX-2 overexpression ($P = 0.005$). Though studies pertaining to the prognostic implication of lvi/pni in HNSCCs are present,^[24,25] there's a paucity of literature studying the correlation between COX-2 and lvi/pni. Our study attempts to shed some light upon this unexplored area. These results might indicate that, the role of COX-2 in tumor metastasis is through lvi spread. Another possibility that exists is that tumors having overexpression of COX-2, which were also found to be of a higher grade, had an earlier involvement of vessels or nerves.

Only 2 (2.2%) patients in this study had distant metastasis at the time of presentation. No significant association was found between COX-2 positivity and distant metastasis. This is in opposition to the scant research available in indexed literature, which attaches a significant association of COX-2 with metastasis.^[10] The probable reason for such a discord in our study might be the lack of surgical intervention in cases of HNSCCs presenting with distant metastasis to our institution. As our study includes only resected specimens of HNSCCs, these results can thus be explained.

CONCLUSIONS

This study supports the view that COX-2 expression is related to tumor growth, differentiation and aggressiveness

and there is a possible scope of using this for targeted therapy in HNSCCs. It also identifies COX-2 as a good independent prognostic marker in HNSCCs in the Indian context.

Acknowledgement

The authors would like to thank the technical staff of the laboratory department for their skillful assistance.

Financial support and sponsorship

Nil.

Conflicts of interest

There are no conflicts of interest.

REFERENCES

- More Y, D'Cruz AK. Oral cancer: Review of current management strategies. *Natl Med J India* 2013;26:152-8.
- Saba NF, Choi M, Muller S, Hyung Ju C, Tighiouart M, Shin DM. Chemoprevention of head and neck cancer by simultaneous blocking of epidermal growth factor receptor and cyclooxygenase signaling pathways: Preclinical and clinical studies. *Clin Cancer Res* 2013;19:15:1244-56.
- Day GL, Blot WJ. Second primary tumors in patients with oral cancer. *Br J Cancer* 1992;70:14-9.
- Sheng H, Shao J, Morrow JD, Beauchamp RD, DuBois RN. Modulation of apoptosis and Bcl-2 expression by prostaglandin E2 in human colon cancer cells. *Cancer Res* 1998;58:362-6.
- Tsuji M, Kawano S, Tsuji S, Sawaoka H, Hori M, DuBois RN. Cyclooxygenase regulates angiogenesis induced by colon cancer cells. *Cell* 1998;93:705-16.
- Mohammad S, Ram H, Gupta PN, Husain N, Bhatt ML. Overexpression of COX-2 in oral squamous cell carcinoma patients undergoing chemoradiotherapy. *Natl J Maxillofac Surg* 2011;2:17-21.
- Itoh S, Matsui K, Furuta I, Takano Y. Immunohistochemical study on overexpression of cyclooxygenase-2 in squamous cell carcinoma of the oral cavity: Its importance as a prognostic predictor. *Oral Oncol* 2003;9:829-35.
- Yeole BB. Trends in incidence of head and neck cancers in India. *Asian Pac J Cancer Prev* 2007;8:607-12.
- Goto R, Hoshikawa H, Fujii T, Indo K, Yoshino K, Imaida K, et al. Clinicopathological significance of cyclooxygenase-2 expression in hypopharyngeal squamous cell carcinoma. *Oncol Rep* 2008;19:645-50.
- Cao J, Guo T, Dong Q, Zhang J, Li Y. miR-26b is downregulated in human tongue squamous cell carcinoma and regulates cell proliferation and metastasis through a COX-2-dependent mechanism. *Oncol Rep* 2015;33:974-80.
- Abrahao AC, Castilho RM, Squarize CH, Molinolo AA, dos Santos-Pinto D Jr, Gutkind JS. A role for COX2-derived PGE2 and PGE2-receptor subtypes in head and neck squamous carcinoma cell proliferation. *Oral Oncol* 2010;46:880-7.
- Kumar V, Cotran RS, Robbins SL. Neoplasia. In: Kumar V, Abbas AK, Aster JC, editors. *Robbins and Cotran Pathologic Basis of Disease: South Asia Edition. Vol. 1., 9th ed.* New Delhi: Reed Elsevier India Pvt Lmtd; 2014. p. 265-340.
- Reed DW, Bradshaw WS, Xie W, Simmons DL. *In vivo* and *in vitro* expression of a non-mammalian cyclooxygenase-1. *Prostaglandins* 1996;52:269-84.
- Tsuji M, DuBois RN. Alterations in cellular adhesion and apoptosis in epithelial cells overexpressing prostaglandin endoperoxide synthase 2. *Cell* 1995;83:493-501.
- Kelley DJ, Mestre JR, Subbaramaiah K, Sacks PG, Schantz SP, Tanabe T, et al. Benzo[a] pyrene up-regulates cyclooxygenase-2 gene expression in oral epithelial cells. *Carcinogenesis* 1997;18:795-9.
- Shenoi R, Devrukkar V, Chaudhuri., Sharma BK, Sapre SB, Chikhale A. Demographic and clinical profile of oral squamous cell carcinoma patients: A retrospective study. *Indian J Cancer* 2012;49:21-6.
- Chaturvedi AK, Engels EA, Anderson WF, Gillison ML. Incidence trends for human papillomavirus-related and -unrelated oral squamous cell carcinomas in the United States. *J Clin Oncol* 2008;26:612-9.
- Lynch TJ, Bell DW, Sordella R, Gurubhagavata S, Okimoto RA, Brannigan BW, et al. Activating mutations in the epidermal growth factor receptor underlying responsiveness of non-small-cell lung cancer to gefitinib. *N Engl J Med* 2004;350:2129-39.
- Sarkis SA, Abdullah BH, Abdul Majeed BA, Talabani NG. Immunohistochemical expression of epidermal growth factor receptor (EGFR) in oral squamous cell carcinoma in relation to proliferation, apoptosis, angiogenesis and lymphangiogenesis. *Head Neck Oncol* 2010;2:13.
- Soland TM, Husvik C, Koppang HS, Boysen M, Sandvik L, Clausen OP, et al. A study of phosphorylated ERK1/2 and COX-2 in early stage (T1-T2) oral squamous cell carcinomas. *J Oral Pathol Med* 2008;37:535-42.
- Chan G, OBoyle J. Cyclooxygenase-2 expression is upregulated in Squamous Cell Carcinoma of the Head and Neck. *Cancer Res* 1999;59:991-94.
- Sakurai K, Urade M, Noguchi K, Hashitani S, Takaoka K, Segawa E, et al. Prognostic significance of cyclooxygenase-2 and DNA topoisomerase IIalpha expression in oral carcinoma. *Head Neck* 2007;29:1002-9.
- Woś J, Bryś M, Lewy-Trenda I, Stasikowska O, Papież P, Papierz W, et al. Analysis of HIF-1α and COX-2 expression in tumor stroma and correlation with the degree of neoplasm invasiveness in laryngeal cancer-preliminary study. *Otolaryngol Pol* 2011;65:102-8.
- Lin YT, Chien CY, Lu CT, Lou SD, Lu H, Huang CC, et al. Triple-positive pathologic findings in oral cavity cancer are related to a dismal prognosis. *Laryngoscope* 2015;125:E300-5.
- Yeh CF, Li WY, Yang MH, Chu PY, Lu YT, Wang YF, et al. Neck observation is appropriate in T1-2, cN0 oral squamous cell carcinoma without perineural invasion or lymphovascular invasion. *Oral Oncol* 2014;50:857-62.