



Contents lists available at ScienceDirect

## Journal of Hand Surgery Global Online

journal homepage: [www.JHSGO.org](http://www.JHSGO.org)

Original Research

## The Index Finger Metacarpal Tubercle

Ronald D. Brown, MD, <sup>\*</sup> Paige L. Myers, MD, <sup>†</sup> Hannah M. Smith, MD, <sup>\*</sup>  
Joseph S. Khouri, MD, <sup>‡</sup> Jeffrey A. Fink, MD <sup>§</sup>

<sup>\*</sup> Division of Plastic Surgery, University of Rochester Medical Center, Rochester, NY

<sup>†</sup> Division of Plastic Surgery, Memorial Sloan Kettering Cancer Center, New York, NY

<sup>‡</sup> Department of Plastic Surgery, Case Western University School of Medicine, Cleveland, OH

<sup>§</sup> Plastic Surgery Group of Rochester, Rochester, NY



## ARTICLE INFO

## Article history:

Received for publication November 12, 2019

Accepted in revised form March 2, 2020

Available online April 15, 2020

## Key words:

Index finger

Index finger pain

Metacarpal tubercle

Radial collateral ligament

**Purpose:** The region of the index finger metacarpophalangeal joint is a common source of hand pain with variable, well-known etiologies. We have identified the tubercle at the dorsoradial neck of the index finger metacarpal as a distinct and specific site of pain in a subset of patients who presented with a chief report of index finger pain. Although experienced hand surgeons may recognize this clinical entity, we found no previous description within the literature.

**Methods:** After institutional review board approval, we performed a retrospective review of all patients presenting to a single surgeon practice with severe pain at the dorsoradial tubercle of the index finger metacarpal unattributable to known etiologies. Patients underwent initial management of steroid injection followed by surgical excision if conservative measures failed.

**Results:** Steroid injection was administered as initial management in 9 of 10 afflicted hands. Five of these hands experienced complete resolution of pain at 4 weeks after injection whereas 4 developed recurrence at an average of 3 months after injection. Among patients with recurrence, one patient opted for a second injection that led to pain resolution 4 weeks later, whereas the remaining 3 hands had surgical excision. All patients who underwent surgical excision reported minimal discomfort and marked improvement in pain after surgery.

**Conclusions:** We identified the tubercle at the dorsoradial neck of the index finger metacarpal as a distinct and specific site of pain in a subset of patients. We postulate that the pathophysiology of pain at the prominent index finger metacarpal tubercle may be related to a subacute radial collateral ligament injury. Steroid injection to the tubercle is a reasonable initial treatment option and satisfactory results may also be obtained with surgical excision.

**Type of study/level of evidence:** Therapeutic IV.

Published by Elsevier Inc. on behalf of The American Society for Surgery of the Hand.  
This is an open access article under the CC BY-NC-ND license (<http://creativecommons.org/licenses/by-nc-nd/4.0/>).

The region of the index finger metacarpophalangeal (MCP) joint is a common source of hand pain with variable etiology. Known causes of pain at this site include stenosing tenosynovitis, ganglion, osteoarthritis, fracture, dislocation, ligament injury, infection, and inflammatory arthropathy. We identified the tubercle at the dorsoradial neck of the index finger metacarpal as a distinct and

specific site of pain in a subset of patients who presented with a chief report of index finger pain. Although this clinical entity may be recognized by experienced hand surgeons, we found no previous description within the literature. This article reports our experience with the diagnosis and management of the index finger metacarpal tubercle as a treatable source of index finger pain in 9 consecutive patients.

**Declaration of interests:** No benefits in any form have been received or will be received by the authors related directly or indirectly to the subject of this article.

**Corresponding author:** Ronald D. Brown, MD, Division of Plastic Surgery, University of Rochester Medical Center, 601 Elmwood Ave., Box 661, Rochester, NY 14642.

E-mail address: [RonaldD.Brown@urmc.rochester.edu](mailto:RonaldD.Brown@urmc.rochester.edu) (R.D. Brown).

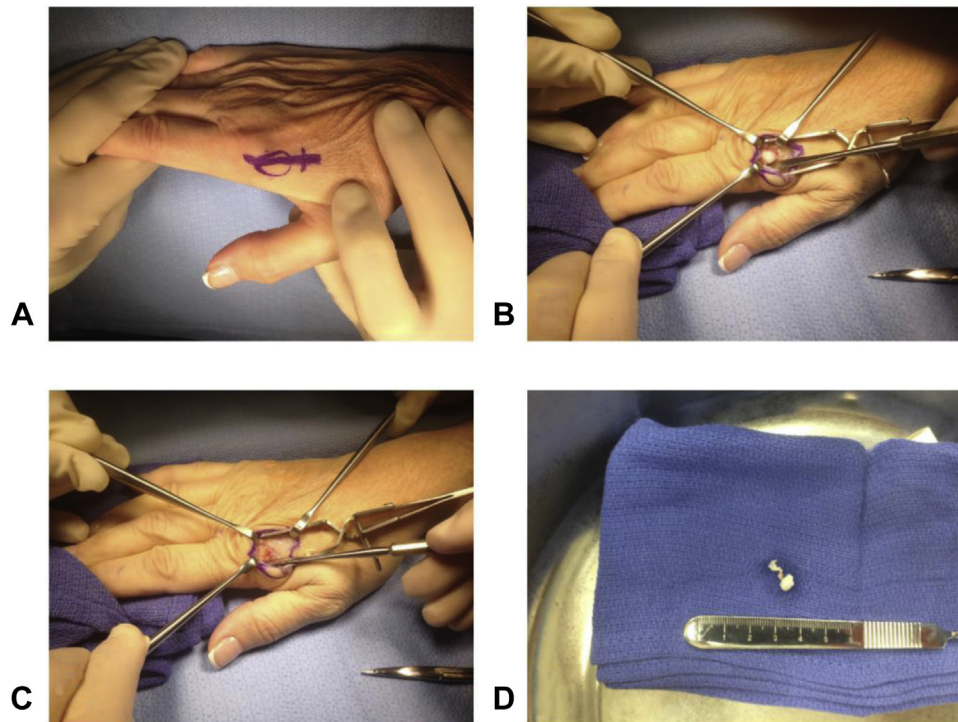
## Materials and Methods

After we obtained institutional review board approval, we retrospectively reviewed all patients presenting to a single hand surgeon's practice from January 1, 2013 to July 31, 2018. Patients

<https://doi.org/10.1016/j.jhsg.2020.03.001>

2589-5141/Published by Elsevier Inc. on behalf of The American Society for Surgery of the Hand.

This is an open access article under the CC BY-NC-ND license (<http://creativecommons.org/licenses/by-nc-nd/4.0/>).



**Figure 1.** Surgical excision of index finger metacarpal tubercle. **A** A 2- to 3-cm skin incision is made over the dorsoradial index finger metacarpal. **B** The index finger metacarpal tubercle is exposed and **C** excised with a rongeur. **D** The specimen is sent for pathologic evaluation.

identified with moderate to severe pain at the dorsoradial tubercle of the index finger metacarpal were included. Other etiologies of pain in this vicinity (eg, stenosing tenosynovitis, ganglion, osteoarthritis, fracture, acute ligament injury, dislocation, infection, and inflammatory arthropathy) were excluded based on history, clinical examination (presence of erythema or swelling, pain at the A1 pulley, tenderness to palpation of the dorsal MCP joint, or pain on axial load across the MCP joint), fluoroscopy, magnetic resonance imaging (MRI), and blood work when indicated. Age, gender, hand dominance, laterality of affected hand, clinical examination (presence of pain, tenderness, and/or radial collateral ligament [RCL] instability), fluoroscopic interpretation of the right index finger (according to the senior hand surgeon), radiologist MRI impression (if obtained), treatment, and length of follow-up were recorded.

Office films via fluoroscopy were obtained in all patients who presented without outside imaging. In addition to the posteroanterior and lateral hand images, we obtained a 45° to 60° pronated oblique view of the hand to best visualize the index finger dorsoradial metacarpal tubercle. All images were reviewed by the senior hand surgeon.

Patients were offered a steroid injection as initial management. Injections consisted of 1.5 mL of a 1:1 mixture of plain 1% lidocaine HCl, USP 10 mg/mL (Hospira, Inc, Lake Forest, IL) and betamethasone sodium phosphate and betamethasone acetate injectable suspension, USP 6 mg/mL (American Regent, Inc, Shirley, NY). This was administered as a single injection in a nonspecific fashion at the base of the palpable dorsoradial index finger metacarpal tubercle using a 5/8-in 25-gauge needle. All injections were administered by the senior hand surgeon.

Patients who failed steroid injection or did not respond to it were offered subsequent elective surgical excision of the tubercle. In lieu of steroid injection as initial management, any patient who presented with concomitant ipsilateral hand diagnoses warranting surgery (eg, basal joint arthritis) was offered surgical excision of the

painful tubercle in a combined procedure to address the additional diagnoses. All surgeries were performed by the senior hand surgeon in an ambulatory surgical center under general anesthesia. With each patient supine on the operating room table, a 2- to 3-cm axially oriented incision was made over the dorsoradial index finger from the base of the proximal phalanx to the dorsoradial tubercle and neck of the metacarpal (Fig. 1A). Dissection was carried sharply through skin and then bluntly through subcutaneous tissues using a spreading technique to preserve radial sensory nerve branches. The proximal 1 cm of radial sagittal band fibers was incised, and the extensor apparatus reflected. The superficial dorsal portion of radial collateral ligament was likewise reflected from the index finger metacarpal tubercle. The tubercle was further cleared of soft tissues sharply using a number 15 blade scalpel (Fig. 1B). Stability of the radial collateral ligament at the MCP joint was routinely confirmed to be intact at this point. Next, the index finger metacarpal tubercle was excised with a rongeur and the excision site smoothed with a rasp (Fig. 1C, 1D). The wound was irrigated with saline. The dorsal fibers of the radial collateral ligament of the MCP joint and periosteum were repaired over the site of the metacarpal tubercle excision using figure-of-8 sutures of 4-0 Vicryl (Ethicon, Inc, Cincinnati, OH). The proximal portion of radial sagittal band was similarly repaired. The wound was irrigated and the skin was closed with interrupted horizontal mattress sutures of 4-0 Prolene (Ethicon, Inc). After closure, it was standard procedure to inject 0.5% plain bupivacaine hydrochloride at the surgical site. Petroleum-based gauze, followed by a bulky, soft dressing with foam and metal finger orthosis and Coban wrap (3M Health Care, St Paul, MN) was used to immobilize the index and middle finger MCP joints in extension. This dressing was left in place until follow-up. Orthosis and suture removal were done at 10 to 14 days. All specimens were sent for pathologic evaluation.

Follow-up for all patients was maintained until resolution of pain, which we defined as treatment completion. Patients receiving

**Table 1**  
Demographics and Outcomes of Patients Presenting With Painful Index Finger Metacarpal Tubercle

Patient	Age, y	Gender	Hand Dominance/ Affected Hand(s)	Imaging Results	Treatment(s)	Length of Follow-Up, mo
1	70	F	R/R	Fluoroscopy: prominent tubercle	Injection (recurred); excision	18
2	49	F	R/R	Fluoroscopy: prominent tubercle MRI: age-indeterminate tear of proximal attachment of index finger RCL	Injection (recurred); excision	12
3	71	F	R/R	Fluoroscopy: prominent tubercle	Excision (with basal joint arthroplasty)	2
4	56	F	R/bilateral	Fluoroscopy: prominent tubercle	L: injection R: injection (recurred); excision	36
5	69	F	R/R	Fluoroscopy: prominent tubercle	Injection	1
6	57	F	R/L	Fluoroscopy: prominent tubercle	Injection (recurred); additional injection	3
7	60	M	R/L	Fluoroscopy: prominent tubercle	Injection	2
8	53	F	R/L	Fluoroscopy: prominent tubercle	Injection	2
9	64	F	R/R	Fluoroscopy: prominent tubercle	Injection	1

injection were seen again at 4 weeks to evaluate for resolution of pain or lack of response to injection. Those with a lack of response to injection or late recurrence were subsequently offered an additional steroid injection or an elective surgical excision. Follow-up for second injections was at 4 weeks, whereas that for patients who underwent surgical excision included orthosis and suture removal at 10 to 14 days, a postoperative visit at 6 weeks, and additional visits as needed afterward. Any patient with resolution of pain after either intervention was discharged with follow-up as necessary.

## Results

Nine patients with a total of 10 afflicted hands were identified to have tenderness at the index finger metacarpal tubercle. Mean follow-up was 8.5 months (range, 1–36 months). Table 1 lists patient demographics. Eight patients were female; all were right-handed and the dominant hand was affected in 6 patients. One patient presented with both hands asynchronously affected. On examination, all affected hands demonstrated focal tenderness to palpation at the index metacarpal tubercle. Seven patient hands experienced pain with RCL stress at 60° index finger MCP joint flexion. No patients exhibited MCP joint instability on RCL stress compared with the contralateral hand. All patients were nontender over the A1 pulley, exhibited no tenderness to palpation at the dorsal surface of the MCP joint, and had no pain on axial load across the MCP joint. Erythema and swelling were absent, and no history of trauma was noted.

Plain films obtained via fluoroscopy demonstrated a prominent index finger metacarpal tubercle in all patients. Fluoroscopic imaging was otherwise normal. Magnetic resonance imaging was obtained for one patient after injection and before surgical excision, which demonstrated an age-indeterminant tear of the proximal attachment of the index finger radial collateral ligament (Table 1).

Steroid injection was administered as initial management in 9 of 10 afflicted hands. Five of these hands experienced complete resolution of pain at 4 weeks after injection, whereas 4 developed recurrence at an average of 3 months from injection. Among patients with recurrence, one opted for a second injection that led to pain resolution 4 weeks later; the remaining 3 hands had surgical excision. Two patients electing subsequent surgical excision had a single procedure, as described earlier, whereas one patient chose to combine this procedure with ipsilateral carpal tunnel and thumb A1 pulley releases for chronic mild carpal tunnel and newly developed stenosing tenosynovitis of the thumb, respectively. Finally, one patient who presented with concomitant ipsilateral basal joint arthritis chose surgical excision of the tubercle with concomitant basal joint arthroplasty as initial management. All

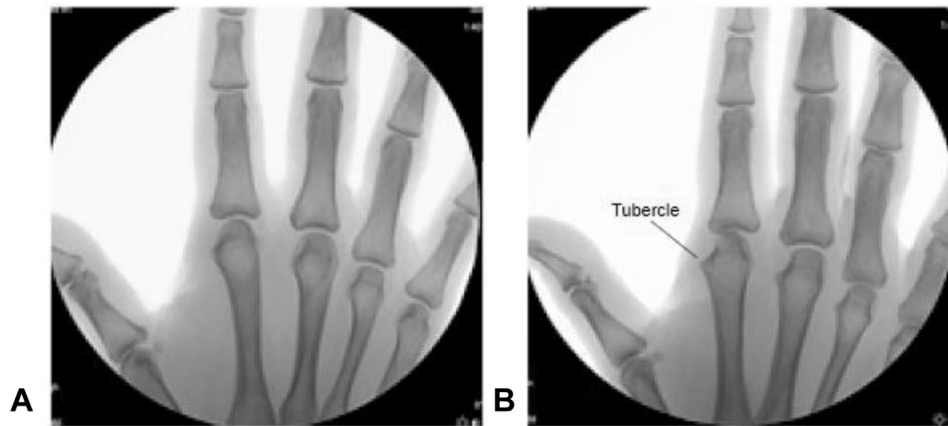
patients who underwent surgical excision reported minimal subjective discomfort and marked improvement in pain at 6 weeks after surgery. There were no recorded complications. Pathologic evaluation of specimens revealed osteochondral and fibrotic soft tissue.

## Discussion

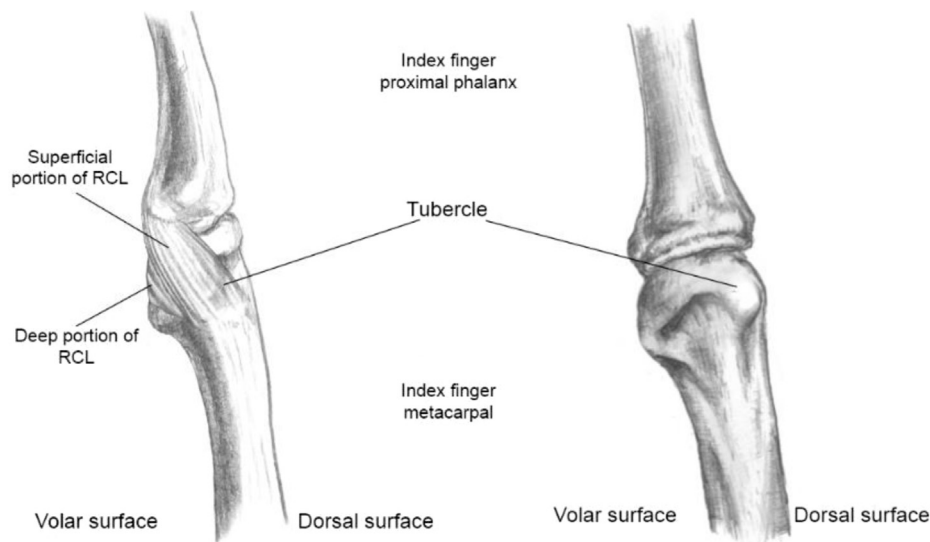
Common causes of hand pain in the vicinity of the index finger MCP joint include stenosing tenosynovitis, ganglion, osteoarthritis, fracture, ligament injury, dislocation, infection, and inflammatory arthropathy. These pathologies are generally easily diagnosed with history, detailed hand examination, simple imaging, and perhaps laboratory work. The patients in this series presented with focal tenderness at the prominence of the index finger metacarpal tubercle. As described, all patients were nontender over the A1 pulley, exhibited no tenderness to palpation at the dorsal surface of the MCP joint, and had no pain on axial load across the MCP joint. Erythema and swelling were absent, and no history of trauma was noted. Pain on stress testing of the radial collateral ligament was variably present, but no patients exhibited instability to ulnar-directed stress testing of that ligament.

We found that the patients demonstrated a prominent-appearing dorsoradial index finger metacarpal tubercle on fluoroscopic or plain film imaging (Fig. 2), which was best visualized using a 45° to 60° pronated oblique view. We believe that this tubercle may be more prominent or enlarged in patients presenting with focal pain at this site, and that an increase in size may also correlate with patients' age. However, we have no objective measurements for comparison. These suspicions are based on subjective clinical experience within this small patient population. Future studies could investigate a correlation between tubercle size in symptomatic individuals (afflicted hand vs contralateral hand) as well as age-matched controls.

We further speculate that the pathophysiology of pain at the prominent index finger metacarpal tubercle may be related to a subacute radial collateral ligament injury owing to its intimate relationship. Radial collateral ligament anatomy at the index MCP joint has been described in detail,<sup>1,2</sup> demonstrating that the ligament consists of a superficial and deep component and has a partial origin in the distal dorsoradial tubercle (Fig. 3). Mild RCL injuries, defined by Gaston and Lourie<sup>3</sup> as grade 1, may present with tenderness to palpation over the RCL but no measured laxity compared with the contralateral digit. This closely mirrors the current patient population, who presented with pain and focal tenderness at the site of origin of the RCL but no observable ligament laxity. We believe these patients may represent a subset of subacute or attritional partial RCL injuries.



**Figure 2.** Fluoroscopy visualizing a prominent bony tubercle on the tubercle on the right index finger metacarpal. **A** Posteroanterior view. **B** Tubercle is best visualized using a 45° to 60° pronated oblique view.



**Figure 3.** Radial collateral ligament at the index finger MCP joint, highlighting its relationship to the tubercle.

The pathophysiology of the prominent nature of the index finger metacarpal tubercle in these patients is also speculative, but it may represent an enthesophyte (a form of bony spur) related to the partially injured RCL. Separate from osteophytes, enthesophytes are typically noted to form at the attachments, or entheses, of tendons and ligaments. These spurs present as irregular outgrowths that extend from bone into tendons or ligaments and can often be detected radiographically.<sup>4</sup> Entesophytes have been postulated to develop as a result of microtears at a ligamentous attachment.<sup>4,5</sup> With this in mind, chronic stress or attrition at the index finger MCP joint RCL could act as a stimulus for bone spur formation and lead to a pronounced metacarpal tubercle.

The anatomical relationship between the tubercle and its ligamentous attachment is likewise relevant during tubercle excision. The primary contribution of the RCL to MCP joint stability has been well-studied.<sup>6,7</sup> Specifically, the superficial portion of the ligament can be disinserted while maintaining strength and stability across the joint.<sup>1,2,6</sup> We believe that this relationship allowed for safe tubercle excision, because none of the patients in the current study undergoing surgical excision demonstrated intraoperative or postoperative joint instability.

In our practice, most patients with index finger metacarpal tubercle pain experienced satisfactory improvement after steroid injection at 4 weeks. Those with recurrence obtained subsequent relief after reinjection or surgical excision, similar to results seen in excision of symptomatic spurs in other problematic areas.<sup>8,9</sup> We found no immediate complications in these patients at treatment completion, which supports our view that steroid injection and surgical excision may be reasonable treatment options for a painful index finger metacarpal tubercle.

Limitations of this series include its retrospective design and that the operating surgeon assessed patients after surgery. In addition, patient outcomes were reported subjectively without using a more objective tool, such as a visual analog scale. Follow-up was also relatively short; however, patients reported improvements as early as a few weeks after surgery. We do not believe that longer follow-up would thus change our results. Strengths of this study include the consecutive patient population and our consistent treatment and surgical techniques.

We identified a subset of patients with problems of index finger pain localized and specific to the index finger metacarpal tubercle. The tubercle can best be detected on 45° to 60° pronated oblique

imaging, and we believe this tubercle is unusually prominent in these patients. We found that steroid injection to the tubercle is a reasonable, minimally invasive initial treatment option, and our experience has been satisfactory results with surgical excision as well.

## References

1. Minami A, An KN, Cooney WP III, Linscheid RL, Chao EY. Ligamentous structures of the metacarpophalangeal joint: a quantitative anatomic study. *J Orthop Res.* 1984;1(4):361–368.
2. Dy CJ, Tucker SM, Kok PL, Hearn KA, Carlson MG. Anatomy of the radial collateral ligament of the index metacarpophalangeal joint. *J Hand Surg Am.* 2013;38(1):124–128.
3. Gaston RG, Lourie GM. Radial collateral ligament injury of the index metacarpophalangeal joint: an underreported but important injury. *J Hand Surg Am.* 2006;31(8):1355–1361.
4. Benjamin M, Rufai A, Ralphs JR. The mechanism of formation of bony spurs (enthesophytes) in the achilles tendon. *Arthritis Rheum.* 2000;43(3):576–583.
5. Rogers J, Shepstone L, Dieppe P. Bone formers: osteophyte and enthesophyte formation are positively associated. *Ann Rheum Dis.* 1997;56(2):85–90.
6. Minami A, An KN, Cooney WP III, Linscheid RL, Chao EY. Ligament stability of the metacarpophalangeal joint: a biomechanical study. *J Hand Surg Am.* 1985;10(2):255–260.
7. Werner D, Kozin SH, Brozovich M, Porter ST, Junkin D, Seigler S. The biomechanical properties of the finger metacarpophalangeal joints to varus and valgus stress. *J Hand Surg Am.* 2003;28(6):1044–1051.
8. Alvi HM, Kalainov DM, Biswas D, Soneru AP, Cohen MS. Surgical management of symptomatic olecranon traction spurs. *Orthop J Sports Med.* 2014;2(7):2325967114542775.
9. Cuono CB, Watson HK. The carpal boss: surgical treatment and etiological considerations. *Plast Reconstr Surg.* 1979;63(1):88–93.